



Article scientifique

Article

2014

Accepted version

Open Access

This is an author manuscript post-peer-reviewing (accepted version) of the original publication. The layout of the published version may differ .

---

## Additive Effect of Repeated Corneal Collagen Cross-linking in Keratoconus

---

Hafezi, Farhad; Tabibian, David; Richoz, Olivier

### How to cite

HAFEZI, Farhad, TABIBIAN, David, RICHOS, Olivier. Additive Effect of Repeated Corneal Collagen Cross-linking in Keratoconus. In: Journal of refractive surgery, 2014, vol. 30, n° 10, p. 716–718. doi: 10.3928/1081597X-20140903-03

This publication URL: <https://archive-ouverte.unige.ch/unige:77474>

Publication DOI: [10.3928/1081597X-20140903-03](https://doi.org/10.3928/1081597X-20140903-03)

See discussions, stats, and author profiles for this publication at: <http://www.researchgate.net/publication/266622800>

# Additive Effect of Repeated Corneal Collagen Cross-linking in Keratoconus

ARTICLE in JOURNAL OF REFRACTIVE SURGERY (THOROFARE, N.J.: 1995) · OCTOBER 2014

Impact Factor: 3.47 · DOI: 10.3928/1081597X-20140903-03 · Source: PubMed

---

READS

148

## 3 AUTHORS:



**Farhad Hafezi**

University of Southern California

187 PUBLICATIONS 3,466 CITATIONS

SEE PROFILE



**David Tabibian**

Hôpitaux Universitaires de Genève

12 PUBLICATIONS 27 CITATIONS

SEE PROFILE



**Olivier Rychoz**

University of Geneva

24 PUBLICATIONS 79 CITATIONS

SEE PROFILE

## Additive Effect of Repeated Corneal Collagen Cross-linking in Keratoconus

Farhad Hafezi, MD, PhD; David Tabibian, MD;  
Olivier Richoz, MD

### ABSTRACT

**PURPOSE:** To report the long-term clinical outcome in a patient diagnosed as having bilateral progressive keratoconus who received a single corneal collagen cross-linking (CXL) treatment in the right eye and repeated CXL in the left eye.

**METHODS:** Observational case report. Topographical changes were assessed by high-resolution Scheimpflug imaging. The right eye underwent a standard epithelium-off CXL procedure in February 2008, followed by the left eye 4 weeks later. In 2012, the left eye was treated with CXL for a second time. Irradiation was performed in all cases at a fluence of 5.4 J/cm<sup>2</sup>. Energy settings were 30 minutes @ 3 mW/cm<sup>2</sup> for the CXL procedures performed in 2008, and 10 minutes @ 9 mW/cm<sup>2</sup> for the second CXL procedure of the left eye that was performed in 2012.

**RESULTS:** The right eye that underwent a single CXL procedure showed a flattening of keratometry values between 2008 and 2012, followed by stabilization. The left eye showed a similar flattening effect between 2008 and 2012, followed by another flattening effect after the second CXL procedure and accompanied by a distinct increase in corrected distance visual acuity.

**CONCLUSIONS:** Following repeated CXL, the corneal stroma and endothelium remained inconspicuous, and postoperative haze and visibility of the stromal demarcation line was similar to what is usually observed after a single CXL procedure. Whether the additive flattening effect of the anterior surface observed in this single case goes along with an additive increase in biomechanical stiffness remains to be seen.

[J Refract Surg. 2014;30(10):716-718.]

Corneal collagen cross-linking (CXL) with riboflavin and ultraviolet-A is an established treatment method for progressive keratoconus. CXL

leads to an increase in biomechanical stiffness of the cornea, as shown in numerous studies.<sup>1-3</sup> The mechanism by which this occurs is most probably an increase in cross-links between collagen fibers and also between proteoglycans and collagen.<sup>4</sup>

The success rate of epithelium-off CXL for keratoconus is high.<sup>5</sup> However, sometimes CXL fails to halt disease progression.<sup>6</sup> Here, a repeated treatment might become necessary.

We highlight the case of a patient diagnosed as having bilateral progressive keratoconus who underwent CXL in both eyes in 2008 with bilateral anterior surface remodeling over the following 4 years. In 2012, a second CXL procedure was performed in the left eye only, and 2 years later, the left eye (repeated CXL) showed a second and strong flattening effect, whereas the right eye (single CXL) showed no further curvature changes.

### CASE REPORT

A 32-year-old man with bilateral reduced visual acuity and increasing astigmatism for more than 1 year was referred to the Institute for Refractive and Ophthalmic Surgery in Zurich, Switzerland, in January 2008. Based on previous corneal topographies and Scheimpflug images (Pentacam; Oculus Optikgeräte GmbH, Wetzlar, Germany) taken that day, the diagnosis of bilateral progressive keratoconus was made: the right and left eye showed maximum keratometry values of 48.0 and 46.6 diopters (D), respectively. Minimum corneal thickness was 442 µm in the right eye and 448 µm in the left eye. Corneal thickness was determined optically using Scheimpflug images (Pentacam) preoperatively and for all follow-up measurements. Corrected distance visual acuity (CDVA) with glasses was 20/20 for the right and left eyes, with a manifest refraction of -1.5 -0.25 × 177 for the right eye and -1.25 -0.5 × 102 for the left eye.

After discussing with the patient, we decided to perform CXL in both eyes. In February and March 2008, epithelium-off CXL procedures were performed in the right and left eyes, according to the standard Dresden protocol (fluence: 5.4 J/cm<sup>2</sup>; settings: 30 minutes @ 3 mW/cm<sup>2</sup>), using an ultraviolet-A irradiation device with a Gaussian beam profile (UV-X 1000; IROC Inno-cross AG, Zug, Switzerland) and iso-osmolaric riboflavin solution (Peschke Meditrade, Huenenberg, Switzerland). Preoperative stromal thickness was 390 µm in the right eye and 400 µm in the left eye, as measured by ultrasound pachymetry (SP-100; Tomey Corporation, Gamagori, Japan). Postoperatively, 0.3% ofloxacin ointment (Floxal; Bausch & Lomb, Inc., Rochester, NY) was applied every 2 hours during the day and before bed until complete closure of the epithelium, followed by fluorometholone eye drops (FML Liquifilm; Allergan, Inc., Irvine, CA) twice daily for 4 weeks. The

From the Department of Ophthalmology, Geneva University Hospitals, Geneva, Switzerland (FH, DT, OR); and the Department of Ophthalmology, University of Southern California, Keck School of Medicine, Los Angeles, California (FH).

Submitted: June 27, 2014; Accepted: July 14, 2014; Posted online: October 3, 2014

The authors have no financial or proprietary interest in the materials presented herein.

Correspondence: Farhad Hafezi, MD, PhD, Department of Ophthalmology, Geneva University Hospitals, Rue Alcide Jentzer 22, Geneva 14, 1211, Switzerland. E-mail: farhad@hafezi.ch

doi:10.3928/1081597X-20140903-03

postoperative course was uneventful. A demarcation line was noted in both cases at a depth of approximately 300  $\mu\text{m}$  at 4 weeks after the procedure.

#### RIGHT EYE

The right eye showed 1.8 D of regression of maximum keratometry values between March 2008 and March 2012 (**Figures 1A-1B**). In the 2 years thereafter, the flattening effect (**Figure 1C**) stabilized and CDVA in the right eye in May 2014 was 20/20 with a manifest refraction of  $-0.25 -1.0 \times 85$ .

#### LEFT EYE

Between 2008 and 2012, the left eye showed distinct remodeling with central flattening of up to 4 D, but also an increase of maximum keratometry values from 46.6 to 47.8 D (**Figures 1D-1E**). In March 2012, we performed a second CXL procedure with the same technical specifications as in 2008, but with one exception: we administered the total fluence within 10 minutes @ 9 mW/cm<sup>2</sup> (CXL-365, Peschke Meditrade). Postoperative care was similar to 2008 and uneventful. More specifically, the corneal endothelium showed no signs of decompensation, the haze was comparable to that seen after the first CXL procedure, and the demarcation line was visible at 4 weeks after CXL at a depth of 250 to 300  $\mu\text{m}$ .

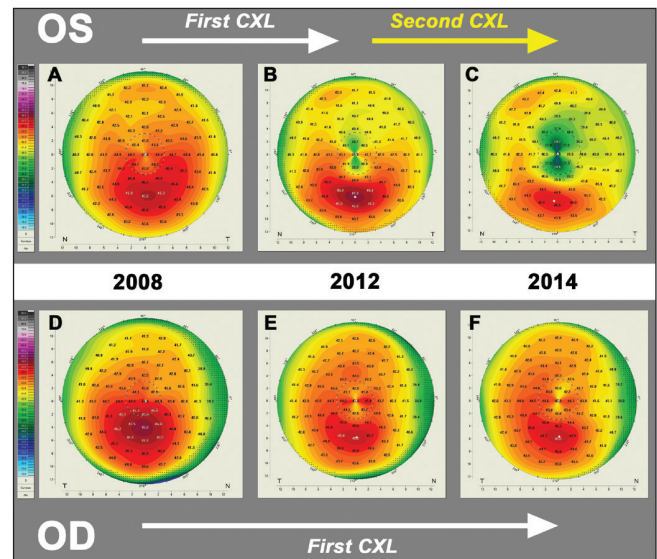
In 2014 (2 years after the repeated CXL procedure), the left eye showed a maximum keratometry value of 45.5 D and a further flattening effect of another 4 D (**Figure 1F**), for a total flattening of 8 D between 2008 and 2014. CDVA was 20/32 with a manifest refraction of  $+6.5 -4.0 \times 91$ .

#### DISCUSSION

The distinct additive remodeling that we observed on the anterior surface of the left cornea after the repeated CXL procedure may not necessarily imply a concomitant increase in corneal stiffness. At the time the initial CXL procedure was performed, we did not yet routinely assess corneal biomechanics in vivo with the Ocular Response Analyzer (Reichert Technologies, Depew, NY), and high-speed Scheimpflug imaging (CorVis; Oculus Optikgeräte GmbH) and Brillouin microscopy were not developed yet.<sup>2</sup>

After a retrospective analysis of the corneal topographical data, the repeated CXL procedure in the left cornea might not have been unequivocally necessary because the observed increase in maximum keratometry values of the inferior mid-periphery might have been a response to the central flattening rather than true keratoconus progression.

Beshtawi et al. recently reported on biomechanical changes induced by repeated CXL in ex vivo human



**Figure 1.** Corneal topography by Scheimpflug imaging (Pentacam HR; Oculus Optikgeräte GmbH, Wetzlar, Germany) in a patient with bilateral progressive keratoconus. Left eye: when compared to the (A) preoperative state, there was a progressive decrease of the keratometric values at (B) 4 years after corneal collagen cross-linking (CXL). (C) Between 4 and 6 years after CXL, no further flattening was observed. Right eye: (D) corneal topography taken prior to CXL showed keratoconus. (E) Remodeling of the anterior surface was observed at 4 years after the first CXL procedure. (F) A repeated CXL was performed and another remodeling effect occurred 2 years later.

corneas using scanning acoustic microscopy, a technology determining changes in the speed of sound in collagen directly relating to biomechanical stiffness. Interestingly, samples that were cross-linked two or three times failed to show an additive increase in speed of sound and stiffness when compared to samples that underwent CXL only once.<sup>7</sup>

Several experimental differences make it hard to compare these results with our own observation. First, repetitive CXL was performed within 24 hours in an ex vivo tissue, which only allowed immediate and mid-term changes to occur after CXL, whereas in our case, 4 years passed between the two procedures, allowing for long-term changes. Second, the average age of donor corneas was 75 years, whereas our patient was 32 years old. This difference in age might have several implications. A cornea stiffens significantly with age.<sup>8</sup> Also, approximately 20% of the elderly show high glycemia, and diabetes goes along with increased biomechanical stiffness.<sup>9</sup> Finally, the percentage of smokers is considerably higher in the elderly, and smoking increases corneal stiffness.<sup>10</sup>

On another note, the left eye presented maximum keratometry values before CXL that were lower than maximum keratometry values of the right eye. One might speculate that the flatter (left) cornea showed a different reaction in remodeling when compared to the steeper (right) cornea.

Our patient showed a stromal haze and demarcation line similar to what is usually observed after a single CXL procedure. On the other hand, repeated CXL led to an additive flattening effect of the anterior surface. Whether this implies an additive increase in biomechanical stiffness remains to be seen.

#### AUTHOR CONTRIBUTIONS

Study concept and design (FH); data collection (FH); analysis and interpretation (FH, DT, OR); drafting of the manuscript (FH); critical revision of the manuscript (FH, DT, OR); supervision (FH)

#### REFERENCES

1. Raiskup F, Spoerl E. Corneal crosslinking with riboflavin and ultraviolet A: I. Principles. *Ocul Surf*. 2013;11:65-74.
2. Scarcelli G, Kling S, Quijano E, Pineda R, Marcos S, Yun SH. Brillouin microscopy of collagen crosslinking: noncontact depth-dependent analysis of corneal elastic modulus. *Invest Ophthalmol Vis Sci*. 2013;54:1418-1425.
3. Wollensak G, Spoerl E, Seiler T. Stress-strain measurements of human and porcine corneas after riboflavin-ultraviolet-A-induced cross-linking. *J Cataract Refract Surg*. 2003;29:1780-1785.
4. Zhang Y, Conrad AH, Conrad GW. Effects of ultraviolet-A and riboflavin on the interaction of collagen and proteoglycans during corneal cross-linking. *J Biol Chem*. 2011;286:13011-13022.
5. Koller T, Mrochen M, Seiler T. Complication and failure rates after corneal crosslinking. *J Cataract Refract Surg*. 2009;35:1358-1362.
6. Hafezi F. Limitation of collagen cross-linking with hypotonic riboflavin solution: failure in an extremely thin cornea. *Cornea*. 2011;30:917-919.
7. Beshtawi IM, Akhtar R, Hillarby MC, et al. Biomechanical changes after repeated collagen cross-linking on human corneas assessed in vitro using scanning acoustic microscopy. *Invest Ophthalmol Vis Sci*. 2014;55:1549-1554.
8. Elsheikh A, Geraghty B, Rama P, Campanelli M, Meek KM. Characterization of age-related variation in corneal biomechanical properties. *J R Soc Interface*. 2010;7:1475-1485.
9. Seiler T, Huhle S, Spoerl E, Kunath H. Manifest diabetes and keratoconus: a retrospective case-control study. *Graefes Arch Clin Exp Ophthalmol*. 2000;238:822-825.
10. Hafezi F. Smoking and corneal biomechanics. *Ophthalmology*. 2009;116:2259.e1.