



Article scientifique

Article

2022

Published version

Open Access

This is the published version of the publication, made available in accordance with the publisher's policy.

Diagnostic value and prognostic significance of MRI findings in sudden sensorineural hearing loss

Todic, Jelena; Guinand, Nils; Lenoir, Vincent; Senn, Pascal; Becker, Minerva






How to cite

TODIC, Jelena et al. Diagnostic value and prognostic significance of MRI findings in sudden sensorineural hearing loss. In: Laryngoscope investigative otolaryngology, 2022, p. lio2.922. doi: 10.1002/lio2.922

This publication URL: <https://archive-ouverte.unige.ch/unige:163433>

Publication DOI: [10.1002/lio2.922](https://doi.org/10.1002/lio2.922)

Diagnostic value and prognostic significance of MRI findings in sudden sensorineural hearing loss

Jelena Todic MD¹  | Nils Guinand MD¹  | Vincent Lenoir MD²  |
Pascal Senn MD¹  | Minerva Becker MD² 

¹Department of Clinical Neurosciences, Clinic of Otorhinolaryngology Head and Neck Surgery, Geneva University Hospitals, University of Geneva, Geneva, Switzerland

²Diagnostic Department, Division of Radiology, Geneva University Hospitals, University of Geneva, Geneva, Switzerland

Correspondence

Minerva Becker, MD, Diagnostic Department, Division of Radiology, Geneva University Hospitals, University of Geneva, Rue Gabrielle-Perret-Gentil 4, Geneva CH-1205, Switzerland.

Email: minerva.becker@hcuge.ch

Present address

Jelena Todic, Department of Surgery, Clinic of Otorhinolaryngology Head and Neck Surgery, CHUV, University of Lausanne, Lausanne, Switzerland.

Abstract

Purpose: We evaluated the clinical significance of magnetic resonance imaging (MRI) findings and their prognostic value for initial hearing loss and recovery in patients with sudden sensorineural hearing loss (SSNHL).

Materials and Methods: This retrospective study included consecutive adult patients with unilateral SSNHL, contrast-enhanced MRI and audiometric testing evaluated in our institution between 2005 and 2017. MRI reports, patient data, treatment, and audiometric tests were reviewed, with the relationship between MRI findings and hearing loss/recovery analyzed.

Results: Overall, 266 patients were included. Additional symptoms comprised tinnitus (114/266; 43%), vertigo (45/266; 17%), ear pain (26/266; 10%), and ear pressure (6/266; 2%). At least one cardiovascular risk factor (hypertension, diabetes, hypercholesterolemia, cardiopathy, and active smoking) existed in 167/266 (63%) patients. Corticosteroid treatment was followed by 198/266 (74%) patients while contraindications/refusal/compliance precluded treatment in 68/266 (26%). Complete, partial or slight hearing recovery occurred in 167/266 (63%) patients. Three MRI patient groups were identified: a group with normal MRI examinations or incidentalomas (128/266; 48%), a group with peripheral auditory system (PAS) lesions (95/266; 36%), and a group with central nervous system (CNS) lesions (43/266; 16%). PAS lesions included lesions from the cochlea to the brain stem (e.g., schwannoma, meningioma, labyrinthitis, intracochlear hemorrhage, vestibulocochlear neuritis), whereas CNS lesions corresponded in 42/43 (98%) of cases to leukoariosis and other vascular lesions (e.g., stroke, hemorrhage, aneurysm, venous sinus thrombosis, and cavernoma). Belonging to one of the three MRI groups did not influence the degree of initial hearing loss, affected frequencies or treatment, $p > .05$. Gender and cardiovascular risk factors did neither affect initial hearing loss nor recovery. However, age > 70 years negatively affected initial hearing loss in all frequencies, as well

Pascal Senn and Minerva Becker shared last authorship.

This is an open access article under the terms of the [Creative Commons Attribution-NonCommercial-NoDerivs](https://creativecommons.org/licenses/by-nc-nd/4.0/) License, which permits use and distribution in any medium, provided the original work is properly cited, the use is non-commercial and no modifications or adaptations are made.

© 2022 The Authors. *Laryngoscope Investigative Otolaryngology* published by Wiley Periodicals LLC on behalf of The Triological Society.

as recovery in all frequencies except 1000 Hz. Also, poor recovery of initial high-frequency hearing loss (>1000 Hz) was significantly associated with CNS lesions.

Conclusion: Age > 70 years and CNS lesions depicted by MRI independently predicted poor auditory recovery, albeit in different frequencies.

Lay Summary: In patients with sudden hearing loss, older age (above 70 years) predicts poorer hearing recovery than in younger patients in most hearing frequencies. In addition, abnormalities of brain tissue revealed by MRI predict poorer hearing recovery at high frequencies.

Level of Evidence: Level III.

KEYWORDS

hearing loss, hearing recovery, magnetic resonance imaging (MRI), prognosis, sudden sensorineural hearing loss (SSNHL)

1 | INTRODUCTION

Sudden sensorineural hearing loss (SSNHL) is still a poorly understood entity.¹ It is defined as hearing loss of >30 dB on three sequential frequencies of a tonal audiogram within 3 days. The incidence varies from 5 to 160 per 100,000 persons per year.²⁻⁷ SSNHL occurs at any age⁴ and all hearing frequencies can be affected, with tinnitus additionally seen in 80% of patients, and vertigo in 30%.⁶ Hearing loss severity varies, and its social impact ranges from moderate to severe disability.^{1,7} Rapid diagnosis is essential for implementing effective treatment to maximize the chances of hearing recovery.

SSNHL is classified as idiopathic in most cases,⁸ etiologic factors being identified in 7%–45% of cases.⁹ In a meta-analysis including 23 articles, the main SSNHL causes were infectious (13%), otological (5%), traumatic (4%), vascular (3%), neoplastic (2%), and autoimmune (2%).¹⁰ Magnetic resonance imaging (MRI) identifies hearing loss etiology in 4%–7% of patients.¹¹ According to the American Academy of Otorhinolaryngology-Head and Neck Surgery Foundation (AAO-HNSF) guidelines, MRI of the brain and temporal bone with intravenous gadolinium-based contrast media is recommended in the initial SSNHL assessment.

Although multiple authors have analyzed the incidence, anatomical location, and etiology of MRI abnormalities in patients with SSNHL, only a handful of studies based on a small number of patients has evaluated the prognostic value of certain MRI abnormalities, for example, inner ear lesions or white matter hyperintensity on hearing recovery.¹²⁻¹⁵ Other authors have focused only on the prognostic value of clinical symptoms and laboratory findings on hearing recovery without taking MRI findings into consideration.¹⁶⁻¹⁹ The results of these different studies are somewhat contradictory and the relationship between clinical findings and MRI lesions is not completely understood neither regarding initial hearing loss nor hearing recovery. The objectives of the current study were to assess the incidence of MRI-detected lesions in a consecutive series of patients with unilateral SSNHL seen over a 12-year period, to evaluate the relationship

between clinical and MRI findings with respect to initial hearing loss, and to assess the prognostic value of clinical and MRI findings for hearing recovery.

2 | MATERIALS AND METHODS

2.1 | Patients

This retrospective monocentric study was approved by the institutional ethics committee and was performed according to the guidelines of the Helsinki II Declaration. To avoid selection bias, a search conducted using the RIS-PACS system of the radiology department in our institution retrieved 298 consecutive patients with SSNHL who underwent MRI and audiometric assessment between 2005 and 2017. Overall, 32 patients were excluded from the study because of bilateral SSNHL ($n = 3$), acute middle ear infection ($n = 27$), and previous SSNHL ($n = 2$). Therefore, 266 patients were included in the analysis. Age, gender, and SSNHL onset date were collected, as were affected side, synchronous dizziness, tinnitus, ear pressure, or pain, otological findings, cardiovascular risk factors, prior or subsequent stroke, and treatment type.

2.2 | Audiometric assessment and MRI imaging

Audiometric evaluation was performed upon diagnosis at the first visit (V0) in the Otorhinolaryngology Head and Neck Surgery Clinic and at subsequent follow-up or at the end of treatment (V1). Hearing measurements were conducted using tonal audiograms at 0.15, 0.25, 0.5, 1, 2, 4, 6, and 8 kHz. The mean hearing threshold was measured at V0 and V1, the difference being expressed in decibels (Δ dB). Hearing recovery was deemed present if Δ dB of mean hearing thresholds were ≥ 15 or if final mean hearing threshold was <25 dB.²⁰ Initial and final hearing loss severity was classified as mild (26–40 dB HL),

moderate (41–55 dB HL), moderately severe (56–70 dB HL), severe (71–90 dB HL), and profound (>90 dB) using Siegel's criteria.²¹

All MRI examinations comprised brain and dedicated temporal bone imaging at 1.5 or 3 T, with MRI scans interpreted by experienced radiologists. Brain sequences included T2, FLAIR, diffusion weighted imaging, T1 ± iv. contrast material, 3DTOF angiography, and post-contrast 3DT1. High-resolution 3DT2 and 3D contrast-enhanced T1 (voxel = 0.5–0.8 mm) were used for temporal bone imaging. In addition, in five patients, delayed post-contrast FLAIR imaging was available. MRI examinations were retrospectively categorized as normal (no abnormalities), displaying peripheral auditory system (PAS) lesions, central nervous system (CNS) lesions, or incidentalomas not-SSNHL-related. PAS lesions included abnormalities from the cochlea to the brainstem, CNS involvement included lesions between the brainstem and cortex, while MRI incidentalomas consisted of fortuitously-discovered abnormalities, unrelated to clinical symptoms, which were then assigned to the normal MRI group for analysis. For classification and statistical analysis, PAS and CNS lesions primed over incidentalomas; therefore, patients with PAS or CNS abnormalities and simultaneous incidentalomas were categorized as belonging to the PAS and CNS group, respectively.

2.3 | Statistical analysis

The statistical program R was employed for analysis. Non-parametric tests (Kruskal–Wallis and Mann–Whitney Wilcoxon) were used to compare hearing loss distribution in the three MRI groups (normal and incidentalomas, PAS lesions, and CNS lesions). In addition, a linear mixed effect model with random effect for the subject estimated on the square root of the average hearing threshold was used, MRI being the principal covariate, with data dichotomized into the categories “MRI with CNS lesions” and “all other” (i.e., normal MRI, MRI with incidentalomas, and MRI with PAS lesions). The model was adjusted for age, gender, and cardiovascular risk factors at baseline visit (V0). The variable visit (V1 = first follow-up visit) was used to capture the progression of hearing recovery between the two visits, with estimations for all frequencies together, 1000 Hz, <1000 Hz, and >1000 Hz. The interaction between MRI and visit introduced the possibility to have a different progression for the two MRI categories, while the interaction between age and visit introduced the possibility to have a different progression according to the age of the patient.

3 | RESULTS

3.1 | Overall clinical data at the first visit (V0)

Of the 266 patients, 137/266 (51.5%) were men and 129/266 (48.5%) were women. Mean age was 52 years. The left ear was affected in 146/266 (55%), and the right in 120/266 (45%). Overall, 75/266 (28%) patients complained of isolated hearing loss, and 191/266 (72%) of

synchronous symptoms, that is, tinnitus 114/266 (43%), vertigo 45/266 (17%), pain 26/266 (10%), and ear pressure 6/266 (2%).

Besides, 167/266 (63%) patients displayed at least one cardiovascular risk factor: hypertension 52/167 (31%), hypercholesterolemia 23/167 (13.7%), diabetes 28/167 (16.7%), cardiopathy 17/167 (10%), and active smoking 31/167 (18.7%). Overall, 23/266 (8.6%) patients exhibited at least two cardiovascular risk factors, and 10/266 (3.8%) at least three. Stroke occurred in 16/167 (9.6%) patients within 6 months of SSNHL.

3.2 | Initial treatment

Among all patients, 198/266 (74.4%) were treated, while 68/266 (25.6%) were not because of lacking compliance, comorbidities contraindicating systemic corticosteroids, or refusal of intra-tympanic corticosteroid administration. Concerning treatment, which was started at V0, 192/266 (72.2%) patients received oral corticosteroids (prednisone, 1 mg/kg during 7.5 days), 2/266 (0.7%) intravenous cortisone (methylprednisolone, 250 mg 1×/day for 2 days), and 4/266 (1.5%) intra-tympanic corticosteroid injections (triamcinolone suspension, 10 mg/ml, one injection). Mean treatment duration was 7.5 ± 3.2 days.

3.3 | MRI results

MRI examinations were normal in 88/266 (33%). PAS lesions were detected in 95/266 (35.7%) patients, CNS lesions in 43/266 (16.2%), and incidentalomas unrelated to SSNHL in 40/266 (15%).

3.3.1 | Peripheral auditory system (PAS) lesions

Concerning PAS lesions, 67/95 (69.8%) were on the same side as SSNHL, in 13/95 (13.5%) contralateral, and in 16/95 (16.7%) bilateral despite unilateral symptoms. Overall, 33/95 (35%) patients exhibited inflammatory lesions with contrast enhancement on MRI (labyrinthitis in 25 cases and cochleovestibular neuritis in 8 cases, all of which disappeared on follow-up MRI scans), 21/95 (22%) neurovascular conflicts, 20/95 (21%) mass-like lesions, 15/95 (16%) superior semicircular canal dehiscence, 3/95 (3%) endolymphatic hydrops, 2/95 (2%) intra-cochlear hemorrhage, and 1/95 (1%) cochlear nerve hypoplasia. Among mass-like lesions, we identified 13/95 (13.6%) schwannomas, 2/95 (2%) meningiomas, and 5/95 (5.2%) arachnoid or dermoid cysts with severe cochleovestibular nerve displacement. Concerning localization, 7/13 schwannomas were located in the internal auditory canal, and 6/13 schwannomas in the labyrinth.

3.3.2 | CNS lesions

CNS lesions found in 43/266 (16.2%) patients included vascular lesions in 14/43 (32.5%) patients (stroke, hemorrhage, aneurysm,

and dural venous sinus thrombosis), leukoaraiosis in 23/43 (53.5%), and 6/43 (14%) congenital malformations (cavernoma/cavernomatosis, $n = 2$; Arnold Chiari, $n = 1$; developmental venous anomalies, $n = 3$).

3.3.3 | Incidentalomas

Incidentalomas were found in 40/266 (15%) patients. They were located in the paranasal sinuses ($n = 12/40$, 30%), nasopharynx ($n = 9/40$, 22.5%), temporomandibular joints ($n = 7/40$, 17.5%), salivary glands ($n = 6/40$, 15%), pituitary gland ($n = 3/40$, 7.5%), and other locations ($n = 3/40$, 7.5%). Paranasal sinus abnormalities included 1/12 polyp, 1/12 submucosal cyst, and 10/12 sinusitis. In the nasopharynx, 2/9 patients had Thorwald's cysts, and 7/9 lymphoid hyperplasia. The temporomandibular joint exhibited joint effusion in 5/7 patients and severe osteoarthritis in 2/7. Sialadenitis was identified in 2/6 patients and parotid tumors in 4/6. Three pituitary microadenomas were found, with neck lipoma and dysthyroid orbitopathy being further detected anomalies. Incidentalomas exerted a clinical impact in 10/40 patients, with 6/40 (15%) undergoing surgery and 4/40 necessitating follow-up. Further radiological examinations occurred in 6/40 patients.

3.4 | Correlation of MRI abnormalities with hearing loss

The association between MRI abnormalities and their likelihood of causing SSNHL was assessed according to their location and relationship to the cochleovestibular nerve and the central auditory system pathways. Peripheral or central auditory system abnormalities on MRI were classified as of certain etiology in 26/266 (9.8%) patients. In 47/266 (17.7%) patients, ipsilateral abnormalities were classified as having a possible association with SSNHL whereas in 45/266 (16.9%) patients, etiologies were classified as having a weak association with SSNHL. Lesions with weak associations included CNS abnormalities affecting the central auditory integration pathways and superior semicircular canal dehiscence.

3.5 | Clinical features and treatment in the three MRI groups

Among the three MRI groups (normal and incidentalomas, PAS lesions and CNS lesions), no difference was detected for age, gender, clinical symptoms, cardiovascular risk factors, percentage of treated versus non-treated patients and type of treatment (Table 1).

TABLE 1 Clinical variables and comparison between the three MRI groups with SSNHL ($n = 266$ patients)

Clinical variables	Normal MRI and MRI with incidentalomas ($n = 128$)	MRI with PAS lesions ($n = 95$)	MRI with CNS lesions ($n = 43$)	p -value (comparison of all three groups)	p -value for comparing "MRI with CNS lesions" versus "all other"
Age, mean (\pm SD)	50.7 (\pm 14.5)	51.1 (\pm 17.5)	54.3 (\pm 16.7)	.435 ^a	.200 ^b
Women, n (%)	57 (44.5)	51 (53.7)	21 (48.8)	.400 ^c	1.000 ^c
Tinnitus, n (%)	57 (44.5)	39 (41.1)	18 (41.9)	.865 ^c	1.000 ^c
Vertigo, n (%)	16 (12.5)	18 (18.9)	11 (25.6)	.113 ^c	.152 ^c
Pain, n (%)	11 (8.6)	9 (9.5)	6 (14)	.573 ^d	.397 ^d
Ear pressure, n (%)	4 (3.1)	2 (2.1)	0 (0)	.755 ^d	.309 ^d
Infection, n (%)	13 (10.2)	12 (12.6)	7 (16.7)	.492 ^d	.297 ^d
Hypertension, n (%)	24 (18.8)	20 (21.1)	8 (18.6)	.899 ^c	1.000 ^c
Hypercholesterinemia, n (%)	7 (5.5)	11 (11.6)	5 (11.6)	.185 ^d	.551 ^d
Diabetes, n (%)	9 (7)	12 (12.6)	7 (16.3)	.148 ^d	.181 ^d
Cardiopathy, n (%)	7 (5.5)	4 (4.2)	6 (14)	.105 ^d	.039 ^d
Tobacco, n (%)	22 (17.2)	8 (8.4)	7 (16.3)	.143 ^d	.633 ^d
Stroke, n (%) ^e	8 (6.2)	3 (3.2)	5 (11.6)	.156 ^d	.150 ^d
Treatment, n (%) ^f	95 (74.2)	74 (77.8)	29 (67.49)	.426 ^c	.251 ^c

Note: Analysis of clinical variables based on MRI results. The p -value is calculated by comparing the three patient groups first and then by comparing the category "MRI with CNS lesions" with the category "all others" (i.e., the group with normal MRI and incidental MRI findings and the group with PAS lesions).

Abbreviations: CNS, central nervous system; MRI, magnetic resonance imaging; n , number; PAS, peripheral auditory system; SD, standard deviation.

^aANOVA test.

^bTwo sample t -test.

^cChi-squared test.

^dFischer's exact test.

^eStroke in the normal MRI group and in the MRI group with PAS lesions occurred within 6 months after MRI.

^fTreatment consisted of oral corticoids in 192/266 (72.2%), iv. corticoids in 2/266 (0.7%) and topic corticoids in 4/266 (1.5%) with a similar distribution among all MRI groups.

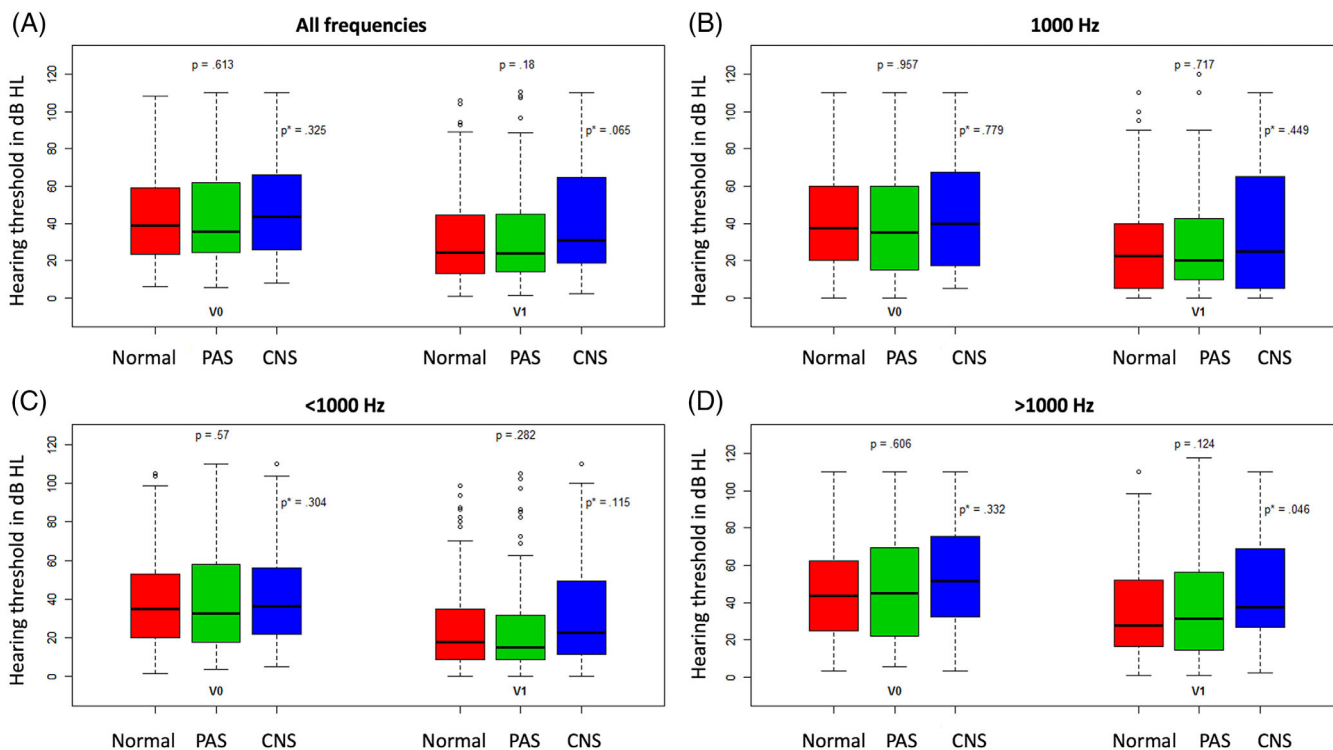


FIGURE 1 Boxplots of hearing thresholds (in dB HL) for the three MRI groups at V0 and at V1. (A) Boxplots for all frequencies together. (B) Boxplots for 1000 Hz. (C) Boxplots for frequencies <1000 Hz. (D) Boxplots for frequencies >1000 Hz. Horizontal lines indicate median values (black lines), the bottom and the top of the box indicate the first and third quartile whereas whiskers indicate the minimum and maximum values. Outliers are indicated by circles. In red, group of patients with normal MRI examinations and with incidentalomas not related to SSNHL (Normal). In green, group of patients with MRI abnormalities of the peripheral auditory system (PAS). In blue, group of patients with CNS abnormalities at MRI (CNS). Note that hearing loss is generally lower at the second visit (V1), illustrating hearing recovery. At each visit “p” is the p-value of a Kruskal-Wallis test that compares hearing loss between the three MRI groups. p* is the p-value of the Mann-Whitney Wilcoxon test of the comparison between hearing loss in the CNS group versus the other MRI groups together.

TABLE 2 Estimates (E) and p-values obtained with a linear mixed effect model with random effect for the subject estimated on the square root of the hearing threshold

SSNHL	All frequencies		1000 Hz		<1000 Hz		>1000 Hz	
	E	p-value	E	p-value	E	p-value	E	p-value
Intercept	6.344	<.001	5.959	<.001	5.772	<.001	6.620	<.001
MRI with CNS lesions	0.132	.688	-0.075	.855	0.253	.489	0.084	.809
Visit = V1	-1.104	<.001	-1.289	<.001	-1.288	<.001	-0.973	<.001
Age	0.036	<.001	0.037	<.001	0.026	.003	0.045	<.001
(MRI with CNS lesions) *V1	0.332	.114	0.188	.549	0.163	.552	0.419	.046
Age*V1	0.013	.007	0.009	.240	0.013	.044	0.013	.007
Gender	-0.071	.764	0.115	.690	0.182	.478	-0.234	.354
Hypercholesterinemia	0.336	.442	0.168	.753	0.114	.810	0.474	.309
Diabetes	0.388	.346	0.276	.583	0.345	.439	0.468	.286
Cardiopathy	0.736	.141	1.215	.047	0.882	.104	0.627	.240
Smoking	-0.611	.075	-1.028	.015	-0.854	.022	-0.412	.260

Note: MRI is the principal covariate and is dichotomized into “MRI with CNS lesions” versus “all others.” The model is adjusted for age, sex and cardiovascular risk factors at baseline visit (V0). The variable visit (V1) captures the progression of hearing recovery between the two visits. (MRI with CNS lesions) *V1 = interaction between MRI category and visit. Age*V1 = interaction between age and visit. Statistically significant values are shown in bold letters.

Abbreviations: CNS, central nervous system; MRI, magnetic resonance imaging.

Likewise, comparing the category “MRI with CNS lesions” with “all other” did not reveal statistically significant differences (Table 1).

3.6 | Initial and follow-up hearing results

The average hearing threshold was 45.03 dB HL at V0 and 34.52 dB HL at V1, respectively. The time interval between V0 and V1 was 15.3 days. Complete hearing recovery at V1 occurred in 109/266 (40.9%) patients, partial recovery in 33/266 (12.4%), slight recovery in 25/266 (9.4%), and no recovery in 99/266 (37.2%). Among the vestibular schwannoma patients, 8/13 (61.5%) presented complete/partial hearing recovery at V1 and 10/13 schwannoma patients benefited from annual MRI examinations with clinical and auditory controls, without requiring surgery. One patient underwent radiosurgery 1-year post-diagnosis, while another patient died from another condition 1-year post-diagnosis. Among the 133/266 (50%) patients evaluated clinically at 3 months after V0, 70% reported improved hearing.

3.7 | Hearing recovery based on MRI results

Among patients with normal MRI examinations or incidentalomas, 71/128 (55.5%) presented complete/partial hearing recovery, and 57/128 (44.5%) slight/no recovery. Among patients with PAS lesions, 52/95 (54.8%) displayed complete/partial hearing recovery, and 43/95 (45.2%) slight/no recovery. Among patients with schwannomas, 8/13 (61.5%) exhibited complete/partial hearing recovery. Among patients with CNS lesions, 19/43 (44.2%) experienced complete/partial recovery, and 24/43 (55.8%) slight/no hearing recovery.

Belonging to one of the three MRI groups (Figure 1) neither impacted initial hearing loss, $p = .613$, nor hearing frequencies (<1000 Hz, $p = .57$; 1000 Hz, $p = .957$; >1000 Hz, $p = .606$). Also, belonging to one of the three MRI groups did not influence overall hearing recovery ($p = .18$) nor recovery at specific frequencies (<1000 Hz, $p = .282$; 1000 Hz, $p = .717$; >1000 Hz, $p = .124$). When comparing the category “MRI with CNS involvement” with the category “all other,” overall hearing loss was similar ($p > .05$). Although overall audiometric recovery was similar ($p = .065$), it varied according to frequencies, with CNS lesion patients experiencing significantly poorer recovery in high frequencies compared to all others (>1000 Hz, $p = .046$, Figure 1).

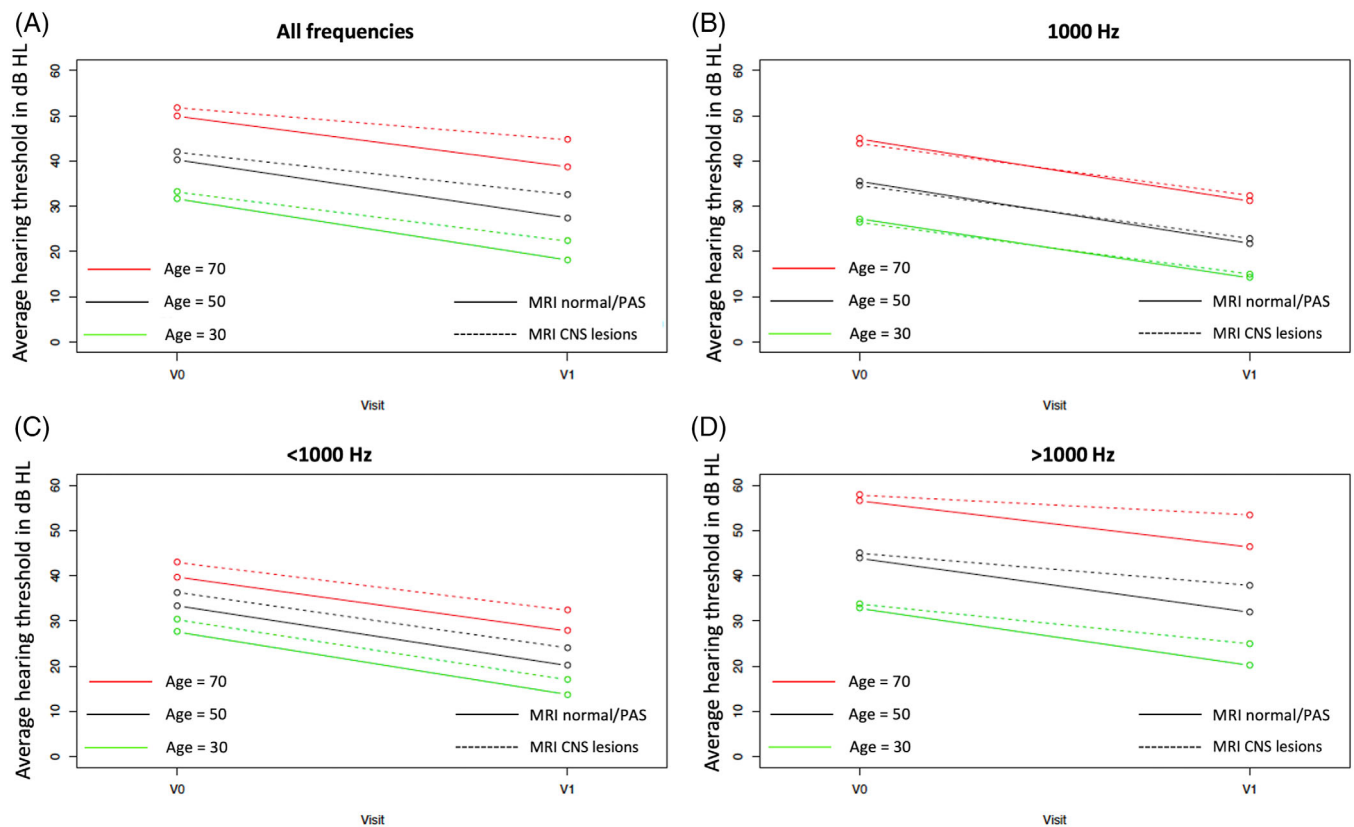


FIGURE 2 Average hearing threshold in dB HL estimated at V0 and V1 for three age values (30, 50, and 70 years) and for the two categories of the MRI variable (“MRI with CNS lesions” versus “all other”). (A) Estimated hearing loss and recovery for all frequencies together. (B) Estimated hearing loss and recovery for 1000 Hz. (C) Estimated hearing loss and recovery for frequencies <1000 Hz. (D) Estimated hearing loss and recovery for frequencies >1000 Hz. The average hearing thresholds were estimated by the models shown in Table 2.

3.8 | Other factors influencing hearing recovery

A linear mixed effect model (as described in the statistical analysis) was applied to compare “MRI with CNS abnormalities” with “all other” (Table 2). Gender or cardiovascular risk factors did not impact initial hearing loss nor recovery in any of the 4 models (all frequencies, 1000 Hz, <1000 Hz and >1000 Hz, $p > .05$, Table 2). However, higher age was associated with a significantly increased initial hearing loss in all models. Hearing recovery between V0 and V1 was significantly impacted by age in three models (all frequencies together, >1000 Hz and <1000 Hz, $p < .05$) but not at 1000 Hz ($p = .240$, Table 2). Belonging to the category “MRI with CNS abnormalities” predicted worse recovery in high frequencies (>1000 Hz, $p = .046$) at V1 but not in the other frequencies (Table 2). Figure 2 shows hearing loss at V0 and recovery at V1 estimated by the four models shown in Table 2 for three age values (30, 50, and 70 years).

4 | DISCUSSION

To the best of our knowledge, this is the largest retrospective study investigating associations between clinical findings (including cardiovascular risk factors) and MRI abnormalities in SSNHL, as well as their prognostic impact on hearing recovery. In our series, 88/266 (33%) patients exhibited normal and 178/266 (67%) abnormal MRI examinations. The prevalence of cardiovascular risk factors was similar in the three MRI groups, that is, normal MRI, MRI with PAS lesions, and MRI with CNS lesions. Gender, cardiovascular risk factors, and belonging to one of the three MRI groups did not affect initial hearing loss. Poor hearing recovery for all frequencies excepting 1000 Hz was significantly associated with age > 70 years, however, neither with gender nor with cardiovascular risk factors. In addition, poor recovery of initial hearing loss in high frequencies (>1000 Hz) was significantly associated with CNS lesions (leukoaraiosis and various lesions of vascular origin) depicted by MRI while recovery in the other frequencies was not.

SSNHL work-up with MRI primarily seeks to exclude morphologic causes including schwannomas,¹¹ other tumors, demyelinating diseases,²² vascular, inflammatory, and hemorrhagic etiologies.^{23,24} Contrast-enhanced MRI is the examination method of choice and several authors have shown that the etiology of SSNHL can be identified by MRI in 7%–57% patients.^{25,26} PAS abnormalities found on MRI, such as labyrinthine hemorrhage, cochlear inflammation or schwannomas reportedly vary between 18% and 31%.²⁷ PAS lesions were the most common abnormalities in our study (35.7%), a finding consistent with other studies.^{23,28} Current MRI sequences can identify intra-labyrinthine hemorrhage and increased protein content, following inflammation or infection^{29,30} while peri-lymphatic contrast enhancement can be precisely evaluated on delayed FLAIR sequences.³¹ Labyrinthine contrast enhancement in SSNHL patients³² was found to correlate with acute inflammation.³⁰ In the current study, we identified 33 patients (12%) with labyrinthine contrast enhancement on MRI non-related to schwannoma and reflecting labyrinthitis. Although contrast

enhancement within the cochlea has been previously associated with poor hearing prognosis,³³ data on reported outcomes are contradictory.³⁰

Endolymphatic hydrops can be diagnosed with delayed FLAIR sequences (obtained 4 h post-contrast injection) due to the delayed accumulation of contrast in the perilymph but not in the endolymph.^{34,35} In the current study, MRI detected cochleovestibular hydrops as a probable cause of SSNHL in 3/266 patients. Nevertheless, delayed FLAIR imaging was available only in five patients as delayed FLAIR is currently not routinely recommended in all SSNHL patients.

Schwannomas are among the most common findings in SSNHL.¹¹ About 10% of patients with cochleovestibular schwannomas exhibit SSNHL as initial symptom ± tinnitus and MRI is the only imaging modality capable of diagnosing these tumors.^{1,36,37} Baird et al.²⁸ analyzed 987 MRIs performed for SSNH or for progressive SNHL. Among 6.9% abnormalities, only 4% were schwannomas. In the current study, MRI detected cochleovestibular schwannomas in 13.6% of patients with PAS lesions and in 4.9% of all SSNHL patients, a finding which is in line with reported data. Among our schwannoma patients, 8/13 (61.5%) presented complete/partial hearing recovery. As suggested by other authors, the therapeutic response to corticosteroid therapy does not exclude schwannoma as diagnosis.³⁸

The reported supra- and infratentorial CNS abnormalities in SSNHL patients are of ischemic origin,³⁹ associated with multiple sclerosis,⁴⁰ or tumors,⁴¹ and brainstem abnormalities are detected in 3% of SSNHL patients.⁴² Hearing loss may be the first warning symptom of an ischemic stroke,⁴³ the risk of stroke at 5 years being 1.64 times higher in SSNHL patients than in controls.⁴⁴ Overall, 10% of the patients in the current study had a stroke within 6 months of the SSNHL episode; the incidence of stroke was, however, similar in all MRI groups. In particular, there was no statistically significant difference regarding stroke incidence between patients with CNS lesions and patients with normal MRI or MRI with PAS lesions (Table 1). According to the literature, SSNHL can occasionally occur as a consequence of basilar artery ischemia, AICA ischemia, extensive bilateral ischemia of the ascending auditory pathways or of both temporal lobes, as well as following sequential bilateral infarctions.^{39,45} Some authors have suggested that SSNHL may result from vascular disruption or ischemia due to pre-existing cardiovascular risk factors.¹⁶ Rudak et al. found that—in comparison to age- and sex-matched controls—smoking and higher fibrinogen plasma levels (as in stroke patients), as well as GPIa C807T polymorphism were associated with an increased risk for SSNHL, however, neither hypercholesterolemia nor hypoalbuminoproteinemia.¹⁷ The authors concluded that vascular involvement may play a role in SSNHL.¹⁷ In contrast, Ballesteros et al. evaluated the presence of genetic and acquired vascular risk factors in 99 patients with SSNHL and found no clear relationship between vascular risk factors and SSNHL, concluding that further studies were necessary to support the hypothesis that SSNHL may represent a vascular symptom.¹⁸ In a retrospective study based on 35 patients with idiopathic SSNHL (17 with hypertension, diabetes mellitus and/or dyslipidemias and 17 patients without associated diseases) Nagaoka

et al. identified a higher prevalence of cerebral microangiopathic changes on MRI scans in patients with associated diseases; in addition, patients with associated diseases were older than patients without associated diseases and they experienced slower hearing recovery in speech discrimination tests.¹² In our study, 63% of the 266 patients with SSNHL presented at least one cardiovascular risk factor, yet without statistically significant differences between the three MRI groups. Although cardiovascular risk factors neither influenced initial hearing loss nor hearing recovery (Tables 1 and 2), CNS anomalies depicted by MRI influenced hearing recovery in high frequencies, whereas recovery in other frequencies was not affected. This effect was independent of age. In the current study, leukoaraiosis represented 53.5% of all CNS anomalies, and 44.2% of the remaining CNS anomalies were of various vascular origin (see Section 3). Leukoaraiosis consists of diffuse alterations of periventricular and subcortical white matter, occurring predominantly in elderly individuals and characterized on MRI by white matter hyperintensity.⁴⁶ The exact etiology is not completely understood: hypoxic-ischemic events caused by small vessel stenosis or occlusion (typically of the thalamostriate and other perforating arteries), blood-brain barrier damage and endothelial dysfunction, as well as subsequent immune and inflammatory activation are thought to play a major role.^{47,48}

Several studies investigated the clinical factors able to predict the probability of later hearing recovery.¹⁹ Poorer hearing recovery was predicted by existing vestibular symptoms and previous hearing loss, these being the only significant predictors.¹⁹ Two studies compared MRI results with auditory recovery, focusing on internal auditory canal abnormalities, hemorrhage, and labyrinth enhancement on standard MRI scans or on delayed MRI scans obtained 4 h after iv. administration of contrast.^{13,14} Compared with patients with normal MRI findings, hearing recovery was worse in patients with PAS abnormalities.^{13,14}

In our study, 63% patients recovered hearing at V1. Age > 70 years was an independent negative prognosticator of hearing recovery for most frequencies excepting 1000 Hz. Our study also showed that although hearing recovery was not affected by cardiovascular factors as assessed by standard clinical and laboratory tests, the presence of CNS lesions detected by MRI (i.e., leukoaraiosis and other vascular lesions) predicted poorer auditory recovery in high frequencies, yet without significant correlations between MRI results and initial hearing impairments. Age and CNS lesions depicted by MRI, therefore, independently predicted poorer recovery albeit in different frequencies. Our study highlights the fact that CNS involvement may play an important role on auditory recovery in SSNHL. In contrast to our study, Lee et al found that the presence of mild degrees of leukoaraiosis was associated with improved hearing gain while patients with more severe leukoaraiosis showed similar hearing recovery as patients without.¹⁵ Further studies to elucidate the effect of leukoaraiosis and other lesions of vascular etiology on hearing recovery are, therefore, warranted.

While MRI-detected incidentalomas are debatable,⁴⁹ their detection had an important clinical impact in 10/40 (25%) of patients with incidentalomas, with 6/40 (15%) undergoing surgery and 4/40 (10%) having clinical follow-up.

Our study has several limitations including follow-up audiograms obtained only at 15 days after SSNHL in all patients and no 3-month follow-up audiograms in 50% patients. Nevertheless, literature reports 65% recovery rates within 14 days, which is comparable to our data. The second study limitation was that 25.6% of patients did not benefit from treatment due to contraindications to corticosteroids, compliance, or refusal. Nevertheless, literature reports a 40% spontaneous recovery rate, in the absence of any treatment.⁵⁰

5 | CONCLUSION

Among 266 patients, 178 (67%) displayed MRI abnormalities, 9.9% of which were etiologically directly correlated with SSNHL, 17.7% possibly correlated, and 16.9% of uncertain correlation. In patients with complete or partial hearing recovery, 76/142 (53.5%) exhibited PAS or CNS abnormalities. Gender, cardiovascular risk factors and belonging to one of the three MRI groups (normal MRI, MRI with PAS lesions, MRI with CNS lesions) did not affect initial hearing loss. Age > 70 years and CNS lesions depicted by MRI (leukoaraiosis and other lesions of vascular origin) independently predicted poorer auditory recovery, albeit in different frequencies.

ACKNOWLEDGMENT

We would like to thank Isabella Locatelli, biomedical statistician at the CHUV for help with statistical analysis.

CONFLICT OF INTEREST

No conflict of interest and no funding for all authors.

ORCID

Jelena Todic  <https://orcid.org/0000-0002-2383-7968>

Nils Guinand  <https://orcid.org/0000-0001-6004-8768>

Vincent Lenoir  <https://orcid.org/0000-0002-8140-8010>

Pascal Senn  <https://orcid.org/0000-0002-4619-3341>

Minerva Becker  <https://orcid.org/0000-0001-9644-9053>

REFERENCES

- Hughes GB, Freedman MA, Haberkamp TJ, Guay ME. Sudden sensorineural hearing loss. *Otolaryngol Clin North Am.* 1996;29(3):393-405.
- Byl FM Jr. Sudden hearing loss: eight years' experience and suggested prognostic table. *Laryngoscope.* 1984;94(5 Pt 1):647-661.
- Wu CS, Lin HC, Chao PZ. Sudden sensorineural hearing loss: evidence from Taiwan. *Audiol Neurootol.* 2006;11(3):151-156.
- Schreiber BE, Agrup C, Haskard DO, Luxon LM. Sudden sensorineural hearing loss. *Lancet.* 2010;375(9721):1203-1211.
- Alexander TH, Harris JP. Incidence of sudden sensorineural hearing loss. *Otol Neurotol.* 2013;34(9):1586-1589.
- Nosrati-Zarenou R, Arlinger S, Hultcrantz E. Idiopathic sudden sensorineural hearing loss: results drawn from the Swedish national database. *Acta Otolaryngol.* 2007;127(11):1168-1175.
- Klemm E, Deutscher A, Mosges R. A present investigation of the epidemiology in idiopathic sudden sensorineural hearing loss. *Laryngorhinootologie.* 2009;88(8):524-527.
- Lin RJ, Krall R, Westerberg BD, Chadha NK, Chau JK. Systematic review and meta-analysis of the risk factors for sudden sensorineural hearing loss in adults. *Laryngoscope.* 2012;122(3):624-635.

9. Kuhn M, Heman-Ackah SE, Shaikh JA, Roehm PC. Sudden sensorineural hearing loss: a review of diagnosis, treatment, and prognosis. *Trends Amplif*. 2011;15(3):91-105.
10. Chau JK, Lin JR, Atashband S, Irvine RA, Westerberg BD. Systematic review of the evidence for the etiology of adult sudden sensorineural hearing loss. *Laryngoscope*. 2010;120(5):1011-1021.
11. Jeong KH, Choi JW, Shin JE, Kim CH. Abnormal magnetic resonance imaging findings in patients with sudden sensorineural hearing loss: vestibular Schwannoma as the most common cause of MRI abnormality. *Medicine*. 2016;95(17):e3557.
12. Nagaoka J, Anjos MF, Takata TT, Chaim RM, Barros F, Penido NO. Idiopathic sudden sensorineural hearing loss: evolution in the presence of hypertension, diabetes mellitus and dyslipidemias. *Braz J Otorhinolaryngol*. 2010;76(3):363-369.
13. Cho J, Cheon H, Park JH, et al. Sudden sensorineural hearing loss associated with inner ear lesions detected by magnetic resonance imaging. *PLoS One*. 2017;12(10):e0186038.
14. Min X, Gu H, Zhang Y, Li K, Pan Z, Jiang T. Clinical value of abnormal MRI findings in patients with unilateral sudden sensorineural hearing loss. *Diagn Interv Radiol*. 2020;26(5):429-436.
15. Lee JW, Kim D, Lee S, et al. The clinical value of periventricular white matter hyperintensity on MRI in sudden sensorineural hearing loss. *Ann Otol Rhinol Laryngol*. 2022;131(3):244-251.
16. Weng SF, Chen YS, Liu TC, Hsu CJ, Tseng FY. Prognostic factors of sudden sensorineural hearing loss in diabetic patients. *Diabetes Care*. 2004;27(10):2560-2561.
17. Rudack C, Langer C, Stoll W, Rust S, Walter M. Vascular risk factors in sudden hearing loss. *Thromb Haemost*. 2006;95(3):454-461.
18. Ballesteros F, Alobid I, Tassies D, et al. Is there an overlap between sudden neurosensorial hearing loss and cardiovascular risk factors? *Audiol Neurootol*. 2009;14(3):139-145.
19. Weiss D, Bocker AJ, Koopmann M, Savvas E, Borowski M, Rudack C. Predictors of hearing recovery in patients with severe sudden sensorineural hearing loss. *J Otolaryngol Head Neck Surg*. 2017;46(1):27.
20. Xie Y, Orabi NA, Zwolan TA, Basura GJ. Outcomes of unilateral idiopathic sudden sensorineural hearing loss: two decades of experience. *Laryngoscope Investig Otolaryngol*. 2019;4(6):693-702.
21. Siegel LG. The treatment of idiopathic sudden sensorineural hearing loss. *Otolaryngol Clin North Am*. 1975;8(2):467-473.
22. Shaia FT, Sheehy JL. Sudden sensori-neural hearing impairment: a report of 1,220 cases. *Laryngoscope*. 1976;86(3):389-398.
23. Fitzgerald DC, Mark AS. Sudden hearing loss: frequency of abnormal findings on contrast-enhanced MR studies. *AJNR Am J Neuroradiol*. 1998;19(8):1433-1436.
24. Marcucci R, Alessandrello Liotta A, Cellai AP, et al. Cardiovascular and thrombophilic risk factors for idiopathic sudden sensorineural hearing loss. *J Thromb Haemost*. 2005;3(5):929-934.
25. Aarnisalo AA, Suoranta H, Ylikoski J. Magnetic resonance imaging findings in the auditory pathway of patients with sudden deafness. *Otol Neurotol*. 2004;25(3):245-249.
26. Ramos HV, Barros FA, Yamashita H, Penido Nde O, Souza AC, Yamaoka WY. Magnetic resonance imaging in sudden deafness. *Braz J Otorhinolaryngol*. 2005;71(4):422-426.
27. Weber PC, Zbar RI, Gantz BJ. Appropriateness of magnetic resonance imaging in sudden sensorineural hearing loss. *Otolaryngol Head Neck Surg*. 1997;116(2):153-156.
28. Baird SM, Nguyen K, Bhatia DDS, Wei BPC. Inner ear and retrocochlear pathology on magnetic resonance imaging for sudden and progressive asymmetrical sensorineural hearing loss. *ANZ J Surg*. 2019;89(6):738-742.
29. Cervantes SS, Barrs DM. Sudden sensorineural hearing loss associated with intralabyrinthine hemorrhage. *Otol Neurotol*. 2015;36(8):e134-e135.
30. Berrettini S, Seccia V, Fortunato S, et al. Analysis of the 3-dimensional fluid-attenuated inversion-recovery (3D-FLAIR) sequence in idiopathic sudden sensorineural hearing loss. *JAMA Otolaryngol Head Neck Surg*. 2013;139(5):456-464.
31. Carfrae MJ, Holtzman A, Eames F, Parnes SM, Lupinetti A. 3 Tesla delayed contrast magnetic resonance imaging evaluation of Meniere's disease. *Laryngoscope*. 2008;118(3):501-505.
32. Sugiura M, Naganawa S, Teranishi M, Nakashima T. Three-dimensional fluid-attenuated inversion recovery magnetic resonance imaging findings in patients with sudden sensorineural hearing loss. *Laryngoscope*. 2006;116(8):1451-1454.
33. Kim DY, Lee JH, Goh MJ, et al. Clinical significance of an increased cochlear 3D fluid-attenuated inversion recovery signal intensity on an MR imaging examination in patients with acoustic neuroma. *AJNR Am J Neuroradiol*. 2014;35(9):1825-1829.
34. Gurkov R, Berman A, Dietrich O, et al. MR volumetric assessment of endolymphatic hydrops. *Eur Radiol*. 2015;25(2):585-595.
35. Voruz F, Lenoir V, Perez Fornos A, Becker M, Guinand N. Meniere's disease, endolymphatic hydrops and MRI. *Rev Med Suisse*. 2018;14(621):1734-1738.
36. Inoue Y, Kanzaki J, Ogawa K. Vestibular schwannoma presenting as sudden deafness. *J Laryngol Otol*. 2000;114(8):589-592.
37. Matthies C, Samii M. Management of vestibular schwannomas (acoustic neuromas): the value of neurophysiology for evaluation and prediction of auditory function in 420 cases. *Neurosurgery*. 1997;40(5):919-929. discussion 29-30.
38. Puccinelli C, Carlson ML. Improvement or recovery from sudden sensorineural hearing loss with steroid therapy does not preclude the need for MRI to rule out vestibular Schwannoma. *Otol Neurotol*. 2019;40(5):674-680.
39. Hausler R, Levine RA. Auditory dysfunction in stroke. *Acta Otolaryngol*. 2000;120(6):689-703.
40. Deroee AF, Huang TC, Morita N, Hojjati M. Sudden hearing loss as the presenting symptom of systemic sclerosis. *Otol Neurotol*. 2009;30(3):277-279.
41. Cadoni G, Cianfoni A, Agostino S, et al. Magnetic resonance imaging findings in sudden sensorineural hearing loss. *J Otolaryngol*. 2006;35(5):310-316.
42. Wu W, Thuomas KA. MR imaging of 495 consecutive cases with sensorineural hearing loss. *Acta Radiol*. 1995;36(6):603-609.
43. Toyoda K, Hirano T, Kumai Y, Fujii K, Kiritoshi S, Ibayashi S. Bilateral deafness as a prodromal symptom of basilar artery occlusion. *J Neurol Sci*. 2002;193(2):147-150.
44. Lin HC, Chao PZ, Lee HC. Sudden sensorineural hearing loss increases the risk of stroke: a 5-year follow-up study. *Stroke*. 2008;39(10):2744-2748.
45. Lee H, Baloh RW. Sudden deafness in vertebrobasilar ischemia: clinical features, vascular topographical patterns and long-term outcome. *J Neurol Sci*. 2005;228(1):99-104.
46. Hachinski VC, Potter P, Merskey H. Leuko-araiosis: an ancient term for a new problem. *Can J Neurol Sci*. 1986;13(4 Suppl):533-534.
47. Marek M, Horyniecki M, Fraczek M, Kluczevska E. Leukoaraiosis - new concepts and modern imaging. *Pol J Radiol*. 2018;83:e76-e81.
48. Moroni F, Ammirati E, Rocca MA, Filippi M, Magnoni M, Camici PG. Cardiovascular disease and brain health: focus on white matter hyperintensities. *Int J Cardiol Heart Vasc*. 2018;19:63-69.
49. Sexton SM. How should we manage incidentalomas? *Am Fam Physician*. 2014;90(11):758-759.
50. Guyot JP, Thielen K. Evolution of sudden deafness without treatment. *Schweiz Med Wochenschr*. 2000;116:935-965.

How to cite this article: Todici J, Guinand N, Lenoir V, Senn P, Becker M. Diagnostic value and prognostic significance of MRI findings in sudden sensorineural hearing loss. *Laryngoscope Investigative Otolaryngology*. 2022;1-9. doi:[10.1002/lio2.922](https://doi.org/10.1002/lio2.922)