



Article scientifique

Article

2020

Published version

Open Access

This is the published version of the publication, made available in accordance with the publisher's policy.

European Society of Coloproctology: guidelines for the management of diverticular disease of the colon

Schultz, J K; Azhar, N; Binda, G A; Barbara, G; Biondo, S; Boermester, M A; Chabok, A; Consten, E C J;
van Dijk, S T; Johanssen, A; Kruis, W; Lambrichts, D; Post, S; Ris, Frédéric [and 8 more]

How to cite

SCHULTZ, J K et al. European Society of Coloproctology: guidelines for the management of diverticular disease of the colon. In: Colorectal Disease, 2020. doi: 10.1111/codi.15140

This publication URL: <https://archive-ouverte.unige.ch/unige:140290>

Publication DOI: [10.1111/codi.15140](https://doi.org/10.1111/codi.15140)

European Society of Coloproctology: guidelines for the management of diverticular disease of the colon

J. K. Schultz* , N. Azhar†‡ , G. A. Binda§, G. Barbara¶ , S. Biondo** ,
M. A. Boermester††, A. Chabok‡‡ , E. C. J. Consten§§¶¶, S. T. van Dijk††,
A. Johanssen*, W. Kruis***, D. Lambrichts††† , S. Post‡‡‡ , F. Ris§§§ ,
T. A. Rockall¶¶¶, A. Samuelsson****††††, S. Di Saverio††††§§§§ , D. Tartaglia¶¶¶¶ ,
A. Thorisson*****††††† , D. C. Winter†††††, W. Bemelman†† and E. Angenete§§§§§††††† 

*Department of Gastrointestinal Surgery, Akershus University Hospital, Lørenskog, Norway, †Colorectal Unit, Department of Surgery, Skåne University Hospital Malmö, Malmö, Sweden, ‡Department of Clinical Sciences, Lund University, Malmö, Sweden, §Colorectal Surgery, BioMedical Institute, Genova, Italy, ¶Department of Medical and Surgical Sciences, University of Bologna, Bologna, Italy, **Department of General and Digestive Surgery – Colorectal Unit, Bellvitge University Hospital, University of Barcelona and IDIBELL, Barcelona, Spain, ††Department of Surgery, Amsterdam Gastroenterology and Metabolism, Amsterdam UMC, location AMC, University of Amsterdam, Amsterdam, The Netherlands, ‡‡Colorectal Unit, Department of Surgery, Centre for Clinical Research Uppsala University, Västmanlands Hospital Västerås, Västerås, Sweden, §§Department of Surgery, Meander Medical Centre, Amersfoort, The Netherlands, ¶¶Department of Surgery, University Medical Center Groningen, Groningen, The Netherlands, ***Faculty of Medicine, University of Cologne, Cologne, Germany, †††Department of Surgery, Erasmus University Medical Center, Rotterdam, The Netherlands, ‡‡‡Mannheim Faculty of Medicine, University of Heidelberg, Mannheim, Germany, §§§Division of Visceral Surgery, Geneva University hospitals and Medical School, Geneva, Switzerland, ¶¶¶Minimal Access Therapy Training Unit (mattu), Royal Surrey County Hospital NHS Trust, Guildford, UK, ****Department of Surgery, NU-Hospital Group, Region Västra Götaland, Trollhättan, Sweden, ††††Department of Surgery, SSORG – Scandinavian Surgical Outcomes Research Group, Institute of Clinical Sciences, Sahlgrenska Academy, University of Gothenburg, Gothenburg, Sweden, ‡‡‡‡Cambridge Colorectal Unit, Cambridge University Hospitals NHS Foundation Trust, Addenbrooke's Hospital, Cambridge, UK, §§§§Department of General Surgery, ASST Sette Laghi, University Hospital of Varese, University of Insubria, Varese, Italy, ¶¶¶¶Emergency Surgery Unit, New Santa Chiara Hospital, University of Pisa, Pisa, Italy, *****Department of Radiology, Västmanland's Hospital Västerås, Västerås, Sweden, †††††Centre for Clinical Research of Uppsala University, Västmanland's Hospital Västerås, Västerås, Sweden, ‡‡‡‡‡St Vincent's University Hospital, Dublin, Ireland, and §§§§§Department of Surgery, Region Västra Götaland, Sahlgrenska University Hospital/Östra, Gothenburg, Sweden

Received 18 March 2020; accepted 7 May 2020; Accepted Article online 18 May 2020

Abstract

Aim The goal of this European Society of Coloproctology (ESCP) guideline project is to give an overview of the existing evidence on the management of diverticular disease, primarily as a guidance to surgeons.

Methods The guideline was developed during several working phases including three voting rounds and one consensus meeting. The two project leads (JKS and EA) appointed by the ESCP guideline committee together with one member of the guideline committee (WB) agreed on the methodology, decided on six themes for working groups (WGs) and drafted a list of research questions. Senior WG members, mostly colorectal surgeons within the ESCP, were invited based on publication records and geographical aspects. Other specialties were included in the WGs where relevant. In addition, one trainee or PhD fellow was invited in each WG. All six WGs revised the research questions if necessary, did a literature search, created evidence tables where feasible, and drafted supporting text to each research question and statement. The text and

statement proposals from each WG were arranged as one document by the first and last authors before online voting by all authors in two rounds. For the second voting ESCP national representatives were also invited. More than 90% agreement was considered a consensus. The final phrasing of the statements with < 90% agreement was discussed in a consensus meeting at the ESCP annual meeting in Vienna in September 2019. Thereafter, the first and the last author drafted the final text of the guideline and circulated it for final approval and for a third and final online voting of rephrased statements.

Results This guideline contains 38 evidence based consensus statements on the management of diverticular disease.

Conclusion This international, multidisciplinary guideline provides an up to date summary of the current knowledge of the management of diverticular disease as a guidance for clinicians and patients.

Correspondence to: Johannes Kurt Schultz, Department of Gastrointestinal Surgery, Akershus University Hospital, Lørenskog, Norway.
E-mail: josc@ahus.no

Introduction

There are currently several national guidelines available from member countries of the European Society of Coloproctology (ESCP) on the management of diverticular disease, some of which are not updated [1–7]. The guidelines committee of the ESCP decided in 2017 to develop a pan-European guideline for the management of diverticular disease, acknowledging that it will be a compromise of different national guidelines and different accessibilities to healthcare and medical procedures in different healthcare systems.

Method

Two project leads (JKS and EA) were appointed by the guideline committee at the annual ESCP meeting in 2017. Together with a representative from the ESCP guidelines committee (WB), they assembled a team of ESCP and United European Gastroenterology members divided into six work groups (WGs). All WGs comprised a group leader, up to three researchers and a surgical resident who were invited personally to participate by the project leaders. Senior group members were specialists in colorectal surgery, gastroenterology or radiology and were considered based on their scientific contribution in the field. Consideration was taken to ascertain that there was a balanced contribution of the different nationalities within each WG. The groups covered six topics: WG I, Aetiology, follow-up including risk for cancer; WG II, Imaging, indication and classifications, initial evaluation of diverticulitis and imaging; WG III, Nonsurgical management of diverticulitis and dietary recommendations; WG IV, Emergency surgery for acute diverticulitis; WG V, Elective surgery for diverticulitis; WG VI, Technical considerations, special considerations. For all six WGs, research questions were formulated and subsequently revised until all members of the WGs agreed. Each WG conducted their literature research and drafted statements and supporting documentation to their research questions.

Search methods and manuscript selection

Based on the research questions a literature search was performed by the individual WGs. The literature searches were performed using MEDLINE/PubMed/ISI/Scopus and the Cochrane database between July and September of 2018.

Study inclusion criteria were systematic reviews, randomized clinical trials, cohort studies and case series on the subject of colonic diverticulosis and diverticulitis. The trainee or PhD candidate in each research group

performed an evaluation of the quality of evidence and created evidence tables with structured summaries for each relevant included article (supplements 1–6). The level of evidence for each recommendation was graded according to the levels of evidence published by the Oxford Centre for Evidence-Based Medicine 2011 [8].

The drafting of supporting text and statements

All statements and the initial supporting text were presented at a face to face meeting of the entire team at the ESCP annual meeting in Nice in September 2018. The content and the strength of each statement and recommendation were reviewed. All statements were then revised to meet the changes requested. A first voting round with all WG members was conducted online in February 2019. After the voting, all statements and the supporting text were revised by the WGs taking into account both the strength of the supporting evidence and the expert comments from the voting round. The results of this revision were then arranged into one document by the first and last authors. During the summer of 2019, all WG members and all country representatives of the ESCP were invited to participate in a second online voting round on all the statements. Based on these surveys, all statements that reached an agreement of more than 90% were considered to be in agreement unless there were important reasoned objections by single voters. All other statements were revised and discussed at a meeting during the ESCP annual meeting in Vienna in September 2019. Following this meeting, all statements and the supporting text were edited by the first and last authors before the paper was sent for final revision and approval by all the authors combined with a third voting on revised statements.

WG I: Aetiology, follow-up including risk for cancer – statement of the problem and epidemiology

1.1 How is diverticular disease defined and how should it be classified?

The evolution of new diagnostic pathways and novel treatments has led to a diversity of terms such as asymptomatic and symptomatic diverticulosis, diverticular disease, acute and chronic diverticulitis and some other subgroup definitions. Unfortunately, this variety causes confusion. To establish clear definitions is important in the area of diverticula-related clinical and scientific communication.

Numerous classifications and modifications describe the various stages of diverticular disease [7,9]. The first

widely used classification by Hinchey [10] was intended as an intra-operative stratification of perforated diverticulitis with abscess or peritonitis enabling surgeons to adjust the surgical approach. It was later modified to pre-operative use, incorporating CT findings [11]. The German guidelines suggest a new classification that is currently under validation. It was developed on the basis of Hinchey/Wasvary and Hansen and Stock, and adapted to current diagnostic and therapeutic aspects [5,12].

The ESCP guideline committee has decided neither to create yet another classification nor to quote one of the existing ones. All the existing classifications lack reliable validation and none of them is generally accepted. The guideline committee has therefore used definitions based on evidence as far as possible with some overlap with existing classifications. Figure 1 displays terms used in this guideline project.

Diverticulosis vs diverticular disease

Diverticulosis of the colon (existence of false diverticula – outpouchings of mucosa and serosa through openings in the muscular layer of the bowel) develops in the majority of individuals in western countries with increasing age and usually remains asymptomatic [13,14]. Diverticulosis *per se* should not therefore be considered a disease. The term diverticular disease implies that there are symptoms related to the diverticula.

Symptomatic uncomplicated diverticular disease (SUDD)

Whether diverticula can lead to symptoms in the absence of inflammation or bleeding is controversial [15–17]. The term symptomatic uncomplicated diverticular disease (SUDD) is used in some countries for patients with diverticula who experience abdominal symptoms (e.g. abdominal pain and bloating) and changes in bowel habit (e.g. diarrhoea, constipation or

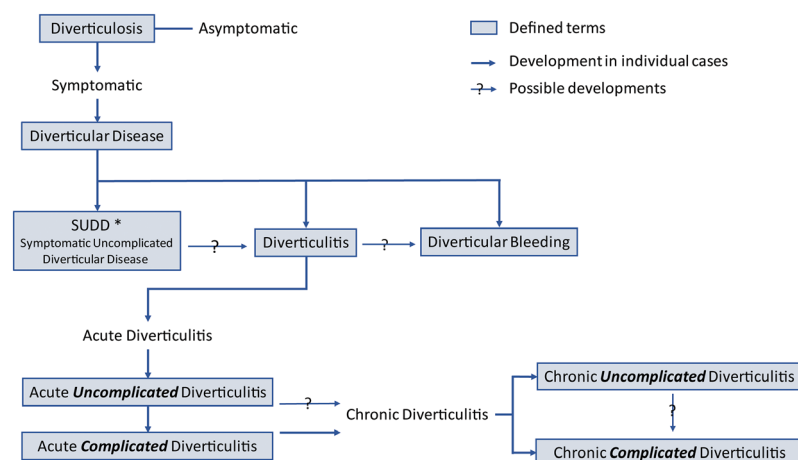
alternating bowel habit) in the absence of inflammation [3,18]. However, the term has not found general acceptance and a uniform definition does not exist [15]. A major difficulty is the differential diagnosis between irritable bowel syndrome (IBS) and SUDD as there is an overlap between the two [18]. Epidemiological studies have shown that IBS-like symptoms may develop after a bout of acute diverticulitis [19]. A comparative study between SUDD and IBS found significantly different pain characteristics [20] with abdominal pain lasting > 24 h occurring more frequently in SUDD, but a recent large cohort study including individuals in a colonoscopy screening programme found no association between diverticulosis and abdominal pain [15]. Currently, there is little evidence on how to manage SUDD.

Diverticulitis. The term diverticulitis describes a peridiverticular inflammation of the bowel wall and usually the surrounding tissue. The theory that the inflammation is a result of translocation of intestinal bacteria through the mucosa of the diverticulum on the basis of a weak barrier has lately been challenged [21] and the true aetiology is unclear.

Diverticulitis can be acute or chronic and complicated or uncomplicated with possible complications including abscess, perforation, fistulas, obstruction and bleeding [3]. The severity of acute diverticulitis, mainly determined by cross-sectional imaging (CT scan, ultrasound) and laboratory tests (C-reactive protein), is decisive and guides management and treatment. In general, uncomplicated acute diverticulitis is differentiated from complicated acute diverticulitis. The cut-off is poorly defined but depends on the degree of inflammation.

Acute uncomplicated diverticulitis. Acute uncomplicated diverticulitis is inflammation in a diverticula-bearing

Figure 1 List of terms and stages used in the guideline. The flowchart shows the different stages of diverticulosis and diverticular disease. Note that although diverticulosis is a *conditio sine qua non* for the other stages, the different stages are not part of a continuous development and may appear independently in individual cases. *The term SUDD is controversial, as it remains unclear whether this is a disease of its own or whether it represents the coexistence of irritable bowel syndrome and diverticulosis.



bowel segment and the surrounding tissue without signs of perforation (extraluminal air) or abscess formation.

Acute complicated diverticulitis. Typical complications of acute diverticulitis occur if the inflammatory process extends beyond the colonic wall. However, peridiverticulitis alone is not considered complicated disease. A covered perforation with air bubbles in proximity to the bowel, intra-abdominal abscess adjacent to the inflamed segment (Hinchey Ib, according to Wasvary) or distant (Hinchey II) and free perforations with purulent or faecal peritonitis (Hinchey III and IV) represent the major manifestations of acute complicated diverticulitis [11].

Chronic diverticulitis. If an acute diverticulitis does not resolve completely, chronic diverticulitis can develop. Wall thickening or chronic mucosal inflammation in the absence of stenosis is called chronic uncomplicated diverticulitis. Complicated chronic diverticulitis includes both stenotic disease, which may lead to acute bowel obstruction, and fistulation most commonly to the urinary tract.

Diverticular bleeding. Diverticular bleeding is reported to account for about 35% of painless lower gastrointestinal bleeding and occurs in up to 50% of elderly patients with diverticulosis [5]. The exact incidence is difficult to estimate, however. Frequently, the bleeding site cannot be identified, and coexisting diverticula may then falsely be reported as the bleeding cause.

Diverticular bleeding is arterial and occurs from rupture of the intramural branches of the marginal artery at the dome or neck of the diverticulum. Trauma from mechanical or chemical causes within the lumen of the diverticulum leads to injury to the penetrating vessels and bleeding. Histopathological examination of diverticular bleeding sites has shown absence of diverticulitis [22], but bleeding may occur during inflammation as well. If surgery is required, precise localization of the bleeding site is crucial for any surgical procedure. Colonic resections in patients with diverticular bleeding and an unclear localization have shown a postoperative mortality of 43% in comparison to 7% in patients with defined bleeding localization [23]. There are separate guidelines for the management of lower gastrointestinal bleeding which is therefore not part of this guideline.

The following statements are definitions by agreement of the guideline group.

Statements

1.1.1 Diverticulosis means an asymptomatic presence of diverticula and is *per se* not a disease.

Agreement 97% (second voting)

1.1.2 Diverticular disease is defined as diverticulosis with related symptoms or complications.

Agreement 100% (consensus meeting)

1.1.3 Clinical and scientific communication on diverticular disease must use accepted definitions.

Agreement 100% (second voting)

1.1.4 It is unclear whether SUDD – as defined by abdominal symptoms without proven inflammation or bleeding – can be considered a disease of its own or whether it represents the coexistence of IBS and diverticulosis.

Evidence level 4. Agreement 100% (consensus meeting)

1.1.5 Diverticulitis should be associated with symptoms and signs of peridiverticular inflammation proven by cross-sectional imaging and laboratory tests. Diagnosis should differentiate between uncomplicated and complicated as well as acute and chronic diverticulitis.

Evidence level 4. Agreement 97% (second voting)

1.1.6 Diverticular bleeding, very probably caused by a mechanical disruption of a vessel, occurs mostly painlessly without preceding diverticulitis. Patients with possible diverticular bleeding often need hospitalization with multidisciplinary treatment options and an urgent or semi-urgent endoscopic evaluation.

Evidence level 4. Agreement 93% (second voting)

1.2 What is the prevalence of diverticulosis?

By far the majority of individuals with diverticulosis remain asymptomatic throughout life [12]. Therefore, the incidence of diverticulosis is difficult to estimate. Most data come from autopsy studies. A prospective study from Taiwan in asymptomatic subjects undergoing colonoscopy for a health screening revealed a frequency of colonic diverticulosis of 256 out of 1899 asymptomatic subjects (13.5%) ranging from 4.9% in young adults (< 39 years) to 74.4% in the group > 70 years of age. There was a clear preponderance of men [24]. In western countries with a predominant Caucasian population, the prevalence is higher [14,15]. Estimated rates of diverticulitis in patients with known diverticulosis are as low as 1%–4% or 1.5–6.0 per 1000 patient-years [25].

Diverticulosis and associated clinical problems are most likely to occur in older age groups. However, although diverticula still are most frequent in elderly individuals, evidence is emerging that the condition has increased particularly in younger subjects under 45 years of age [26].

1.3 What is the incidence of uncomplicated and complicated diverticulitis and what are the annual healthcare costs for diverticulitis in Europe?

Although there is quite a variability of frequency rates for diverticulitis in the literature, there is some evidence that the incidence of diverticulitis has risen over the last years particularly in younger adults and women. There are almost no population-based data. Nearly all studies refer to the number of hospital admissions (Data S1, 1.3a). A recent Italian study found an overall rate of 48 hospital admissions for acute diverticular disease per 100 000 inhabitants in 2015, and a yearly increase of over 3% from 2008. Interestingly, the age-specific rate was constant for older ages and there was only a slight increase for the younger age groups; thus some of the increase of the overall rate might be attributed to the aging population. The overall rate of hospital admissions for acute diverticular disease per 100 000 hospitalizations was 248 with an annual increase of 7.5% from 190 in 2008 to 310 in 2015 [27]. From the USA, a prevalence of 92/100 000 persons with a preponderance of women has been reported [28].

In the Netherlands, approximately 22 000 patients per year are referred to secondary care with diverticulitis. Ten per cent of these patients will develop complications such as abscess or perforation and will require further treatment in the form of close observation, antibiotics, percutaneous drainage or surgery [29]. Due to uncertainties about the incidence, it is difficult to estimate the health economic burden of diverticulitis and there are no reliable calculations (Data S1; 1.3b).

1.4 What are the risk factors for diverticulosis, diverticulitis and its complications?

The formation of diverticula and the pathogenesis of diverticular disease is multifactorial and as yet not completely understood (Data S1; 1.4). Traditionally, the factors are thought to include older age, environment (diet, physical activity) and intestinal motility. Obesity is a major risk factor with a linear relationship and a relative risk for each 5-unit body mass index increase of 1.28 (95% CI 1.18–1.40) for diverticular disease, 1.31 (95% CI 1.09–1.56) for diverticulitis and 1.20 (95% CI 1.04–1.40) for complicated diverticular disease (defined as bleeding, abscess or perforation) [30]. Recent research has identified other factors, such as genetic patterns, altered tissue composition and malfunction as associated with neuro-gastrointestinal disturbances [21]. Colonic diverticula may occur in all segments of the colon but mostly in the sigmoid colon, with the second most common site in the right colon [31].

For practical reasons, risk factors for the development, appearance and outcome of acute diverticulitis are split into noncontrollable factors (age, sex and genetics) and factors that can be influenced.

Twin studies have demonstrated that a genetic component is present in the development of diverticulosis [32,33]. Few genetic studies have identified the actual genes that are susceptible culprits. Genetic connective tissue disorders like Ehlers–Danlos and Marfans syndrome have been linked to the development of diverticulosis in young age [34,35]. Some studies indicated that genes involved in immunity, extracellular matrix, cell adhesion, membrane transport and intestinal motility may be related to diverticular disease [36–38]. However, the exact mechanisms remain to be shown.

Food and lifestyle are among the commonly discussed controllable risk factors, particularly dietary fibre. Epidemiological studies indicate that dietary fibre has a protective effect against development of diverticulosis and diverticulitis [39,40]. In addition, nuts, grains, corn and popcorn have been shown in big cohort studies to be protective against the development of diverticulitis [41]. Red meat and smoking are possible risk factors [21].

Obesity is a risk factor for developing diverticulosis, diverticulitis and diverticular bleeding while physical activity is protective [42–45].

Commonly used drugs, such as nonsteroidal anti-inflammatory drugs, aspirin, acetaminophen, corticosteroids and opioids increase the risk of diverticular disease, particularly complicated diverticulitis [46].

In Denmark, 12%–17% of all hospitalizations for diverticulitis are for complicated diverticulitis with a marked increase of 43% in absolute numbers between 2000 and 2012 [47]. Similar trends have been reported from Scotland [48].

Acute complicated diverticulitis comes with considerable mortality. In the largest series of Hinchey Ib–II diverticulitis ($n = 3148$, nationwide Danish registry), 8.7% of patients died within 30 days from admission, and 2.5% of those discharged alive died within 30 days from discharge; age and use of glucocorticoids were the main independent risk factors for death in multivariate analysis [49]. Following an episode of acute diverticulitis with abscess formation, there is a marked risk for recurrence. The nationwide Danish registry data show recurrence rates of 9%–24%. Most recurrences and recurrence-related mortality occurred within the first year [50].

Mortality risk increases even more in the case of free perforations with peritonitis. A Dutch series from 1990 to 2005 found it to be as high as 26.5% during initial hospital stay with an overall 5-year survival of just 53%, mainly caused by the poor general health of the patients [51].

Both the risk of a subsequent free perforation and the risk of death decrease with the number of previous episodes [49,52]. The first episode of complicated diverticulitis is by far the most dangerous.

Statements

1.4.1 The development of diverticulosis is multifactorial and risk factors include age, genetic predisposition and obesity. The pathogenesis from diverticulosis to diverticulitis and its complications can be influenced by lifestyle and medications.

Evidence level 2. Agreement 100% (consensus meeting)

1.4.2 Acute complicated diverticulitis is associated with considerable short-term and long-term mortality. The risk of severe complications is highest at the first episode of diverticulitis and decreases with the number of recurrences.

Evidence level 2. Agreement 100% (second voting)

1.5 How should patients be followed-up after an episode of uncomplicated and complicated diverticulitis?

Due to the generally benign course of diverticulitis a routine follow-up of the disease itself seems only justified in unresolved complicated cases. However, although the widespread use of abdominal CT in the acute setting has made the diagnostics more accurate, the differentiation between diverticulitis and colorectal cancer (CRC) is still difficult in some cases. Most previous guidelines recommended routine colonoscopy some weeks after an episode of acute diverticulitis [6]. The rationale was that early detection of CRC in misdiagnosed patients could reduce the chance of dissemination. No randomized trials to investigate the usefulness of this practice (by comparing cancer-specific survival with and without endoscopy) exist. Many primarily retrospective studies have investigated detection rates for CRC with colonoscopy after acute diverticulitis (Data S1, 1.5). However, meta-analyses of data have been troubled by the heterogeneity of the studies, the lack of a valid reference population, inconsistent reporting of CT verification of the diverticulitis episode, inconsistent definitions of uncomplicated and complicated diverticulitis and the lack of information about ongoing symptoms in the included patients [53–57].

Routine colonoscopy after an episode of conservatively treated complicated diverticulitis is generally accepted, as the prevalence of CRC is between 7.9% and 10.8% in this group [53,55,56].

For patients with CT verified uncomplicated diverticulitis, the two most recent meta-analyses have calculated a prevalence of CRC of 0.5% and 1.2% respectively due

to the inclusion of different studies [55,56]. Furthermore, in the meta-analyses different reference populations are used leading to different conclusions. Meyer *et al.* calculated the prevalence of CRC after uncomplicated diverticulitis to be higher than that in the rest of the population whereas Rottier *et al.* found these prevalences to be similar. It should be noted that the prevalence of undiagnosed CRC in the asymptomatic background population can only be estimated. Detection rates of CRC in screening programmes vary between 0.1% [58] and 1% [59] (mostly around 0.5% [60]), depending on the age and risk profile of the included population. Screening probably overestimates the prevalence of CRC in asymptomatic patients, as participation rates are usually far below 50% and symptomatic and high-risk patients probably are more likely to attend. Also, incidence rates for CRC have been used to estimate the prevalence of undiagnosed CRC in the population [55,61], which has the weakness that it is uncertain how long the CRC existed before diagnosis.

After a CT verified uncomplicated diverticulitis, colonoscopy is usually part of the normal work-up of symptomatic patients (bleeding, changed bowel habits or ongoing pain). Controversy exists whether asymptomatic patients need endoscopic follow-up.

Statement

1.5.1 Endoscopic follow-up: for patients with symptom-free recovery after a single episode of CT verified uncomplicated diverticulitis endoscopic follow-up remains controversial and may not be necessary. All other patients treated without resection for acute diverticulitis should be followed up with an examination of the colon at least 6 weeks after the acute episode, if not done within the last 3 years.

Evidence level 3. Agreement 100% (third voting)

WG II: Imaging, indication and classifications – initial evaluation of diverticulitis and imaging

2.1 How can clinical findings be correlated to the severity of the disease?

Before the introduction of current imaging modalities, acute diverticulitis was a diagnostic challenge [62]. A diagnosis of acute diverticulitis based solely on clinical findings is incorrect in more than 50% of cases [63]. Together with other clinical findings, laboratory tests may be helpful to guide the clinician in the diagnosis [64]. Several studies indicate that C-reactive protein levels are correlated to the severity of disease and

recurrence rates; however, certain discrimination between the stages of the disease is not possible [65–68]. Existing studies investigating the correlation between clinical findings and staging at imaging are very heterogeneous and generally not of high quality [29]. Clinical findings may lead the clinician, however, when deciding the urgency of imaging and intervention.

Statement

2.1.1 There is a poor correlation between clinical findings and severity of the disease.

Evidence level 2. Consensus 100% (consensus meeting)

2.2 When should imaging be obtained on index and successive presentations of disease? (Which cases can be treated in primary care without imaging?)

Due to the low diagnostic accuracy of a clinical evaluation, imaging is generally required to confirm the clinical suspicion of acute diverticulitis in primary and secondary care, especially in patients with no previous diagnosis of diverticulitis [64,69,70]. Even successive presentation of diverticulitis may require imaging to confirm the diagnosis. However, as the course of acute uncomplicated diverticulitis even with small abscesses is benign [71], and severe complications are rare with low C-reactive protein levels, an observational strategy without imaging may be adequate in mild cases, especially in frequent recurrent disease [69]. If no imaging is obtained, elective endoscopic examination, if not recently done, may be helpful for differential diagnosis.

Statement

2.2.1 Imaging is required to confirm the diagnosis of acute diverticulitis if there is no prior diagnostic information.

Evidence level 2, Strong recommendation. Consensus 100% (consensus meeting)

2.3 What is the most appropriate imaging tool to diagnose acute diverticulitis?

CT, ultrasound and MRI are possible imaging modalities that have been studied as tools to identify and classify diverticulitis. CT has a high sensitivity and specificity in the diagnosis of acute diverticulitis [72]. Although abdominal ultrasound in expert hands has a high diagnostic accuracy, it has not gained widespread popularity [73]. Ultrasound has the advantages of avoiding ionizing radiation and easy repetition if needed

and it can be useful in pregnancy [72,74]. However, it is less accurate for abscess identification and exclusion of other gastrointestinal issues. A modified Hinchey classification cannot be assessed by ultrasound evaluation [75,76]. MRI is highly sensitive and specific in the differential diagnostics of diverticulitis [77]. However, as it is time consuming and less available than CT it has not found wide acceptance. MRI is an alternative when ultrasound is inconclusive in pregnant women as well as after the acute phase to assist in differential diagnoses.

Statement

2.3.1 CT is recommended as the first-line investigation in suspected diverticulitis. Ultrasound and MRI are alternatives.

Evidence level 2, Strong recommendation. Consensus 100% (consensus meeting)

2.4 Which CT classification is appropriate?

There are many classifications in the literature but most of the published papers use either the Hinchey classification or a modified version of it. However, the Hinchey classification was originally a classification of intra-operative findings in patients with perforated diverticulitis and included only patients with abscesses or free perforations. One should be aware that the most frequently used modification by Wasvary also includes mild phlegmonous disease in the absence of complications [11,78–83]. It is useful for classifying both acute uncomplicated and complicated diverticulitis although there is little validation.

Statement

2.4.1 No CT classification is superior to others as a diagnostic tool for acute diverticulitis. Each centre should choose their preferred classification in communication with available radiologists.

Evidence level 5, Conditional recommendation. Consensus 100% (third voting)

WG III: Nonsurgical management of diverticulitis and dietary recommendations

3.1 Should uncomplicated diverticulitis be treated with antibiotics?

Two randomized clinical trials (AVOD [84,85] and DIABOLO [71,86]) were performed comparing

antibiotic and nonantibiotic treatment in immunocompetent and nonseptic patients with uncomplicated acute diverticulitis. No differences in time to recovery from the initial episode or in hospital stay were seen in the two trials (Data S3; 3.1). Furthermore, no differences were observed in the two trials regarding rates of complicated diverticulitis and the need for sigmoid resection after the initial diverticulitis episode and on long term (up to 11 years), in rates of recurrent diverticulitis, and in the need for sigmoid resection during the initial diverticulitis episode. Slightly but nonsignificantly more (elective) sigmoid resections were performed in the nonantibiotic group at 24 months (DIABOLO trial). This may have been caused by a lower threshold for surgery in the nonantibiotic group as they may have felt undertreated for their initial episode. Antibiotic-related morbidity occurred in 8.3% of patients in the antibiotic group from the DIABOLO trial. Two recent meta-analyses of the two randomized trials concluded that patients can be treated safely without antibiotics [87,88]. Cross-sectional imaging to confirm the diagnosis of uncomplicated diverticulitis was performed in both randomized trials and is encouraged in this guideline (Statement 2.2.1). However, if imaging in mild cases is not obtained, an observational strategy without antibiotic treatment seems justified as there is no evidence whatsoever for a positive effect of antibiotics in this situation.

Statement

3.1.1 Patients with acute uncomplicated diverticulitis do not require antibiotics routinely. Antibiotic treatment should be reserved for immunocompromised patients and patients with sepsis.

Evidence level 1, Strong recommendation. Consensus 100%, consensus meeting

3.2 What is the role of antibiotics in complicated diverticulitis?

Little evidence exists about antibiotic treatment in patients with complicated diverticulitis. Many patients with complicated diverticulitis are critically ill and it seems unethical to investigate the role of antibiotics in these patients. Patients who might be eligible for nonantibiotic treatment are those with small abscesses or small air bubbles around the sigmoid. In the above-mentioned AVOD study [84], patients with radiological signs of complications were excluded. The Dutch DIABOLO trial did include patients with small abscesses on CT [71]. However, the number of patients in this category was very small and no final conclusions can be drawn. There are several cohort studies investigating

patients with pericolic air, showing that they have the same prognosis as patients with uncomplicated diverticulitis [89–91]. However, in nearly all of these studies patients were treated with antibiotics [92].

Statement

3.2.1 Patients with radiological signs of complicated diverticulitis should normally be treated with antibiotics.

Evidence level 3, Conditional recommendation. Consensus 100%, consensus meeting

3.3 Which group of diverticulitis patients can safely be treated as outpatients?

Two recent systematic reviews [93,94] have studied the evidence. One included 21 and the other 19 studies including one randomized trial [95] comparing inpatient and outpatient treatment for patients with uncomplicated diverticulitis, and comparable rates of readmission were found. The 19 studies combined showed a pooled readmission rate of 7%, very low rates of surgical or percutaneous interventions (0.2%) and potential healthcare cost savings up to 82% (Data S3; 3.3). Most studies only selected patients as outpatient treatment candidates based on patient characteristics (such as absence of comorbidities or immunosuppressed state), clinical condition (such as having uncomplicated diverticulitis and ability to tolerate oral intake) and patients' social environment (adequate family and social network). The second review published in 2019 included 21 studies and found a failure rate of 4.3% but highlighted that there were no criteria of failure, which makes patient selection difficult.

Statement

3.2.2 For patients with an adequate social network tolerating oral intake, outpatient treatment of uncomplicated diverticulitis seems to be safe in the absence of sepsis, significant comorbidity and immunosuppression.

Evidence level 2, Conditional recommendation. Consensus 97%, consensus meeting

3.4 Which supportive measures should be recommended in the acute stage of diverticulitis?

Although dietary restrictions and bed rest have been suggested as part of the treatment of acute diverticulitis,

no benefit has ever been proven in studies. Many surgeons have traditionally recommended a low residue diet, but there is little evidence to support this practice. Two observational studies showed that an unrestricted diet is not associated with an increase in the rate of diverticular complications. A retrospective study showed no increase in complications in a group of patients with a solid food diet compared to several types of dietary restrictions [96]. A prospective single-arm study with an unrestricted diet found an 8.1% complication rate after 6 months, which is comparable to rates in the literature on uncomplicated diverticulitis [97]. Additionally, a randomized trial found no increased pain scores, no increased length of hospital stay and no treatment failures in patients with an unrestricted oral regimen compared to an intravenous regimen including a minimum 24 h of fasting [98]. Notably, this trial primarily compared oral and intravenous antibiotics which may have affected its results. Bed rest has not been studied at all. In addition, all patients with acute uncomplicated diverticulitis included in studies regarding outpatient management with or without antibiotics have had oral antibiotics with comparable outcomes as in the literature (Data S3; 3.4).

Statements

3.4.1 There is no evidence to support dietary restrictions. An unrestricted diet (when tolerated) is preferable.

Evidence level 3, Conditional recommendation. Consensus 93% (second voting)

3.4.2. Any evidence regarding bed rest is lacking and, since imposed physical inactivity may impair the patients' general condition, bed rest is not recommended.

Evidence level 4, Conditional recommendation. Consensus 100% (second voting)

3.5 Are medical agents (mesalazine, rifaximin, probiotics) useful to prevent recurrences or persistent symptoms after an episode of acute diverticulitis?

Several medical agents have been studied for their ability to prevent recurrent diverticulitis or persistent symptoms after an episode of acute diverticulitis: mesalazine (anti-inflammatory agent), rifaximin (nonsystemic, broad-spectrum nonabsorbable antibiotic) and probiotics (Data S3; 3.5). Mesalazine has been studied most thoroughly. A recent systematic review including seven randomized trials showed a pooled risk ratio for recurrent diverticulitis of 0.90 (95% CI 0.61–1.33) for mesalazine treatment compared to no treatment or placebo

[99]. Mesalazine may reduce global symptom scores. This has only been investigated by two trials including few patients (77 mesalazine and 76 control patients) [100,101]. The effect of 7–10 days per month rifaximin was assessed in one proof-of-concept randomized clinical trial [102] (rifaximin *vs* placebo) and two observational studies [103,104] (rifaximin *vs* mesalazine). The randomized clinical trial found no difference in recurrent diverticulitis rates at 48 weeks in the intention-to-treat analysis, although some benefit of rifaximin was seen in additional analyses that were adjusted for several confounders. However, the number needed to treat is high and it is hence not clinically useful. The two observational studies comparing rifaximin and mesalazine found opposite results – one was in favour of rifaximin and the other in favour of mesalazine. Probiotics have been the topic of two randomized trials demonstrating conflicting results. One trial compared a combination of probiotics and mesalazine with mesalazine monotherapy [101]. The probiotics/mesalazine group yielded the highest rate of recurrent diverticulitis and gastrointestinal complaints. The other trial found lower rates of recurrent diverticulitis in the probiotics group compared to the control (no treatment) group, but this trial included only 43 and 40 patients per group respectively and followed patients for only 3 months [105].

Statement

3.5.1. From the available medical agents, neither mesalazine, rifaximin nor probiotics can be recommended to prevent recurrent diverticulitis or persistent complaints after an episode of acute diverticulitis.

Evidence level 3, Conditional recommendation. Consensus 96% (second voting)

3.6 Should a high-fibre diet be recommended following an episode of acute diverticulitis?

A recent systematic review identified only two randomized studies assessing the effect of fibre modifications following an episode of acute diverticulitis [106]. Both studies were conducted over 30 years ago and included only 20 and 56 patients, respectively. A three-arm randomized cross-over intervention study showed a higher proportion of patients being symptom free after 1 month of fibre supplements compared to a high-fibre diet. A retrospective cohort study demonstrated a lower recurrence rate in patients adhering to a high-fibre diet compared to patients not adhering to this diet [107]. This is in line with large epidemiological cohort studies

concluding that a high-fibre diet is associated with a lower risk of diverticular disease [39,40,108]. Although this evidence suggests that a high-fibre diet may be beneficial in the prevention of diverticulitis and its recurrence or persistent symptoms, no final conclusions can be drawn due to the limitations of these studies.

Statement

3.6.1 Although a high-fibre diet may be recommendable for general health purposes, there is little evidence that it can prevent recurrent episodes or persistent symptoms in patients with acute diverticulitis.

Evidence level 3, Conditional recommendation. Consensus 93% (second voting)

3.7 What is the appropriate treatment strategy for patients with a diverticular abscess in the acute setting?

The management of acute diverticulitis with abscess formation consists of two different topics: how to manage these abscesses in the acute stage of disease and whether to perform an elective resection due to the complicated nature of this initial episode (see Statement 5.2.1). Diverticular abscesses can initially be treated with antibiotics and/or percutaneous drainage and/or surgery. A great number of studies have assessed the risk of treatment failure in one or more of these treatment strategies. However, no randomized data are available, and the observational studies suffer from high risk of selection bias (Data S3; 3.7). In almost all studies abscesses are larger and patients more severely ill in percutaneous drainage groups compared to the antibiotic groups, and in the surgical groups compared to nonsurgical groups, hampering the comparison of outcomes between these groups. A recent systematic review including 42 studies found comparable rates of treatment failure for antibiotics (19.9%), percutaneous abscess drainage (20.8%) and nonoperative management (20.6%) [109]. Mortality rates increased with increasing invasiveness of treatment: 0.6% for antibiotics, 1.1% for nonoperative, 1.6% for percutaneous drainage and 12.1% for surgery. A recent large multicentre observational study including 447 patients demonstrates a significantly higher rate of treatment failure in the percutaneous drainage group compared to antibiotic treatment group (36% *vs* 24%, $P = 0.013$) and more complications in a subgroup of patients with a large or distant abscess (Hinchey II) when undergoing percutaneous drainage compared to antibiotics (12% *vs* 4%, $P = 0.032$), although these

results were probably affected by selection bias as previously mentioned [110]. In an attempt to eliminate this selection bias as much as possible in observational data, a multivariate analysis has been performed showing that percutaneous drainage was not independently associated with treatment failure (OR 1.47, 95% CI 0.81–2.68). In addition to earlier studies indicating 3 cm as the best cut-off above which treatment failure is more likely, multivariate analysis in this study showed an abscess cut-off size of 3 cm as the best predictor for treatment failure and 5 cm for the need for emergency surgery. However, in subgroups of patients with abscesses larger than 3 and 5 cm, respectively, percutaneous drainage was not able to decrease the rates of treatment failure. In summary, the risk of adverse outcomes increases with abscess size, but the role of percutaneous drainage remains unclear.

Statement

3.7.1 Although the role of percutaneous drainage of abscesses in acute diverticulitis is not completely clear, it may be considered in patients with an abscess larger than 3 cm. Emergency surgery should be kept as last resort for patients failing other non-surgical treatments.

Evidence level 3, Conditional recommendation. Consensus 100% (consensus meeting)

WG IV: Emergency surgery for acute diverticulitis

4.1 What are the indications for abdominal exploration in patients with acute diverticulitis?

Clinical evaluation alone is very subjective and has not been assessed in many studies. Traditionally, clinical signs of sepsis in combination with generalized peritonitis were considered an indication for surgery. This practice is based on experience rather than evidence. Radiologically detected extraluminal air has usually been considered as a sign of perforation with indication for surgery. There is little evidence, however, whether pericolic or free air alone is an indication for exploration or not. If extraluminal air is used as a surrogate marker for abdominal exploration, there are five retrospective and three prospective cohort studies with a total of 1470 patients [89–91,111–115]. Most of the studies are of poor quality with a low number of patients (Data S4; 4.1). Between 0% and 10% of all patients required a surgical procedure.

Free fluid has been suggested to be another surrogate marker, but it is frequently found in uncomplicated diverticulitis as well, rendering the use as a surrogate marker for complicated disease difficult [84].

Statement

4.1.1 It seems fairly safe to observe immunocompetent haemodynamically stable patients even if there are radiological signs of extraluminal air. Immediate surgery should be considered in haemodynamically unstable or septic patients.

Evidence level 3, Conditional recommendation. Consensus 100% (second voting)

4.2 Which surgical approach is appropriate in patients with faecal peritonitis (overt perforation)?

There are no randomized trials that involve nonsurgical or nonresectional treatment for faecal peritonitis [116–119]. Some patient series have investigated laparoscopic closure of a perforation combined with laparoscopic lavage but there is little evidence to support this practice [120]. There are some studies suggesting damage control with a second look within a couple of days [116,121]. Neither are established techniques. There are no randomized trials comparing the laparoscopic *vs* the open technique for faecal peritonitis and existing nonrandomized trials are heavily influenced by selection bias.

Statement

4.2.1 The surgical approach in patients with faecal peritonitis should be related to the experience of the surgeon; there is no evidence supporting laparoscopic or open surgery. Resection is the treatment of choice.

Evidence level 4, Strong recommendation. Consensus 97% (second voting)

4.3 Which surgical approach is appropriate in patients with purulent peritonitis?

There are three recently published randomized trials comparing laparoscopic lavage to open surgery with sigmoid resection with or without primary anastomosis (Data S4; 4.3). In the three studies, a total of 358 Hinchey III patients were included of whom 185 underwent laparoscopic lavage [122–124]. Several meta-analyses have been performed with somewhat different results [125–133]. There are several

noncomparative cohorts showing that laparoscopic lavage is feasible in selected patients [134].

Laparoscopic lavage reduces the risk for colostomy at 1- and 2-year follow-up but may in the short term result in intra-abdominal abscesses and overlooked free perforations or tumour perforations requiring reintervention (drainage or reoperation) [135,136]. Laparoscopic lavage is cheaper than resection and colostomy (Hartmann's procedure) [137–139].

Statement

4.3.1 Laparoscopic lavage is feasible in selected patients with Hinchey III peritonitis. Alternatively, resection is recommended.

Evidence level 2, Conditional recommendation. Consensus 93% (second voting)

4.4 What is the role of restoration of intestinal continuity with or without proximal faecal diversion in the management of acute diverticulitis?

Several studies have addressed the intestinal continuity during surgical treatment for acute diverticulitis. There are three cohort studies and four randomized trials [116–119,140–142]. The randomized clinical trials all include a diverting loop ileostomy in the primary anastomosis arm. None of the randomized clinical trials found a difference in morbidity or mortality between primary anastomosis and sigmoid resection with colostomy. Primary anastomosis will result in a lower stoma rate but may also increase the risk for complications. Many studies have used a diverting loop ileostomy. The DIVA arm of the LADIES trial has indicated that primary anastomosis is a safe option for Hinchey III and Hinchey IV patients compared to resection and a stoma [142]. The larger cohort studies included both Hinchey III and Hinchey IV and one of the cohort studies included 67 721 patients [141]. This study found a higher risk for complications in patients with anastomosis and diversion compared to colostomy.

Statement

4.4.1 Primary anastomosis with or without diverting ileostomy can be performed in haemodynamically stable and immunocompetent patients with Hinchey III or IV diverticulitis.

Evidence level 2, Conditional recommendation. Consensus 97% (second voting)

WG V: Elective surgery for diverticulitis

5.1 When should elective sigmoid colectomy be considered after recovery from uncomplicated acute diverticulitis?

Previously elective colon resection after the second episode of uncomplicated diverticulitis in order to prevent severe attacks was widely recommended [79,143,144]. While sigmoid resection is effective to reduce the risk of recurrent attacks of diverticulitis, several cohort studies have shown that complications are most likely to occur at the first episode and prophylactic surgery to prevent complications is not indicated [52,145]. The only justifiable reason to operate on patients with recurrent disease or with ongoing symptoms after uncomplicated diverticulitis is to improve their quality of life (QoL). There are numerous retrospective cohort studies on elective surgery [146–151], some of them addressing QoL [150,151] (Data S5, 5.1). These studies are very heterogeneous and of low quality, with a high probability of selection bias and inconsistent findings [152].

Recently the short- and long-term results of the DIRECT trial have been published. This is the only randomized trial comparing elective surgery *vs* conservative management of patients with frequently recurrent diverticulitis or ongoing symptoms after an episode of diverticulitis [153,154]. The QoL after 6 month and after 5 years was significantly better for patients in the surgical group. However, the trial had several limitations. It was prematurely aborted, had a relatively small sample size and the observed difference in QoL between the groups was quite small. Furthermore, the inclusion criteria were very strict, only patients with frequent recurrences (more than two within 2 years) or patients with ongoing symptoms and radiologically or endoscopically proven ongoing inflammation were eligible. The complication rate in the operative group was high (15% anastomotic leakages).

Statements

5.1.1 Elective surgery to prevent complicated disease is not justified, irrespective of the number of previous attacks.

Evidence level 2, Strong recommendation, Consensus: 97% (second voting)

5.1.2 There is no evidence to support resection in symptomatic patients without radiological or endoscopic signs of ongoing inflammation, stenosis or fistula.

Evidence level 3, Strong recommendation. Consensus 97% (second voting)

5.1.3 The goal of elective surgery after one or more episodes of diverticulitis is to improve QoL. The indication should be individualized and based on the frequency of recurrences, duration and severity of symptoms after the attacks and the comorbidity of the patient.

Evidence level 3, Strong recommendation. Consensus 97% (second voting)

5.2 Should elective colectomy typically be offered/considered after recovery from a conservatively managed episode of acute complicated diverticulitis?

Traditionally most patients with acute complicated diverticulitis were treated with emergency surgery, which before the era of cross-sectional imaging was the only way to diagnose complicated disease with certainty [10]. The introduction of CT and transcutaneous treatment of abscesses has revolutionized the treatment of abscesses and acute surgery is rarely required in these patients. It is quite likely that the frequent use of CT has also led to a stage migration, as the detection of small amounts of extraluminal air and small abscesses is much easier with up to date multidetector CT scanning. Many patients with covered perforations or even with distant free air are now initially treated conservatively with antibiotics alone. Several previous guidelines recommend elective resection after a complicated attack but there is little evidence to support this practice. Some retrospective cohort studies have reported higher recurrence rates after acute complicated diverticulitis (up to > 60%) compared to acute uncomplicated diverticulitis (15%–23%) whereas others report similar recurrence rates in both groups [84,86,155–157]. A systematic review shows a recurrence rate of 25.5% in 7653 patients with diverticular abscesses [109]. Other studies that are published later show mostly comparable rates of 25%–30% but ranging from 9% to 61% [50,110,158–162]. Several studies included in the systematic review do not show an increased risk for complications in recurrent episodes; others [160] report a 63% complicated recurrence rate and the previously discussed large observational study [110] shows 43% of recurrences being complicated. It should be noted that a substantial number of patients can be treated nonoperatively again and the risk of recurrence requiring acute operation following conservative management of acute complicated diverticulitis is relatively low [159,160]. There is only one small trial which randomized patients with extraluminal air and/

or abscesses to either elective surgery ($n = 26$) or observation ($n = 81$). The majority of patients in the observation group did not require elective surgery. However, QoL was not evaluated in this trial [163] (Data S5, 5.2).

Statement

5.2.1 The decision to operate on patients after a conservatively managed episode of acute complicated diverticulitis should follow the same principles as for patients with uncomplicated diverticulitis, resection is not recommended routinely.

Evidence level 3, Conditional recommendation. Consensus 100% (second voting)

5.3 How should surgery of persisting abscesses and fistulas be performed and is there a role for nonsurgical treatment?

There are few high-quality studies investigating the management of persistent abscesses and fistulas due to diverticulitis. Some descriptive case series, focusing either on the open or the laparoscopic approach, supported resection with primary anastomosis when possible and contextual bladder resection if needed [164–172]. Only one small retrospective cohort study investigated laparoscopic *vs* open surgery, demonstrating similar results [173]. Although limited by the poor quality of included studies, two meta-analyses by the same first author reported no clear advantage of the laparoscopic approach [174,175]. Furthermore, the authors highlighted that the laparoscopic approach may be challenging and consequently should be performed by experienced laparoscopic surgeons. There is only scarce evidence for the use of a robotic approach [176,177]. The conservative management of fistulas is documented only in two older retrospective studies [178,179]. Although limited by several sources of bias, the results of these studies were in favour of surgical management when the patient's general condition allows it, as the conservative treatment is related to a high mortality rate and poor QoL (Data S5, 5.3). There is no evidence concerning oncological *vs* nononcological resection.

Statement

5.3.1 Fistulas or persistent abscesses should normally be treated with laparoscopic or open resection of the diseased bowel with or without anastomosis.

Evidence level 3, Conditional recommendation. Consensus 100% (second voting)

5.4 Which surgical approach is most appropriate in elective surgery for diverticulitis (open/laparoscopic)?

Laparoscopic sigmoid resection for the treatment of diverticular disease is feasible in an elective setting [180–185]. Three randomized controlled trials comparing laparoscopic to open sigmoid resection have been published [186–188]. However, they were all underpowered, included different stages of the disease and reported inconsistent results. Only two of these conclude with better short-term outcomes with laparoscopic resection [187,188] and none of the three demonstrated convincing superiority of the laparoscopic over an open approach in long-term results. Three meta-analyses about the role of mini-invasive surgery for elective surgery for diverticulitis have been published [189–191], two of which included nonrandomized studies [189,190]. The Cochrane review by Abraha *et al.* [191] analysed only the three existing randomized clinical trials. They find it uncertain whether laparoscopic sigmoid resection has any substantial advantage over open sigmoid resection in diverticular disease (Data S5, 5.4). However, laparoscopic surgery has evolved since these trials were conducted and it is likely that laparoscopic resection has the same short-term advantages in diverticular disease as demonstrated for other diagnoses.

Statement

5.4.1 Elective colon resection for diverticulitis should preferably be performed laparoscopically when feasible.

Evidence level 3, Conditional recommendation. Consensus 100% (second voting)

5.5 Should immunocompromised and young patients be treated differently?

In immunosuppressed patients, complicated diverticulitis appears to be more aggressive, with more frequent free peritoneal perforation and worse outcomes [192,193]. The incidence of complicated diverticulitis in patients after organ transplant is approximately 1% higher than in immunocompetent patients [194]. Non-operative management of renal transplant patients with uncomplicated diverticulitis is safe, with outcomes similar to immunocompetent patients. However, the optimal management of renal transplant patients with complicated diverticulitis remains unclear as both treatment choices and complication rates differed from immunocompetent patients [195]. Comparison of

elective colectomy in transplant patients after one episode *vs* multiple attacks of diverticulitis showed no differences in complication rates and mortality. Colectomy after a single attack of diverticulitis in transplant patients is not justified as the operative risk is higher in these patients [196].

Among immunocompromised patients, chronic corticosteroid users have the highest risk of emergency surgery and of recurrence, especially in the first year after a diverticulitis attack. There should be a low threshold for abdominal CT in their follow-up, to search for persistent fluid collections or pericolic inflammation, in which case elective surgery may be indicated [197] (Data S5; 5.5a).

In young patients elective surgery after one episode of acute diverticulitis has been suggested due to the supposedly higher risk of recurrences and a more aggressive presentation [198]. In a systematic review including 4751 patients younger and 18 328 older than 50 years of age, patients younger than 50 years substantially differ from patients older than 50 years only in the risk for recurrent disease. Although the relative risk for requiring urgent surgery for recurrent disease may be higher in younger patients, the absolute risk difference was relatively small (7.3% *vs* 4.9%) [199]. Nevertheless, controversy persists about whether younger patients have more aggressive attacks, and the effect of the disease on their QoL. However, recommendation of more liberal resection in younger patients is not supported by the evidence [200] (Data S5; 5.5b).

Statement

5.5.1 The decision for elective resection after an acute episode of diverticulitis in immunocompromised and younger patients should follow the same principles as in other patients and is not recommended routinely.

Evidence level 3, Conditional recommendation. Consensus 100% (consensus meeting)

WG VI: Technical considerations – special considerations

6.1 What is the role of leak tests in surgery for diverticular disease?

The literature search did not show studies assessing intra-operative leak tests during surgery for diverticulitis (Data S6; 6.1). However, a systematic review and meta-analysis of 20 studies assessing intra-operative air leak test (ALT) during colorectal surgery concluded that evidence

suggests that ALT is necessary to identify patients with a higher risk of colorectal anastomotic leakage [201]. In addition, another systematic review assessed ALT and recommended intra-operative ALT, since it is relatively simple, inexpensive and allows for intra-operative revision of the anastomosis [202]. This is further supported by the results of the largest randomized trial so far, comparing ALT to no ALT in 145 colorectal surgery patients, that demonstrated that ALT significantly reduces the incidence of postoperative clinical and radiological leaks [203]. We suggest that, in the case of a doubtful air leak, the test should be repeated. Moreover, after a positive ALT, a test with methylene blue might be used to examine the extent and location of the leak.

Statement

6.1.1. An ALT of the colorectal anastomosis during surgery for sigmoid diverticulitis is recommended.

Evidence level 2, Conditional recommendation. Consensus 93% (second voting)

6.2 Which extent of resection is appropriate in an emergency setting?

Most literature regarding the extent of resection is based on retrospective data of elective surgery for diverticular disease [204–209]. A recent case-control study did not show histological inflammation or diverticula at the resection margins to be correlated with the occurrence of anastomotic stenosis [206]. Extending margins in the case of extensive diverticulosis seems unnecessary to prevent recurrent diverticulitis [209]. However, with regard to the construction of an anastomosis, it seems important to resect the grossly inflamed bowel segment both proximally and distally. Limited data are available on the proximal resection margin, whereas more data are available on the distal margin. Evidence from studies comparing colo-sigmoid and colorectal anastomoses suggests that the latter has a lower frequency of recurrent disease [204] (Data S6; 6.2).

Statements

6.2.1 In the emergency setting, the focus is to control sepsis and resect the perforated segment.

Evidence level 4, Conditional recommendation. Consensus 100% (consensus meeting)

6.2.2 In the case of resection and primary anastomosis, sigmoid resection down to the rectum with colorectal anastomosis should be done, with the proximal margin in as healthy colon as possible.

Evidence level 3, Strong recommendation. Consensus 100% (consensus meeting)

6.3 What is the preferred vascular approach in surgery for diverticular disease?

A meta-analysis, published in 2012, indicates no significant difference in anastomotic leak rate between preservation or ligation of the inferior mesenteric artery (IMA) [210]. Results from a randomized, controlled trial comparing IMA preservation and ligation in patients undergoing surgery for diverticulitis (note that Hinchey III/IV were not included) show an improvement in intestinal function through a reduction in neo-sigmoid denervation [211]. Results from a comparable randomized trial show clinical and radiological leakage rates to be lower in the IMA preservation group [212]. More recent evidence, from both retrospective and prospective cohort studies, was either in favour of IMA preservation or inconclusive on its effect compared to IMA ligation [213–217]. A recent review and meta-analysis failed to demonstrate a statistically significant difference in the anastomotic leakage rate comparing IMA preservation with IMA ligation [218]. The authors conclude that, to date, there is insufficient evidence to recommend the IMA-preserving technique as mandatory in resection for left-sided colonic diverticular disease and the decision remains at the discretion of the operating surgeon. High ligation seems warranted in cases with diagnostic uncertainty or when cancer cannot be excluded (inconclusive CT, MRI or endoscopy), whereas IMA preservation might be beneficial in cases where the diagnosis is clear (Data S6; 6.3).

Statement

6.3.1 In cases where there is no suspicion of cancer, IMA-preserving surgery can be performed to optimize preservation of the vascularization and the autonomic nerves.

Evidence level 2, Strong recommendation. Consensus 97% (second voting)

6.4 What is the role of ureteral stents in elective resection for diverticular disease?

No results from prospective, randomized trials were available [219–222]. Results from large population-based studies performed in the USA have shown that,

after adjustment for other patient and clinical factors, ureteral stenting in surgery for diverticular disease is significantly associated with a longer operative time, as well as a longer length of stay and higher costs [219,220,222]. Despite this, the benefits of ureteral stent use remain unclear, since the available literature indicates that selective stent use might have led to confounding by indication. Evidence identifying patient populations that most probably benefit from ureteral stenting is not available yet (Data S6; 6.4).

Statement

6.4.1 Ureteral stenting is not recommended as a routine, due to increased costs and operative time, but may be appropriate in selected cases with severe complicated disease.

Evidence level 3, Conditional recommendation. Consensus 100% (second voting)

6.5 Should the splenic flexure routinely be mobilized?

One retrospective study was identified that compared routine splenic flexure mobilization with no splenic flexure mobilization in elective surgery for diverticular disease [223]. Data were derived from a population-based cohort, with innate risk of selection bias, and showed splenic flexure mobilization to be safe and feasible (Data S6; 6.5). Despite a trend towards an increased minor morbidity rate (defined as superficial or deep surgical site infection, pneumonia, unplanned intubation, urinary tract infection or deep vein thrombosis) after splenic flexure mobilization, no difference was found in major adverse events. One other retrospective study showed from univariate analysis that splenic flexure mobilization did not seem to contribute to the complication rate [224]. From the literature, it is suggested that splenic flexure mobilization is performed on an individual basis, depending on the anatomy, disease extent, and the potential for the creation of a tension-free anastomosis [223].

Statement

6.5.1 Partial or full mobilization of the splenic flexure might facilitate the anastomosis being made of soft and compliant descending colon, by being brought down to the pelvic brim and anastomosed with the rectum without tension. It is up to the judgement of the surgeon whether this is necessary.

Evidence level 3, Conditional recommendation. Consensus 100% (second voting)

Acknowledgements

We thank all the national representatives who responded in the second voting round for their valuable contribution: Ondrej Ryska (Czech Republic), Georgios Pechlivanides (Greece), Jürgen Mulsow (Ireland), Jeroen W A Leijtens (Netherlands), Nuno Rama (Portugal), Victor Tomulescu (Romania), Gregor Norčič (Slovenia), Marcel Sadeghi (Sweden), Ugur Sungurtekin (Turkey), Ivan Dimitrijevic (Serbia). Further, we thank the ESCP guideline committee for initiating and supporting the project. Special thanks to Stefan van Dijk and the Dutch guideline group for providing their latest evidence tables.

Funding

The European Society of Coloproctology (ESCP) funded two face to face meetings in conjunction with the ESCP annual meeting. Otherwise, the project did not receive any funding.

Conflicts of interest

WK had fees for teaching and advice from the Institute Allergo San, Austria, and Falk, Germany; otherwise none of the authors reported a conflict of interest.

Ethical approval and informed consent

Ethic approval, patient consent, permissions to reproduce and clinical trial registration not relevant.

References

- 1 Tonelli F, Di Carlo V, Liscia G, Serventi A. [Diverticular disease of the colon: diagnosis and treatment. Consensus Conference, 5th National Congress of the Italian Society of Academic Surgeons]. *Ann Ital Chir* 2009; **80**: 3–8.
- 2 Fozard JB, Armitage NC, Schofield JB, Jones OM, Association of Coloproctology of Great Britain and Ireland. ACPGBI position statement on elective resection for diverticulitis. *Colorectal Dis* 2011; **13**(Suppl 3): 1–11.
- 3 Andersen JC, Bundgaard L, Elbrond H *et al.* Danish national guidelines for treatment of diverticular disease. *Dan Med J* 2012; **59**: C4453.
- 4 Andeweg CS, Mulder IM, Felt-Bersma RJ *et al.* Guidelines of diagnostics and treatment of acute left-sided colonic diverticulitis. *Dig Surg* 2013; **30**: 278–92.
- 5 Kruis W, Germer CT, Leifeld L *et al.* Diverticular disease: guidelines of the German Society for Gastroenterology, Digestive and Metabolic Diseases and the German Society for General and Visceral Surgery. *Digestion* 2014; **90**: 190–207.
- 6 Vennix S, Morton DG, Hahnloser D, Lange JF, Bemelman WA; Research Committee of the European Society of Coloproctology. Systematic review of evidence and consensus on diverticulitis: an analysis of national and international guidelines. *Colorectal Dis* 2014; **16**: 866–78.
- 7 Galetin T, Galetin A, Vestweber KH, Rink AD. Systematic review and comparison of national and international guidelines on diverticular disease. *Int J Colorectal Dis* 2018; **33**: 261–72.
- 8 Oxford Centre for Evidence-Based Medicine 2011 Levels of Evidence. <http://www.cebm.net/wp-content/uploads/2014/06/CEBM-Levels-of-Evidence-2.1.pdf> (accessed September 2017).
- 9 Klarenbeek BR, de Korte N, van der Peet DL, Cuesta MA. Review of current classifications for diverticular disease and a translation into clinical practice. *Int J Colorectal Dis* 2012; **27**: 207–14.
- 10 Hinchey EJ, Schaal PG, Richards GK. Treatment of perforated diverticular disease of the colon. *Adv Surg* 1978; **12**: 85–109.
- 11 Wasvary H, Turfah F, Kadro O, Beauregard W. Same hospitalization resection for acute diverticulitis. *Am Surg* 1999; **65**: 632–5; discussion 636.
- 12 Pfutzer RH, Kruis W. Management of diverticular disease. *Nat Rev Gastroenterol Hepatol* 2015; **12**: 629–38.
- 13 Peery AF, Keku TO, Martin CF *et al.* Distribution and characteristics of colonic diverticula in a United States screening population. *Clin Gastroenterol Hepatol* 2016; **14**: 980–5.e1.
- 14 Rustom LBO, Sharara AI. The natural history of colonic diverticulosis: much ado about nothing? *Inflamm Intest Dis* 2018; **3**: 69–74.
- 15 Peery AF, Keku TO, Addamo C *et al.* Colonic diverticula are not associated with mucosal inflammation or chronic gastrointestinal symptoms. *Clin Gastroenterol Hepatol* 2018; **16**: 884–91.e1.
- 16 Tursi A, Scarpignato C. Symptomatic uncomplicated diverticular disease: chronic abdominal pain in diverticulosis is not enough to make the diagnosis. *Clin Gastroenterol Hepatol* 2018; **16**: 2001–2.
- 17 Jarbrink-Sehgal ME, Andreasson A, Talley NJ, Agreus L, Song JY, Schmidt PT. Symptomatic diverticulosis is characterized by loose stools. *Clin Gastroenterol Hepatol* 2016; **14**: 1763–70.e1.
- 18 Scarpignato C, Barbara G, Lanis A, Strate LL. Management of colonic diverticular disease in the third millennium: highlights from a symposium held during the United European Gastroenterology Week 2017. *Therap Adv Gastroenterol* 2018; **11**: 1–7.
- 19 Cohen E, Fuller G, Bolus R *et al.* Increased risk for irritable bowel syndrome after acute diverticulitis. *Clin Gastroenterol Hepatol* 2013; **11**: 1614–9.
- 20 Cuomo R, Barbara G, Andreatozzi P *et al.* Symptom patterns can distinguish diverticular disease from irritable bowel syndrome. *Eur J Clin Invest* 2013; **43**: 1147–55.
- 21 Strate LL, Morris AM. Epidemiology, pathophysiology, and treatment of diverticulitis. *Gastroenterology* 2019; **156**: 1282–98. e1281.
- 22 Mohammed Ilyas MI, Szilagyi EJ. Management of diverticular bleeding: evaluation, stabilization, intervention,

- and recurrence of bleeding and indications for resection after control of bleeding. *Clin Colon Rectal Surg* 2018; **31**: 243–50.
- 23 Parkes BM, Obeid FN, Sorensen VJ, Horst HM, Fath JJ. The management of massive lower gastrointestinal bleeding. *Am Surg* 1993; **59**: 676–8.
 - 24 Wang FW, Chuang HY, Tu MS *et al*. Prevalence and risk factors of asymptomatic colorectal diverticulosis in Taiwan. *BMC Gastroenterol* 2015; **15**: 40.
 - 25 Shahedi K, Fuller G, Bolus R *et al*. Long-term risk of acute diverticulitis among patients with incidental diverticulosis found during colonoscopy. *Clin Gastroenterol Hepatol* 2013; **11**: 1609–13.
 - 26 Etzioni DA, Mack TM, Beart RW Jr, Kaiser AM. Diverticulitis in the United States: 1998–2005: changing patterns of disease and treatment. *Ann Surg* 2009; **249**: 210–7.
 - 27 Binda GA, Mataloni F, Bruzzone M *et al*. Trends in hospital admission for acute diverticulitis in Italy from 2008 to 2015. *Tech Coloproctol* 2018; **22**: 597–604.
 - 28 Wheat CL, Strate LL. Trends in hospitalization for diverticulitis and diverticular bleeding in the United States from 2000 to 2010. *Clin Gastroenterol Hepatol* 2016; **14**, 96–103. e101.
 - 29 Bolkenstein HE, van de Wall BJM, Consten ECJ, Broeders I, Draaisma WA. Risk factors for complicated diverticulitis: systematic review and meta-analysis. *Int J Colorectal Dis* 2017; **32**: 1375–83.
 - 30 Aune D, Sen A, Leitzmann MF, Norat T, Tonstad S, Vatten LJ. Body mass index and physical activity and the risk of diverticular disease: a systematic review and meta-analysis of prospective studies. *Eur J Nutr* 2017; **56**: 2423–38.
 - 31 Golder M, Ster IC, Babu P, Sharma A, Bayat M, Farah A. Demographic determinants of risk, colon distribution and density scores of diverticular disease. *World J Gastroenterol* 2011; **17**: 1009–17.
 - 32 Granlund J, Svensson T, Olen O *et al*. The genetic influence on diverticular disease – a twin study. *Aliment Pharmacol Ther* 2012; **35**: 1103–7.
 - 33 Strate LL, Erichsen R, Baron JA *et al*. Heritability and familial aggregation of diverticular disease: a population-based study of twins and siblings. *Gastroenterology* 2013; **144**: 736–42. e731; quiz e714.
 - 34 Leganger J, Soborg MK, Mortensen LQ, Gregersen R, Rosenberg J, Burcharth J. Association between diverticular disease and Ehlers–Danlos syndrome: a 13-year nationwide population-based cohort study. *Int J Colorectal Dis* 2016; **31**: 1863–7.
 - 35 Santin BJ, Prasad V, Caniano DA. Colonic diverticulitis in adolescents: an index case and associated syndromes. *Pediatric Surg Int* 2009; **25**: 901–5.
 - 36 Maguire LH, Handelman SK, Du X, Chen Y, Pers TH, Speliotes EK. Genome-wide association analyses identify 39 new susceptibility loci for diverticular disease. *Nat Genet* 2018; **50**: 1359–65.
 - 37 Sigurdsson S, Alexandersson KF, Sulem P *et al*. Sequence variants in ARHGAP15, COLQ and FAM155A associate with diverticular disease and diverticulitis. *Nat Commun* 2017; **8**: 15789.
 - 38 Camilleri M, Sandler RS, Peery AF. Etiopathogenetic mechanisms in diverticular disease of the colon. *Cell Mol Gastroenterol Hepatol* 2020; **9**: 15–32.
 - 39 Crowe FL, Appleby PN, Allen NE, Key TJ. Diet and risk of diverticular disease in Oxford cohort of European Prospective Investigation into Cancer and Nutrition (EPIC): prospective study of British vegetarians and non-vegetarians. *BMJ* 2011; **343**: d4131.
 - 40 Aldoori WH, Giovannucci EL, Rockett HR, Sampson L, Rimm EB, Willett WC. A prospective study of dietary fiber types and symptomatic diverticular disease in men. *J Nutr* 1998; **128**: 714–9.
 - 41 Strate LL, Liu YL, Syngal S, Aldoori WH, Giovannucci EL. Nut, corn, and popcorn consumption and the incidence of diverticular disease. *JAMA* 2008; **300**: 907–14.
 - 42 Hjern F, Wolk A, Hakansson N. Obesity, physical inactivity, and colonic diverticular disease requiring hospitalization in women: a prospective cohort study. *Am J Gastroenterol* 2012; **107**: 296–302.
 - 43 Kopylov U, Ben-Horin S, Lahat A, Segev S, Avidan B, Carter D. Obesity, metabolic syndrome and the risk of development of colonic diverticulosis. *Digestion* 2012; **86**: 201–5.
 - 44 Strate LL, Liu YL, Aldoori WH, Syngal S, Giovannucci EL. Obesity increases the risks of diverticulitis and diverticular bleeding. *Gastroenterology* 2009; **136**, 115–22. e111.
 - 45 Nagata N, Sakamoto K, Arai T *et al*. Visceral abdominal obesity measured by computed tomography is associated with increased risk of colonic diverticulosis. *J Clin Gastroenterol* 2015; **49**: 816–22.
 - 46 Bohm SK, Kruis W. Lifestyle and other risk factors for diverticulitis. *Minerva Gastroenterol Dietol* 2017; **63**: 110–8.
 - 47 Hupfeld L, Pommergaard HC, Burcharth J, Rosenberg J. Emergency admissions for complicated colonic diverticulitis are increasing: a nationwide register-based cohort study. *Int J Colorectal Dis* 2018; **33**: 879–86.
 - 48 Paterson HM, Arnott ID, Nicholls RJ *et al*. Diverticular disease in Scotland: 2000–2010. *Colorectal Dis* 2015; **17**: 329–34.
 - 49 Gregersen R, Andresen K, Burcharth J, Pommergaard HC, Rosenberg J. Short-term mortality, readmission, and recurrence in treatment of acute diverticulitis with abscess formation: a nationwide register-based cohort study. *Int J Colorectal Dis* 2016; **31**: 983–90.
 - 50 Gregersen R, Andresen K, Burcharth J, Pommergaard HC, Rosenberg J. Long-term mortality and recurrence in patients treated for colonic diverticulitis with abscess formation: a nationwide register-based cohort study. *Int J Colorectal Dis* 2018; **33**: 431–40.
 - 51 Vermeulen J, Gosselink MP, Hop WC *et al*. Long-term survival after perforated diverticulitis. *Colorectal Dis* 2011; **13**: 203–9.
 - 52 Ritz JP, Lehmann KS, Frericks B, Stroux A, Buhr HJ, Holmer C. Outcome of patients with acute sigmoid

- diverticulitis: multivariate analysis of risk factors for free perforation. *Surgery* 2011; **149**: 606–13.
- 53 Sharma PV, Eglinton T, Hider P, Frizelle F. Systematic review and meta-analysis of the role of routine colonic evaluation after radiologically confirmed acute diverticulitis. *Ann Surg* 2014; **259**: 263–72.
 - 54 Sai VF, Velayos F, Neuhaus J, Westphalen AC. Colonoscopy after CT diagnosis of diverticulitis to exclude colon cancer: a systematic literature review. *Radiology* 2012; **263**: 383–90.
 - 55 Rottier SJ, van Dijk ST, van Geloven AAW *et al.* Meta-analysis of the role of colonoscopy after an episode of left-sided acute diverticulitis. *Br J Surg* 2019; **106**: 988–97.
 - 56 Meyer J, Orci LA, Combescure C *et al.* Risk of colorectal cancer in patients with acute diverticulitis: a systematic review and meta-analysis of observational studies. *Clin Gastroenterol Hepatol* 2019; **17**, 1448–56. e1417.
 - 57 Daniels L, Unlu C, de Wijkerslooth TR, Dekker E, Boermeester MA. Routine colonoscopy after left-sided acute uncomplicated diverticulitis: a systematic review. *Gastrointest Endosc* 2014; **79**: 378–89 quiz 498–498 e375.
 - 58 Quintero E, Castells A, Bujanda L *et al.* Colonoscopy versus fecal immunochemical testing in colorectal-cancer screening. *N Engl J Med* 2012; **366**: 697–706.
 - 59 Blumenstein I, Tacke W, Bock H *et al.* Prevalence of colorectal cancer and its precursor lesions in symptomatic and asymptomatic patients undergoing total colonoscopy: results of a large prospective, multicenter, controlled endoscopy study. *Eur J Gastroenterol Hepatol* 2013; **25**: 556–61.
 - 60 Niv Y, Hazazi R, Levi Z, Fraser G. Screening colonoscopy for colorectal cancer in asymptomatic people: a meta-analysis. *Dig Dis Sci* 2008; **53**: 3049–54.
 - 61 Meyer J, Thomopoulos T, Usel M *et al.* The incidence of colon cancer among patients diagnosed with left colonic or sigmoid acute diverticulitis is higher than in the general population. *Surg Endosc* 2015; **29**: 3331–7.
 - 62 Almy TP, Howell DA. Medical progress. Diverticular disease of the colon. *N Engl J Med* 1980; **302**: 324–31.
 - 63 Werner A, Diehl SJ, Farag-Soliman M, Duber C. Multi-slice spiral CT in routine diagnosis of suspected acute left-sided colonic diverticulitis: a prospective study of 120 patients. *Eur Radiol* 2003; **13**: 2596–603.
 - 64 Lameris W, van Randen A, van Gulik TM *et al.* A clinical decision rule to establish the diagnosis of acute diverticulitis at the emergency department. *Dis Colon Rectum* 2010; **53**: 896–904.
 - 65 Makela JT, Klintrup K, Rautio T. The role of low CRP values in the prediction of the development of acute diverticulitis. *Int J Colorectal Dis* 2016; **31**: 23–7.
 - 66 Makela JT, Klintrup K, Takala H, Rautio T. The role of C-reactive protein in prediction of the severity of acute diverticulitis in an emergency unit. *Scand J Gastroenterol* 2015; **50**: 536–41.
 - 67 Buchs NC, Konrad-Mugnier B, Jannot AS, Poletti PA, Ambrosetti P, Gervaz P. Assessment of recurrence and complications following uncomplicated diverticulitis. *Br J Surg* 2013; **100**: 976–9; discussion 979.
 - 68 Jamal Talabani A, Endreseth BH, Lydersen S, Edna TH. Clinical diagnostic accuracy of acute colonic diverticulitis in patients admitted with acute abdominal pain, a receiver operating characteristic curve analysis. *Int J Colorectal Dis* 2017; **32**: 41–7.
 - 69 Andeweg CS, Knobben L, Hendriks JC, Bleichrodt RP, van Goor H. How to diagnose acute left-sided colonic diverticulitis: proposal for a clinical scoring system. *Ann Surg* 2011; **253**: 940–6.
 - 70 Kiewiet JJ, Andeweg CS, Laurell H *et al.* External validation of two tools for the clinical diagnosis of acute diverticulitis without imaging. *Dig Liver Dis* 2014; **46**: 119–24.
 - 71 Daniels L, Unlu C, de Korte N *et al.* Randomized clinical trial of observational versus antibiotic treatment for a first episode of CT-proven uncomplicated acute diverticulitis. *Br J Surg* 2017; **104**: 52–61.
 - 72 Lameris W, van Randen A, Bipat S, Bossuyt PM, Boermeester MA, Stoker J. Graded compression ultrasonography and computed tomography in acute colonic diverticulitis: meta-analysis of test accuracy. *Eur Radiol* 2008; **18**: 2498–511.
 - 73 O'Leary DP, Lynch N, Clancy C, Winter DC, Myers E. International, expert-based, consensus statement regarding the management of acute diverticulitis. *JAMA Surg* 2015; **150**: 899–904.
 - 74 Andeweg CS, Wegdam JA, Groenewoud J, van der Wilt GJ, van Goor H, Bleichrodt RP. Toward an evidence-based step-up approach in diagnosing diverticulitis. *Scand J Gastroenterol* 2014; **49**: 775–84.
 - 75 Ripolles T, Agramunt M, Martinez MJ, Costa S, Gomez-Abril SA, Richart J. The role of ultrasound in the diagnosis, management and evolutive prognosis of acute left-sided colonic diverticulitis: a review of 208 patients. *Eur Radiol* 2003; **13**: 2587–95.
 - 76 Schwerk WB, Schwarz S, Rothmund M. Sonography in acute colonic diverticulitis. A prospective study. *Dis Colon Rectum* 1992; **35**: 1077–84.
 - 77 Heverhagen JT, Sitter H, Zielke A, Klose KJ. Prospective evaluation of the value of magnetic resonance imaging in suspected acute sigmoid diverticulitis. *Dis Colon Rectum* 2008; **51**: 1810–5.
 - 78 Sher ME, Agachan F, Bortul M, Nogueras JJ, Weiss EG, Wexner SD. Laparoscopic surgery for diverticulitis. *Surg Endosc* 1997; **11**: 264–7.
 - 79 Kohler L, Sauerland S, Neugebauer E. Diagnosis and treatment of diverticular disease: results of a consensus development conference. The Scientific Committee of the European Association for Endoscopic Surgery. *Surg Endosc* 1999; **13**: 430–6.
 - 80 Mora Lopez L, Flores Clotet R, Serra Aracil X, Montes Ortega N, Navarro SS. The use of the modified Neff classification in the management of acute diverticulitis. *Rev Esp Enferm Dig* 2017; **109**: 328–34.
 - 81 Sartelli M, Moore FA, Ansaloni L *et al.* A proposal for a CT driven classification of left colon acute diverticulitis. *World J Emerg* 2015; **10**: 3.

- 82 Kaiser AM, Jiang JK, Lake JP *et al.* The management of complicated diverticulitis and the role of computed tomography. *Am J Gastroenterol* 2005; **100**: 910–7.
- 83 Ambrosetti P, Jenny A, Becker C, Terrier TF, Morel P. Acute left colonic diverticulitis – compared performance of computed tomography and water-soluble contrast enema: prospective evaluation of 420 patients. *Dis Colon Rectum* 2000; **43**: 1363–7.
- 84 Chabok A, Pahlman L, Hjern F, Haapaniemi S, Smedh K; AVOD Study Group. Randomized clinical trial of antibiotics in acute uncomplicated diverticulitis. *Br J Surg* 2012; **99**: 532–9.
- 85 Isacson D, Smedh K, Nikberg M, Chabok A. Long-term follow-up of the AVOD randomized trial of antibiotic avoidance in uncomplicated diverticulitis. *Br J Surg* 2019; **106**: 1542–8.
- 86 van Dijk ST, Daniels L, Unlu C *et al.* Long-term effects of omitting antibiotics in uncomplicated acute diverticulitis. *Am J Gastroenterol* 2018; **113**: 1045–52.
- 87 Desai M, Fathallah J, Nutalapati V, Saligram S. Antibiotics versus no antibiotics for acute uncomplicated diverticulitis: a systematic review and meta-analysis. *Dis Colon Rectum* 2019; **62**: 1005–12.
- 88 van Dijk ST, Chabok A, Dijkgraaf MG, Boermeester MA, Smedh K. Observational versus antibiotic treatment for uncomplicated diverticulitis: an individual-patient data meta-analysis. *Br J Surg* 2020; **107**: 1062–9. doi:10.1002/bjs.11465.
- 89 Costi R, Cauchy F, Le Bian A, Honart JF, Creuze N, Smadja C. Challenging a classic myth: pneumoperitoneum associated with acute diverticulitis is not an indication for open or laparoscopic emergency surgery in hemodynamically stable patients. A 10-year experience with a nonoperative treatment. *Surg Endosc* 2012; **26**: 2061–71.
- 90 Sallinen VJ, Mentula PJ, Leppaniemi AK. Nonoperative management of perforated diverticulitis with extraluminal air is safe and effective in selected patients. *Dis Colon Rectum* 2014; **57**: 875–81.
- 91 Dharmarajan S, Hunt SR, Birnbaum EH, Fleshman JW, Mutch MG. The efficacy of nonoperative management of acute complicated diverticulitis. *Dis Colon Rectum* 2011; **54**: 663–71.
- 92 van Dijk ST, Doelare SAN, van Geloven AAW, Boermeester MA. A systematic review of pericolic extraluminal air in left-sided acute colonic diverticulitis. *Surg Infect* 2018; **19**: 362–8.
- 93 van Dijk ST, Bos K, de Boer MGJ *et al.* A systematic review and meta-analysis of outpatient treatment for acute diverticulitis. *Int J Colorectal Dis* 2018; **33**: 505–12.
- 94 Cirocchi R, Randolph JJ, Binda GA *et al.* Is the outpatient management of acute diverticulitis safe and effective? A systematic review and meta-analysis. *Tech Coloproctol* 2019; **23**: 87–100.
- 95 Biondo S, Golda T, Kreisler E *et al.* Outpatient versus hospitalization management for uncomplicated diverticulitis: a prospective, multicenter randomized clinical trial (DIVER trial). *Ann Surg* 2014; **259**: 38–44.
- 96 van de Wall BJ, Draaisma WA, van Iersel JJ, van der Kaaij R, Consten EC, Broeders IA. Dietary restrictions for acute diverticulitis: evidence-based or expert opinion? *Int J Colorectal Dis* 2013; **28**: 1287–93.
- 97 Stam MA, Draaisma WA, van de Wall BJ, Bolkenstein HE, Consten EC, Broeders IA. An unrestricted diet for uncomplicated diverticulitis is safe: results of a prospective diverticulitis diet study. *Colorectal Dis* 2017; **19**: 372–7.
- 98 Ridgway PF, Latif A, Shabbir J *et al.* Randomized controlled trial of oral *vs* intravenous therapy for the clinically diagnosed acute uncomplicated diverticulitis. *Colorectal Dis* 2009; **11**: 941–6.
- 99 Iannone A, Ruospo M, Wong G *et al.* Mesalazine for people with diverticular disease: a systematic review of randomized controlled trials. *Can J Gastroenterol Hepatol* 2018; **2018**: 1–12.
- 100 Parente F, Bargiggia S, Prada A *et al.* Intermittent treatment with mesalazine in the prevention of diverticulitis recurrence: a randomised multicentre pilot double-blind placebo-controlled study of 24-month duration. *Int J Colorectal Dis* 2013; **28**: 1423–31.
- 101 Stollman N, Magowan S, Shanahan F, Quigley EM, DIVA Investigator Group. A randomized controlled study of mesalamine after acute diverticulitis: results of the DIVA trial. *J Clin Gastroenterol* 2013; **47**: 621–9.
- 102 Lanis A, Ponce J, Bignamini A, Mearin F. One year intermittent rifaximin plus fibre supplementation *vs.* fibre supplementation alone to prevent diverticulitis recurrence: a proof-of-concept study. *Dig Liver Dis* 2013; **45**: 104–9.
- 103 Festa V, Spila Alegiani S, Chiesara F *et al.* Retrospective comparison of long-term ten-day/month rifaximin or mesalazine in prevention of relapse in acute diverticulitis. *Eur Rev Med Pharmacol Sci* 2017; **21**: 1397–404.
- 104 Tursi A, Elisei W, Giorgetti GM *et al.* Effectiveness of different therapeutic strategies in preventing diverticulitis recurrence. *Eur Rev Med Pharmacol Sci* 2013; **17**: 342–8.
- 105 Dughera L, Serra AM, Battaglia E, Tibaudi D, Navino M, Emanuelli G. Acute recurrent diverticulitis is prevented by oral administration of a polybacterial lysate suspension. *Minerva Gastroenterol Dietol* 2004; **50**: 149–53.
- 106 Dahl C, Crichton M, Jenkins J *et al.* Evidence for dietary fibre modification in the recovery and prevention of recurrence of acute, uncomplicated diverticulitis: a systematic literature review. *Nutrients* 2018; **10**: 1–18.
- 107 Leahy AL, Ellis RM, Quill DS, Peel AL. High fibre diet in symptomatic diverticular disease of the colon. *Ann R Coll Surg Engl* 1985; **67**: 173–4.
- 108 Crowe FL, Balkwill A, Cairns BJ *et al.* Source of dietary fibre and diverticular disease incidence: a prospective study of UK women. *Gut* 2014; **63**: 1450–6.
- 109 Gregersen R, Mortensen LQ, Burcharth J, Pommergaard HC, Rosenberg J. Treatment of patients with acute colonic diverticulitis complicated by abscess formation: a systematic review. *Int J Surg* 2016; **35**: 201–8.
- 110 Lambrichts DPV, Bolkenstein HE, van der Does D *et al.* Multicentre study of non-surgical management of

- diverticulitis with abscess formation. *Br J Surg* 2019; **106**: 458–66.
- 111 Sallinen VJ, Leppaniemi AK, Mentula PJ. Staging of acute diverticulitis based on clinical, radiologic, and physiologic parameters. *J Trauma Acute Care Surg* 2015; **78**: 543–51.
 - 112 Thorisson A, Smedh K, Torkzad MR, Pahlman L, Chabok A. CT imaging for prediction of complications and recurrence in acute uncomplicated diverticulitis. *Int J Colorectal Dis* 2016; **31**: 451–7.
 - 113 Mora Lopez L, Serra Pla S, Serra-Aracil X, Ballesteros E, Navarro S. Application of a modified Neff classification to patients with uncomplicated diverticulitis. *Colorectal Dis* 2013; **15**: 1442–7.
 - 114 Garcia-Gomez MA, Belmonte-Montes C, Cosme-Reyes C, Aguirre Garcia MP. [Prognostic value of the presence of pericolic air bubbles detected by computed tomography in acute diverticulitis]. *Cir Cir* 2017; **85**: 471–7.
 - 115 Lahat A, Avidan B, Sakhnini E, Katz L, Fidler HH, Meir SB. Acute diverticulitis: a decade of prospective follow-up. *J Clin Gastroenterol* 2013; **47**: 415–9.
 - 116 Sohn M, Iesalnieks I, Agha A *et al.* Perforated diverticulitis with generalized peritonitis: low stoma rate using a ‘Damage Control Strategy’. *World J Surg* 2018; **42**: 3189–95.
 - 117 Oberkofler CE, Rickenbacher A, Raptis DA *et al.* A multicenter randomized clinical trial of primary anastomosis or Hartmann’s procedure for perforated left colonic diverticulitis with purulent or fecal peritonitis. *Ann Surg* 2012; **256**: 819–26; discussion 826–817.
 - 118 Binda GA, Karas JR, Serventi A *et al.* Primary anastomosis *vs* nonrestorative resection for perforated diverticulitis with peritonitis: a prematurely terminated randomized controlled trial. *Colorectal Dis* 2012; **14**: 1403–10.
 - 119 Bridoux V, Regimbeau JM, Ouaisi M *et al.* Hartmann’s procedure or primary anastomosis for generalized peritonitis due to perforated diverticulitis: a prospective multicenter randomized trial (DIVERTI). *J Am Coll Surg* 2017; **225**: 798–805.
 - 120 Franklin ME Jr, Portillo G, Trevino JM, Gonzalez JJ, Glass JL. Long-term experience with the laparoscopic approach to perforated diverticulitis plus generalized peritonitis. *World J Surg* 2008; **32**: 1507–11.
 - 121 Sohn M, Agha A, Heitland W, Gundling F, Steiner P, Iesalnieks I. Damage control strategy for the treatment of perforated diverticulitis with generalized peritonitis. *Tech Coloproctol* 2016; **20**: 577–83.
 - 122 Schultz JK, Yaqub S, Wallon C *et al.* Laparoscopic lavage *vs* primary resection for acute perforated diverticulitis: the SCANDIV randomized clinical trial. *JAMA* 2015; **314**: 1364–75.
 - 123 Vennix S, Musters GD, Mulder IM *et al.* Laparoscopic peritoneal lavage or sigmoidectomy for perforated diverticulitis with purulent peritonitis: a multicentre, parallel-group, randomised, open-label trial. *Lancet* 2015; **386**: 1269–77.
 - 124 Thornell A, Angenete E, Bisgaard T *et al.* Laparoscopic lavage for perforated diverticulitis with purulent peritonitis: a randomized trial. *Ann Intern Med* 2016; **164**: 137–45.
 - 125 Angenete E, Bock D, Rosenberg J, Haglind E. Laparoscopic lavage is superior to colon resection for perforated purulent diverticulitis –a meta-analysis. *Int J Colorectal Dis* 2017; **32**: 163–9.
 - 126 Ceresoli M, Coccolini F, Montori G, Catena F, Sartelli M, Ansaloni L. Laparoscopic lavage versus resection in perforated diverticulitis with purulent peritonitis: a meta-analysis of randomized controlled trials. *World J Emerg Surg* 2016; **11**: 42.
 - 127 Cirocchi R, Di Saverio S, Weber DG *et al.* Laparoscopic lavage versus surgical resection for acute diverticulitis with generalised peritonitis: a systematic review and meta-analysis. *Tech Coloproctol* 2017; **21**: 93–110.
 - 128 Galbraith N, Carter JV, Netz U *et al.* Laparoscopic lavage in the management of perforated diverticulitis: a contemporary meta-analysis. *J Gastrointest Surg* 2017; **21**: 1491–9.
 - 129 Marshall JR, Buchwald PL, Gandhi J *et al.* Laparoscopic lavage in the management of Hinchey grade III diverticulitis: a systematic review. *Ann Surg* 2017; **265**: 670–6.
 - 130 Penna M, Markar SR, Mackenzie H, Hompes R, Cunningham C. Laparoscopic lavage versus primary resection for acute perforated diverticulitis: review and meta-analysis. *Ann Surg* 2018; **267**: 252–8.
 - 131 Shaikh FM, Stewart PM, Walsh SR, Davies RJ. Laparoscopic peritoneal lavage or surgical resection for acute perforated sigmoid diverticulitis: a systematic review and meta-analysis. *Int J Surg* 2017; **38**: 130–7.
 - 132 Acuna SA, Wood T, Chesney TR *et al.* Operative strategies for perforated diverticulitis: a systematic review and meta-analysis. *Dis Colon Rectum* 2018; **61**: 1442–53.
 - 133 Schmidt S, Ismail T, Puhon MA, Soll C, Breitenstein S. Meta-analysis of surgical strategies in perforated left colonic diverticulitis with generalized peritonitis. *Langenbecks Arch Surg* 2018; **403**: 425–33.
 - 134 Binda GA, Bonino MA, Siri G *et al.* Multicentre international trial of laparoscopic lavage for Hinchey III acute diverticulitis (LLO Study). *Br J Surg* 2018; **105**: 1835–43.
 - 135 Schultz JK, Wallon C, Blecic L *et al.* One-year results of the SCANDIV randomized clinical trial of laparoscopic lavage versus primary resection for acute perforated diverticulitis. *Br J Surg* 2017; **104**: 1382–92.
 - 136 Kohl A, Rosenberg J, Bock D *et al.* Two-year results of the randomized clinical trial DILALA comparing laparoscopic lavage with resection as treatment for perforated diverticulitis. *Br J Surg* 2018; **105**: 1128–34.
 - 137 Angenete E, Thornell A, Burcharth J *et al.* Laparoscopic lavage is feasible and safe for the treatment of perforated diverticulitis with purulent peritonitis: the first results from the randomized controlled trial DILALA. *Ann Surg* 2016; **263**: 117–22.
 - 138 Gehrmann J, Angenete E, Bjorholt I, Bock D, Rosenberg J, Haglind E. Health economic analysis of laparoscopic lavage versus Hartmann’s procedure for diverticulitis in

- the randomized DILALA trial. *Br J Surg* 2016; **103**: 1539–47.
- 139 Vennix S, van Dieren S, Opmeer BC, Lange JF, Bemelman WA. Cost analysis of laparoscopic lavage compared with sigmoid resection for perforated diverticulitis in the LADIES trial. *Br J Surg* 2017; **104**: 62–8.
 - 140 Sohn MA, Agha A, Steiner P *et al.* Damage control surgery in perforated diverticulitis: ongoing peritonitis at second surgery predicts a worse outcome. *Int J Colorectal Dis* 2018; **33**: 871–8.
 - 141 Cauley CE, Patel R, Bordeianou L. Use of primary anastomosis with diverting ileostomy in patients with acute diverticulitis requiring urgent operative intervention. *Dis Colon Rectum* 2018; **61**: 586–92.
 - 142 Lambrechts DPV, Vennix S, Musters GD *et al.* Hartmann's procedure versus sigmoidectomy with primary anastomosis for perforated diverticulitis with purulent or faecal peritonitis (LADIES): a multicentre, parallel-group, randomised, open-label, superiority trial. *Lancet Gastroenterol Hepatol* 2019; **4**: 599–610.
 - 143 Wong WD, Wexner SD, Lowry A *et al.* Practice parameters for the treatment of sigmoid diverticulitis – supporting documentation. The Standards Task Force. The American Society of Colon and Rectal Surgeons. *Dis Colon Rectum* 2000; **43**: 290–7.
 - 144 Roberts P, Abel M, Rosen L *et al.* Practice parameters for sigmoid diverticulitis. The Standards Task Force American Society of Colon and Rectal Surgeons. *Dis Colon Rectum* 1995; **38**: 125–32.
 - 145 Haglund U, Hellberg R, Johnsen C, Hulten L. Complicated diverticular disease of the sigmoid colon. An analysis of short and long term outcome in 392 patients. *Ann Chir Gynaecol* 1979; **68**: 41–6.
 - 146 Klarenbeek BR, Samuels M, van der Wal MA, van der Peet DL, Meijerink WJ, Cuesta MA. Indications for elective sigmoid resection in diverticular disease. *Ann Surg* 2010; **251**: 670–4.
 - 147 Boostrom SY, Wolff BG, Cima RR, Merchea A, Dozois EJ, Larson DW. Uncomplicated diverticulitis, more complicated than we thought. *J Gastrointest Surg* 2012; **16**: 1744–9.
 - 148 Li D, Baxter NN, McLeod RS, Moineddin R, Nathens AB. The decline of elective colectomy following diverticulitis: a population-based analysis. *Dis Colon Rectum* 2016; **59**: 332–9.
 - 149 von Strauss und Torney M, Thommen S, Dell-Kuster S *et al.* Surgical treatment of uncomplicated diverticulitis in Switzerland: comparison of population-based data over two time periods. *Colorectal Dis* 2017; **19**: 840–50.
 - 150 Brandlhuber M, Genzinger C, Brandlhuber B, Sommer WH, Muller MH, Kreis ME. Long-term quality of life after conservative treatment versus surgery for different stages of acute sigmoid diverticulitis. *Int J Colorectal Dis* 2018; **33**: 317–26.
 - 151 Polese L, Bressan A, Savarino E *et al.* Quality of life after laparoscopic sigmoid resection for uncomplicated diverticular disease. *Int J Colorectal Dis* 2018; **33**: 513–23.
 - 152 Andeweg CS, Berg R, Staal JB, ten Broek RP, van Goor H. Patient-reported outcomes after conservative or surgical management of recurrent and chronic complaints of diverticulitis: systematic review and meta-analysis. *Clin Gastroenterol Hepatol* 2016; **14**: 183–90.
 - 153 Bolkenstein HE, Consten ECJ, van der Palen J *et al.* Long-term outcome of surgery versus conservative management for recurrent and ongoing complaints after an episode of diverticulitis: 5-year follow-up results of a multicenter randomized controlled trial (DIRECT-Trial). *Ann Surg* 2019; **269**: 612–20.
 - 154 van de Wall BJM, Stam MAW, Draaisma WA *et al.* Surgery versus conservative management for recurrent and ongoing left-sided diverticulitis (DIRECT trial): an open-label, multicentre, randomised controlled trial. *Lancet Gastroenterol Hepatol* 2017; **2**: 13–22.
 - 155 Lamb MN, Kaiser AM. Elective resection versus observation after nonoperative management of complicated diverticulitis with abscess: a systematic review and meta-analysis. *Dis Colon Rectum* 2014; **57**: 1430–40.
 - 156 Eglinton T, Nguyen T, Raniga S, Dixon L, Dobbs B, Fризelle FA. Patterns of recurrence in patients with acute diverticulitis. *Br J Surg* 2010; **97**: 952–7.
 - 157 Rose J, Parina RP, Faiz O, Chang DC, Talamini MA. Long-term outcomes after initial presentation of diverticulitis. *Ann Surg* 2015; **262**: 1046–53.
 - 158 Aquina CT, Becerra AZ, Xu Z *et al.* Population-based study of outcomes following an initial acute diverticular abscess. *Br J Surg* 2019; **106**: 467–76.
 - 159 Buchwald P, Dixon L, Wakeman CJ, Eglinton TW, Fризelle FA. Hinchey I and II diverticular abscesses: long-term outcome of conservative treatment. *ANZ J Surg* 2017; **87**: 1011–4.
 - 160 Devaraj B, Liu W, Tatum J, Cologne K, Kaiser AM. Medically treated diverticular abscess associated with high risk of recurrence and disease complications. *Dis Colon Rectum* 2016; **59**: 208–15.
 - 161 Garfinkle R, Kugler A, Pelsser V *et al.* Diverticular abscess managed with long-term definitive nonoperative intent is safe. *Dis Colon Rectum* 2016; **59**: 648–55.
 - 162 Jalouta T, Jrebi N, Luchtefeld M, Ogilvie JW Jr. Diverticulitis recurrence after percutaneous abscess drainage. *Int J Colorectal Dis* 2017; **32**: 1367–73.
 - 163 You K, Bendl R, Taut C *et al.* Randomized clinical trial of elective resection versus observation in diverticulitis with extraluminal air or abscess initially managed conservatively. *Br J Surg* 2018; **105**: 971–9.
 - 164 Rosen DR, Hwang GS, Ault GT, Ortega AE, Cologne KG. Operative management of diverticulitis in a tertiary care center. *Am J Surg* 2017; **214**: 37–41.
 - 165 Smeenk RM, Plaisier PW, van der Hoeven JA, Hesp WL. Outcome of surgery for colovesical and colovaginal fistulas of diverticular origin in 40 patients. *J Gastrointest Surg* 2012; **16**: 1559–65.
 - 166 Niebling M, van Nunspeet L, Zwaving H, Eddes EH, Bosker R, Schattenkerk ME. Management of colovesical

- fistulae caused by diverticulitis: 12 years of experience in one medical centre. *Acta Chir Belg* 2013; **113**: 30–4.
- 167 Miyaso H, Iwakawa K, Hamada Y *et al.* Ten cases of colovesical fistula due to sigmoid diverticulitis. *Hiroshima J Med Sci* 2015; **64**: 9–13.
 - 168 Melchior S, Cudovic D, Jones J, Thomas C, Gillitzer R, Thuroff J. Diagnosis and surgical management of colovesical fistulas due to sigmoid diverticulitis. *J Urol* 2009; **182**: 978–82.
 - 169 Marney LA, Ho YH. Laparoscopic management of diverticular colovesical fistula: experience in 15 cases and review of the literature. *Int Surg* 2013; **98**: 101–9.
 - 170 Aydinli HH, Benlice C, Ozuner G, Gorgun E, Abbas MA. Risk factors associated with postoperative morbidity in over 500 colovesical fistula patients undergoing colorectal surgery: a retrospective cohort study from ACS-NSQIP database. *Int J Colorectal Dis* 2017; **32**: 469–74.
 - 171 Anania G, Vedana L, Santini M *et al.* Complications of diverticular disease: surgical laparoscopic treatment. *G Chir* 2014; **35**: 126–8.
 - 172 Abbass MA, Tsay AT, Abbas MA. Laparoscopic resection of chronic sigmoid diverticulitis with fistula. *JSLS* 2013; **17**: 636–40.
 - 173 Badic B, Leroux G, Thereaux J *et al.* Colovesical fistula complicating diverticular disease: a 14-year experience. *Surg Laparosc Endosc Percutan Tech* 2017; **27**: 94–7.
 - 174 Cirocchi R, Cochetti G, Randolph J *et al.* Laparoscopic treatment of colovesical fistulas due to complicated colonic diverticular disease: a systematic review. *Tech Coloproctol* 2014; **18**: 873–85.
 - 175 Cirocchi R, Arezzo A, Renzi C *et al.* Is laparoscopic surgery the best treatment in fistulas complicating diverticular disease of the sigmoid colon? A systematic review. *Int J Surg* 2015; **24**(Pt A): 95–100.
 - 176 Maciel V, Lujan HJ, Plasencia G *et al.* Diverticular disease complicated with colovesical fistula: laparoscopic versus robotic management. *Int Surg* 2014; **99**: 203–10.
 - 177 Elliott PA, McLemore EC, Abbass MA, Abbas MA. Robotic versus laparoscopic resection for sigmoid diverticulitis with fistula. *J Robot Surg* 2015; **9**: 137–42.
 - 178 Solkar MH, Forshaw MJ, Sankararajah D, Stewart M, Parker MC. Colovesical fistula – is a surgical approach always justified? *Colorectal Dis* 2005; **7**: 467–71.
 - 179 Garcea G, Majid I, Sutton CD, Pattenden CJ, Thomas WM. Diagnosis and management of colovesical fistulae; six-year experience of 90 consecutive cases. *Colorectal Dis* 2006; **8**: 347–52.
 - 180 Papageorge CM, Kennedy GD, Carchman EH. National trends in short-term outcomes following non-emergent surgery for diverticular disease. *J Gastrointest Surg* 2016; **20**: 1376–87.
 - 181 Levack M, Berger D, Sylla P, Rattner D, Bordeianou L. Laparoscopy decreases anastomotic leak rate in sigmoid colectomy for diverticulitis. *Arch Surg* 2011; **146**: 207–10.
 - 182 Keller DS, Delaney CP, Hashemi L, Haas EM. A national evaluation of clinical and economic outcomes in open versus laparoscopic colorectal surgery. *Surg Endosc* 2016; **30**: 4220–8.
 - 183 Masoomi H, Buchberg BS, Magno C, Mills SD, Stamos MJ. Trends in diverticulitis management in the United States from 2002 to 2007. *Arch Surg* 2011; **146**: 400–6.
 - 184 Kirchhoff P, Matz D, Dincler S, Buchmann P. Predictive risk factors for intra- and postoperative complications in 526 laparoscopic sigmoid resections due to recurrent diverticulitis: a multivariate analysis. *World J Surg* 2011; **35**: 677–83.
 - 185 Pendlimari R, Touzios JG, Azodo IA *et al.* Short-term outcomes after elective minimally invasive colectomy for diverticulitis. *Br J Surg* 2011; **98**: 431–5.
 - 186 Raue W, Paolucci V, Asperger W *et al.* Laparoscopic sigmoid resection for diverticular disease has no advantages over open approach: midterm results of a randomized controlled trial. *Langenbecks Arch Surg* 2011; **396**: 973–80.
 - 187 Gervaz P, Inan I, Perneger T, Schiffer E, Morel P. A prospective, randomized, single-blind comparison of laparoscopic versus open sigmoid colectomy for diverticulitis. *Ann Surg* 2010; **252**: 3–8.
 - 188 Klarenbeek BR, Veenhof AA, Bergamaschi R *et al.* Laparoscopic sigmoid resection for diverticulitis decreases major morbidity rates: a randomized control trial: short-term results of the Sigma Trial. *Ann Surg* 2009; **249**: 39–44.
 - 189 Cirocchi R, Farinella E, Trastulli S, Sciannone F, Audisio RA. Elective sigmoid colectomy for diverticular disease. Laparoscopic *vs* open surgery: a systematic review. *Colorectal Dis* 2012; **14**: 671–83.
 - 190 Haas JM, Singh M, Vakil N. Mortality and complications following surgery for diverticulitis: systematic review and meta-analysis. *United Eur Gastroenterol J* 2016; **4**: 706–13.
 - 191 Abraha I, Binda GA, Montedori A, Arezzo A, Cirocchi R. Laparoscopic versus open resection for sigmoid diverticulitis. *Cochrane Database Syst Rev* 2017; **11**: CD009277.
 - 192 Biondo S, Borao JL, Kreisler E *et al.* Recurrence and virulence of colonic diverticulitis in immunocompromised patients. *Am J Surg* 2012; **204**: 172–9.
 - 193 Pourfarziani V, Mousavi-Nayeeni SM, Ghaheiri H *et al.* The outcome of diverticulosis in kidney recipients with polycystic kidney disease. *Transplant Proc* 2007; **39**: 1054–6.
 - 194 Oor JE, Atema JJ, Boermeester MA, Vrouenraets BC, Unlu C. A systematic review of complicated diverticulitis in post-transplant patients. *J Gastrointest Surg* 2014; **18**: 2038–46.
 - 195 Sugrue J, Lee J, Warner C *et al.* Acute diverticulitis in renal transplant patients: should we treat them differently? *Surgery* 2018; **163**: 857–65.
 - 196 Lee JT, Skube S, Melton GB *et al.* Elective colectomy for diverticulitis in transplant patients: is it worth the risk? *J Gastrointest Surg* 2017; **21**: 1486–90.
 - 197 Biondo S, Trenti L, Elvira J, Golda T, Kreisler E. Outcomes of colonic diverticulitis according to the reason of immunosuppression. *Am J Surg* 2016; **212**: 384–90.
 - 198 Rafferty J, Shellito P, Hyman NH, Buie WD, Standards Committee of the American Society of Colon and Rectal

- Surgeons. Practice parameters for sigmoid diverticulitis. *Dis Colon Rectum* 2006; **49**: 939–44.
- 199 van de Wall BJ, Poerink JA, Draaisma WA, Reitsma JB, Consten EC, Broeders IA. Diverticulitis in young versus elderly patients: a meta-analysis. *Scand J Gastroenterol* 2013; **48**: 643–51.
 - 200 Simianu VV, Fichera A, Bastawrous AL *et al.* Number of diverticulitis episodes before resection and factors associated with earlier interventions. *JAMA Surg* 2016; **151**: 604–10.
 - 201 Wu Z, van de Haar RC, Sparreboom CL *et al.* Is the intraoperative air leak test effective in the prevention of colorectal anastomotic leakage? A systematic review and meta-analysis. *Int J Colorectal Dis* 2016; **31**: 1409–17.
 - 202 Daams F, Wu Z, Lahaye MJ, Jeekel J, Lange JF. Prediction and diagnosis of colorectal anastomotic leakage: a systematic review of literature. *World J Gastrointest Surg* 2014; **6**: 14–26.
 - 203 Beard JD, Nicholson ML, Sayers RD, Lloyd D, Everson NW. Intraoperative air testing of colorectal anastomoses: a prospective, randomized trial. *Br J Surg* 1990; **77**: 1095–7.
 - 204 Benn PL, Wolff BG, Ilstrup DM. Level of anastomosis and recurrent colonic diverticulitis. *Am J Surg* 1986; **151**: 269–71.
 - 205 Bergamaschi R, Arnaud JP. Anastomosis level and specimen length in surgery for uncomplicated diverticulitis of the sigmoid. *Surg Endosc* 1998; **12**: 1149–51.
 - 206 Bressan A, Marini L, Michelotto M *et al.* Risk factors including the presence of inflammation at the resection margins for colorectal anastomotic stenosis following surgery for diverticular disease. *Colorectal Dis* 2018; **20**: 923–30.
 - 207 Thaler K, Baig MK, Berho M *et al.* Determinants of recurrence after sigmoid resection for uncomplicated diverticulitis. *Dis Colon Rectum* 2003; **46**: 385–8.
 - 208 Thaler K, Weiss EG, Noguera JJ, Arnaud JP, Wexner SD, Bergamaschi R. Recurrence rates at minimum 5-year follow-up: laparoscopic versus open sigmoid resection for uncomplicated diverticulitis. *Surg Laparosc Endosc Percutan Tech* 2003; **13**: 325–7.
 - 209 Wolff BG, Ready RL, MacCarty RL, Dozois RR, Beart RW Jr. Influence of sigmoid resection on progression of diverticular disease of the colon. *Dis Colon Rectum* 1984; **27**: 645–7.
 - 210 Cirocchi R, Trastulli S, Farinella E *et al.* Is inferior mesenteric artery ligation during sigmoid colectomy for diverticular disease associated with increased anastomotic leakage? A meta-analysis of randomized and non-randomized clinical trials. *Colorectal Dis* 2012; **14**: e521–e529.
 - 211 Masoni L, Mari FS, Nigri G *et al.* Preservation of the inferior mesenteric artery via laparoscopic sigmoid colectomy performed for diverticular disease: real benefit or technical challenge: a randomized controlled clinical trial. *Surg Endosc* 2013; **27**: 199–206.
 - 212 Tocchi A, Mazzoni G, Fornasari V, Miccini M, Daddi G, Tagliacozzo S. Preservation of the inferior mesenteric artery in colorectal resection for complicated diverticular disease. *Am J Surg* 2001; **182**: 162–7.
 - 213 Borchert DH, Schachtebeck M, Schoepe J *et al.* Observational study on preservation of the superior rectal artery in sigmoid resection for diverticular disease. *Int J Surg* 2015; **21**: 45–50.
 - 214 De Nardi P, Gazzetta P. Does inferior mesenteric artery ligation affect outcome in elective colonic resection for diverticular disease? *ANZ J Surg* 2018; **88**: E778–E781.
 - 215 Lehmann RK, Brounts LR, Johnson EK, Rizzo JA, Steele SR. Does sacrifice of the inferior mesenteric artery or superior rectal artery affect anastomotic leak following sigmoidectomy for diverticulitis? A retrospective review. *Am J Surg* 2011; **201**: 623–7.
 - 216 Posabella A, Rotigliano N, Tampakis A, von Flue M, Fuglistaler I. Peripheral vs pedicle division in laparoscopic resection of sigmoid diverticulitis: a 10-year experience. *Int J Colorectal Dis* 2018; **33**: 887–94.
 - 217 Sohn M, Schlitt HJ, Hornung M *et al.* Preservation of the superior rectal artery: influence of surgical technique on anastomotic healing and postoperative morbidity in laparoscopic sigmoidectomy for diverticular disease. *Int J Colorectal Dis* 2017; **32**: 955–60.
 - 218 Cirocchi R, Popivanov G, Binda GA *et al.* Sigmoid resection for diverticular disease – to ligate or to preserve the inferior mesenteric artery? Results of a systematic review and meta-analysis. *Colorectal Dis* 2019; **21**: 623–31.
 - 219 Chiu AS, Jean RA, Gorecka J, Davis KA, Pei KY. Trends of ureteral stent usage in surgery for diverticulitis. *J Surg Res* 2018; **222**, 203–11. e203.
 - 220 Coakley KM, Kasten KR, Sims SM, Prasad T, Heniford BT, Davis BR. Prophylactic ureteral catheters for colectomy: a national surgical quality improvement program-based analysis. *Dis Colon Rectum* 2018; **61**: 84–8.
 - 221 Masoomi H, Buchberg B, Nguyen B, Tung V, Stamos MJ, Mills S. Outcomes of laparoscopic versus open colectomy in elective surgery for diverticulitis. *World J Surg* 2011; **35**: 2143–8.
 - 222 Speicher PJ, Goldsmith ZG, Nussbaum DP, Turley RS, Peterson AC, Mantyh CR. Ureteral stenting in laparoscopic colorectal surgery. *J Surg Res* 2014; **190**: 98–103.
 - 223 Schlussek AT, Wiseman JT, Kelly JF *et al.* Location is everything: the role of splenic flexure mobilization during colon resection for diverticulitis. *Int J Surg* 2017; **40**: 124–9.
 - 224 Simon T, Orangio GR, Ambroze WL *et al.* Factors associated with complications of open versus laparoscopic sigmoid resection for diverticulitis. *JSLC* 2005; **9**: 63–7.

Supporting Information

Additional Supporting Information may be found in the online version of this article:

Data S1. Evidence tables workgroup 1 Aetiology, follow-up including risk for cancer - Statement of the Problem and epidemiology

Data S2. Evidence tables workgroup 2 Imaging, indication and classifications - initial evaluation of diverticulitis and imaging

Data S3. Evidence tables workgroup 3 Non-surgical management of diverticulitis and dietary recommendations

Data S4. Evidence tables workgroup 4 Emergency surgery for acute diverticulitis

Data S5. Evidence tables workgroup 5 Elective surgery for Diverticulitis

Data S6. Evidence tables workgroup 6 Technical Considerations - Special Considerations