



Article scientifique

Article

1997

Published version

Open Access

This is the published version of the publication, made available in accordance with the publisher's policy.

Sentence reading: a functional MRI study at 4 tesla

Bavelier, Daphné; Corina, D; Jezzard, P; Padmanabhan, S; Clark, V P; Karni, A; Prinster, A; Braun, A; Lalwani, A; Rauschecker, J P; Turner, R; Neville, H

How to cite

BAVELIER, Daphné et al. Sentence reading: a functional MRI study at 4 tesla. In: Journal of Cognitive Neuroscience, 1997, vol. 9, n° 5, p. 664–686. doi: 10.1162/jocn.1997.9.5.664

This publication URL: <https://archive-ouverte.unige.ch/unige:97803>

Publication DOI: [10.1162/jocn.1997.9.5.664](https://doi.org/10.1162/jocn.1997.9.5.664)

Sentence Reading: A Functional MRI Study at 4 Tesla

D. Bavelier

Georgetown Institute for Cognitive and Computational Sciences

D. Corina

University of Washington

P. Jezzard

National Institute of Mental Health, NIH

S. Padmanabhan

University of Oregon

V. P. Clark and A. Karni

National Institute of Mental Health, NIH

A. Prinster

INB CNR U. Milan, Inst. H. S. Raffaele

A. Braun

National Institute on Deafness and Communication Disorders, NIH

A. Lalwani

Epstein Laboratories, San Francisco

J. P. Rauschecker

Georgetown Institute for Cognitive and Computational Sciences
National Institute of Mental Health, NIH

R. Turner

Wellcome Department of Cognitive Neurology—Institute of Neurology

H. Neville

University of Oregon

Abstract

■ In this study, changes in blood oxygenation and volume were monitored while monolingual right-handed subjects read English sentences. Our results confirm the role of the left peri-sylvian cortex in language processing. Interestingly, individual subject analyses reveal a pattern of activation characterized by several small, limited patches rather than a few large, anatomically well-circumscribed centers. Between-subject analyses confirm a lateralized pattern of activation and reveal active

classical language areas including Broca's area, Wernicke's area, and the angular gyrus. In addition they point to areas only more recently considered as language-relevant including the anterior portion of the superior temporal sulcus. This area has not been reliably observed in imaging studies of isolated word processing. This raises the hypothesis that activation in this area is dependent on processes specific to sentence reading. ■

INTRODUCTION

The study of the neurobiology of language has been dominated by an approach, defined in the last century, which hypothesized a few, well-circumscribed cerebral regions or centers specialized for activities related to language. This approach led to the proposal of a framework for the cortical organization of language in which three main cerebral regions in the left peri-sylvian cortex played a major role in language activities: the frontal operculum (Broca's area) for speech production, the posterior part of the superior temporal region and the supramarginal gyrus (Wernicke's area) for speech comprehension, and the angular gyrus, characterized by Dejerine, for written word processing (for reviews, see Caplan, 1987; Damasio, 1991). Although this view has been extremely enduring, the field of the neurobiology of language has undergone a profound revolution as the tools for localizing brain structures and for assessing behavior have become more and more refined. This work has led some authors to reconsider the role of the traditional language centers in language processing and to challenge the traditional view of cortically well-delineated language centers.

The advent of noninvasive high-resolution anatomical imaging techniques, such as computerized tomography and, more recently, functional magnetic resonance imaging (fMRI), has provided the means of characterizing with considerable anatomical detail cerebral lesions and their surrounding tissues. These new techniques have allowed a concurrent assessment of behavior and localization of lesions in many patients. Overall, this wealth of data has confirmed the critical role of the left peri-sylvian cortex for language processing. However, it has also clearly revealed a number of inconsistencies within the classical framework of language centers. Probably the most striking ones are dissociations between a given function and its proposed underlying neural substrate. For example, not all patients diagnosed with Broca's aphasia have a lesion in Broca's area, and lesions in Broca's area do not always result in Broca's aphasia (Kertesz, Harlock, & Coates, 1979; Kohlmeyer, 1979; Mohr, 1976; Moutier, 1908; Murdoch, Afford, Ling, & Ganguley, 1986; see also Dronkers, Shapiro, Redfern, & Knight, submitted for review). New techniques that allow the reconstruction of lesions onto standardized templates have permitted the characterization of the variability and overlap of lesions across patients. Dronkers, Redfern, and Ludy (1995), for example, have found that Wernicke's aphasia is not predicted by lesions to Wernicke's area alone but rather by widespread damage to the temporal lobe that extends to the deep white matter of the posterior temporal cortex and middle temporal gyrus. In general, these studies indicate that a part of the cortex considerably more extensive than the traditionally associated cerebral region must be lesioned in order to produce a persisting aphasic syndrome. The

view of a more widespread cortical organization for language is also supported by the pattern of results revealed by the use of techniques such as electrical stimulation (Penfield & Roberts, 1959; Ojemann, 1991), recordings of neuronal impulse activity (Bechtereva, Medvedev, Abdullaev, Melnichuk, & Gurchin, 1989a, 1989b; Creutzfeldt, Ojemann, & Lettich, 1989), and subdural electrode implants (Halgren et al., 1980; McCarthy, Nobre, Bentin & Spencer, 1995; Nobre & McCarthy, 1995; Nobre, Allison, & McCarthy, 1994). These techniques are used primarily to map the cortical sites relevant for language processing before surgery in epileptic patients, and they involve injecting or recording electrical currents at precise locations, generally on the cortical surface. Results from these studies indicate that language-activated cortical regions are found not only in the classical language areas but also throughout the extent of prefrontal cortex and along the anterior part of the temporal lobe in the left hemisphere (Ojemann, 1991).

These studies have also generated a number of results that directly question the notion of a few, well-delineated language centers. For example, Ojemann (1988; 1991) has described the cortical surface locations at which naming is disrupted by electrical stimulation. These reports often show that the effect of disruption of naming by stimulation is localized within as little as 5 mm. These findings suggest that language-relevant cortical regions can be extremely patchy and focal. A similar pattern of organization has been observed from subdural implants whereby the signal observed at two adjacent electrode sites, separated by only a few millimeters, reveal a different functional specialization of the underlying cortex (Nobre et al., 1994; Nobre & McCarthy, 1995). Additionally, the comparison of the localization of language-related patches between subjects indicates that the distribution of these patches is variable from one subject to the other (Ojemann, 1991). The overall pattern of results suggests a cortical organization of language in small nonadjacent focal spots distributed throughout the left peri-sylvian cortex, rather than in a few large cortically well-circumscribed language centers. The interpretation of these results should of course be modulated by the facts that the data come exclusively from clinical populations that have chronic neural damage, that for the most part only the cortical surface has been mapped, and that in most studies only naming has been used to evaluate language skills. However, these data provide valuable evidence on the foundational hypotheses of the traditional view and raise new hypotheses about cerebral organization for language.

More recently the development of functional imaging techniques has enabled the assessment of brain organization for language in normal healthy volunteers. The ERP techniques permit a characterization of language activity with high temporal resolution and the spatial resolution of these techniques is improving (Neville,

1995; see special issue on ERPs in *Language and Cognitive Processes*, 8, 1993). Higher spatial resolution (but poorer temporal resolution) is afforded by the positron emission tomography (PET) and fMRI techniques. A number of PET studies of language processing have recently been reported. However, since most of the studies published to date have averaged brains across subjects before localizing the activation and, in addition, have considered extent of activation as an index of the strength of the activation, these studies are by design ill-suited to bring evidence on the hypothesis that the cortical language system is instantiated in small, separate focal patches of cortex. However, these studies provide valuable insights into the principal brain areas supporting language processing. Overall these studies confirm the participation of a number of classical language areas such as Broca's, Wernicke's, and the supramarginal gyrus and the supplementary motor area. They also support the proposal of additional language-related areas beyond the classical structures (Mazoyer et al., 1993; Petersen & Fiez, 1993). In particular, they suggest that the anterior extent of the left superior temporal gyrus and the left prefrontal cortex (specifically the dorsolateral prefrontal cortex) are active during language processing. Attributing an exact functional role to each region has proven more challenging, though, since studies designed to activate the same language process have led to the characterization of nonoverlapping areas, and conversely, a given area has sometimes been involved in different aspects of language (for reviews, see Demonet, Wise, & Frackowiak, 1993; Poeppel, 1996). As we have seen, this state of affairs is not specific to imaging studies but has also been repeatedly observed throughout the study of aphasia. Hence, although most language functions seem clearly organized within the left peri-sylvian region, no well-circumscribed region has yet been characterized as clearly related to a specific component of language.

There are two often-cited sources of our limitation in understanding the neural basis of language. The first one is "the coarseness of anatomical localization compared to the scale of the micro-circuitry that actually computes language" (Dronkers & Pinker, in press). Indeed, all the studies based on lesions had perforce to deal with gross anatomical alterations. Sophisticated computer techniques for normalization between the brains of different subjects are being developed and have already had a great impact on the field. It has, however, been argued that the process of anatomical standardization may obscure individual patterns of activation, render certain foci undetectable, and select only for widespread nonfocal activation (Poeppel, 1996; Steinmetz & Seitz, 1991). This argument is based on the observation that the large individual variations in cerebral sulci, brain size, and shape may result in a nonnegligible amount of smearing when anatomical standardization is performed. Hence, pooling together standardized brains may result in averaging together different anatomical regions across sub-

jects (Ss). While relying on individual anatomy to average across Ss avoids this latter problem, the areas considered are then much larger and the microstructure of the activation may be obscured. Hence, averaging based on standardization or anatomical localization may at present defeat any characterization of the functional-structural correspondences at a fine anatomical level. The assessment of the functional organization of the cortex has at present much to gain by being guided by the pattern of organization at the individual level. A number of investigators have already begun to define the area studied for each subject by its functional specificity and then average between Ss based on these functionally defined regions of interest. This technique ensures that comparable regions between Ss are averaged together by taking advantage of the high resolution of fMRI at the individual level (Tootell et al., 1995). Unfortunately, it requires pre-specified knowledge of some functional parameters that specifically activate the area studied. Such preexisting knowledge is not yet available for language-related areas, and so it is not yet possible to use individual data to guide between-Ss averaging in language studies. We think, however, that the characterization of the activation at the individual level is valuable in informing about the nature of the underlying cortical organization and in improving analyses techniques.

The second source of limitation when studying the neural basis of language comes from the selection of the task. The problem of task selection when studying language is not new. Traditionally, language functions of aphasic patients were tested by assessing language-related activities, such as speaking, listening, repeating, or naming. In the last 30 years, the number and type of language functions considered has increased as the methods for assessing language functions have built upon the work within linguistics and psycholinguistics (Blumstein, 1995; Caplan, 1995; Price et al., 1994; Zurif & Swinney, 1994; Special Issue, *Brain and Language*, 45, 1993; Special Issue, *Brain and Language*, 50, 1995). In particular, it has resulted in the breakdown of language into subcomponents including phonology, phonetics, syntax, semantics, and pragmatics. However, even simple tasks, hypothesized to index selectively particular aspects of language processing, often do not tap only one component of language processing but encompass a complex chain of processing. This renders the linguistic process we want to characterize and the various activities related to the task difficult to tease apart. Moreover, it has also been noted that constrained tasks, such as a purely phonetic task, are often highly unnatural and may encourage subjects to rely on strategies that are only remotely related to those at play during natural language processing (see Poeppel, 1996, for a discussion). For these reasons, a number of authors have argued for the use of tasks that are cognitively natural for the skill studied (Demonet et al., 1993; Poeppel, 1996). Sentence processing is commonly agreed to be a cognitively natu-

ral language task. It is clear that tasks that selectively identify a specific subcomponent of language processing are often bound to be unnatural since the different aspects of language are usually not processed separately. However, this problem is not specific to the field of the neurobiology of language. Experimental psycholinguistics has had to face the same shortcomings. Thus much may be gained from lesion and functional activation studies that have been guided by careful psycholinguistic and linguistic analyses of the tasks.

As a first step toward overcoming these sources of limitation when studying the neural basis of language, we conducted a sentence processing study using the fMRI technique. Although the comparison we used (sentence reading versus the viewing of consonant strings) does not permit the characterization of specific subcomponents of language processing, it has the advantage of using stimuli relatively natural for the subjects and stimuli for which underlying processes have been well characterized. Hence, sentence reading has been acknowledged to invoke many of the different aspects of language processing (orthography, phonology, syntax, semantics, and verbal short-term memory) as well as basic visual recognition routines. By contrast, the presentation of consonant strings is believed to activate only basic visual recognition routines similar to those that are triggered during the recognition of visual shapes. The comparison of these two conditions should reveal brain areas concerned with subroutines related to language processing, from orthographic coding to verbal short-term memory. The use of fMRI permitted the characterization of the pattern of activation in individual subjects. Unlike previous studies, this enabled us to directly test the hypothesis that language may be represented at the neural level within multiple small foci. In addition, the data were averaged across subjects so as to characterize the anatomical areas consistently active across the whole population. This provides a useful comparison to previous imaging studies of language.

Eight young, healthy, monolingual, right-handed subjects participated in the study. Each subject participated in two separate sessions, one for each hemisphere. Each session was comprised of three English runs and three control runs. The control runs consisted of a language subjects were not familiar with (American Sign Language, ASL). For each run, the stimuli were presented using an ABAB . . . design. Each AB cycle consisted of a 32-sec block of sentences (A condition) that alternated with a 32-sec block of baseline stimuli (B condition). The English runs consisted of written English sentences (A) alternating with consonant strings (B). The ASL runs consisted of a film of a native signer producing either ASL sentences (A) or nonsign gestures (B). Since none of the subjects were familiar with ASL, we hypothesized no reliable difference in activation between ASL sentences and nonsigns. To ensure attention, at the end of each run, subjects were presented with a set of sen-

tences and a set of consonant strings/nonsigns. Half of the recognition stimuli in each set had been presented before and half were new; subjects were to decide whether or not the stimuli had been presented in the run before. Order of language presentation and of hemisphere imaged were counterbalanced across subjects. No stimuli were ever repeated. The first two runs of each session were always very short and used as primers. Hence, there were four experimental runs: two for English and two for ASL. In the following, we will first report the behavioral data and then characterize the pattern of activity in individual subjects and finally the pattern of activity across subjects.

RESULTS

Behavioral Data

The percentage of correct recognition of previously seen versus new stimuli was scored for each of the experimental runs across subjects (see Table 1). A $2 \times 2 \times 2$ analysis of variance with language (English versus ASL), stimulus type (sentences versus consonant strings/nonsigns), and order of runs (first versus second) revealed main effects of language ($F(1,7) = 32, p < 0.001$) and of stimulus type ($F(1,7) = 43, p < 0.0001$). These effects establish that performance was more accurate for English than for ASL and for sentences than for consonant strings/nonsigns. Moreover, these last two factors interacted ($F(1,7) = 8, p < 0.028$) due to a larger effect of stimulus type in English than in ASL. Separate ANOVAS for English and ASL conditions were then performed. For English, a 2×2 ANOVA with stimulus type and run order as variables showed a main effect of stimulus type ($F(1,7) = 40, p < 0.0001$), confirming that subjects were more accurate on sentences than consonant strings. No other effects were significant ($ps > 0.08$). For American Sign Language, a 2×2 ANOVA with stimulus type and run order showed no significant effect. Hence, no effect of stimulus type was found, confirming that subjects were as inaccurate on ASL sentences as on nonsign gestures. These data show that for these native English speakers the task was easier for English sentences than for consonant strings. But for signs, these subjects, who did not know ASL, performed as poorly on the sentences as on the nonsign gestures. These results are consistent with ample evidence in the literature that

Table 1. Percentage of Correct Recognition as a Function of Stimulus Type and Language.

	<i>English</i>	<i>ASL</i>
Sentences	85	56
Nonstrings	51	50

meaningful stimuli are easier to encode and remember than unfamiliar, meaningless patterns (Craik & Lockhart, 1972).

fMRI Data: Individual Subjects

For each subject and for each run, the pattern of activation for each of the eight imaged slices was assessed by performing, on a voxel-by-voxel basis, a correlation between the time-series of activation of the voxel and a sine wave that modeled the alternations between sentences and consonant strings/nonsigns (see "Method" section for further details). This correlation map was then thresholded to retain only voxels whose activity over time correlated ($r > 0.5$, $p < 0.001$) with the stimulus alternation. An example of such a time-series is shown in Figure 1. Finally, the thresholded correlation map was overlaid over the corresponding structural MRI generating images such as the ones displayed in Figure 2, p. 669. Figure 2 presents the pattern of activation for reading English sentences in five individual subjects through a relatively lateral para-sagittal cut ($x =$ approximately -54 mm in Talairach coordinates (Talairach & Tournoux, 1988)). A gross comparison of the main anatomical traits of these brains confirm the large individual variability in shape and location of anatomical features across subjects. More revealing for our purpose, however, is the organization of the activation in each subject. The pattern of activation in each subject was characterized by several scattered small (2 to 3 voxels) patches. It is important to note that this pattern of activation is not due to the use of a high threshold that masks an underlying broadly distributed activation. Highly correlated voxels did not appear as the peaks of a broad area of

activation but were directly surrounded by voxels with low correlation values.

It is instructive to compare these data to those gathered during fMRI experiments using similar imaging parameters but employing nonlanguage sensory stimulation. Under these conditions, typically only a few large patches of activation are observed (Karni et al., 1995, for motor performance; Clark et al., 1996, for face processing; Tootell et al., 1995, for motion processing). Some subjects participating in the language experiment were also studied at the end of the session using a simple nonlanguage-related visual stimulation task. During the visual stimulation run, subjects viewed moving spirals that alternated with static spirals. We consistently observed a large posterior and lateral activation of at least 10 contiguous voxels or more for this contrast. Such results demonstrate that neither the details of the MRI protocol we used nor the analysis technique can account for the patchy activation we observe when comparing sentences to consonant strings. Moreover, the maximum percentages of signal change observed in the language and visual runs were comparable, suggesting that the patchiness of the activation was not due to a lack of sensitivity of the technique. Further research is required to determine whether the noted pattern of activation is a characteristic of the functional organization within the cortices active in our study (associative but not primary or secondary cortices) or whether it is specific to certain cognitive or control tasks.

Typically in our sentence reading experiment, on average 5 to 10% of the voxels within an anatomical region (e.g., Broca's area) were found to be active in a given run. A comparison of the distribution of activation across subjects reveals that while the foci of activation fell within the same broad anatomical areas for all subjects, there was a large variability in the exact distribution of the activation within a given anatomical area across subjects (Figure 2). Analyses of individual subjects also allowed us to assess the reliability, within subject, of the pattern of activation from one run to another similar but not identical run. For each subject, we computed the number of active voxels in the first run that were either active again or directly adjacent to an active voxel in the second run. The overlap from run to run was 69% for temporal regions (anterior, middle, and posterior sectors of the superior temporal sulcus) and 67% for inferior frontal structures (Broca and precentral sulcus, inferior part) but only 19% for frontal regions (frontal pole and orbito-frontal cortex). In general, areas that were reliably active in the between-Ss analysis (temporal regions, inferior frontal structures, and middle frontal) tended to show a higher percentage of within-Ss overlap. This makes statistical sense since the larger the area of activation, the greater the chances of overlap. It is, however, interesting to note that even for areas robustly active across Ss, the overlap of the activity from one run to another within the same Ss was not 100%, and could be

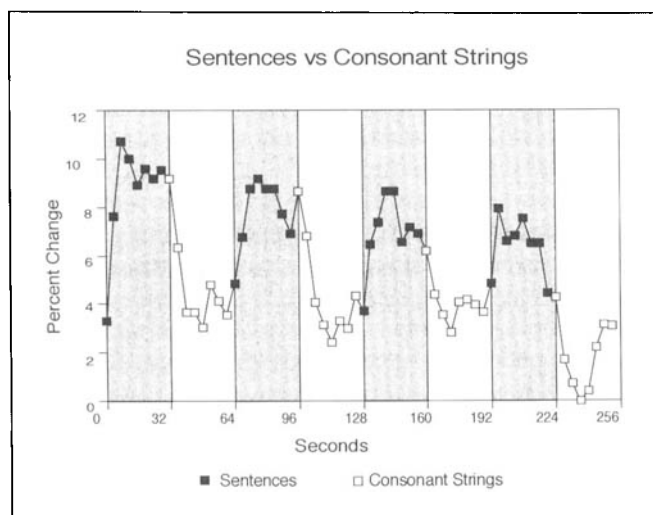


Figure 1. Example of a correlated time-series. Shaded areas correspond to the blocks during which subjects processed English sentences.

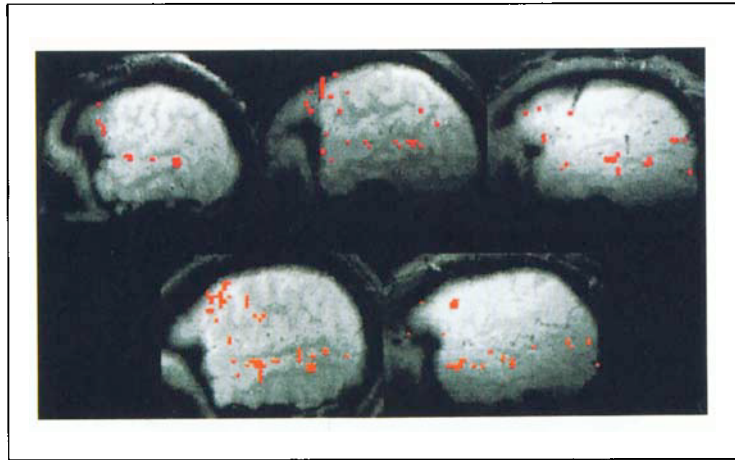


Figure 2. Individual activation for five subjects showing active voxels (overlaid on their corresponding structural MR scans). Note that with the MRI sequence used, the gray matter appears brighter than the white matter; this contrast is opposite to that obtained with a conventional T1 weighted MR image.

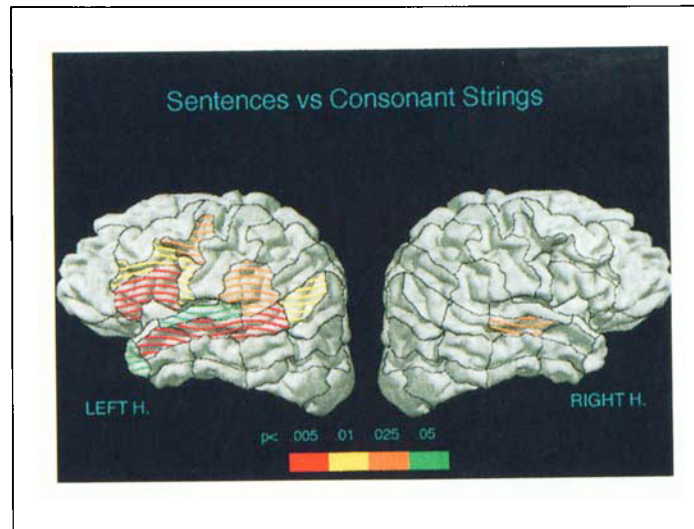


Figure 4. Schematic representation of the active areas during the processing of English sentences as revealed by the between-subject analysis. While the robustness of the activation is indicated by the coloring over the entire area (from red to green), it is important to remember that active voxels comprised only 5 to 10% of the spatial extent of an area.

Figure 6. Timing of the activation (in secs) for robustly active areas. Areas displayed on the left showed the smallest delay between the stimulus alternation and the MR signal. Areas with increasing delay are plotted from left to right.

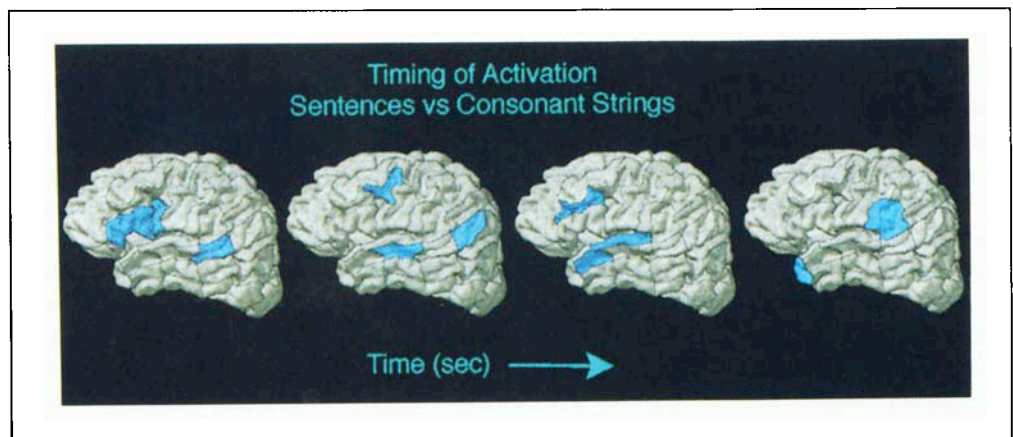


Figure 3. Anatomical regions considered shown on the lateral surface of a 3-D-reconstructed brain. See Table 2 abbreviation key.

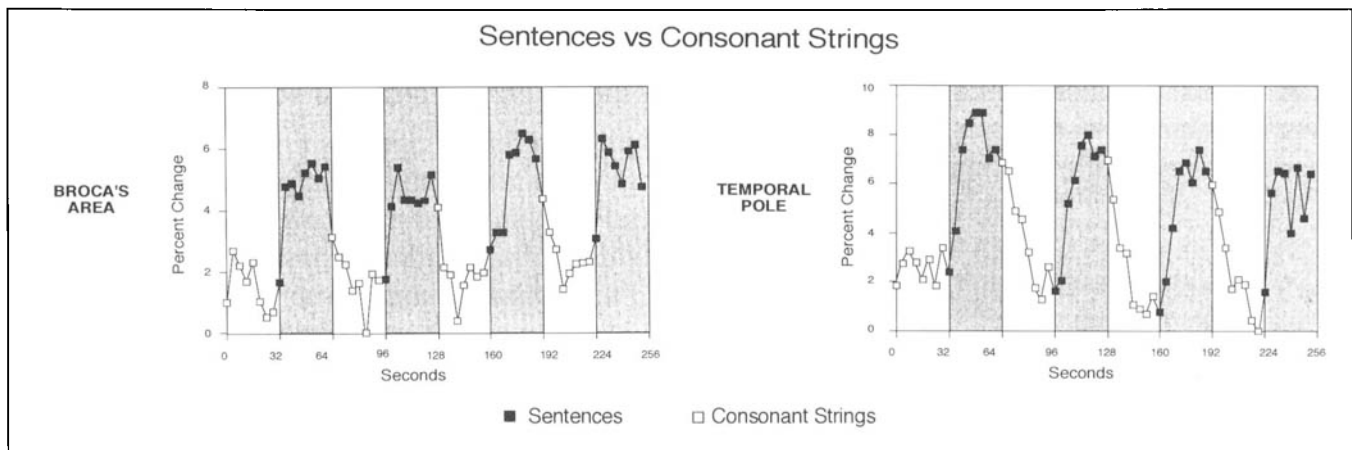
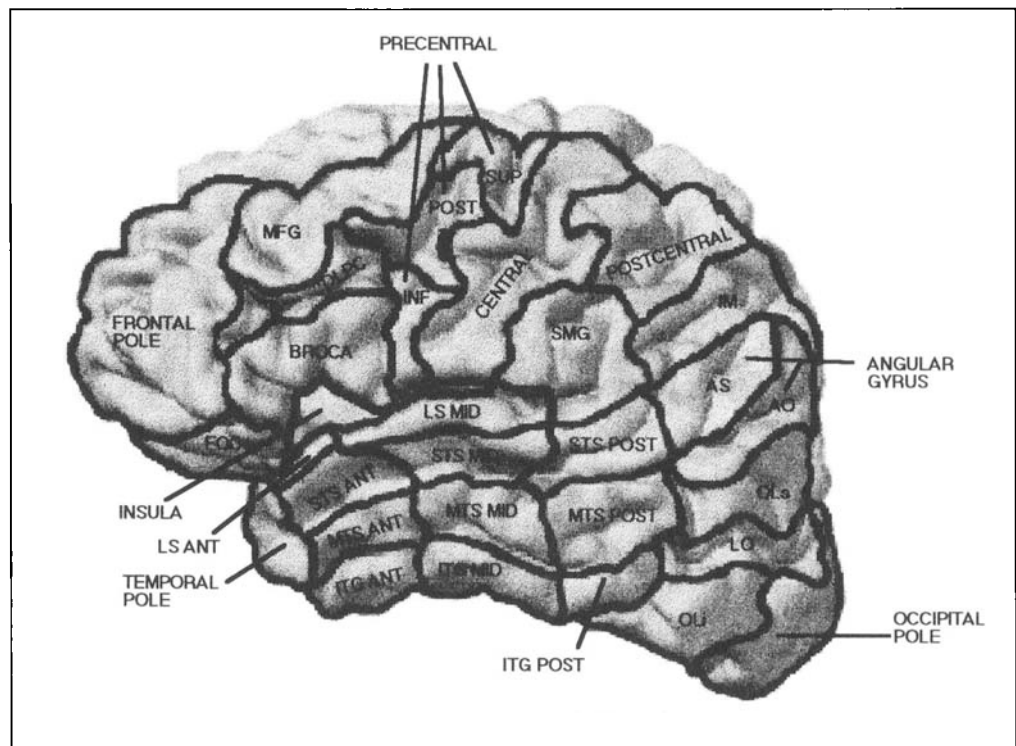


Figure 5. Examples of time-series for two active areas illustrating how activation increases with sentence processing and decreases with consonant strings. Shaded areas correspond to the English sentences blocks.

as low as 47% (in middle frontal structures such as the dorsolateral prefrontal cortex and precentral sulcus, superior part). To our knowledge, the sources of these variations over time are not well defined. There is, however, a growing literature that indicates that the functional recruitment of areas varies over time, as a function of the attentional state of the Ss (see O'Craven, Rosen, Kwong, Treisman, & Savoy, 1997) and/or the familiarity with the stimuli and the task (see Raichle, 1991; Raichle et al., 1994; Karni et al., 1995). As the resolution of imaging techniques increases, the study of intrasubject variability as a function of the cognitive state of the Ss

has been made possible and will be important for understanding the functional organization of the brain.

The effects of spatial filtering on such a distribution of activation deserves consideration (Forman et al., 1995; Friston, Worsley, Frackowiak, Mazziotta, & Evans, 1994; Poline & Mazoyer, 1993). The main motivation behind the use of spatial filtering is the assumption that activation is spatially correlated across contiguous voxels. In PET, in which different stages of data filtering are performed before extracting the activation map, this assumption is clearly valid. By contrast, it seems that the degree of spatial correlation is much less in fMRI (For-

Table 2. Key to the 31 Anatomical Regions Shown in Figure 3.

<i>Frontal</i>	
Middle frontal gyrus	MFG
Frontal pole	Frontal pole
Frontal orbital cortex	FOC
Dorsolateral prefrontal cortex	DLPC
Broca's area	Broca
Precentral sulcus, inferior part	Precentral inferior
Precentral sulcus, posterior part	Precentral posterior
Precentral sulcus, superior part	Precentral superior
Central sulcus	Central
<i>Temporal</i>	
Temporal pole	Temporal pole
Inferior temporal gyrus, ant. part	ITG ant.
Inferior temporal gyrus, mid. part	ITG mid.
Inferior temporal gyrus, post. part	ITG post.
Middle temporal sulcus, ant. part	MTS ant.
Middle temporal sulcus, mid. part	MTS mid.
Middle temporal sulcus, post. part	MTS post.
Superior temporal sulcus, ant. part	STS ant.
Superior temporal sulcus, mid. part	STS mid.
Superior temporal sulcus, post. part	STS post.
Lateral (sylvian) fissure, ant. part	LS ant.
Lateral (sylvian) fissure, mid. part	LS mid.
Insula	Insula
<i>Parietal</i>	
Supra-marginal gyrus	SMG
Angular sulcus	AS
Anterior occipital sulcus	AO
Postcentral sulcus	Postcentral
Intermediate sulcus of Jensen	IM
<i>Occipital</i>	
Superior occipital lateral gyrus	OLs
Lateral occipital sulcus	LO
Inferior occipital lateral gyrus	OLi
Occipital pole	Occipital pole

man et al., 1995). Since the fMRI technique does not induce sizeable spatial correlation between voxels, the use of spatial filtering in fMRI mainly emanates from the assumption that true neural activity will lead to hemodynamic changes over several contiguous voxels. Although this appears to have been the case for reports of sensory experiments, at the present time there is no a priori reason to believe that activation over contiguous voxels is a ubiquitous feature of neural activation. The voxel resolution at which our fMRI study was performed ($2.5 \times 2.5 \times 5$ mm) is extremely coarse compared to functional neuronal organization. Indeed, a basic unit of the mature cortex, the cortical column, is at most 900 μ m. Moreover, intracranial recording and stimulation studies have indicated that regions separated by just 1 mm or so can display different functional specializations (Ojemann, 1988; 1991; Nobre et al., 1994; Nobre & McCarthy, 1995). The pattern of data reported above for individual subjects suggests that even a few isolated voxels may reflect significant neural activity. For these reasons spatial filtering was not employed here. It is crucial, however, to guard against false positive probability. The reliability of our results was ensured by requiring a minimum number of active voxels within each area (independently of whether these active voxels are spatially contiguous or not) and a replicable pattern of data across sets and across subjects.

Individual subject's data in the present language study indicate that the activation is rather focal and variable across subjects. It is distributed throughout the left perisylvian cortex and is not restricted to classical language areas but extends into the left prefrontal areas and the left anterior temporal lobe. This pattern of findings supports the view of a cortical organization for language in a network of focal regions distributed throughout the left perisylvian cortex (Mazoyer et al., 1993; Mesulam, 1990; Mountcastle, 1995; Ojemann, 1991).

fMRI Data: Across Subject Averaging

Individual subject analysis permitted the characterization of the pattern of activation at a fine anatomical level; however, it is also important to assess the pattern of activation that best describes organization across subjects. This analysis is essential for the purpose of comparison with previous data from lesions and from imaging studies. Intersubject analyses were performed by relying on the subdivisions defined by anatomical regions. For each subject, anatomical regions were delineated by hand on each of the eight structural images collected (according to the anatomical divisions by Rademacher, Galaburda, Kennedy, Filipek, & Caviness, 1992). As illustrated in Figure 3 and Table 2, the anatomical subdivisions considered relied mostly on sulcal, rather than gyral, anatomy since distinguishing between the two banks of a sulcus was at times challenging in our data (see "Across-Subject Analysis" in the "Methods" sec-

tion). When the thresholded activation map was overlaid over its corresponding structural image, active voxels were readily classified according to the previously delineated anatomical region into which they fell. Eighteen of the thirty-one regions considered are listed in Table 3 along with their corresponding Brodmann area and their Talairach location (Brodmann, 1909; Talairach & Tournoux, 1988). The remaining 13 regions never showed reliable activation and so will not be discussed further.

A main multivariate analysis was performed with language (English versus ASL), hemisphere (left versus right), region (10 levels, see "Method" section), and order of runs (first versus second) as factors (see "Method" section). Main effects of language ($F(3, 1400) = 72.8, p < 0.00001$), of hemisphere ($F(3, 1400) = 25.2, p < 0.00001$), and of regions ($F(27, 4089) = 6.9, p < 0.00001$) indicated more activation for English than for American

Sign Language, more activation in the left than the right hemisphere, and greater activation for some anatomical regions than others, establishing regional specialization of the activation. Interactions between all of these three factors (language by hemisphere ($F(3, 1400) = 30.8, p < 0.00001$), language by regions ($F(27, 4089) = 5.5, p < 0.00001$), hemisphere by regions ($F(27, 4089) = 3.7, p < 0.00001$), as well as language by hemisphere by regions ($F(27, 4089) = 3.6, p < 0.00001$)) clearly established a different distribution of the activity across hemispheres and regions for each language. These results led us to analyze the English and the American Sign Language runs separately. Although a main effect of order of runs ($F(3, 1400) = 6.1, p < 0.0004$) revealed a stronger activation for the second run than the first one, order of run did not interact with any of the other factors ($ps > 0.45$) suggesting that this effect is shared across all conditions.

Table 3. Eighteen of the Anatomical Regions Imaged and Brodmann's Areas They Encompass.

<i>Areas</i>	<i>Brodmann</i>	<i>Talairach^a</i>
<i>Frontal</i>		
Middle frontal gyrus	46, 9, 8, 6	(-43, 25, 37)
Frontal pole	10, 11	(-43, 50, 0)
Dorsolateral prefrontal cortex	45, 46	(-47, 30, 20)
Broca	45, 44	(-47, 21, 9)
Precentral sulcus, inf.	44, 6	(-51, 4, 17)
Precentral sulcus, post.	44, 9 (6)	(-47, 6, 40)
Central sulcus	3, 4	(-47, -10, 45)
<i>Temporal</i>		
Temporal pole	38	(-51, 17, -17)
Superior temporal sulcus, ant.	21, 38	(-51, 8, -10)
Superior temporal sulcus, mid.	21, 22	(-51, -10, -2)
Superior temporal sulcus, post.	21, 22	(-51, -30, 5)
Sylvian fissure, ant.	38, 22	(-47, 12, -2)
Sylvian fissure, mid. (PP, H1)	22, 41 (43)	(-47, -10, 10)
<i>Parietal</i>		
Supra-marginal gyrus	40	(-55, -50, 37)
Angular sulcus	39	(-51, -60, 24)
Anterior occipital sulcus	37, 19	(-47, -65, 2)
Intermediate sulcus of Jensen	39, 40	(-47, -55, 37)
Postcentral sulcus	3, 2	(-47, -25, 45)

^a Talairach coordinates are given as examples of points typically comprised in this region.

Table 4. Written English Condition: Positively Correlated Activation^a

<i>Areas</i>	<i>Left H. act.</i>	<i>Right H. act.</i>	<i>Act. × hemi.</i>
<i>Frontal</i>			
Middle frontal gyrus	.43	1.0	.29
Frontal pole	.16	.27	.19
Dorsolateral prefrontal cortex	.0064	.42	.044
Broca	.0016	.09	.0049
Precentral sulcus, inf.	.0064	.09	.0058
Precentral sulcus, post.	.018	.27	.037
Central sulcus	.09	.27	.73
<i>Temporal</i>			
Temporal pole	.044	.42	.14
Superior temporal sulcus, ant.	.0016	.09	.015
Superior temporal sulcus, mid.	.0016	.023	.07
Superior temporal sulcus, post.	.0001	.27	.0006
Sylvian fissure, ant.	.09	.27	.32
Sylvian fissure, mid. (PP, H1)	.044	.27	.42
<i>Parietal</i>			
Supramarginal gyrus	.018	.16	.24
Angular sulcus	.0064	1.0	.0003
Anterior occipital sulcus	.09	.16	.24
Intermediate sulcus of Jensen	1.0	1.0	1.0
Postcentral sulcus	1.0	1.0	.36

^a Results of the multivariate analyses of variance carried out for each anatomical region in each hemisphere (Left H. act. = left hemisphere activation; Right H. act. = right hemisphere activation). Results from the between-hemisphere analyses are also reported and index the degree of lateralization of the activation (Act. × Hemi. = activation by hemisphere effect).

Pattern of Results for Written English

A multivariate analysis with hemisphere, region, and order of runs as factors revealed main effects of hemisphere ($F(3, 686) = 31.9, p < 0.00001$) and of regions ($F(27, 2004) = 6.7, p < 0.00001$). A robust interaction between hemisphere and region was observed ($F(27, 2004) = 3.7, p < 0.00001$); none of the other effects reached significance ($ps > 0.15$). These results indicate, in accordance with previous research, a stronger activity in the left hemisphere than the right, as well as regional specializations specific to each hemisphere. Accordingly, the level of activity in each of the 31 anatomical regions considered in each hemisphere was tested by performing separate multivariate analyses. In order to assess the degree of lateralization of the activation in each region, a between-hemisphere analysis was also performed. The

main results of these analyses are summarized in Table 4 and displayed in Figure 4, p. 669. Figure 5 illustrates the pattern of activation over time as a function of the conditions alternation for two active regions.

Left Hemisphere. In the left hemisphere, active areas include three main categories of anatomical regions: regions classically thought of as language areas, regions recently hypothesized to participate in language processing, and one region not predicted to be language relevant on the basis of previous work.

Active regions include those that have been classically thought of as language centers, such as Broca's area (Broca and inferior precentral sulcus), Wernicke's area (posterior superior temporal sulcus, supramarginal gyrus), and the angular gyral region (angular sulcus and anterior occipital sulcus). Since each of these regions has

been classically associated with language functions, their participation in the present study is not surprising. However, their exact function and the extent of their role in linguistic processing is still the subject of much debate.

BROCA'S AREA. While Broca's area was initially thought of as the center of language production, it has also been proposed to support some aspects of syntactic processing. As of today, two principal roles are still associated with Broca's area: syntactic processing and verbal short-term memory. There is a wealth of data showing that Broca's aphasics have subtle alterations of their syntactic skills, leading to the characterization of Broca's aphasics as "agrammatical" (Zurif, Caramazza, & Meyerson, 1972; Zurif & Swinney, 1994; Special Issue, *Brain and Language*, 45, 1993). However, this characterization is currently debated (Braver et al., 1997; Dronkers, Shapiro, Redfern, & Knight, 1992; Frackowiak, 1994; Menn & Obler, 1990; Stromswold, Caplan, Alpert, & Rauch, 1996).

Although Broca's area was active in our experiment, it is interesting to note that the inferior portion of the precentral sulcus, a neighboring but separate anatomical region, was also active. This region is sufficiently near to Broca's area to be encompassed in lesions or imaging studies that used brain normalization. It may be argued that activation of the inferior portion of the precentral sulcus corresponds to the motor planning of articulatory movements that would be consistent with the representation of the mouth/face at this location. However, subjects in our experiments were asked to read silently and were effectively restrained from moving; moreover, we have found this area to be activated when deaf subjects process ASL, a visuo-manual language (Neville et al., 1995), suggesting it is not directly tied to the motor mouth representation. Previous imaging studies have indicated the participation of premotor areas (Corbetta, Miezin, Dobmeyer, Shulman, & Petersen, 1991; Petersen, Fox, Posner, Mintun, & Raichle, 1988; 1989; Rueckert et al., 1994), and it has been proposed that activation of that region is related to efficient response selection (Petersen & Fiez, 1993). However, given the experimental design in the present study, in which no specific response selection was required at the time of stimulus presentation, this account seems unlikely.

WERNICKE'S AREA. Wernicke's area (including the posterior part of the superior temporal gyrus and the supramarginal gyrus) has been hypothesized to be the locus of several separate linguistic components. While it is believed to support some aspects of speech perception, it has also been viewed either as the center of phonological processing or as a word lexicon. The view that Wernicke's area supports some aspects of speech perception is consistent with the classical comprehension deficit shown by Wernicke's aphasic patients, and this notion has also been supported by several PET findings.

Studies requiring the discrimination of word sounds or the processing of auditory speech, whether foreign or familiar, indicate activation in Wernicke's area (Demonet et al., 1992; Mazoyer et al., 1993; Paulesu, Frith, & Frackowiak, 1993; Sergent, Zuck, Levesque, & MacDonald, 1992).

There is much debate, however, about which aspects of speech processing Wernicke's area is responsible for. The finding of Wernicke's activation when the task requires phonological processing of visually presented stimuli but not when it requires semantic association of similar stimuli has led some authors to propose that activation of Wernicke's area is linked to auditory or phonological processing and to short-term storage (see Petersen & Fiez, 1993, p. 521). Alternatively, the modulation of activation in Wernicke's area as a function of task demands has led other authors to propose that this area is part of a neural network that makes up the semantic system, such as a lexicon for written and spoken words (Howard et al., 1992; Friston, Frith, Liddle, & Frackowiak, 1991; Wise, Chollet, et al., 1991; Wise, Hadar, Howard, & Patterson, 1991). Either or both of these proposals could account for the pattern of data we report; indeed the Wernicke's activation we observe could be due to either phonological recoding and short-term memory storage or contact with the written word lexicon. However, note that there are two main regions of activation that have been considered as Wernicke's area. The first includes the posterior two-thirds of the superior temporal sulcus (STS); activation of this area was extremely robust across subjects. The second area is the supramarginal gyrus and the adjacent posterior portion of the sylvian fissure. In our study, the activation in this area was more diffuse and variable across subjects. Although these two areas are often grouped together, it is not clear that they are responsible for similar functions.

ANGULAR GYRUS. The activation of the angular gyrus (in particular, the angular sulcus) in the reading task we present is consistent with the extensive documentation of its role in the comprehension of written language in the clinical neuropsychological literature. This result, however, contrasts with the lack of evidence from PET studies for activation of this region during written word processing (see Black & Behrmann, 1994, for a review). Perhaps the effort required to read sentences rather than single words is important in activating this region.

Results from our experiment also indicate regions whose participation in the language system has only been recently hypothesized. These regions include the whole extent of the STS as well as part of the prefrontal cortex (dorsolateral prefrontal cortex and adjacent portions of the precentral sulcus).

SUPERIOR TEMPORAL REGION. Although the role of the posterior two-thirds of the temporal lobe in language proc-

essing was highlighted by Wernicke and others, it is only recently that the anterior and middle portion of the superior temporal region have been considered as potential neural substrates for language processing. Evidence for this participation comes from multiple sources. The study of patients with damage to the left anterior temporal region indicates that this region plays a major role in verbal learning and verbal memory (Milner, 1971). These patients show impoverished recall of stories but intact comprehension and good working memory capacity (Frisk & Milner, 1990). Electrical mapping of the cortical surface of the temporal lobe in epileptic patients (Haglund, Berger, Shamseldin, Lettich, & Ojemann, 1994; Ojemann, 1991) also reveals that language sites, as tested by naming disruption, are not restricted to the posterior two-thirds of the gyrus but are often found in the mid and anterior portion of the superior temporal gyrus. The analysis of patients who have difficulty naming objects has also led some authors to propose that the whole extent of the superior and middle temporal cortex acts as a noun lexicon (Damasio & Damasio, 1992). More recently, Dronkers, Wilkins, Van Valin, Redfern, and Jaeger (1994) have reanalyzed the lesions of patients with a severe disruption of morphosyntactic comprehension. They found that all of these patients had lesions in the anterior portion of the superior temporal gyrus (in the anterior portion of area 22, which would correspond to our anterior and mid STS, as well as mid lateral sulcus, suggesting that part of this region may also participate in syntactic processing). Finally, in a PET study, Mazoyer et al. (1993) found a significant asymmetrical activation of the anterior portion of the superior temporal gyrus when subjects were listening to meaningful stories in French but not to lists of unrelated words. These authors hypothesized that this area may be related to not only memory for the linguistic content of the stimuli but also syntactic parsing or prosodic analysis.

Thus, the studies available to date suggest at least three linguistic functions for the middle and anterior portion of the superior/middle temporal region: verbal memory, semantic processing, and syntactic analysis. In the context of previous research, it seems plausible to hypothesize that there is some degree of functional specialization within the temporal lobe. Deep temporal structures are known to mediate the formation of memory and have been hypothesized to participate in the encoding of verbal memory. Such regions (limbic system) are medial to the structures imaged in our experiment and so will not be discussed further. A number of results suggest that semantic processing may be mediated mainly through middle temporal structures, while syntactic analysis is more confined to anterior temporal structures. Mazoyer et al. (1993), for example, report activation of middle temporal structures for meaningful stories but not for pseudoword sentences and semantically anomalous sentences. This same area is also weakly

activated during the presentation of isolated words consistent with the idea that it is involved in conceptual processing and most reliably recruited when conceptual relationships between the words need to be computed (Price, Wise, & Frackowiak, 1996; Mazoyer et al., 1993). By contrast, in the Mazoyer et al. study (1993), the anterior temporal regions were found to be active for any sentential material: meaningful stories but also pseudo-word sentences and semantically anomalous sentences. The specificity of this area for aspects of language processing unique to sentences seems quite strong. A recent PET study by Price et al. (1996), most comparable to the present study, contrasted word and consonant string processing. The middle/inferior temporal junction was found to be more active for words than for consonant strings, but no reliable activity was observed in the anterior half of the temporal lobe. This result directly contrasts with the reliable recruitment of this area in the present study which compared sentences to consonant strings processing. Over all the studies of isolated word processing, the anterior and middle temporal areas have not emerged as reliably active areas. This contrasts with the robust recruitment of these areas in this and other studies employing sentences. (The discussion of existing PET data is, however, constrained by the fact that the anterior portion of the temporal lobe was not always included in the analysis process.) Additional research is certainly needed to specify the linguistic functions of the temporal areas, but it seems plausible at present to hypothesize that the anterior and middle portions of the STS participate in syntactic and semantic analysis of sentential material, respectively. Additionally, in this study, the timing of the activation along the superior temporal sulcus provides some suggestions that activation proceeds along the STS from posterior to anterior areas (see Figure 6, p. 669). The raw fMRI signal consists of a varying signal over time; by averaging the time-series across all the voxels of one area, the temporal profile of the activation for that area can be estimated and compared to that observed in other areas (see "Temporal Characteristics of the Activation" in the "Method" section). In particular, whether activity peaks at the same time or with a lag from one region to another can be computed. This timing information may reflect, and thus provide an estimate of, the relative timing of the neural activity between areas. Here activation occurred fastest in the posterior part of the STS, followed by the mid and then anterior portion of the STS and finally the temporal pole. This result would be consistent with a posterior to anterior spreading of the activation along the STS, and it reinforces the hypothesis of functional specialization within the temporal lobe. Of course, an interpretation of the timing differences of the fMRI signal has to be cautioned by the fact that the time resolution of the fMRI signal is gross (on the order of seconds), that it does not follow the neural activity in real time, and that

it may also reflect differences in microvasculature between brain areas.

PREFRONTAL CORTEX. Another region that has been recently hypothesized to participate in language processing is the prefrontal cortex and in particular the dorsolateral prefrontal cortex (DLPC). Electrical stimulation studies, for example, not only confirm that the inferior frontal gyrus or Broca's area participates in some aspects of language but also indicate language sites in the middle and superior frontal regions. In particular, language-relevant sites are more numerous in portions of the middle frontal gyrus (Ojemann, 1992). The DLPC has also been implicated in several PET studies. Petersen et al. (1988) first reported participation of this area when subjects had to produce the verb corresponding to an action (verb generation task). Since then DLPC participation has been observed in a wide range of conditions, such as verb generation tasks for auditory or written stimuli (Petersen et al., 1988; 1989) and reading real words using pseudowords as a baseline (Petersen, Fox, Snyder, & Raichle, 1990). These results have led some authors to propose that the DLPC is active during processing of semantic associations. However, the finding that the DLPC activation disappears when the task used is overlearned (Raichle et al., 1994) has led to the proposal that the DLPC is responsible for the modulation of activation within related structures such as Wernicke's area (Friston et al., 1991; Frith, Friston, Liddle, & Frackowiak, 1991). Whether the DLPC is best described as the locus of semantic processing or as a modulator during semantic processing, its activation in our study is consistent with previous data. It is interesting to note that the relative timing of the activation suggests that activation occurs first in Broca's area and the inferior portion of the precentral sulcus and then in the DLPC (see Figure 6). The difference in relative timing between the inferior frontal areas and the DLPC supports the view that the nature of the processing differs in these regions.

Right Hemisphere. Analyses of the right hemisphere indicate robust activation only in the mid portion of the STS. Analysis of the timing of the activation revealed that it was similar to that of the anterior portion of the lateral sulcus within the left hemisphere; hence activation in the right hemisphere seems to take time to develop. The role of the right hemisphere in language has not been extensively assessed, but it is known from split-brain subjects and from lesioned patients that the right hemisphere is capable of or even specialized for certain aspects of language processing, including affective aspects (Black & Behrmann, 1994; Gardner, Ling, Flamm, & Silvermoon, 1975; Searleman, 1983; Zaidel, 1990). Its role in linguistic processing is more controversial. The available studies suggest that the right hemisphere has quite a limited capacity for phonetic and syntactic processing, but good capacity for lexical access (Gazzaniga, 1983; Zaidel, 1990).

Recent imaging studies also suggest a participation of right hemisphere structures, in particular the right STS in language processing (Mazoyer et al., 1993; Paulesu et al., 1993). Interestingly, this same region in the left hemisphere is believed to be specialized for lexical processing; hence activation of this area in the right hemisphere may be related to the lexical capacities of the right hemisphere.

Activation Asymmetries. Overall activation was more robust in the left than right hemisphere, and some regions in particular showed more lateralization than others. Posterior temporal and temporo-parietal regions when active were clearly lateralized to the left hemisphere (STS and the angular sulcus) as well as the inferior and mid prefrontal regions.

Negative Correlations. Negative correlations correspond to voxels whose activation followed the stimulus alternation but showed a decrease of activation for sentences relative to consonant strings. Examples of negatively correlated time-series are displayed in Figure 7. A main MANOVA of negatively correlated voxels with hemisphere, regions, and order of runs as factors revealed only a main effect of run order ($F(3, 686) = 3.37$, $p < 0.018$) and a main effect of regions ($F(27, 2004) = 3.9$, $p < 0.00001$; all other $ps > 0.5$). Hence, in contrast to the positively correlated activation, the negative activation was not lateralized to the left hemisphere but was bilateral. Analyses for each anatomical region of negatively correlated voxels are summarized in Table 5 and displayed in Figure 8 on p. 679. Active regions include superior frontal structures, the left central sulcus, and the parietal lobe. It is interesting to note that no negative activation is observed in the areas where we observed robust positive activation (i.e., the inferior frontal areas, the extent of the STS, and the angular gyrus in the left hemisphere). In a recent PET study, Price et al. (1996) compared words and consonant strings processing while subjects performed a feature detection task. Interestingly, they also reported little overlap between areas positively correlated (word-consonant string) and areas negatively correlated (consonant string-word).

The correct interpretation of negatively correlated activation is unknown at present; however, there are a number of potential explanations that are of interest to consider. The little amount of overlap between positively and negatively correlated areas suggests that they may be involved in different cognitive processes. While positively correlated activation is hypothesized to reveal areas that support sentence processing, negatively correlated activation may correspond to areas that are more engaged during the processing of consonant strings than sentences. An alternative account is that the negatively correlated activation indexes redistribution of blood supply throughout the brain (either due to a passive redistribution or related to active inhibition of negatively

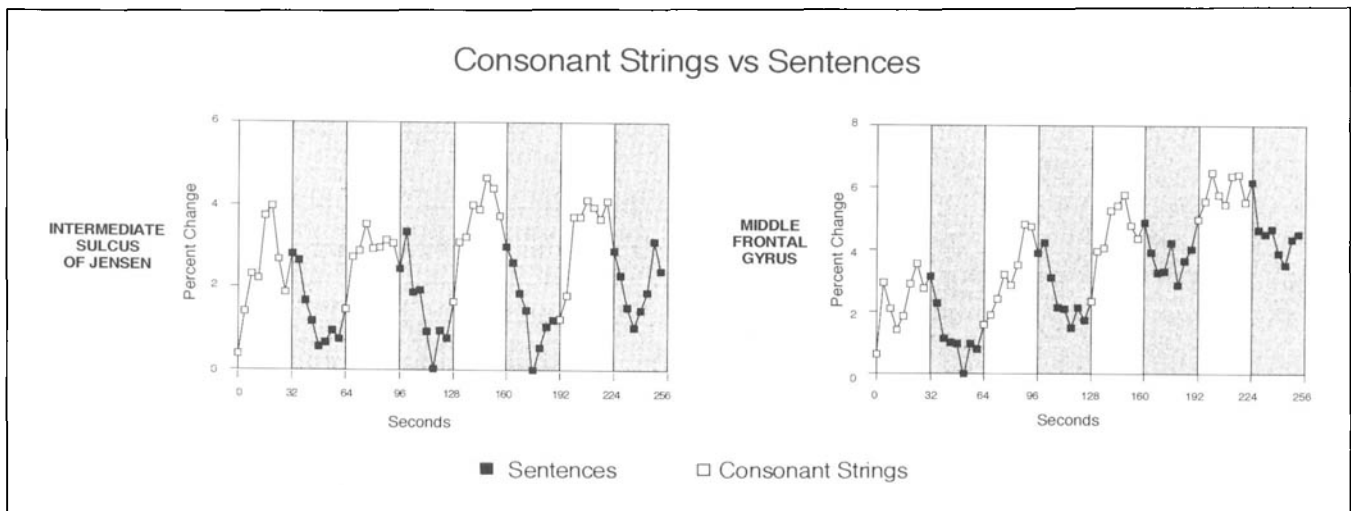


Figure 7. Examples of negatively correlated time-series for two active areas illustrating how activation increases with consonant strings and decreases with sentence processing. Shaded areas correspond to the English sentences blocks.

correlated areas by positively correlated areas) (see Clark et al., 1996, for a similar proposal). It is interesting to note that similar negative changes have been reported in the PET literature (Fiez et al. 1995; Haxby et al., 1991; Haxby et al., 1994). Fiez et al. (1995), for example, reported that negative changes occurred primarily in the central sulcus and parietal cortex when comparing a fixation task to a difficult auditory task. They proposed that these decreases may reflect an attentional shift from a spatial task (the fixation task) to a nonspatial task (auditory task) or alternatively an active inhibition of areas important for visual-spatial processing during a nonspatial auditory task. Interestingly, a large number of the negatively correlated areas we observed are also located in the central sulcus and the parietal lobe (postcentral and intermediate sulcus of Jensen), although our study did not involve the comparison between a visuospatial task and a non-visuospatial task. This pattern of activation may, however, reflect the greater recruitment of visual attention processes during consonant string than sentence processing. It will be important for future work to disentangle the hypothesis of active inhibition of task-irrelevant areas by task-relevant areas from the one of a more robust activation for the control task. The complete understanding of negatively correlated activation or negative changes will also require further exploration of the link between a neurally active area and its hemodynamic response as well as its consequences on the hemodynamic response of other brain areas.

Pattern of Results for American Sign Language

A main multivariate analysis with hemisphere, region, and order of runs as factors revealed an effect of run order ($F(3, 712) = 6.5, p < 0.0003$) due to a larger

activation in the second than the first run. None of the other effects reached significance ($p > 0.5$). For the purpose of comparison with the pattern of activation during English processing, for each hemisphere the level of activity in each of the 31 anatomical areas considered was assessed. No area was robustly active ($ps > 0.4$).

This pattern of results stands in sharp contrast to that observed in the same subjects when reading English. The absence of robust activation confirms the validity of our analysis technique. Indeed, we did not expect to find any linguistically relevant areas to be active during the ASL runs. These subjects were not familiar with ASL, and their behavioral performance clearly indicates that processing ASL sentences was as difficult for them as was processing nonsigns.

GENERAL DISCUSSION

Our study establishes that when right-handed monolingual native English speakers read English as compared to consonant strings, a limited set of anatomical areas becomes active. In the left hemisphere, the traditional language areas such as Broca's, Wernicke's, and the angular gyrus are active as well as the anterior extent of the superior temporal region and the dorsolateral prefrontal cortex. By contrast, robust activation was only observed in the mid portion of the superior temporal sulcus in the right hemisphere. The same subjects, who were not familiar with American Sign Language, did not show any robust activation when presented with alternations of signed sentences and pseudosigns, confirming the robustness of our analysis technique.

The different aspects of the activation reported in this study reveal several important points about cortical organization for language. The study of activation within subjects indicated activation in several small, local, and

Table 5. Written English Condition: Negatively Correlated Activation^a

<i>Areas</i>	<i>Left H. act.</i>	<i>Right H. act.</i>	<i>Act. × hemi.</i>
<i>Frontal</i>			
Middle frontal gyrus	.09	.0034	.66
Frontal pole	.044	.023	.9
Dorsolateral prefrontal cortex	.16	.023	.66
Broca	1.0	.16	.31
Precentral sulcus, inf.	.43	.049	.22
Precentral sulcus, post.	.09	.049	.22
Central sulcus	.018	.09	.45
<i>Temporal</i>			
Temporal pole	.09	.27	.19
Superior temporal sulcus, ant.	1.0	1.0	.39
Superior temporal sulcus, mid.	1.0	1.0	.63
Superior temporal sulcus, post.	1.0	1.0	.45
Sylvian fissure, ant.	.27	.09	.49
Sylvian fissure, mid. (PP, H1)	1.0	.42	.52
<i>Parietal</i>			
Supramarginal gyrus	.044	.32	.16
Angular sulcus	.16	.045	.2
Anterior occipital sulcus	.43	.034	.41
Intermediate sulcus of Jensen	.09	.0004	.53
Postcentral sulcus	.018	.0098	.89

^a Results of the multivariate analyses of variance carried out for each anatomical region in each hemisphere for negatively correlated activation (Left H. act. = left hemisphere activation; Right H. act. = right hemisphere activation). Results from the between-hemisphere analyses are also reported and index the degree of lateralization of the activation (Act. × Hemi. = activation by hemisphere effect).

distributed patches of cortex. This finding supports recent proposals of a cortical organization for language in a network of focal areas distributed throughout the left peri-sylvian cortex, rather than in a few cortically well-circumscribed areas. These findings demonstrate that the fMRI technique can resolve small and parcellated activity patterns that may be a key to the understanding of cerebral brain organization for higher cognitive functions, such as language. Future research will have to identify and characterize these various networks of focal areas (see Friston et al., 1991; McIntosh et al., 1994, for such an approach).

The comparison of individual patterns of activation across subjects revealed a surprisingly large variability of the functional to anatomical mapping from one subject to the other. While Broca's area was recruited for every

subject, the fine localization of the activation with respect to the main sulci that characterizes this structure varied significantly between subjects. Other reports in the literature are consistent with this observation. For example, Sereno et al. (1995) mapped the fine functional organization of the primary visual cortices in different subjects. While the general pattern of functional organization was similar across subjects, the relationships between known anatomical landmarks and the functional organization were quite variable from one subject to the other. The ability to observe interindividual variability reveals the exquisite sensitivity of the fMRI technique. Although this variability challenges the standard view of a robust mapping between anatomy and function, we think that its observation in studies like ours, which examine a subtle cognitive contrast, opens exciting

Figure 8. Pattern of active areas for negatively correlated activation as revealed by the between-subject analysis.

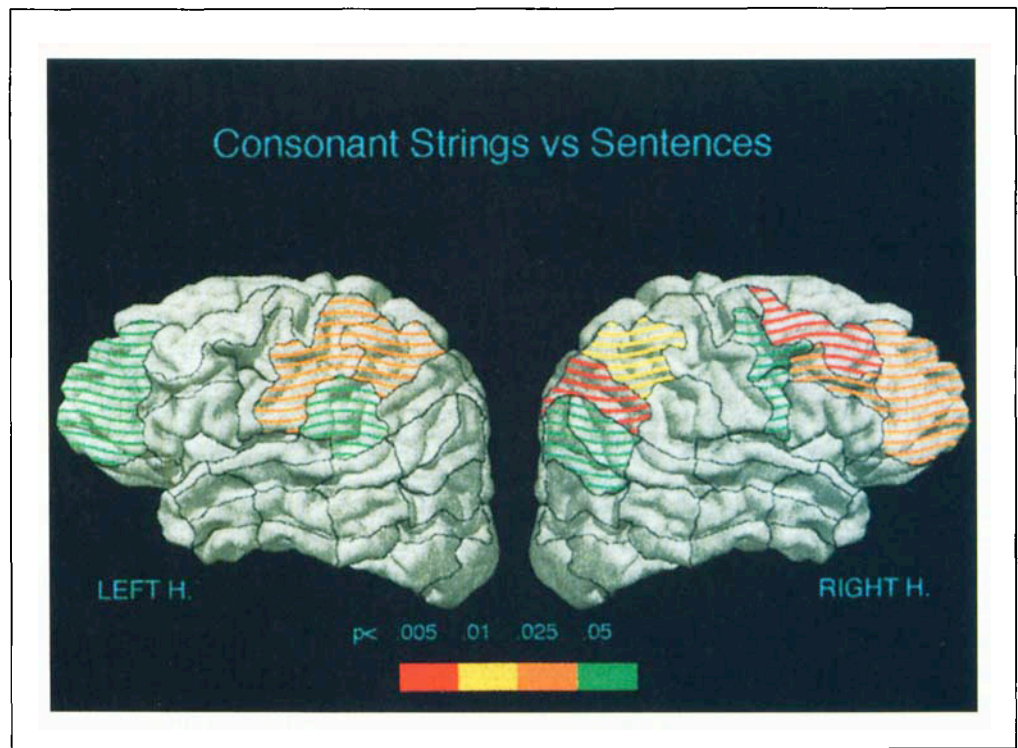
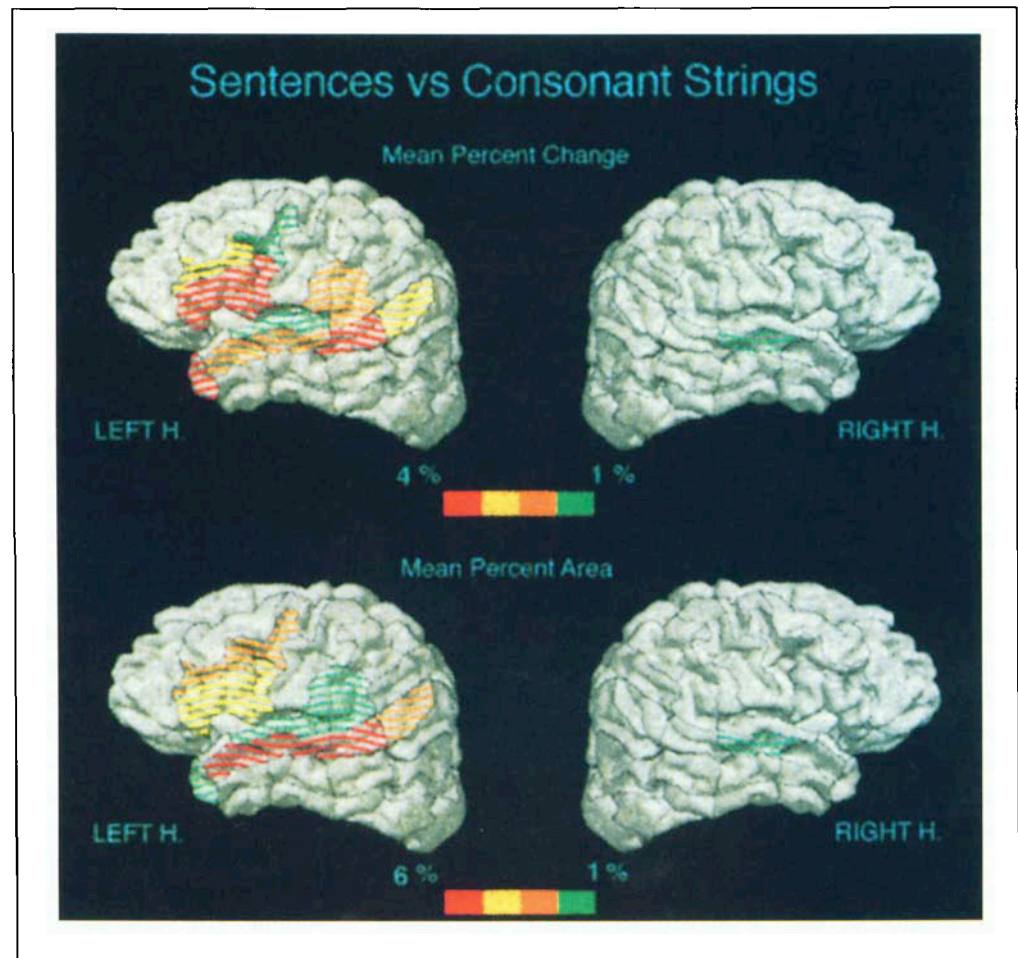


Figure 9. Measures across subjects for active areas: (a) Mean percentage change (from greater than 1% in green to 4% and larger in red); (b) mean percentage area (from greater than 1% in green to 6% and larger in red).



possibilities for future research. Indeed, as a number of investigators have begun to show for sensory functions, it indicates that one will be able to monitor the fine structure of functional changes as a subject's experience, familiarity, or attentional demands for a cognitive task are modified.

This study also points to several new areas of interest within the imaging literature. First, this study was run in a 4 Tesla field. The observation that some of the most robustly active areas displayed a percentage change of the order of 2% raises the possibility that some of the activation we reported may be barely detectable at lower fields (Turner et al., 1993). Reports by Small, Noll, Perfetti, and Schneider (1995) and Just, Carpenter, Keller, Eddy, and Thulborn (1996) of activation in the posterior portion of the superior temporal region in a sentence reading task at 1.5T is encouraging. However, whether the full pattern of organization we describe can be observed at lower fields awaits future investigations. In particular, it is worth emphasizing that the present study is one of the few studies in the literature to address the question of the cerebral organization for a language comprehension task. In general activation during comprehension tasks is much weaker (in percentage change and extent) than activation observed during production tasks such as naming or verb generation, paradigms most commonly described in the literature. Secondly, our design allowed us to use time-series analysis techniques to detect the activation (Bandettini, 1993; Bandettini, Jesmanowicz, Wong, & Hyde, 1993; Binder & Rao, 1994; Friston, Jezzard, & Turner, 1994). This technique has several advantages; in particular, it enabled us to gather information about the time course of the activation. This temporal information is unique to fMRI and gives a window into the dynamics of the processing; it may eventually make it possible to distinguish the varied neural processes engaged by a task, based on their different time courses. Hence, it will be important for future research to address the extent to which timing differences reflect different functional specializations or different physiological properties of tissues. The availability of temporal information in fMRI data will be an invaluable tool to further assess the functional connectivity during specific cognitive tasks.

Finally, a distinctive feature of this study was the use of sentences rather than isolated words. While both words and sentences engage lexical analysis, aspects of syntactic and semantic analysis are unique to sentences. The observed pattern of activation between subjects highlights the role of anterior temporal areas in sentence processing. This area has been seldom associated with language processing in neuropsychological studies of language processing. Similarly, most recent imaging studies of language processing bear little or no mention of this structure. However, this lack of report fits well with the hypothesized role of this area in language processing

(Dronkers et al., 1994). If this area is indeed essential in mediating aspects of syntactic processing, it is unlikely to have been recruited in imaging studies that focused on single-word processing. Furthermore, although cases with lesions to anterior temporal areas are found in the neuropsychological literature, they are likely to have been classified either as Broca's aphasics when the lesions extended to the superior areas of the brain or as deficits in verbal short-term memory in cases where the lesions were more focused in the temporal lobe (Milner, 1971). Our results reinforce the view that a closer investigation of the anterior part of the STS in language processing should be a fruitful area of investigation. This study presents one of the first comprehensive investigations of the neurobiology of sentence processing employing a technique that permits insight into both group and individual patterns of cortical activation. Although it will be important for future research to tease apart the various aspects of sentence processing that contributed to the pattern of activation described in this paper, this study already suggests that anterior temporal areas may be more specialized for syntactic/semantic aspects of language processing than for lexical aspects of language processing.

METHOD

Subjects

A total of eight subjects (four females, four males) were run. The subjects were healthy, young adults (range = 23 to 31 years old). They were right-handed, monolinguals, and native speakers of English. None of the subjects was familiar with American Sign Language. Data from each hemisphere were acquired in two separate sessions. Subjects were paid for their participation.

MRI Characteristics

Gradient-echo echo-planar images were obtained using a 4T whole body MR system, fitted with a removable z-axis head gradient coil (Turner et al., 1993), and driven by an Omega console (Bruker, Fremont, CA). Eight sagittal slices were collected during each TR interval of 4 sec. with in-plane resolution of 2.5×2.5 mm and slice thickness of 5 mm. Each experimental run of 64 images per slice thus lasted 256 sec. Contiguous slices were obtained, positioned from the lateral surface of the brain to a depth of 40 mm. The echo time (TE) was 28 msec, giving a range of BOLD contrast intensities from 2 to 15% depending on the areas and subjects studied. For each of the subjects, only one hemisphere was imaged in a given session since a 20-cm diameter transmit/receive radio-frequency surface coil was used, giving adequate signal-to-noise ratio only as deep as the brain midline. The subjects' heads were immobilized by care-

fully placed foam pads. At the beginning and end of each run, high-resolution gradient-echo GRASS reference scans that corresponded to the EPI slices were obtained (TR 200 msec, TE 10 msec, flip angle 15°). These reference scans gave good gray/white/cerebro-spinal-fluid (CSF) contrast and permitted identification of activated areas in relation to sulcal anatomy.

Stimulus Material

The written English stimuli consisted of short declarative English sentences (mean length = six words, range = four to nine words) and of consonant strings of equivalent length to the words used (mean length = four letters). The material was presented in three different runs. Each of the experimental runs consisted of alternating 32-sec-long blocks of written English sentences and consonant strings. We will refer to this alternation of written English and consonant strings as a cycle. One experimental run was short (two cycles long) while the other two were longer (four cycles long). A set of sentences parallel to those in English was prepared for American Sign Language. A native deaf signer was filmed while either signing short declarative sentences or formally possible but nonexistent (nonsign) gestures. As for English, the material was divided into three different runs, one 2 cycles long and the other two 4 cycles long. Each session comprised six runs; subjects were always presented first with the 2-cycle runs of English and of ASL to ensure that they understood the task and the nature of the stimuli. Runs of English and of ASL always alternated. Whether subjects started with an English run or an ASL run was counterbalanced between subjects. Furthermore, for English as for ASL, one of the long cycle runs began with sentences while the other began with consonant strings/nonsigns so as to control for any order effect within runs.

Procedure

Subjects were lying on a patient bed, viewing a screen at their feet by means of a mirror. For each run, subjects were asked to carefully read the sentences and the consonant strings. Sentences were displayed one word at a time for 400 msec followed by a 200-msec inter-stimulus interval (ISI). The end of each sentence was followed by a 1-sec ISI. The same rate of presentation was used during the consonant string presentation. At the end of the run, six sentences and six consonant strings were flashed one at a time, and subjects had to indicate whether or not they had appeared earlier by raising a finger on the left or right hand. Half of the test items had been presented earlier; the other half was new. New items were, however, similar to some of the presented items, so as to ensure full attention.

Data Analysis

Behavioral Data

Percentage of correct recognition was computed for each language and each type of stimulus (see Table 1) and then entered in an analysis of variance with language and type of stimuli (sentences versus consonant strings/nonsigns) as factors.

fMRI Data Analysis

Individual Subjects Analysis. The fMRI technique permits the monitoring of the local increase in oxygen delivery that occurs in active cerebral tissue. As the ratio of oxygenated to deoxygenated hemoglobin increases within the microvasculature of metabolically active areas, an increased MR signal relative to the resting state is observed from these areas. Hence, areas that are specifically involved in sentence processing should show an increased activation during the sentence block as compared to the consonant strings or nonsigns. The first step in the analysis was to check the experimental runs for motion artifacts. Runs with visible motion, as defined by abrupt transitions in time-series of a number of voxels and prominent edge effects, were discarded from the analysis (4 out of 32 runs were discarded). Then, a cross-correlation thresholding method was used to determine active voxels (Bandettini et al., 1993). Because the experimental design consisted of a continuous alternation of blocks of sentences and blocks of consonant strings/nonsign gestures, activation related to sentence processing should follow this alternation; this assumption is naturally embodied in the cross-correlation analysis. This method involves performing, on a voxel-by-voxel basis, first a linear regression and then a correlation between the signal time-series and a sine wave of reference that modeled the language alternations. Only voxels that showed a correlation greater than 0.5 were considered as active and kept for further analyses. This method has several advantages over the subtraction technique (see Binder & Rao, 1994, p. 197): It more clearly delineates areas of stimulus-related change; it allows one to naturally model the linear drift often observed in the fMRI data, and it allows one to extract information about the temporal aspects of the response.

The threshold correlation value of 0.5 was chosen so as to ensure that the probability of rejecting the null hypothesis when it is true was much less than 0.05 in the between-subjects analysis, while still being reasonably small within each subject. The effective degrees of freedom for the signal time-series were estimated ($df = 35$), leading to $\alpha = 0.0013$ for each voxel (Friston et al., 1994). For each anatomical region, the three aforementioned variables were then derived: presence of active voxels in area, percentage of active voxels, and percentage change of signal in the active voxels. How-

ever, since the number of voxels within an anatomical region varied, regions were considered as active only if they included k or more active voxels, where the computation of k is a function of the number of voxels in the region. For each region of size n voxels, we computed k such that the probability of rejecting k times or more the null hypothesis when true given n draws was set to a prespecified fixed value, hence ensuring comparable alpha levels across regions.

Across-Subject Analysis. Once a map of active voxels is generated, a number of activation variables can be extracted: the timing of the activation, but also the percentage change in activation, the spatial extent of the activation, and importantly, the anatomical localization of the activation. We delineated the MR images collected into 31 anatomical regions according to the Rademacher et al. (1992) divisions of the lateral surface of the brain. These divisions are based on the sulcal anatomy, cytoarchitectonic structure, and the known pattern of projections. The difference between gray and white matter readily available in MR images allowed us to easily localize the different sulci. Distinguishing between the two different banks of the sulcus in order to identify the different gyri was, however, more challenging in our data since the delineating CSF was not always visible. For this reason, all the anatomical areas we described were defined relative to sulcal anatomy and not gyral anatomy (see Table 3 for a list of the 18 principal areas and their corresponding Brodmann areas and Talairach coordinates). These anatomical divisions were then used to classify the active voxels in separate anatomical regions. Between-subject analyses were performed by averaging active voxel information within each anatomical region. Activation measurements were made on the three following variables for each area and each subject's set whether active voxels were present in the region (1 or 0 coding), the mean percentage change of activation of active voxels in the region, and the mean spatial extent of activation in the region (expressed as a ratio of the number of active voxels over the total number of voxels in the region). Multivariate analysis was used to represent the pattern of activation as simply as possible while taking into account all the different aspects of the activation. The main analyses included hemisphere, regions, and order of runs as factors and were performed using a MANOVA on the three aforementioned variables (BMDP Statistical Software). For one or two group's comparison, Hotelling's T^2 statistic was used; for more than two group's comparison, Wilks's lambda likelihood statistic was used (the associated F statistic was computed using Rao's approximation). In these analyses, the dimensionality of the region factor was also reduced so as to increase the power of the analysis. Hence, the 31 anatomical regions were initially grouped into 10 super-anatomical regions relying on their anatomical contiguity and their well-agreed-upon structural similarities. When

a main region effect was obtained, region by region analyses of each of the 31 areas were performed using MANOVAs with the three aforementioned variables as the dependent variables. For each region, the null hypothesis tested was that the amount of activation was zero.

Temporal Characteristics of the Activation. The use of cross-correlation thresholding to determine active voxels involved looking for the time delay that led to a maximum correlation between the voxel time-series and the sine wave time-series that model the stimulus alternations. The computed time delay for the voxels in a slice was then corrected to take account of delays resulting from the known order in which the slices were collected. Active voxels (i.e., above r threshold) whose activation increased with English sentences and decreased with consonant strings were considered as positively correlated voxels (time delay around 0 up to 16 sec). For each anatomical region, we computed the mean time delay across active voxels and across subjects as one index of the time-course of the activation in the region. We also computed the time necessary for the activation to raise by 90% of the mean difference when switching from the consonant strings to the sentence condition and observed a value of 10.9 sec. This value falls well in the range of previous reports (Bandettini, 1993). A similar measure of the time necessary for the activation to decrease by 90% of the mean difference when switching from the sentences condition to the consonant strings condition revealed a value of 11.3 sec. It is interesting to note that while the time course of the increase in activation is typically faster than its relaxation (Bandettini, 1993; Turner & Grinvald, 1994), these times were very similar in our experiment. Unless indicated, analyses discussed in the "Results" section concern only the positively correlated voxels since they are believed to directly indicate activation related to language processing. However, negatively correlated voxels, that is voxels whose activation decreased with English sentences relative to consonant strings, were also observed (time delay around 32 up to 48 sec). Analysis of these voxels is reported under the "Negative Correlation."

Percentage Change. Percentage change in activation was computed for active voxels. Unlike previous studies, percentage change was computed while taking the time lag revealed by the cross-correlation analysis into consideration.

Spatial Extent of Activation. Activation extent was computed by finding the ratio of active voxels over the total number of voxels for each anatomical region. It is important to note that unlike previous studies, the number of active voxels does not indicate the size of a single area of activation whose center of mass is in the anatomical area, but rather the number of active voxels, whether

contiguous or not, that fell within the boundary of the predefined anatomical area.

Use of a Multiple Index for Evaluating Activation. There are several different aspects of the fMRI signal that denote neural activity. The fractional change (or percent) of signal, which reflects changes in deoxyhemoglobin concentration in each voxel (a combination of blood oxygenation level changes and blood volume changes) is often used as a direct index of neural activity (Blamire et al., 1992; Tootell et al., 1995; Turner et al., 1993). Alternatively, a number of studies have relied on the extent of activation, arguing that the larger the spatial extent of the activation, the larger the set of neurons involved (Shaywitz et al., 1995; Karni et al. 1995). Those aspects of the fMRI signal that best index the underlying neural activity are at present unclear. Relying on percentage change alone can lead to a number of misidentifications of activation. First, percentage change might be largest over large vessels (Menon, Ogawa, Tank, & Ugurbil, 1993); hence such an analysis is at risk of biasing the data toward large vessels rather than real areas of activation. More importantly though, measures of percentage change are sensitive to shifts of baseline, especially if powerful methods for image realignment are not available. These shifts have been observed by many fMRI groups and are visible within most experiments. Moreover, the percentage change level may not be proportional to the functional importance of a region. An area may be critically but transiently active during a task, leading only to a weak change in percentage activation (see, however, Tootell et al., 1995, for a powerful demonstration of how percentage change can be used as a parametric index of the activation). Similarly, the inherent assumption when relying on spatial extent that the more active voxels, the more significant they are, may not be biologically plausible. Considering spatial extent improves the robustness of the analysis from a statistical standpoint. However, from the point of view of the microscopic organization of function in the brain, several adjacent voxels may not indicate a more robust activation than one or a few voxels. In our studies, and most similar studies, one voxel ($2.5 \times 2.5 \times 5$ mm in our case) includes a sizeable number of neurons (probably in the order of several million). In these conditions, small, functionally specific foci may only appear as an activation over a few voxels. It is worth remembering that typically in our study only 5 to 10% of each anatomical region considered was active. For these reasons, we believe one should not commit to either percentage change or spatial extent for assessing activation but rather should consider these two variables together. Our analysis relied on the use of multivariate analysis with the three following variables: percentage change of activation in area, spatial extent of activation in area, and whether or not the area was found active. Multivariate analysis allowed us to naturally construct a simple measure of activation, yet one

that still contains the different aspects of the initial sample information.

To illustrate the importance of a multiple index to measure activation, we computed the mean percentage change and the mean percentage extent of the activation across subjects for robustly active areas. Figure 9a, p. 679, illustrates the range of the mean percentage change across runs for the robustly active areas. The mean percent change in our experiment was, on average, 3%, ranging from as low as 0.5% up to 14%. In the robustly active areas considered, most values ranged between 1.5 and 4%. The comparison of Figure 9a to Figure 4 clearly illustrates that relying on percentage change only would have led to a different interpretation of the data with a greater role for the temporal pole and a lesser one for the DLPC. Similarly, Figure 9b illustrates the range of the mean extent of the activation across runs for robustly active areas. The mean size of an anatomical region was approximately 220 voxels in our experiment; the mean percentage extent of the activation ranged from as low as 1 to 21%. In this case, relying on percentage extent would have led to greatly deemphasizing the activation within Broca's area. Interestingly, there is only one region that shows a large percentage change, a large extent, and robust activation, and this is the posterior section of the superior temporal region. Small et al. (1995) also reported this region as active using a similar reading task at 1.5T. However, these authors did not comment on any other active areas, raising the question of the importance of the field strength (4T versus 1.5T) in the overall pattern of results we describe.

Acknowledgments

We are greatly indebted to Dr. Robert Balaban of NHLBI, NIH, for giving us access to the MR Facilities. We are grateful to M. Sereno and A. Dale for lending us one of their 3-D inflated brains for the figures and to J. Haxby for lending us equipment. We thank M. Baker, A. Jones, K. Keil, and E. Klineberg for their contributions during the running, analysis, and manuscript preparation phases of this study. We are also grateful to Alexandre Pouget and Karl Friston for inspiring discussions on the analysis techniques and to B. Ewans for her active participation in the taping of the ASL stimuli. This research was supported by NINDS Grant number DC00128 to Helen Neville, by a McDonnell Pew Foundation postdoctoral fellowship to Daphne Bavelier, and by a grant from the Human Frontier Science Program organization to Dr. Turner.

Reprint requests should be sent to Daphne Bavelier, Institute for Cognitive and Computational Sciences, Georgetown University, 3970 Reservoir Road NW, Washington DC 20007, or by e-mail to daphne@giccs.georgetown.edu.

REFERENCES

- Bandettini, P. A. (June 1993). MRI studies of brain activation: Temporal characteristics. *SMRM/SMRI Joint Workshop on Functional MRI of the Brain*, Arlington, VA, 143-151.

- Bandettini, P. A., Jesmanowicz, A., Wong, E. C., & Hyde, J. S. (1993). Processing strategies for time course data sets in functional MRI of the human brain. *Magnetic Resonance in Medicine*, *30*, 161-173.
- Bechtereva, N. P., Medvedev, S. V., Abdullaev, Y. G., Melnichuk, K. V., & Gurchin, F. A. (1989a). Psychophysiological macro-mapping of the human brain. *International Journal of Psychophysiology*, *8*, 107-135.
- Bechtereva, N. P., Medvedev, S. V., Abdullaev, Y. G., Melnichuk, K. V., & Gurchin, F. A. (1989b). Neuronal activity in central gyri of the human cortex during recognition of semantic and grammatical features of speech. *Doklady Akademii Nauk SSSR*, *309*, 1247-1252. Translated in *Doklady Biological Sciences, Proceedings of the Academy of Sciences of the USSR*, 1990 (pp. 791-794). New York: Plenum.
- Binder, J. R., & Rao, S. M. (1994). Human brain mapping with functional magnetic resonance imaging. In A. Kertesz (Ed.), *Localization and neuroimaging in neuropsychology* (pp. 185-212). San Diego, CA: Academic Press.
- Black, S., & Behrmann, M. (1994). Localization in alexia. In A. Kertesz (Ed.), *Localization and neuroimaging in neuropsychology* (pp. 331-376). San Diego, CA: Academic Press.
- Blamire, A. M., Ogawa, S., Ugurbil, K., Rothmann, D., McCarthy, G., Ellermann, J. M., Hyder, F., Rattner, Z., & Shulman, R. G. (1992). Dynamic mapping of the human visual cortex by high-speed magnetic resonance imaging. *Proceedings of the National Academy of Science*, *89*, 11069-11073.
- Blumstein, S. E. (1995). The neurobiology of language. In J. L. Miller and P. D. Eimas (Eds.), *Speech, language, and communication. Handbook of Perception and Cognition (2nd ed.)*, *11* (pp. 339-370). San Diego: Academic Press.
- BMDP Statistical Software (1992). *BMDP Release 7*. Berkeley: University of California Press.
- Braver, T. S., Cohen, J. D., Nystrom, L. E., Jonides, J., Smith, E. E., & Noll, D. C. (1997). A parametric study of prefrontal cortex involvement in human working memory. *Neuroimage*, *5*(1), 49-62.
- Brodmann, K. (1909). *Vergleichende lokalisationslehre der grosshirnrinde in ihren prinzipien dargestellt auf grund des zellenbaues*. Leipzig: Barth.
- Caplan, D. (1987). *Neurolinguistics and linguistic aphasiology*. Cambridge, UK: Cambridge University Press.
- Caplan, D. (1995). Language disorders. In R. L. Mapou & J. Spector (Eds.), *Clinical neuropsychological assessment: A cognitive approach. Critical issues in neuropsychology* (pp. 83-113). New York: Plenum Press.
- Clark, V. P., Keil, K., Maisog, J. M., Courtney, S. M., Ungerleider, L. G., & Haxby, J. V. (1996). Functional magnetic resonance imaging (fMRI) of human visual cortex during face matching: A comparison with positron emission tomography (PET). *Neuroimage*, *4*, 1-15.
- Corbetta, M., Miezin, F. M., Dobmeyer, S., Shulman, G. L., & Petersen, S. E. (1991). Selective and divided attention during visual discriminations of shape, color, & speed: Functional anatomy by positron emission tomography. *Journal of Neuroscience*, *11*, 2383-2402.
- Craik, F. I. M., & Lockhart, R. S. (1972). Levels of processing: A framework for memory research. *Journal of Verbal Learning and Verbal Behavior*, *12*, 599-607.
- Creutzfeldt, O., Ojemann, G., & Lettich, E. (1989). Neuronal activity in human lateral temporal lobe. I. Response to speech. *Experimental Brain Research*, *77*, 476-489.
- Damasio, A. R., & Damasio, H. (1992). Brain and language. *Scientific American*, *267*, 88-95.
- Damasio, H. (1991). Neuroanatomical correlates of the aphasia. In M. T. Sarno (Ed.), *Acquired aphasia* (pp. 45-71). San Diego, CA: Academic Press.
- Demonet, J-F, Chollet, F., Ramsay, S., Cardebat, D., Nespoulous, J. L., Wise, R., Rascol, A., & Frackowiak, R. (1992). The anatomy of phonological and semantic processing in normal subjects. *Brain*, *115*, 1753-1768.
- Demonet, J-F, Wise, R., & Frackowiak, R. S. J. (1993). Language functions explored in normal subjects by positron emission tomography: A critical review. *Human Brain Mapping*, *1*, 39-47.
- Dronkers, N. F., & Pinker, S. (In press). Language and the aphasias. In E. Kandel, J. Schwartz, & T. Jeffries (Eds.), *Principles in Neural Science*, 4th ed.
- Dronkers, N. F., Redfern, B. B., & Ludy, C. A. (1995). Lesion localization in chronic Wernicke's aphasia. *Brain and Language*, *51*, 62-65.
- Dronkers, N. F., Shapiro, J. K., Redfern, B. B., & Knight, R. T. (1992). The role of Broca's area in Broca's aphasia. *Journal of Clinical and Experimental Neuropsychology*, *14*, 52-53.
- Dronkers, N. F., Shapiro, J. K., Redfern, B. B., & Knight, R. T. (Submitted). The third left frontal convolution and aphasia: On beyond Broca.
- Dronkers, N. F., Wilkins, D. P., Van Valin, R. D., Redfern, B. B., & Jaeger, J. J. (1994). A reconsideration of the brain areas involved in the disruption of morphosyntactic comprehension. *Brain and Language*, *47*, 461-463.
- Fiez, J. A., Raichle, M. A., Miezin, F. M., Petersen, S. E., Tallal, P., & Katz, W. F. (1995). PET studies of auditory and phonological processing: Effects of stimulus characteristics and task demands. *Journal of Cognitive Neuroscience*, *7*(3), 357-375.
- Forman, S. D., Cohen, J. D., Fitzgerald, M., Eddy, W. F., Mintun, M. A., & Noll, D. C. (1995). Improved assessment of significant activation in functional magnetic resonance imaging (fMRI): Use of a cluster-size threshold. *Magnetic Resonance in Medicine*, *33*, 636-647.
- Frackowiak, R. (1994). Functional mapping of verbal memory and language. *Trends in Neuroscience* *17*, 109-115.
- Frisk, V., & Milner, B. (1990). The relationship of working memory to the immediate recall of stories following unilateral temporal or frontal lobectomy. *Neuropsychologia*, *28*, 121-135.
- Friston, K. J., Frith, C. D., Liddle, P. F., & Frackowiak, R. S. (1991). Investigating a network model of word generation with positron emission tomography. *Proceedings of the Royal Society of London B*, *244*, 101-106.
- Friston, K. J., Jezzard, P., & Turner, R. (1994). Analysis of functional MRI time-series. *Human Brain Mapping*, *1*, 153-171.
- Friston, K. J., Worsley, K. J., Frackowiak, R. S. J., Mazziotta, J. C., & Evans, A. C. (1994). Assessing the significance of focal activation using their spatial extent. *Human Brain Mapping*, *1*, 210-220.
- Frith, C. D., Friston, K. J., Liddle, P. F., & Frackowiak, R. S. (1991). A PET study of word finding. *Neuropsychologia*, *29*, 1137-1148.
- Gardner, H., Ling, P., Flamm, L., & Silvermoon, J. (1975). Comprehension and appreciation of humorous material following brain damage. *Brain*, *98*, 399-412.
- Gazzaniga, M. S. (1983). Right hemisphere language following brain bisection: A 20-year perspective. *American Psychologist*, *38*, 525-537.
- Haglund, M. M., Berger, M. S., Shamseldin, M., Lettich, E., & Ojemann, G. A. (1994). Cortical localization of temporal lobe language sites in patients with gliomas. *Neurosurgery*, *34*, 567-576.
- Halgren, E., Squires, N. K., Wilson, C. L., Rohrbaugh, J. W., Babb, T. L., & Crandall, P. H. (1980). Endogenous potentials generated in the human hippocampal formation and amygdala by infrequent events. *Science*, *210*, 803-805.

- Haxby, J. V., Grady, C. L., Horwitz, B., Ungerleider, L. G., Mishkin, M., Carson, R. E., Herscovitch, P., Shapiro, M. B., & Rapoport, S. I. (1991). Dissociation of object and spatial visual processing pathways in human extrastriate cortex. *Proceedings of the National Academy of Sciences of the United States of America*, *88*, 1621-1625.
- Haxby, J. V., Horwitz, B., Ungerleider, L. G., Maisog J. M., Pietrini, P., & Grady, C. L. (1994). The functional organization of human extrastriate cortex: A PET-rCBF study of selective attention to faces and locations. *Journal of Neuroscience*, *14*, 6336-6353.
- Howard, D., Patterson, K., Wise, R., Brown, W. D., Friston, K., Weiller, C., & Frackowiak, R. (1992). The cortical localization of the lexicons. Positron emission tomography evidence. *Brain*, *115*, 1769-1782.
- Just, M. A., Carpenter, P. A., Keller, T. A., Eddy, W. F., & Thulborn, K. R. (1996). Brain activation modulated by sentence comprehension. *Science*, *274*, 114-116.
- Kertesz, A., Harlock, W., & Coates, R. (1979). Computer tomographic localization, lesion size, & prognosis in aphasia and nonverbal impairment. *Brain and Language*, *8*, 34-50.
- Karni, A., Meyer, G., Jezzard, P., Adams, M. M., Turner, R., & Ungerleider, L. G. (1995). Functional MRI evidence for adult motor cortex plasticity during motor skill learning. *Nature*, *377*, 155-158.
- Kohlmeyer, K. (1979). Disorders of brain function due to stroke. Correlates in regional cerebral blood flow and in computerized tomography. In F. Hoffmeister & C. Muller (Eds.), *Bayer symposium: Brain function in old age* (pp. 242-258). New York: Springer-Verlag.
- Language and Cognitive Processes*, *8*, 1993.
- Mazoyer, B., Tzourio, N., Frak, V., Syrota, A., Murayama, N., Levrier, O., Salamon, G., Dehaene, S., Cohen, L., & Mehler, J. (1993). The cortical representation of speech. *Journal of Cognitive Neuroscience*, *5*, 467-479.
- McCarthy, G., Nobre, A. C., Bentin, S., & Spencer, D. D. (1995). Language-related field potentials in the anterior-medial temporal lobe: I. Intracranial distribution and neural generators. *Journal of Neuroscience*, *15*, 1080-1089.
- McIntosh, A. R., Grady, C. L., Ungerleider, L. G., Haxby, J. V., Rapoport, S. I., & Horwitz, B. (1994). Network analysis of cortical visual pathways mapped with PET. *Journal of Neuroscience*, *14*(2), 655-66.
- Menn, L., & Obler, L. (1990). *Agrammatic aphasia: A cross-language narrative sourcebook*. Amsterdam, Philadelphia: J. Benjamins.
- Menon, R. S., Ogawa, S., Tank, D. W., & Ugurbil, K. (1993). 4 Tesla gradient recalled echo characteristics of photic stimulation-induced signal changes in the human primary visual cortex. *Magnetic Resonance in Medicine*, *30*, 380-386.
- Mesulam, M. M. (1990). Large-scale neurocognitive networks and distributed processing for attention, language and memory. *Annals of Neurology*, *28*, 597-613.
- Milner, B. (1971). Disorders of learning and memory after temporal lobe lesions in man. *Clinical Neurosurgery*, *19*, 421-446.
- Mohr, J. P. (1976). Broca's area and Broca's aphasia. In H. Whitaker & H. Whitaker (Eds.), *Studies in neurolinguistics*, *1*, (pp. 201-233). New York: Academic Press.
- Mountcastle, V. (1995). The evolution of ideas concerning the function of the neocortex. *Cerebral Cortex*, *5*, 289-295.
- Moutier, F. (1908). *L'aphasie de Broca*. Paris: Steinheil.
- Murdoch, B. E., Afford, R. J., Ling, A. R., & Ganguley, B. (1986). Acute computerized tomographic scans: Their value in the localization of lesions and as prognostic indicators in aphasia. *Journal of Communication Disorders*, *19*, 311-345.
- Neville, H. (1995). Developmental specificity in neurocognitive development in humans. In M. Gazzaniga (Ed.), *The cognitive neurosciences*, (pp. 219-231). Cambridge, MA: MIT Press.
- Neville, H., Corina, D., Bavelier, D., Clark, V. P., Jezzard, P., Prinster, A., Padmanabhan, S., Braun, A., Rauschecker, J., & Turner, R. (1995). Effects of early experience on cerebral organization for language: An fMRI study of sentence processing in English and ASL by hearing and deaf subjects. *Human Brain Mapping, Supplement 1*, 278.
- Nobre, A. C., Allison, T., & McCarthy, G. (1994). Word recognition in the human inferior temporal lobe. *Nature*, *372*, 260-263.
- Nobre, A. C., & McCarthy, G. (1995). Language-related field potentials in the anterior-medial temporal lobe: II. Effects of word type and semantic priming. *Journal of Neuroscience*, *15*, 1090-1099.
- O'Craven, K. M., Rosen, B. R., Kwong, K. K., Treisman, A., & Savoy, R. L. (1997). Voluntary attention modulates fMRI activity in human MT-MST. *Neuron*, *18*, 591-598.
- Ojemann, G. A. (1988). Effect of cortical and subcortical stimulation on human language and verbal memory. In F. Plum (Ed.), *Language, communication and the brain*, (pp. 101-115). New York: Raven Press.
- Ojemann, G. A. (1991). The cortical organization of language. *The Journal of Neuroscience*, *11*(8), 2281-2287.
- Ojemann, G. A. (1992). Localization of language in frontal cortex. In P. Chauvel & A. V. Delgado-Escueta (Eds.), *Advances in Neurology*, *57*, (pp. 361-368). New York: Raven Press.
- Paulesu, E., Frith, C. D., & Frackowiak, R. S. (1993). The neural correlates of the verbal component of working memory. *Nature*, *362*, 342-345.
- Penfield, W., & Roberts, L. (1959). *Speech and brain-mechanisms*. Princeton, NJ: Princeton University Press.
- Petersen, S. E., & Fiez, J. A. (1993). The processing of single words studied with positron emission tomography. *Annual Review of Neuroscience*, *16*, 509-530.
- Petersen, S. E., Fox, P. T., Posner, M., Mintun, M., & Raichle, M. E. (1988). Positron emission tomographic studies of the cortical anatomy of single-word processing. *Nature*, *331*, 585-589.
- Petersen, S. E., Fox, P. T., Posner, M., Mintun, M., & Raichle, M. E. (1989). Positron emission tomographic studies of the cortical anatomy of single-word processing. *Journal of Cognitive Neuroscience*, *1*, 153-170.
- Petersen, S. E., Fox, P. T., Snyder, A. Z., & Raichle, M. E. (1990). Activation of extrastriate and frontal cortical areas by visual words and word-like stimuli. *Science*, *249*, 1041-1044.
- Poeppel, D. (1996). A critical review of PET studies of phonological processing. *Brain and Language*, *55*, 317-351.
- Poline, J.-B., & Mazoyer, M. (1993). Analysis of individual positron emission tomography activation maps by detection of high signal-to-noise ratio pixel clusters. *Journal of Cerebral Blood Flow Metabolism*, *13*, 425-237.
- Price, C. J., Wise, R. J. S., & Frackowiack, R. S. J. (1996). Demonstrating the implicit processing of visually presented words and pseudowords. *Cerebral Cortex*, *6*, 62-78.
- Price, C. J., Wise, R. J. S., Watson, J. D. G., Patterson, K., Howard, D., & Frackowiack, R. S. J. (1994). Brain activity during reading: The effects of exposure duration and task. *Brain*, *117*, 1255-1269.
- Rademacher, J., Galaburda, A. M., Kennedy, D. N., Filipek, P. A., & Caviness, V. S. (1992). Human cerebral cortex: Localization, parcellation and morphometry with magnetic resonance imaging. *Journal of Cognitive Neuroscience*, *4*, 352-374.
- Raichle, M. E. (1991). Memory mechanisms in the processing

- of words and word-like symbols. *Exploring brain functional anatomy with positron tomography*. (pp. 198-217). Chichester: Wiley (Ciba Foundation Symposium 163).
- Raichle, M. E., Fiez, J. A., Videen, T. O., MacLeod, A. M., Pardo, J. V., Fox, P. T., & Petersen, S. E. (1994). Practice-related changes in human brain functional anatomy during nonmotor learning. *Cerebral Cortex*, 4, 8-26.
- Rueckert, L., Appollonio, I., Grafman, J., Jezzard, P., Johnson, J. R., LeBihan, D., & Turner, R. (1994). Magnetic resonance imaging functional activation of left frontal cortex during covert word production. *Journal of Neuroimaging*, 4, 67-70.
- Searleman, A. (1983). Language capabilities of the right hemisphere. In A. Young (Ed.), *Functions of the right cerebral hemisphere* (pp. 87-11). London: Academic Press.
- Sereno, M. I., Dale, A. M., Reppas, J. B., Kwong, K. K., Belliveau, J. W., Brady, T. J., Rosen, B. R., & Tootell, R. B. (1995). Borders of multiple visual areas in humans revealed by functional magnetic resonance imaging [see comments]. *Science*, 268 (5212), 889-93.
- Sergent, J., Zuck, E., Levesque, M., & MacDonald, B. (1992). Positron emission tomography study of letter and object processing: Empirical findings and methodological considerations. *Cerebral Cortex*, 2, 68-80.
- Shaywitz, B. A., Shaywitz, S. E., Pugh, K. R., Constable, R. T., Skudlarski, P., Fulbright, R. K., Bronen, R. A., Fletcher, J. M., Shankweiler, D. P., Katz, L., & Gore, J. C. (1995). Sex differences in the functional organization of the brain for language. *Nature*, 373, 607-609.
- Small, S. L., Noll, D. C., Perfetti, C. A., & Schneider, W. (1995). Activation of left superior temporal sulcus with functional MRI of sentence processing. *Society for Neuroscience Abstracts*, 21(3), 1964.
- Steinmetz, H., & Seitz, R. J. (1991). Functional anatomy of language processing: Neuroimaging and the problem of individual variability. *Neuropsychologia*, 29, 1149-1161.
- Stromswold, K., Caplan, D., Alpert, N., & Rauch, S. (1996). Localization of syntactic comprehension by positron emission tomography. *Brain and Language*, 52(3), 452-473.
- Talairach, J., & Tournoux, P. (1988). *Co-planar stereotaxic atlas of the human brain: A 3-dimensional proportional system, an approach to cerebral imaging*. New York: Thieme Medical Publishers.
- Tootell, R. B., Reppas, J. B., Kwong, K. K., Malach, R., Born, R. T., Brady, T. J., Rosen, B. R., & Belliveau, J. W. (1995). Functional analysis of human MT and related visual cortical areas using magnetic resonance imaging. *Journal of Neuroscience*, 15, 3215-3230.
- Turner, R., & Grinvald, A. (1994). Direct visualization of patterns of deoxygenation and reoxygenation in monkey cortical vasculature during functional brain activation. *Proceedings of the Fourth Society of Magnetic Resonance Meeting*, (p. 430). New York.
- Turner, R., Jezzard, P., Wen, K. K., Kwong, D., LeBihan, T., Zeffiro, T., & Balaban, R. S. (1993). Functional mapping of the human visual cortex at 4 and 1.5 Tesla using deoxygenation contrast EPI. *Magnetic Resonance in Medicine*, 29, 277-279.
- Wise, R., Chollet, F., Hadar, U., Friston, K., Hoffner, E., & Frackowiak, R. (1991). Distribution of cortical neural networks involved in word comprehension and word retrieval. *Brain*, 114, 1803-1817.
- Wise, R., Hadar, U., Howard, D., & Patterson, K. (1991). Language activation studies with positron emission tomography. *Ciba Foundation Symposium*, 163, 218-234.
- Zaidel, E. (1990). Language functions in the two hemispheres following complete cerebral commissurotomy and hemispherectomy. In R. D. Nebes & S. Corkin (Eds.), *Handbook of neuropsychology*, 4 (pp. 115-150). Amsterdam: Elsevier.
- Zurif, E. B., Caramazza, A., & Myerson, R. (1972). Grammatical judgments of agrammatic aphasics. *Neuropsychologia*, 10, 405-417.
- Zurif, E. B., & Swinney, D. (1994). The neuropsychology of language. In M. A. Gernsbacher (Ed.), *Handbook of psycholinguistics* (pp. 1055-1074). San Diego, CA: Academic Press.