



Article scientifique

Article

2013

Published version

Open Access

This is the published version of the publication, made available in accordance with the publisher's policy.

Platypnea-orthodeoxia syndrome in the elderly treated by percutaneous patent foramen ovale closure: a case series and literature review

Blanche, Coralie Amandine; Noble, Stéphane Laurent; Roffi, Marco; Testuz, Ariane Marie; Mueller, Hajo; Meyer, Philippe; Bonvini, John M; Bonvini, Robert

How to cite

BLANCHE, Coralie Amandine et al. Platypnea-orthodeoxia syndrome in the elderly treated by percutaneous patent foramen ovale closure: a case series and literature review. In: European journal of internal medicine, 2013, vol. 24, n° 8, p. 813–817. doi: 10.1016/j.ejim.2013.08.698

This publication URL: <https://archive-ouverte.unige.ch/unige:90400>

Publication DOI: [10.1016/j.ejim.2013.08.698](https://doi.org/10.1016/j.ejim.2013.08.698)



Original article

Platypnea–orthodeoxia syndrome in the elderly treated by percutaneous patent foramen ovale closure: A case series and literature review[☆]



Coralie Blanche^a, Stéphane Noble^a, Marco Roffi^a, Ariane Testuz^a, Hajo Müller^a, Philippe Meyer^a, John M. Bonvini^b, Robert F. Bonvini^{a,*}

^a Cardiology Division, University Hospital, Geneva, Switzerland

^b Anesthesiology Department, University Hospital, Zurich, Switzerland

ARTICLE INFO

Article history:

Received 26 April 2013

Received in revised form 24 July 2013

Accepted 12 August 2013

Available online 3 September 2013

Keywords:

Cardiac platypnea–orthodeoxia syndrome

Patent foramen ovale

Percutaneous closure

ABSTRACT

Background: Platypnea–orthodeoxia syndrome (POS) is a rare clinical phenomenon, associating normal oxygen saturation in a supine position and arterial hypoxemia in an upright position. This pathology can be secondary to an intracardiac shunt, a pulmonary vascular shunt or a ventilation–perfusion mismatch. Cardiac POS occurs in the presence of a right-to-left cardiac shunt, most commonly through a patent foramen ovale (PFO).

Methods and results: From our single-center prospective database of percutaneous PFO closure we identified five patients (4 females, mean age: 77 ± 11 years) out of 224 (2.2%) patients with a PFO who presented with a POS of cardiac origin. Transthoracic and transoesophageal echocardiographic examinations revealed the underlying mechanisms of POS and the diagnosis was confirmed by right-and-left cardiac catheterization (RLC) and by measuring serial blood oxygen saturation in the pulmonary veins and left atrium in supine and upright positions. PFO was associated with atrial septal aneurysm and a persistent prominent Eustachian valve in 3 patients.

All patients underwent a successful percutaneous PFO closure without any immediate or subsequent complications (mean follow-up of 24 ± 18 months). Immediately after the procedure, mean arterial oxygen saturation improved from $83\% \pm 3$ to $93\% \pm 2$ in an upright position and symptoms disappeared.

Conclusion: POS is a rare and under-diagnosed pathology that must be actively investigated in the presence of position-dependent hypoxemia. The diagnostic work-up must exclude other causes of hypoxemia and confirm the intracardiac shunt using either contrast echocardiography or RLC. For cardiac POS, percutaneous PFO closure is a safe and effective technique that immediately relieves orthodeoxia and patient symptoms.

© 2013 European Federation of Internal Medicine. Published by Elsevier B.V. All rights reserved.

1. Introduction

Platypnea–orthodeoxia syndrome (POS) is a rare clinical phenomenon, associating normal oxygen saturation in the supine position (= platypnea) and arterial oxygen desaturation in an upright position (= orthodeoxia) [1]. The exact underlying mechanisms leading to this unusual condition are not fully understood, but most probably derive from one of the following three categories: intracardiac shunting, pulmonary vascular shunting, ventilation–perfusion mismatch or a combination of these mechanisms [2].

One of the typical issues associated with cardiac POS is the presence of an intracardiac right-to-left shunt through a patent foramen ovale (PFO) [3]. The PFO may remain clinically silent for decades, but when the right–left pressure equilibrium is challenged (e.g. after acute

pulmonary injury) or when the heart–lung anatomy is distorted and re-directs venous blood toward the PFO (e.g., after pulmonary surgery) [4–6] it may abruptly manifest itself by the development of POS.

Another known but atypical clinical scenario for cardiac POS is an increase in pulmonary vascular resistances and right ventricular and atrial pressures following pulmonary embolism (PE) which has subsequently opened the PFO and favored the right to left shunt. Since there is a physiological orthostatic increase in intrathoracic pressures [7], this phenomenon is accentuated in an upright position.

To correctly establish the diagnosis of POS, an arterial oxygen desaturation (i.e. <95% while breathing ambient air) in an upright position needs to be observed, while measuring normal saturations in the supine position. Usually these positional arterial oxygen evaluations are performed using a standard pulse oximeter, which in stable patients correlates well with invasive blood-gas analysis [8–10].

Additionally, contrast echocardiography, invasive heart catheterization and thoracic computer tomography (CT)-scan are all used to identify the mechanisms leading to POS, to exclude other causes of hypoxemia as well as to locate and quantify the right-to-left shunt.

Presently, the only treatment to reduce the amount of de-oxygenated blood to the left heart chambers is to eliminate the

[☆] The authors have no commercial associations or sources of support that might pose a conflict of interest.

* Corresponding author at: Division of Cardiology, University Hospital of Geneva, 4, Rue Gabrielle Perret-Gentil, 1211 Geneva 14, Switzerland. Tel.: +41 22 372 72 00; fax: +41 22 372 72 29.

E-mail address: Robert.Bonvini@hcuge.ch (R.F. Bonvini).

shunt by surgical or percutaneous procedures, since neither pharmacological approaches nor changes in lifestyle have proved effective [11].

The following report describes five patients presenting with cardiac POS, the challenges of the diagnostic evaluation, as well as the positive outcomes obtained after percutaneous PFO closure and in addition it reviews current literature on the subject.

2. Materials and methods

From a prospectively maintained PFO database of 224 patients in whom PFO was percutaneously closed at our tertiary university hospital, we identified five patients between December 2002 and December 2012 with symptomatic cardiac POS (2.2%). Before considering these patients for PFO closure, they were evaluated by trained cardiologists and pneumologists who excluded other possible etiologies of dyspnea and hypoxemia, notably PE and other lung or cardiac diseases. All patients were investigated with transthoracic (TTE) and transesophageal echocardiograph (TEE) with injected contrast/air bubbles to detect a shunt as well as with a pulmonary CT-angiography. In one patient, cardiac catheterization was performed before PFO closure to confirm the diagnosis of a right-to-left shunt. PFO closure was performed according to standard practice [12,13]. Residual shunt and device position were assessed by TTE at day 1 and 6 months. For all patients, complete positional oxygen saturation measurements were obtained at day one after the procedure and in the event of any recurring symptoms.

3. Clinical cases (Table 1)

3.1. Patient no. 1

Following knee surgery, an 83 year-old woman was referred for recurrent episodes of severe hypoxemia when in an upright position. The pulmonary work-up excluded PE and other parenchymal diseases. Standard TTE was normal, notably without any signs of pulmonary hypertension (PH), but contrast TEE revealed a large PFO associated with an atrial septal aneurysm (ASA) and a significant right-to-left shunt at rest, increasing during Valsalva. Cardiac catheterization confirmed normal pulmonary pressures (mean right atrial pressure 1 mmHg and mean pulmonary pressure 9 mmHg) and showed no shunt in a supine

position, but a right-to-left shunt when the patient was upright with a Qp/Qs = 0.87, confirming the diagnosis of cardiac POS. The patient underwent percutaneous PFO closure using an 18-mm AMPLATZER® PFO Occluder (St. Jude Medical, USA). Arterial oxygen saturation (SaO₂) immediately increased after PFO closure from 77% to 93% when sitting despite the presence of a mild residual right-to-left shunt. The cause for the development of this significant shunt was attributed to dilatation and elongation of the ascending aorta and multiple vertebral osteoporotic fractures leading to kyphoscoliosis. Five years later, the patient was readmitted for orthopedic reasons and SaO₂ in both supine and upright positions remained normal (95%) with a mild residual right-to-left shunt on the contrast TTE.

3.2. Patient no. 2

A 75-year-old obese woman was admitted complaining of dyspnea on exertion for 3 months and severe hypoxemia (SaO₂ 85%) requiring oxygen-therapy. Complete lung function tests showed a severe restrictive syndrome and carbon monoxide diffusion problems, and chest CT-scan revealed bilateral segmental PE. One month later the evolution was not satisfactory despite anticoagulation, with persistent dyspnea and episodes of desaturation in an upright position. The hypoxemia could not be explained by the PE alone; therefore, it was decided to perform contrast TTE and TEE. These exams showed a large PFO with possible position-dependent right-to-left shunt. Cardiac POS was confirmed as the main cause of hypoxemia by serial arterial blood gas tests in different positions (SaO₂ of 94% when supine vs. SaO₂ of 85% when sitting). The main cause of the shunt was the presence of right diaphragmatic paralysis leading to compression of the right cardiac chambers, as noted on the TTE, redirecting the inferior vena cava flow directly through the PFO.

No significant shunt in a supine position was detected during cardiac catheterization (Qp/Qs = 1), and the right chamber pressure measurements showed no PH (mean right atrial pressure 6 mmHg and mean pulmonary pressure 20 mmHg). The patient underwent PFO closure using a 35-mm AMPLATZER® PFO Occluder. The episodes of hypoxemia ceased immediately. SaO₂ in a sitting position increased from 85% to 94% without any residual shunt on the TTE. The patient was discharged from hospital under oral anticoagulation for the PE and at 12 months follow up was free of symptoms.

Table 1
Baseline and procedural characteristics.

Pts	Sex	Age (77 ± 11)	Co-morbidities	Symptoms	Conditions favoring POS	Hemodynamic characteristics	Upright SaO ₂ before → after	Size of the PFO occluder device
1	F	83	Dyslipidemia	Dyspnea at rest	K, AoD, ASA	No PH, Qp/Qs = 0.87	77% → 93%	18 mm
2	F	75	Systemic hypertension	Dyspnea on exertion	DP, EV	No PH Qp/Qs = 1	85% → 94%	35 mm
3	F	80	Microscopic PN, PE	Dyspnea and cough	RS, ASA, EV	No PH Qp/Qs = 0.7	82% → 90%	35 mm
4	M	60	Lymphoma, CKD, stroke	Dyspnea at rest	DP, ASA	No PH Supine: LA 93% PV 97% Upright: LA 89% PV 97%	85% → 96%	25 mm
5	F	89	Systemic hypertension, heart failure, pacemaker for third AV block	Dyspnea at rest	EV, AoD	No PH Supine: LA 93% PV 97% Upright: LA 83% PV 97%	85% → 91%	35 mm

Pts = patients
CKD = chronic kidney disease
POS = platypnea-orthodeoxia syndrome
EV = prominent Eustachian valve
PV = pulmonary vein
DP = diaphragmatic paralysis

M = male
PE = pulmonary embolism
ASA = atrial septal aneurysm
PH = pulmonary hypertension
AV = atrio-ventricular block
ResS = restrictive syndrome

F = female
PN = polyarteritis nodosa
AoD = aortic root dilatation
LA = left atrium
K = kyphoscoliosis

3.3. Patient no. 3

An 80-year-old woman with a history of microscopic polyarteritis nodosa with renal and pulmonary involvement and a C-protein deficiency with recurrent PE was referred to our hospital for progressive dyspnea associated with fever and a cough. The lung CT-scan showed a worsening of her pulmonary fibrosis as well as a lung infection. Treatment with antibiotics and corticosteroids was initiated and clinical evolution was slowly favorable despite persistent episodes of severe hypoxemia (up to 82%) when sitting upright. Contrast TTE and TEE revealed an important right-to-left shunt related to a large PFO, associated with ASA and a prominent Eustachian valve. These findings added to the progression of pulmonary fibrosis and restrictive syndrome (total pulmonary capacity: 59% of predicted value) explained the development of the syndrome. Indeed, the change of pulmonary volumes led to right atrial deformation and vena cava flow redirection through the PFO. PH was excluded by cardiac catheterization (mean right atrial pressure 8 mmHg and mean pulmonary pressure 13 mmHg) and a Qp/Qs of 0.7 confirmed the presence of a significant shunt. Therefore PFO closure using a 35-mm AMPLTZER® PFO Occluder was concomitantly performed. An immediate clinical improvement was observed with SaO₂ increasing from 82% to 90% when sitting. The outcome at 6 months was favorable despite a small residual shunt on the contrast TTE.

3.4. Patient no. 4

The fourth patient, a 60-year-old obese man, was hospitalized following an ischemic stroke attributed to a paradoxical embolism. The patient was discharged under oral anticoagulation, but was readmitted a few months later for unexplained episodes of hypoxemia when sitting upright. TTE and TEE showed a PFO with ASA, as well as compression of the right cardiac chambers due to right diaphragmatic paralysis and ascension. There were no indirect signs of elevated right ventricular pressure and tricuspid flow velocities were normal. Contrast administration showed a significant and position-dependent right-to-left shunt, so it was decided to attempt PFO closure both for the POS and history of embolic stroke. The PFO was successfully closed with the implantation of a 25-mm Cribiform AMPLATZER® PFO Occluder. At the end of the procedure, the patient reported a significant improvement of his dyspnea and SaO₂ had increased from 85% to 96% when sitting upright.

3.5. Patient no. 5

An 89-year-old woman with a history of heart failure, with low left ejection fraction and an aneurismal ascending aorta, was initially admitted for septic shock secondary to ischemic colitis. She underwent abdominal surgery with a favorable outcome initially, but developed recurrent episodes of severe hypoxemia (SaO₂ ~85%), which in the first instance were attributed to acute pulmonary edema due to uncontrolled hypertension. It was then noted that these hypoxemic episodes only occurred when the patient was sitting upright, suggesting POS. Acute PE was excluded by thoracic CT-scan which confirmed the aneurismal dilatation of the ascending aorta as the main cause for the development of POS. TEE showed a prominent Eustachian valve, moderate interatrial right-to-left shunt detected by color Doppler and bubble tests, and a large PFO. Systolic pulmonary pressure as assessed through tricuspid regurgitation flow analysis was 20 mmHg, with no other indirect signs of PH. The shunt significantly increased when the patient was in an upright position, suggesting the presence of cardiac POS. Cardiac catheterization confirmed the diagnosis with a “step-down” of oxygen saturation between the pulmonary veins (PVs) and left atrium (LA) in an upright position. The PFO was successfully closed with a 35-mm AMPLATZER® PFO Occluder with an immediate improvement of the

SaO₂ from 85% to 91% when sitting. At 6-month follow up, the patient remained asymptomatic.

4. Discussion

POS is rarely diagnosed and its prevalence in the general population remains unknown [14]. Accordingly, only isolated case-reports and a few case-series have been reported so far, suggesting that POS may be largely under-diagnosed and/or under-reported [15]. The diagnosis of POS is difficult and our case-series confirms that in patients presenting with respiratory symptoms, POS is usually a “rule-out diagnosis” suspected only at the end of an extensive and non-standardized medical work-up. Once the existence of POS is established, the underlying mechanism has to be determined to guide treatment strategy, especially if one considers that there are three main physiopathological mechanisms leading to this syndrome: 1) intra-cardiac shunt (or cardiac POS), 2) intrapulmonary shunt (pulmonary arterio-venous malformation, hepato-pulmonary syndrome) and 3) ventilation-perfusion mismatch.

All our patients had cardiac POS caused by a right-to-left intracardiac shunt, without any sign of PH at echocardiography or cardiac catheterization. In typical cardiac POS, the net right-to-left driving forces are seldom secondary to PH, but rather depend on congenital or acquired favorable atrial anatomy which redirects vena cava blood flow preferentially through the PFO, without the need for a significant pressure gradient. Indeed, despite its presence since birth in about 25% of the general population, a PFO most often does not give rise to POS. Even if an interatrial communication (PFO or ASD) is necessary for cardiac POS development, and ASA or prominent Eustachian valve act as contributing factors, the main cause for right-to-left shunt development is right chamber anatomy modification in later life [16]. Several mechanical conditions – mainly right diaphragmatic paralysis and ascension [17,18], kyphoscoliosis [19], restrictive lung disease, previous pneumonectomy [4,5,20], pleural effusion, and ectatic/aneurysmal ascending aorta [21,22] – may lead to atrial chamber or septum deformity, thus changing the anatomic relationship between the atrial septum and the inferior vena cava and therefore facilitating desaturated blood flow redirection through the PFO. In our case series, the septum anatomical modifications were due to aortic dilatation, right diaphragmatic paralysis and ascension, restrictive lung disease and kyphoscoliosis.

4.1. Diagnostic evaluation of POS

Contrast TTE is the most valuable tool to confirm the presence of right-to-left shunt, while TEE is better for assessing the atrial and interatrial anatomy (e.g., large PFO ± ASA ± Eustachian valve) [23–25]. The magnitude of right-to-left shunt and especially its position-dependency (e.g., supine, sitting, standing) should be confirmed with serial oxygen saturation measurements obtained through standard pulse oximetry or, if possible, through blood gas analysis.

Despite the fact that these non-invasive oxygen saturation measurements are generally used in the early stages of POS diagnosis, the gold standard diagnostic test remains cardiac catheterization with oxygen saturation measurements directly in the LA and in the PVs. A “step-down” of the oxygen saturation between the PVs and LA definitively confirms the presence of an interatrial right-to-left shunt, necessary to diagnose POS of cardiac origin. The sensitivity of this method may be increased by performing several provocative tests, such as the Valsalva maneuver, which can increase the degree of shunt in an upright position. In everyday practice however, these serial measurements are not routinely performed as the non-invasive workup is usually sufficient to establish the diagnosis (echocardiography, peripheral oxygen saturation measurements) and also because patient disability rather than shunt magnitude dictates the decision for PFO closure. However, right heart catheterization has a crucial role in establishing pulmonary pressure, as severe PH might worsen after PFO closure and might lead

to clinical deterioration of the patient's condition despite correction of the right-to-left shunt.

4.2. POS treatment modalities

The treatment of choice for cardiac POS is the percutaneous closure of the communication between the right and left atria. Before the procedure, it is essential to confirm the cardiac origin of POS as well as the clinical relevance of the cardiac shunt in the mixed form of POS.

Due to the relative rarity of this syndrome, PFO closure in this clinical setting has been described by only a few retrospective series and several case reports [11,14,26,27]. In 2000 Godart et al. [11] reported 11 consecutive patients with severe cardiac POS secondary to a PFO, for whom successful PFO closure led to a significant increase in blood oxygen saturation immediately after the procedure with no recurrence of hypoxemia during 30 months of follow-up. Delgado et al. [28] obtained similar results in a population of 18 patients: all had a confirmed diagnosis of cardiac POS secondary to a PFO or atrial septal defect and underwent percutaneous closure of the defect with significant clinical improvement. More recently, Guerin et al. [14] reported a retrospective multicenter study of 78 patients (mean age 67 ± 11 years), presenting with POS of all types, who underwent percutaneous PFO closure. In this series, the largest published so far, the most frequently observed medical conditions leading to the development of POS were previous pneumonectomy and an ascending aortic aneurysm. The procedure was successful in 76 patients with immediate improvement of oxygen saturation and dyspnea. During a mean follow-up of 15 ± 12 months, a small residual shunt was observed in six asymptomatic patients, while five other patients still reported dyspnea without evidence of a residual shunt. Similar results were reported in the study by Landzberg et al. [27], where 3 patients out of 8 already had severe hypoxemia when supine and remained oxygen-dependant after successful PFO closure. In these studies, the three different types of POS were probably included, explaining the lack of improvement in some patients after PFO closure. This non-response to PFO-closure emphasizes the importance of excluding other causes of hypoxemia and other forms of POS before attempting PFO closure. Finally, residual shunt after PFO closure should also be considered as a possible cause for persistence of hypoxemia. Operators should be aware of specific technical difficulties associated with PFO closure in the setting of POS. These difficulties are essentially due to the different anatomic variations and deformities of the septum responsible for POS, and which can lead to suboptimal device placement and deployment, with consecutive persistence of a residual shunt [29].

Interestingly, in our series, the patients had different baseline characteristics compared to Guerin's study [14], but had similar improvement following PFO closure. Indeed, they were older (mean age 77 ± 11 years), and presented different co-morbidities. The percutaneous PFO closure was performed successfully in all five cases with a mean upright oxygen saturation increasing from $83\% \pm 3$ before to $93\% \pm 2$ after closure (Fig. 1).

4.3. Study limitations and strengths

Our study has some limitations that have to be acknowledged; they are mainly related to the small sample size. However, most of the studies in the literature dealing with POS are case-reports that have the same limitations, finely underlining the rarity of this pathology and the difficulty in its diagnosis. Furthermore, many of the remaining reported studies included mixed types of POS, possibly decreasing the efficacy of PFO closure.

The strength of our small study was to exclusively include patients with cardiac type POS confirmed at cardiac catheterization, offering an accurate assessment of the efficacy of the percutaneous treatment once the right-to-left shunt had been reduced by the closure procedure.

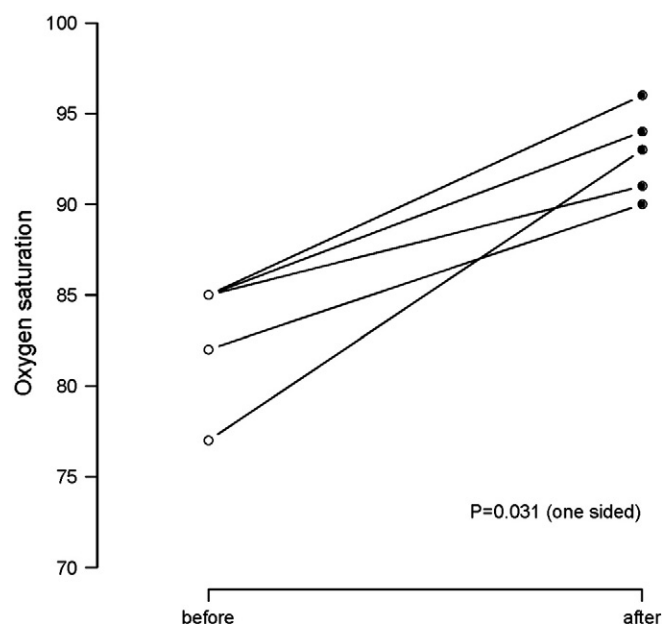


Fig. 1. shows the arterial oxygen saturation in the upright position immediately before and after the closure procedure.

5. Conclusions

Platypnea–orthodeoxia syndrome is a rare and complex clinical phenomenon that must be actively screened in the presence of unexplained positional hypoxemia. POS can be divided into three categories according to the underlying pathophysiological mechanism (i.e., intracardiac shunting, pulmonary vascular shunting or ventilation–perfusion mismatch). To confirm the diagnosis of cardiac POS, contrast TTE \pm TEE must show the presence of a right-to-left shunt and orthodeoxia must be demonstrated with pulse oximetry or blood gas analysis. Before considering percutaneous closure of the interatrial shunt, cardiac catheterization with complete step-by-step oxygen saturation – including PVs and LA – may be required to confirm the clinical relevance of the PFO. This is of paramount importance in patients suffering from mixed type POS.

Finally, percutaneous PFO closure should be considered the treatment of choice for cardiac POS since this approach has proved to be safe, reliable and effective while immediately leading to a significant improvement of hypoxemia and patient symptoms.

Conflict of interests

No disclosure to be reported for the authors. There was no industry funding for this article.

Learning points

- Platypnea–orthodeoxia syndrome is a rare, complex and under-diagnosed clinical phenomenon.
- POS must be actively screened in the presence of unexplained positional hypoxemia.
- Percutaneous PFO closure should be considered the treatment of choice for cardiac POS.
- PFO closure immediately leads to significant improvement of hypoxemia and patient symptoms.

References

- [1] Altman M, Robin ED. Platypnea (diffuse zone i phenomenon?). *N Engl J Med* 1969;281:1347–8.

- [2] Chen GP, Goldberg SL, Gill Jr EA. Patent foramen ovale and the platypnea-orthodeoxia syndrome. *Cardiol Clin* 2005;23:85–9.
- [3] Sorrentino M, Resnekov L. Patent foramen ovale associated with platypnea and orthodeoxia. *Chest* 1991;100:1157–8.
- [4] Begin R. Platypnea after pneumonectomy. *N Engl J Med* 1975;293:342–3.
- [5] Dlabal PW, Stutts BS, Jenkins DW, Harkleroad LE, Stanford WT. Cyanosis following right pneumonectomy: importance of patent foramen ovale. *Chest* 1982;81:370–2.
- [6] Mashman WE, Silverman ME. Platypnea related to constrictive pericarditis. *Chest* 1994;105:636–7.
- [7] Seward JB, Hayes DL, Smith HC, Williams DE, Rosenow III EC, Reeder GS, et al. Platypnea-orthodeoxia: clinical profile, diagnostic workup, management, and report of seven cases. *Mayo Clin Proc* 1984;59:221–31.
- [8] Hanning CD, Alexander-Williams JM. Pulse oximetry: a practical review. *BMJ* 1995;311:367–70.
- [9] Smatlak P, Knebel AR. Clinical evaluation of noninvasive monitoring of oxygen saturation in critically ill patients. *Am J Crit Care* 1998;7:370–3.
- [10] Forbes WH. The equilibrium between oxygen and haemoglobin. II. The oxygen dissociation curves of dilute solutions of horse haemoglobin. *J Physiol* 1931;71:261–7.
- [11] Godart F, Rey C, Prat A, Vincentelli A, Chmait A, Francart C, et al. Atrial right-to-left shunting causing severe hypoxaemia despite normal right-sided pressures. Report of 11 consecutive cases corrected by percutaneous closure. *Eur Heart J* 2000;21:483–9.
- [12] Meier B. Catheter-based closure of the patent foramen ovale. *Circulation* 2009;120:1837–41.
- [13] Wahl A, Praz F, Stinimann J, Windecker S, Seiler C, Nedeltchev K, et al. Safety and feasibility of percutaneous closure of patent foramen ovale without intra-procedural echocardiography in 825 patients. *Swiss Med Wkly* 2008;138:567–72.
- [14] Guerin P, Lambert V, Godart F, Legendre A, Petit J, Bourlon F, et al. Transcatheter closure of patent foramen ovale in patients with platypnea-orthodeoxia: results of a multicentric french registry. *Cardiovasc Intervent Radiol* 2005;28:164–8.
- [15] Cheng TO. Platypnea-orthodeoxia syndrome: etiology, differential diagnosis, and management. *Catheter Cardiovasc Interv* 1999;47:64–6.
- [16] Vale TA, Newton JD, Orchard E, Bhindi R, Wilson N, Ormerod OJ. Prominence of the eustachian valve in paradoxical embolism. *Eur J Echocardiogr* 2011;12:33–6.
- [17] Ghamande S, Ramsey R, Rhodes JF, Stoller JK. Right hemidiaphragmatic elevation with a right-to-left interatrial shunt through a patent foramen ovale: a case report and literature review. *Chest* 2001;120:2094–6.
- [18] Toffart AC, Bouvaist H, Feral V, Blin D, Pison C. Hypoxemia-orthodeoxia related to patent foramen ovale without pulmonary hypertension. *Heart Lung* 2008;37:385–9.
- [19] Sanikommu V, Lasorda D, Poornima I. Anatomical factors triggering platypnea-orthodeoxia in adults. *Clin Cardiol* 2009;32:E55–7.
- [20] Bhattacharya K, Birla R, Northridge D, Zamvar V. Platypnea-orthodeoxia syndrome: a rare complication after right pneumonectomy. *Ann Thorac Surg* 2009;88:2018–9.
- [21] Bertaux G, Eicher JC, Petit A, Dobsak P, Wolf JE. Anatomic interaction between the aortic root and the atrial septum: a prospective echocardiographic study. *J Am Soc Echocardiogr* 2007;20:409–14.
- [22] Faller M, Kessler R, Chaouat A, Ehrhart M, Petit H, Weitzenblum E. Platypnea-orthodeoxia syndrome related to an aortic aneurysm combined with an aneurysm of the atrial septum. *Chest* 2000;118:553–7.
- [23] Hirai N, Fukunaga T, Kawano H, Honda O, Sakamoto T, Yoshimura M, et al. Platypnea-orthodeoxia syndrome with atrial septal defect. *Circ J* 2003;67:172–5.
- [24] Bashour T, Kabbani S, Saalouke M, Cheng TO. Persistent eustachian valve causing severe cyanosis in atrial septal defect with normal right heart pressures. *Angiology* 1983;34:79–83.
- [25] Acharya SS, Kartan R. A case of orthodeoxia caused by an atrial septal aneurysm. *Chest* 2000;118:871–4.
- [26] Waight DJ, Cao QL, Hijazi ZM. Closure of patent foramen ovale in patients with orthodeoxia-platypnea using the amplatzer devices. *Catheter Cardiovasc Interv* 2000;50:195–8.
- [27] Landzberg MJ, Sloss LJ, Faherty CE, Morrison BJ, Bittl JA, Bridges ND, et al. Orthodeoxia-platypnea due to intracardiac shunting—relief with transcatheter double umbrella closure. *Cathet Cardiovasc Diagn* 1995;36:247–50.
- [28] Delgado G, Inglessis I, Martin-Herrero F, Yoerger D, Liberthson R, Buoanno F, et al. Management of platypnea-orthodeoxia syndrome by transcatheter closure of atrial communication: hemodynamic characteristics, clinical and echocardiographic outcome. *J Invasive Cardiol* 2004;16:578–82.
- [29] Zavalloni D, Lisignoli V, Barbaro C, Mennuni M, Tosi P, Marcheselli S, et al. Platypnoea-orthodeoxia syndrome secondary to patent foramen ovale (pfo): a challenging subset for pfo percutaneous closure. *Heart Lung Circ* 2013;22(8):642–6.