



Article scientifique

Lettre

2013

Published version

Open Access

This is the published version of the publication, made available in accordance with the publisher's policy.

Delayed paraplegia due to "surgiceloma" following thoracotomy for a Pancoast tumor

Schatlo, Bawarjan; Eger, Antoine-Flavien; Schaller, Karl Lothard; Tessitore, Enrico

How to cite

SCHATLO, Bawarjan et al. Delayed paraplegia due to 'surgiceloma' following thoracotomy for a Pancoast tumor. In: Acta neurochirurgica, 2013, vol. 155, n° 7, p. 1243–1244. doi: 10.1007/s00701-013-1703-3

This publication URL: <https://archive-ouverte.unige.ch/unige:45467>

Publication DOI: [10.1007/s00701-013-1703-3](https://doi.org/10.1007/s00701-013-1703-3)

Delayed paraplegia due to “surgiceloma” following thoracotomy for a Pancoast tumor

Bawarjan Schatlo · Antoine-Flavien Eger · Karl Schaller · Enrico Tessitore

Received: 21 March 2013 / Accepted: 26 March 2013 / Published online: 17 April 2013
© Springer-Verlag Wien 2013

Dear Editor,

Oxidized regenerated cellulose (ORC, Surgicel®, Ethicon Inc.) is widely used as a hemostatic fleece. The manufacturer recommends removing as much ORC as possible before closure. As one of the possible complications of its use, postoperative neurological compression symptoms caused by so-called “surgiceloma” have been described in the spine [1] and brain [2, 4]. Since this entity regularly occurs despite better knowledge, we would like to share our experience with a catastrophic complication following the inappropriate use of ORC in spinal surgery.

A 54-year-old male underwent posterolateral thoracotomy for a Pancoast tumor T4N0M0 of the right upper pulmonary lobe with infiltration of the vertebral body of Th2 at another institution. The patient awoke from surgery without neurological deficits. On postoperative day 1, he fell asleep in the afternoon and woke up with paraplegia and complete sensory loss in his right leg. An emergency MRI showed a mass lesion within the spinal canal at the Th2 level (Fig. 1a) whereupon the patient was transferred to our department for neurosurgical treatment. After a Th2–Th3 laminectomy (Fig. 1b), we found ORC material compressing the spinal cord from the right side and penetrating the dura, creating a cerebrospinal fluid (CSF) leak. A postoperative MRI showed the sequelae of the compression as an intramedullary hyperintense signal on T2-weighted imaging at the Th2–Th3 level (Fig. 1c). The patient was sent to rehabilitation with some recovery in the left leg. He died 1 year later because of the progression of the underlying oncological disease.

We found 17 ($N=17$) reports of delayed neural compression due to ORC after a comprehensive MEDLINE search, and we would like to summarize the most salient features. Almost half of the described procedures ($8/17=47\%$) were thoracotomies at vertebral levels Th3 to Th8 for resection of neoplasms in adults. Three pediatric cases of thoracic surgery that resulted in neural compression syndromes due to ORC were also reported. Median time to symptom discovery was at 30 h postoperatively. The delayed occurrence of symptoms indicates that neurological deficits were not due to inadequate application of pressure on neural structures, but due to delayed swelling of the hemostatic material that was left in place and subsequent migration of material into the spinal canal via the neuroforamen.

Eleven out of 17 patients (64 %) already had complete paraplegia at the time of reoperation. This indicates that by the time of symptom onset, the damage to the spinal cord is almost irreversible and decompression—if at all—only partly attenuates the damage.

Hemostatic agents can be hypointense on T1- and T2-weighted imaging and may therefore be indistinguishable from (1) epidural hematoma or (2) a herniated disc on MRI [3]. In most of the literature, the “surgiceloma” was described as an extradural mass.

While careful hemostasis during spinal and thoracic procedures is mandatory, it is also necessary to remain mindful of the amount of hemostatic materials we leave in situ. Removal of hemostatic fabric after successful hemostasis can prevent debilitating complications.

B. Schatlo (✉) · A.-F. Eger · K. Schaller · E. Tessitore
Department of Neurosurgery, Faculty of Medicine,
Geneva University Hospital, 6, Rue Gabrielle Perret Gentil,
1211 Geneva, Switzerland
e-mail: schatlo@gmail.com

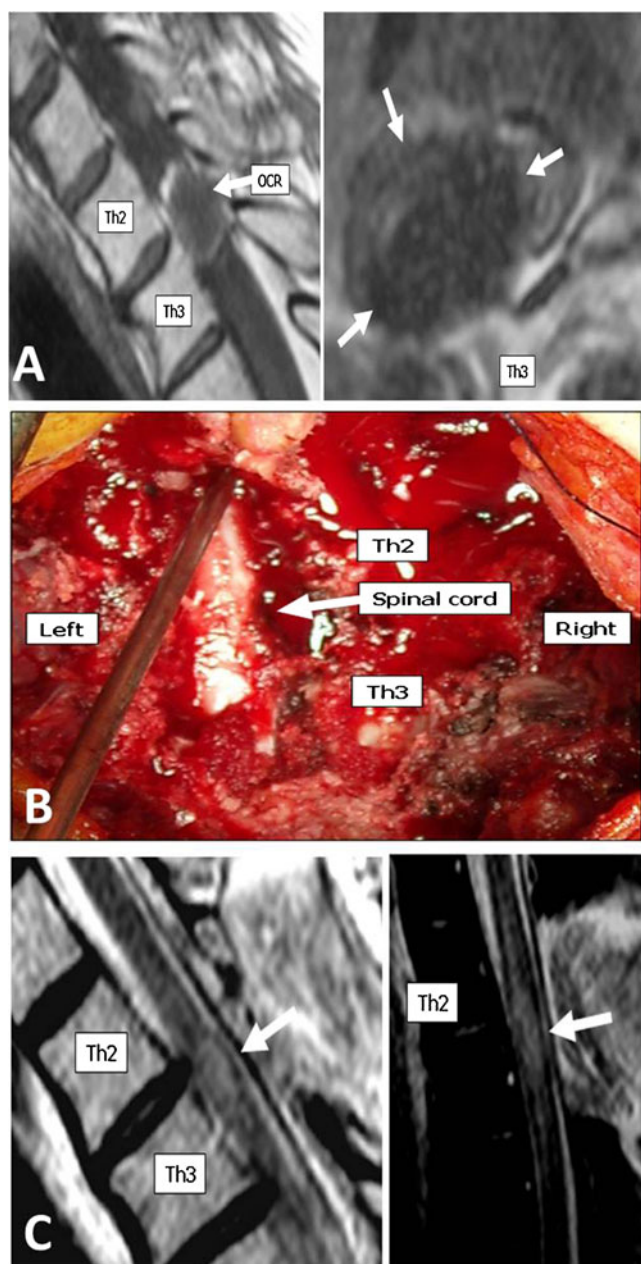


Fig. 1 **a** MRI scan on admission: On the left, T1-weighted sagittal view, the “surgiceloma” (OCR) is visible as a hypointense mass with a hyperintense ring filling the spinal canal at the Th2-Th3 level (*arrow*). On the axial T2-weighted view shown on the right, there is a hypointense mass that appears to fill the intervertebral foramen and partially the spinal canal on the right (*arrows*). **b** Surgical site after Th2-3 laminectomy. The spinal cord is visibly thinned out from the right as a result of severe compression. **c** One week following surgery, the spinal cord showed signs of permanent damage. Arrows indicate the affected area as a hyperintense signal on T2-weighted imaging (*left*) and as a hypersignal on standard inversion recovery T2-weighted imaging (*right*)

Conflicts of interest None

References

1. Dogan S, Kocaeli H, Doygun M (2005) Oxidised regenerated cellulose as a cause of paraplegia after thoracotomy: case report and review of the literature. *Spinal Cord* 43:445–447
2. Kothbauer KF, Jallo GI, Siffert J, Jimenez E, Allen JC, Epstein FJ (2001) Foreign body reaction to hemostatic materials mimicking recurrent brain tumor. Report of three cases. *J Neurosurg* 95:503–506
3. Partheni M, Kalogheropoulou C, Karageorgos N, Panagiotopoulos V, Voulgaris S, Tzortzidis F (2006) Radiculopathy after lumbar discectomy due to intraspinal retained Surgicel: clinical and magnetic resonance imaging evaluation. *Spine J* 6:455–458
4. Schonauer C, Tessitore E, Barbagallo G, Albanese V, Moraci A (2004) The use of local agents: bone wax, gelatin, collagen, oxidized cellulose. *Eur Spine J* 13(Suppl 1):S89–S96