



Article professionnel

Article

2001

Published version

Open Access

This is the published version of the publication, made available in accordance with the publisher's policy.

---

## Endoscopic Neck Dissection in Human Cadavers

---

Dulguerov, Pavel; Leuchter, Igor; Szalay, Ildiko; Allal, Abdelkarim Said; Marchal, Francis; Lehmann, Willy; Fasel, Jean

### How to cite

DULGUEROV, Pavel et al. Endoscopic Neck Dissection in Human Cadavers. In: The Laryngoscope, 2001, vol. 111, n° 12, p. 2135–2139. doi: 10.1097/00005537-200112000-00010

This publication URL: <https://archive-ouverte.unige.ch/unige:25953>

Publication DOI: [10.1097/00005537-200112000-00010](https://doi.org/10.1097/00005537-200112000-00010)

# Endoscopic Neck Dissection in Human Cadavers

Pavel Dulguerov, MD; Igor Leuchter, MD; Ildiko Szalay-Quinodoz, MD; Abdelkarim S. Allal, MD; Francis Marchal, MD; Willy Lehmann, MD; Jean H. D. Fasel, MD

**Objective:** To evaluate the feasibility and efficacy of endoscopic neck dissection (END) in human cadavers. **Study Design:** Experimental self-controlled study. **Methods:** END on five human cadavers through three openings: one for the camera, one for the dissecting instrument, and one for a grasping one. The tissue specimens removed were divided into traditional neck groups (I to V). After the completion of END, open neck dissection was performed using standard surgical techniques and the remaining tissue within each neck group was retrieved. The important neck structures (carotid artery, internal jugular vein, cranial nerves X, XI, and XII, phrenic nerve) were evaluated for lesions. A pathologist evaluated each specimen, without knowing its exact origin in terms of neck group or side, and type of surgical technique used. For each specimen, the number of retrieved lymph nodes and their anatomic integrity was analyzed. **Results:** Ten neck dissections were performed on 5 cadavers, without any major difficulty. An injury of the internal jugular vein occurred twice and once the phrenic nerve was cut. Little tissue was usually left for open surgical dissection. The average number of retrieved lymph nodes by endoscopy was  $4.9 \pm 2.7$  (mean  $\pm$  standard deviation). Completion open neck dissection retrieved an additional  $0.5 \pm 0.5$  lymph nodes. Efficacy of END was  $92 \pm 10\%$ . The majority of retrieved lymph nodes were intact but exhibited important postmortem autolysis artifacts. **Conclusions:** Endoscopic neck dissection is possible in human cadavers and is free of lesions to major structures. The majority of neck lymph nodes can be removed endo-

scopically. **Key Words:** Neck dissection, endoscopy, experimental, surgical technique.

*Laryngoscope*, 111:2135–2139, 2001

## INTRODUCTION

The extent and morbidity of neck dissection has steadily decreased over the last several decades. The radical neck dissection described by Crile<sup>1</sup> and popularized by Martin<sup>2</sup> has progressively been replaced by “functional”<sup>3,4</sup> and selective neck dissections,<sup>5,6</sup> without compromising the oncologic outcome.

Endoscopic neck surgery is a new set of surgical procedures, aiming at removing cervical pathologic structures through small incisions with endoscopic instruments and techniques (for review, see Dulguerov<sup>7</sup>). While the exact indications of endoscopic neck surgery remain to be defined, it has the potential of spanning the majority of the spectrum of traditional neck surgery. Gagner<sup>8</sup> was the first to report on an endoscopic procedure within the neck in 1996: he removed hypertrophic parathyroid glands for hyperparathyroidism. Since then, few reports have been published on human endoscopic thyroid<sup>9–13</sup> and parathyroid<sup>10,14–18</sup> surgery. These studies report on a total of 53 thyroidectomies<sup>9–11</sup> and 102 parathyroidectomies<sup>8,10,14–16,19–22</sup> completed successfully in humans.

Endoscopically assisted surgery<sup>23–26</sup> is a different approach in which a relative large incision (3 cm or more) is made and retraction is provided with various instruments, which could resemble modified laryngoscopes. The use of these instruments can be seen as a backward step from typical endoscopic surgery techniques or as a prudent intermediate progression step before adopting formal endoscopic techniques. The description in early publications on human<sup>8,14,15,27–29</sup> and animal<sup>27,29,30</sup> thyroid and parathyroid surgery of serious side effects related to the high pressure CO<sub>2</sub> insufflation required to maintain a closed working cavity could be a possible explanation.

Until recently,<sup>31</sup> no study had directly addressed the possibility of an endoscopic neck dissection (END) in animals or humans. Our initial attempts of END in an animal model were encouraging.<sup>31</sup> In that study, an

Presented at the 104th Annual Meeting of the Triological Society, Palm Desert, CA, May 16, 2001.

From the Division of Head and Neck Surgery (P.D., I.L., F.M., W.L.), the Department of Pathology (I.S.-Q.), the Division of Radio-Oncology (A.S.A.), and the Department of Anatomy (J.H.D.F.), Geneva University Hospital, Geneva, Switzerland.

Funded provided by the Carlos et Elsie de Reuter Foundation, Geneva, Switzerland.

Editor's Note: This Manuscript was accepted for publication August 2, 2001.

Send Correspondence to Pavel Dulguerov, MD, Division of Head and Neck Surgery, Geneva University Hospital, 24, rue Micheli-du-Crest, 1211 Geneva 14, Switzerland. E-mail: pavel.dulguerov@hcuge.ch

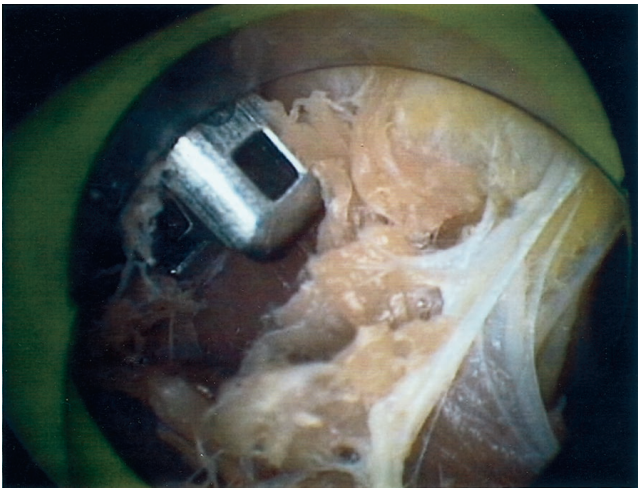


Fig. 1. Endoscopic view at the beginning of the procedure. The view is limited and obscured by numerous fibrous tissue strands. The initial purpose is to create tunnels to bring the dissecting (shown) and grasping instruments in full view.

END was performed on mini-pigs and was followed by an open traditional surgical neck dissection (OND). A pathologic evaluation, blinded to the exact origin of the specimen, revealed an efficacy of  $88 \pm 10\%$  (mean  $\pm$  standard deviation) of END when compared with OND.<sup>31</sup> Similar methodology and techniques were used in this study in human cadaver specimens.

#### METHODS

Five unembalmed human cadavers, donated for scientific teaching purposes to the Division of Anatomy of the University of Geneva, were used (3 women and 2 men, age at death: range 63–89 y, mean 81 y). In one case, the neck arteries and veins were injected with colored latex for iconographic purposes. To do so, the three main branches of the aortic arch and the superior vena cava were selectively injected. On all corpses, bilateral neck procedures were performed.

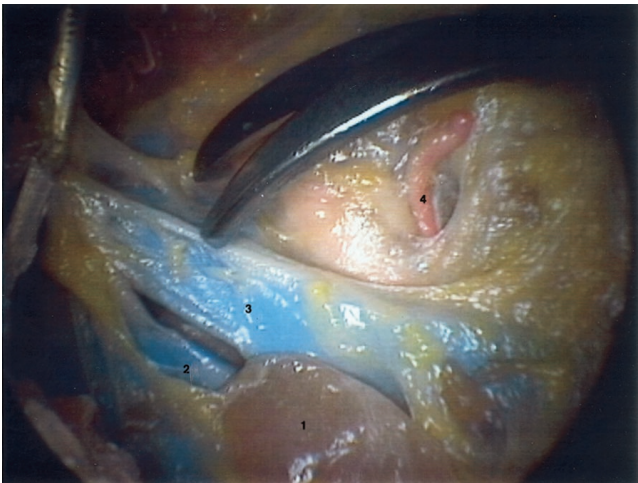


Fig. 2. Endoscopic view of a working cavity. The grasping instrument, in the upper left corner, and the scissors are seen. 1 = sectioned omohyoid muscle; 2 = internal jugular vein; 3 = anterior jugular vein; 4 = superior thyroid artery.

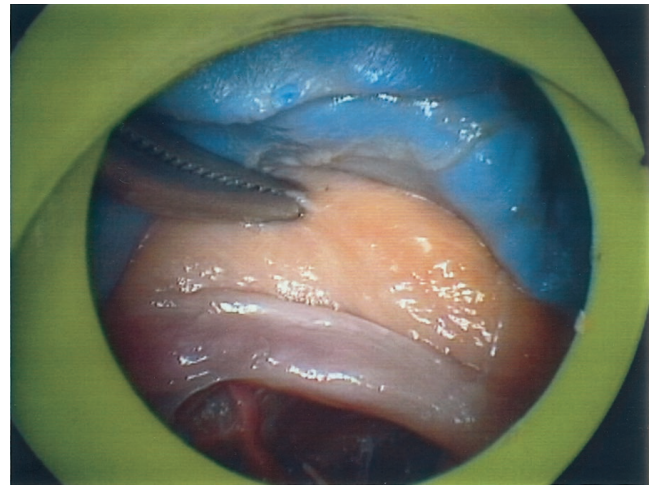


Fig. 3. Dissection of the structures of the carotid space. From top to bottom, internal jugular vein, carotid artery, and vagus nerve.

Three trocars were used for END: two were 10 mm and one was 5 mm in diameter. A placement, similar to the animal studies,<sup>31</sup> was found optimal: the optic-camera trocar was placed in the lateral aspect of the neck, in front of the sternocleidomastoid muscle, at the level of the mid-neck. The placement of the other two trocars was closer to the midline in regions roughly corresponding to level II and IV. The larger trocar was on the side of the nondominant hand of the surgeon. It was used for the passage of grasping instruments and removal of the resected neck tissue. The smaller trocar was used for the passage of scissors or other dissecting instruments.

At the beginning of the surgery, a working cavity was created by blunt dissection, initially with scissors around the trocar, followed by a dissection with a blunt tip dissector. This was performed through the optic trocar and allowed the introduction of the other trocars under direct vision. The created cavity was

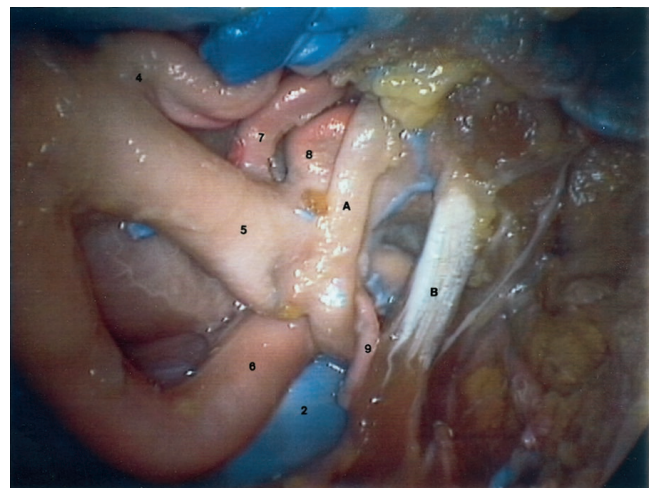


Fig. 4. Endoscopic view of the carotid bifurcation area. 2 = internal jugular vein; 4 = superior thyroid artery; 5 = external carotid artery; 6 = internal carotid artery; 7 = lingual artery; 8 = facial artery; 9 = sternomastoid branch of occipital artery (cut after crossing the hypoglossal nerve); A = hypoglossal nerve; B = posterior belly of the digastric muscle.

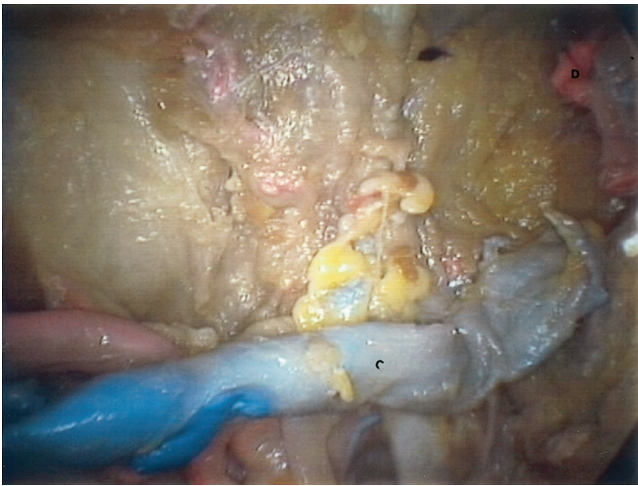


Fig. 5. Group I after dissection. The salivary glands in the cadaver are mostly autolyzed. C = facial vein; D = cut superior edge of facial artery.

maintained by trocars that allowed upward traction (OMS T12BT, Origin Medical Systems, Menlo Park, CA).

Endoscopic surgical techniques used during neck dissection involved pediatric surgery endoscopic instruments, usually grasping the fibrofatty lymphatic bearing tissue with a grasping forceps for retraction, while different instruments were used for blunt dissection and scissors for cutting under direct vision. Using these endoscopic surgical techniques, dissection of the different neck levels was performed and the tissue removed from each level labeled as a different specimen. Each specimen represented a thorough dissection of a given neck level, including the fibrofatty tissue, rather than node plucking. After completion of the endoscopic dissection, the neck skin was opened and traditional surgical techniques were used to remove the remaining tissue within each level.

The specimens retrieved from 4 cadavers (8 neck dissections) were sent to the pathologist who examined these specimens in a blinded fashion, not knowing if the neck tissue was from an endoscopic or surgical neck dissection. Assessment of the number

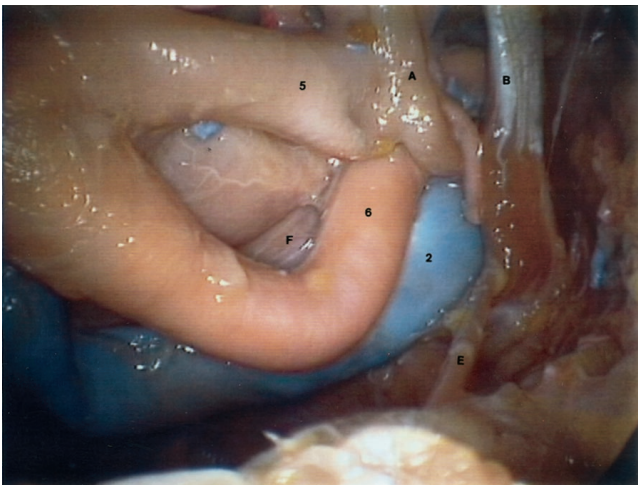


Fig. 6. Group II after dissection. 2 = internal jugular vein; 5 = external carotid artery; 6 = internal carotid artery; A = hypoglossal nerve; B = digastric muscle; E = spinal nerve; F = vagus nerve.

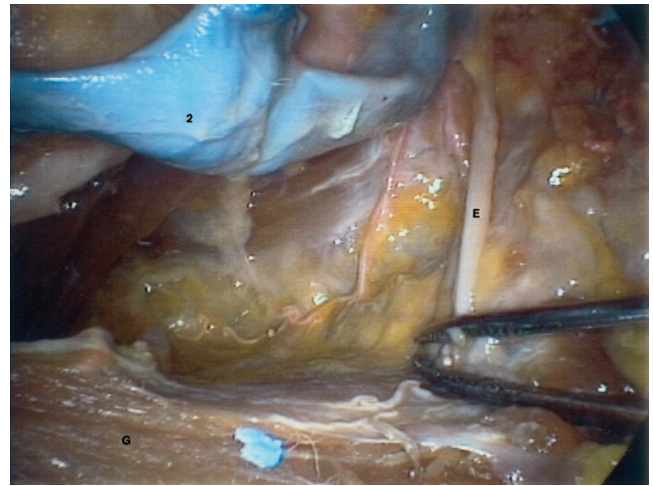


Fig. 7. Groups III and IV after dissection. 2 = internal jugular vein; E = spinal nerve; G = sternocleidomastoid muscle.

of removed neck lymph nodes within each specimen was performed. In addition, the pathologist estimated the degree of trauma of the nodes and their anatomic integrity, as well as the histology of the remaining structures found within each specimen.

Statistical comparison of the number of nodes was carried out with the Fisher's exact test as implemented in the SPSS software package (version 9.0, Chicago, IL).

## RESULTS

In 5 cadavers 10 neck dissections were performed, 5 on the right and 5 on the left side. The visualization during the procedure was excellent and Figures 1 through 8 show the aspect of the dissected neck during END at different stages.

During END, there were no lesions of major structures such as rupture of carotid artery or lesion of the vagus, spinal, or hypoglossal nerves. However, in 2 of the early neck dissections, lesions of internal jugular vein

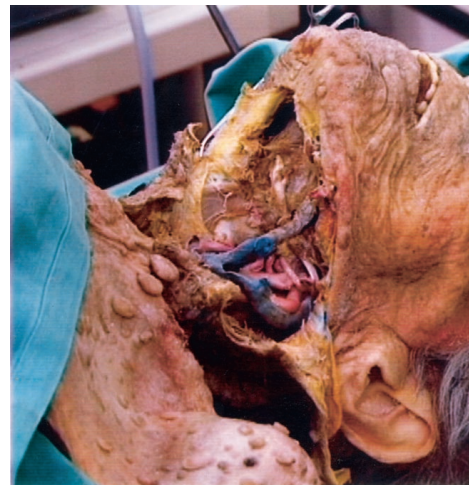

Fig. 8. View after the END is completed and the cadaver skin is opened. The patient had neurofibromatosis. A good view of the dissection in groups I, II, and III is present.

were found and in one instance the phrenic nerve could not be identified.

The average total number of retrieved lymph nodes by END was  $5.75 \pm 2.06$  in 5 right END and  $4.0 \pm 3.27$  in the 5 left END. The completion OND revealed an additional  $0.5 \pm 0.58$  lymph nodes on both the right and left sides. Therefore, the efficacy of END in terms of lymph node retrieval was  $92 \pm 10\%$  on both the right and left sides.

The data for each neck level are presented in Table I. The average number of lymph nodes removed by END and OND for levels I, II, III, IV, and V were respectively 0.5 and 0.14, 0.75 and 0.13, 0.88 and 0.0, 0.5 and 0.13, 2.25 and 0.13. For each neck lymph node level, the efficacy of lymph node retrieval by END was between 80% and 100%.

According to the pathologist, only 2 lymph nodes exhibited mechanical trauma (crushing artifacts), one removed by END and one by OND. However, the majority of lymph nodes presented an advanced degree of autolysis. The average size of the removed lymph nodes was 0.5 cm. Besides lymph nodes, various quantities of adipose tissue were present in the specimen, accompanied in few instances by salivary gland or muscle tissue.

## DISCUSSION

This study extends the encouraging data obtained for END in an animal model.<sup>31</sup> The visualization during the procedure was excellent, mainly because of the lack of bleeding, but also because of the magnification provided by the optical system. No lesions of the major neck structures occurred during END, except for the mentioned lesions of the internal jugular vein. This is most probably the result of the collapsed, narrow aspect of this structure in cadavers and the fact that we were initially looking for a larger vessel. However, only the application of END in patients could verify that such injury could be prevented.

We are somewhat disappointed by the low number of retrieved lymph nodes. However, the explanation lies in the advanced age of the subjects (mean age at death, 81 y) and the important postmortem autolysis. Nevertheless, the neck fibrofatty tissue was completely removed (Fig. 8)

when inspected by OND. In addition, the yield in terms of endoscopically retrieved lymph nodes, relative to the total lymph nodes removed, was similar to our previous animal experiments: the efficiency of END was between 85% and 95% for all neck levels.

The lack of bleeding in cadavers and the more familiar human neck anatomy made END in human cadavers much easier than similar surgery in the porcine animal model.<sup>31</sup> However, alive patients do bleed, and head and neck surgeons should undertake END in patients only after mastering thoroughly endoscopic knot tying to handle endoscopically potential bleeding sources. For any type of endoscopic surgery, such as laparoscopy or endoscopic sinus surgery, bleeding is a major technical problem because it hampers visualization and its handling could result in damaging vital nearby structures by intempestive coagulation. In our preliminary attempts of END in alive patients (unpublished data), we encountered bleeding from the beginning of the procedure, during the creation of a working cavity, rendering initial attempts of END frustrating.

Before embarking on END in patients, surgeons should also be familiar with the large number of complications, often fatal, described in the early literature on human<sup>8,14,15,27-29</sup> and animal<sup>27,29,30</sup> thyroid and parathyroid surgery. Some of the serious side effects, such as arterial and venous injuries, are probably the result of lack of familiarity with endoscopic techniques and have become infrequent. Others, such as pneumothorax, are related to the high pressure CO<sub>2</sub> insufflation used to maintain a closed working cavity. Because of the danger of pneumothorax, level IV nodes should be addressed at the end of the procedure when significant air leak is present around the trocars.<sup>31</sup> An even better alternative is to use upward traction and not to rely heavily on gas insufflation.<sup>7,11,30</sup>

While the possible applications of endoscopic neck surgical techniques are speculative, we tend to position endoscopic neck surgery for intermediate size lesions, such as submandibular gland and branchial cleft cysts removal. In addition, endoscopic thyroidectomy and parathyroidectomy seem to be increasingly performed, as reviewed earlier. Probably the association of END with the

TABLE I.  
Number of Lymph Nodes Retrieved by Endoscopic Neck Dissection and Open Surgical Neck Dissection.

No.	END/OND												% END/Total	
	Level I		Level II		Level III		Level IV		Level V		TOTAL			
	Right	Left	Right	Left	Right	Left	Right	Left	Right	Left	Right	Left	Right	Left
1	1/0	1/0	2/1	0/0	0/0	1/0	0/0	0/0	4/0	2/1	7/1	4/1	88%	80%
2	0/0	0/0	0/0	0/0	0/0	0/0	0/0	0/0	4/0	0/0	4/0	0/0	100%	100%
3	1/0	0/1	1/0	3/0	4/0	0/0	2/0	0/0	0/0	5/0	8/0	8/1	100%	89%
4	1/0	0/0	0/0	0/0	2/0	0/0	1/1	1/0	0/0	3/0	4/1	4/0	80%	100%
Total	3/0	1/1	3/1	3/0	6/0	1/0	3/1	1/0	8/0	10/1	23/2	16/2		
Mean	0.75/0.0	0.25/0.25	0.75/0.25	0.75/0.0	1.5/0.0	0.25/0.0	0.75/0.25	0.25/0.0	2.0/0.0	2.50/0.25	5.75/0.50	4.0/0.50	0.92	0.92
SD	0.50/0.0	0.50/0.50	0.96/0.50	1.5/0.0	1.9/0.0	0.50/0.0	0.96/0.50	0.50/0.0	2.31/0.0	2.08/0.50	2.06/0.58	3.27/0.58	0.10	0.10

END = endoscopic neck dissection; OND = open surgical neck dissection.

mapping of sentinel nodes<sup>32-34</sup> could allow for the evaluation of the neck status with minimal morbidity before the final treatment decision is taken. The precise knowledge of the neck status can dramatically alter the treatment protocols and decrease the morbidity associated with these treatments.

However, before applying endoscopic neck surgical techniques to human neck pathologies, extensive training with endoscopic surgical techniques in closed cavities is mandatory. Like all new and involved surgical techniques, endoscopic neck dissection is time consuming initially and there is certainly a learning curve. Whether this technique is worthwhile in terms of operating room time, complications, and morbidity remains to be determined.

## BIBLIOGRAPHY

- Crile G. Excision of cancer of the head and neck. *JAMA* 1906;47:1780-1788.
- Martin H, Del Valle B, Ehrlich H, Cahan WG. Neck dissection. *Cancer* 1951;4:441-499.
- Suarez O. El problema se las metastasis linfaticas y alejadas del cancer de laringe e hipofaringe. *Revista Otorhinolaringol* 1963;23:83-89.
- Bocca E, Pignataro O, Oldini C. Functional neck dissection: an evaluation and review of 843 cases. *Laryngoscope* 1984;94:942-945.
- Pitman KT, Johnson JT, Myers EN. Effectiveness of selective neck dissection for management of the clinically negative neck. *Arch Otolaryngol Head Neck Surg* 1997;123:917-922.
- Ambrosch P, Kron M, Pradier O, Steiner W. Efficacy of selective neck dissection: a review of 503 cases of elective and therapeutic treatment of the neck in squamous cell carcinoma of the upper aerodigestive tract. *Otolaryngol Head Neck Surg* 2001;124:180-187.
- Dulguerov P. Endoscopic neck surgery. In: Wackym PA, Rice DH, Schaefer SD, eds. *Minimally Invasive Surgery of the Head, Neck, and Skull Base*. Philadelphia: Lippincott-Raven Publishers, 2001.
- Gagner M. Endoscopic subtotal parathyroidectomy in patients with primary hyperparathyroidism. *Br J Surg* 1996;83:875.
- Huscher CS, Chiodini S, Napolitano C, Recher A. Endoscopic right thyroid lobectomy. *Surg Endosc* 1997;11:877.
- Yeung GH, Ng JW. The technique of endoscopic exploration for parathyroid adenoma of the neck. *Aust N Z J Surg* 1998;68:147-150.
- Shimizu K, Akira S, Jasmi AY, et al. Video-assisted neck surgery: endoscopic resection of thyroid tumors with a very minimal neck wound. *J Am Coll Surg* 1999;188:697-703.
- Miccoli P, Berti P, Bendinelli C, Conte M, Fasolini F, Martino E. Minimally invasive video-assisted surgery of the thyroid: a preliminary report. *Langenbecks Arch Chir* 2000;385:261-264.
- Gagner M, Inabnet WB III. Endoscopic thyroidectomy for solitary thyroid nodules. *Thyroid* 2001;11:161-163.
- Naitoh T, Gagner M, Garcia-Ruiz A, Heniford BT. Endoscopic endocrine surgery in the neck. An initial report of endoscopic subtotal parathyroidectomy. *Surg Endosc* 1998;12:202-205.
- Miccoli P, Bendinelli C, Vignali E, et al. Endoscopic parathyroidectomy: report of an initial experience. *Surgery* 1998;124:1077-1079.
- Dralle H, Lorenz K, Nguyen-Thanh P. Minimally invasive video-assisted parathyroidectomy—selective approach to localized single gland adenoma. *Langenbecks Arch Chir* 1999;384:556-562.
- Baca I, Jacek G, Grzybowski L. Endoscopic parathyroidectomy. Surgical technique in primary hyperparathyroidism. *Zentralbl Chir* 2000;125:916-919.
- Kitano H, Fujimura M, Hirano M, et al. Endoscopic surgery for a parathyroid functioning adenoma resection with the neck region-lifting method. *Otolaryngol Head Neck Surg* 2000;123:465-466.
- Cougard P, Goudet P, Osmak L, Ferrand L, Letourneau B, Brun JM. La vidéocervicoscopie dans la chirurgie de l'hyperparathyroïdie primitive. Etude préliminaire portant sur 19 patients. *Ann Chir* 1998;52:885-889.
- Chowbey PK, Mann V, Khullar R, Sharma A, Baijal M, Vashistha A. Endoscopic neck surgery: expanding horizons. *J Laparoendosc Surg* 1999;9:397-400.
- Miccoli P, Bendinelli C, Berti P, Vignali E, Pinchera A, Marcocci C. Video-assisted versus conventional parathyroidectomy in primary hyperparathyroidism: a prospective randomized study. *Surgery* 1999;126:1117-1121.
- Peix JL, el Khazen M, Mancini F, Binet A, Berger N, Lapras V. Les opérations pour hyperparathyroïdie primaire en 1998. A propos de 66 patients et de trois voies d'abord. *Ann Chir* 2000;125:346-352.
- Bellantone R, Lombardi CP, Raffaelli M, Rubino F, Boscherini M, Perilli W. Minimally invasive, totally gasless video-assisted thyroid lobectomy. *Am J Surg* 1999;177:342-343.
- Gauger PG, Reeve TS, Delbridge LW. Endoscopically assisted, minimally invasive parathyroidectomy. *Br J Surg* 1999;86:1563-1566.
- Henry JF, Defechereux T, Gramatica L, de Boissezon C. Minimally invasive videoscopic parathyroidectomy by lateral approach. *Langenbecks Arch Chir* 1999;384:298-301.
- Yeh TS, Jan YY, Hsu BR, Chen KW, Chen MF. Video-assisted endoscopic thyroidectomy. *Am J Surg* 2000;180:82-85.
- Brunt LM, Jones DB, Wu JS, Quasebarth MA, Meininger T, Soper NJ. Experimental development of an endoscopic approach to neck exploration and parathyroidectomy. *Surgery* 1997;122:893-901.
- Gottlieb A, Sprung J, Zheng XM, Gagner M. Massive subcutaneous emphysema and severe hypercarbia in a patient during endoscopic transcervical parathyroidectomy using carbon dioxide insufflation. *Anesth Analg* 1997;84:1154-1156.
- Carreno OJ, Wilson WR, Nootheti PK. Exploring endoscopic neck surgery in a porcine model. *Laryngoscope* 1999;109:236-240.
- Jones DB, Quasebarth MA, Brunt LM. Videoendoscopic thyroidectomy: experimental development of a new technique. *Surg Laparosc Endosc* 1999;9:167-170.
- Dulguerov P, Vaezi AE, Belenger J, et al. Endoscopic neck dissection in an animal model: comparison of nodal yield with open-neck dissection. *Arch Otolaryngol Head Neck Surg* 2000;126:417-420.
- Cabanas RM. An approach for the treatment of penile carcinoma. *Cancer* 1977;39:456-466.
- Morton DL, Wen DR, Wong JH, et al. Technical details of intraoperative lymphatic mapping for early stage melanoma. *Arch Surg* 1992;127:392-399.
- Dulguerov P, Leuchter I, Lehmann W, Allal AS. The sentinel lymph node—theoretical considerations. *Adv Cancer Res*. Submitted for publication.