



Article scientifique

Article

2022

Published version

Open Access

This is the published version of the publication, made available in accordance with the publisher's policy.

Second consensus document on diagnosis and management of acute deep vein thrombosis: updated document elaborated by the ESC Working Group on aorta and peripheral vascular diseases and the ESC Working Group on pulmonary circulation and right ventricular function

Mazzolai, Lucia; Ageno, Walter; Alatri, Adriano; Bauersachs, Rupert; Becattini, Cecilia; Brodmann, Marianne; Emmerich, Joseph; Konstantinides, Stavros; Meyer, Guy; Middeldorp, Saskia; Monreal, Manuel; Righini, Marc Philip; Aboyans, Victor

How to cite

MAZZOLAI, Lucia et al. Second consensus document on diagnosis and management of acute deep vein thrombosis: updated document elaborated by the ESC Working Group on aorta and peripheral vascular diseases and the ESC Working Group on pulmonary circulation and right ventricular function. In: European journal of preventive cardiology, 2022, vol. 29, n° 8, p. 1248–1263. doi: 10.1093/eurjpc/zwab088

This publication URL: <https://archive-ouverte.unige.ch/unige:161630>

Publication DOI: [10.1093/eurjpc/zwab088](https://doi.org/10.1093/eurjpc/zwab088)

Second consensus document on diagnosis and management of acute deep vein thrombosis: updated document elaborated by the ESC Working Group on aorta and peripheral vascular diseases and the ESC Working Group on pulmonary circulation and right ventricular function

Lucia Mazzolai ^{1*}, **Walter Ageno**², **Adriano Alatri**¹, **Rupert Bauersachs**^{3,4}, **Cecilia Becattini**⁵, **Marianne Brodmann**⁶, **Joseph Emmerich**⁷, **Stavros Konstantinides**^{4,8}, **Guy Meyer**[†], **Saskia Middeldorp**⁹, **Manuel Monreal**¹⁰, **Marc Righini**¹¹, and **Victor Aboyans**¹²

¹Division of Angiology, Heart and Vessel Department, Lausanne University Hospital, Chemin de Mont-Paisible 18, CH-1011 Lausanne, Switzerland; ²Department of Medicine and Surgery, University of Insubria, Via Ravasi 2, 21100 Varese, Italy; ³Department of Vascular Medicine, Klinikum Darmstadt GmbH, Grafenstraße 9, 64283 Darmstadt, Germany; ⁴Departement of Vascular Medicine, Center for Thrombosis and Hemostasis, University Medical Center Mainz, Langenbeckstr. 1, 55131 Mainz, Germany; ⁵Departement of Internal and Cardiovascular Medicine—Stroke Unit, University of Perugia, Perugia, Italy; ⁶Département of Internal Medicine, Division of Angiology, Medical University Graz, Graz, Austria; ⁷Department of Vascular Medicine, Groupe Hospitalier Paris Saint-Joseph and University of Paris, Paris, France; ⁸Department of Cardiology, Democritus University of Thrace, Alexandroupolis, Greece; ⁹Department of Vascular Medicine, Amsterdam UMC, University of Amsterdam, Amsterdam Cardiovascular Sciences, Amsterdam, The Netherlands; ¹⁰Department of Internal Medicine, Hospital Germans Trias i Pujol, Universidad Autónoma de Barcelona, Badalona, Barcelona, Spain; ¹¹Division of Angiology and Hemostasis, Department of Internal Medicine, Geneva University Hospital, Geneva, Switzerland; and ¹²Department of Cardiology, Dupuytren University Hospital and Inserm 1094, Tropical Neuroepidemiology, School of Medicine, 2 avenue martin Luther-King 87042 Limoges, France

Received 19 October 2020; revised 25 February 2021; editorial decision 5 May 2021; accepted 7 May 2021; online publish-ahead-of-print 13 July 2021

This consensus document is proposed to clinicians to provide the whole spectrum of deep vein thrombosis management as an update to the 2017 consensus document. New data guiding clinicians in indicating extended anticoagulation, management of patients with cancer, and prevention and management of post-thrombotic syndrome are presented. More data on benefit and safety of non-vitamin K antagonists oral anticoagulants are highlighted, along with the arrival of new antidotes for severe bleeding management.

Keywords

Consensus • Deep vein thrombosis • Ultrasound • Anticoagulation • Diagnosis • Pulmonary embolism
• Cancer • Post-thrombotic syndrome • Catheter-directed thrombolysis • Pregnancy • Risk • Compression

* Corresponding author. Tel: +41 21 3140768; +41 795565661, Email: lucia.mazzolai@chuv.ch

[†]Deceased.

© The Author(s) 2021. Published by Oxford University Press on behalf of the European Society of Cardiology.

This is an Open Access article distributed under the terms of the Creative Commons Attribution Non-Commercial License (<http://creativecommons.org/licenses/by-nc/4.0/>), which permits non-commercial re-use, distribution, and reproduction in any medium, provided the original work is properly cited. For commercial re-use, please contact journals.permissions@oup.com

Summary of consensus statements

DVT diagnosis

Revised. Clinical prediction rule (two-level modified Wells score, [Supplementary material online, Table S1](#)) should be used to stratify patients with suspected DVT

Revised. ELISA D-dimer or highly sensitive immunoturbidimetric tests should be measured in 'unlikely' clinical probability patients to exclude DVT diagnosis

Venous US is recommended as first-line imaging method for DVT diagnosis

Venous CT scan should be reserved to selected patients only

Venous US may be proposed also in case of confirmed PE, for initial reference venous imaging, useful in case of DVT recurrence suspicion or further stratification in selected patients

Venous US may be considered for further severity stratification in selected patients with concomitant suspected PE

Initial and long-term DVT management

Patients with proximal DVT should be anticoagulated for at least 3 months

Patients with isolated distal DVT at high risk of recurrence should be anticoagulated, as for proximal DVT; for those at low risk of recurrence shorter LMWH treatment (4–6 weeks), even at lower anticoagulant doses, or ultrasound surveillance may be considered

In non-cancer patients

- NOACs should be preferred as first-line anticoagulant therapy in absence of contraindications
- *New.* If a parenteral agent is used, LMWH should be preferred over UFH for the initial treatment

New. In cancer patients:

- LMWH should be preferred over UFH for initial treatment
- LMWH is recommended over VKA for long-term treatment
- Edoxaban and rivaroxaban should be considered as an alternative to LMWH for initial and long-term treatment in patients without gastrointestinal or urothelial cancer. Caution should be made for any potential drug interaction with anti-cancer therapy
- Apixaban should be considered as an alternative to LMWH for initial and long-term treatment in patients without primary or metastatic brain cancer or acute leukaemia. Caution should be made for any potential drug interaction with anti-cancer therapy
- LMWH is preferred over NOACs for initial and long-term treatment in cancer patients, with unstable clinical situations, such as low platelet count, nausea, and vomiting, and a risk of expected drug interactions with the anti-cancer therapy as well as those undergone surgery involving the upper gastrointestinal tract

New. Anticoagulant choice should include patient's preference, and may include cost, mode of administration, and monitoring options

Revised. Adjuvant catheter-directed thrombolysis should not be routinely performed and be reserved for individual and very severe cases and performed in experienced centres

Primary acute DVT stenting or mechanical thrombus removal alone are not recommended

Revised. Vena cava filters should be considered if anticoagulation is absolutely contraindicated or in case of recurrent VTE event under adequate therapeutic anticoagulation

Revised. In patients with proximal DVT, immediate (<24 h from diagnosis) compression therapy associated with early mobilization and walking exercise may be proposed to relieve acute venous symptoms

Extended management (>first 3 months) of DVT (without PE)

Revised. When deciding for extended anticoagulation, individual risk assessment should be proposed for all DVT patients, also taking into account patients' preferences, compliance, and impact of long-term DVT complications. For this purpose scores may be helpful in risk stratification

New. In patients at low risk of recurrence (Table 5), anticoagulation discontinuation should be proposed

New. In patients at intermediate risk of recurrence (Table 5), anticoagulation extension should be considered, provided bleeding risk is low

New. Currently, reduced-dose apixaban and rivaroxaban have shown their benefit in patients at intermediate risk of recurrence

New. In patients at high risk or variable higher risk of recurrence (Table 5), anticoagulation should be continued, provided bleeding risk is low

In absence of contraindications, NOACs should be preferred as first-line extended anticoagulant therapy in non-cancer patients, except in patients with antiphospholipid syndrome

New. In patients with antiphospholipid syndrome, anticoagulation extension with VKA is recommended

New. In absence of contraindications, full-dose oral anticoagulants may be proposed in active cancer patients after 6 months treatment

When VKAs are proposed, they should be administered at conventional intensity regimen (INR 2–3)

New. Patients on extended anticoagulation, should be assessed regularly (at least yearly) for patient preference, benefit/risk balance, and PTS development monitoring

At anticoagulation discontinuation, venous US should be performed to establish a baseline comparative exam in case of recurrence

New. Use of elastic compression stocking should be individualized

New. Endovascular recanalization may be considered on an individual base in patients with chronic venous occlusion provided dedicated venous material is used in expert centres

DVT management in special situations

Revised. In case of upper extremity deep vein thrombosis (UEDVT) suspicion, venous US is the first choice imaging test; if negative, CT venography should be performed

Treatment of UEDVT is similar to that of lower limb DVT with regard to anticoagulation

New. In case of catheter-related thrombosis, the catheter may be kept in place if it is functional, well positioned, and non-infected

Revised. For acute (up to 15 days) treatment of cerebral vein thrombosis LMWH should be proposed

Revised. For long-term treatment of cerebral vein thrombosis dabigatran or VKA should be suggested

LMWH are recommended for acute treatment of splanchnic vein thrombosis

New. VKA should be proposed for long-term treatment of splanchnic vein thrombosis

New. LMWH may be proposed for long-term treatment of splanchnic vein thrombosis in selected cases (cirrhosis, solid cancer, or high risk of bleeding)

DVT in pregnancy, oral contraception, and thrombophilia

Revised. Venous US including visualization of iliac veins is recommended as first-line DVT imaging test

During pregnancy, LMWH should be proposed for initial and long-term treatment

Revised. Anticoagulant treatment should be continued until 6 weeks after delivery and at least for 3 months

New. Non-hormonal contraception, a levonorgestrel intrauterine device, the progestogen-only pill, or a subcutaneous progestogen implant are safe with regard to DVT risk

New. Routine anti-Xa monitoring and dose adaptation is not recommended in pregnant patients

New. Testing for thrombophilia should be reserved for situations where results would change management

Introduction

This consensus on diagnosis and management of deep vein thrombosis (DVT)¹ is proposed to clinicians as an update to the 2017 consensus document and a companion paper to the 2019 ESC guidelines on diagnosis and management of pulmonary embolism (PE)² in order to provide the whole spectrum of management of patients with venous thromboembolic disease (VTE). Management of DVT has similarities with that of PE, however, many diagnostic and therapeutic features

present particularities which have recently been subject to a high flow of new evidence, justifying the need for an update of the previous document,¹ with a timely publication along with the new ESC PE guidelines.² Of importance, this document integrates new data guiding clinicians deciding for extended anticoagulation, management of patients with cancer, prevention and management of post-thrombotic syndrome (PTS), management of bleeding during anticoagulation, and management of DVT in pregnancy (including hormone-related DVT and thrombophilia). More data on benefit and security of non-vitamin K antagonists oral

anticoagulants (NOACs) are highlighted, along with the arrival of new antidotes for the management of severe bleeding. On behalf of the two ESC working groups, authors emphasize the multidisciplinary approach for comprehensive management of both aspects of VTE, which may occur in a same patient, simultaneously, or over time. In line with ESC documents, the term NOAC is used instead of direct oral anticoagulant.

Deep vein thrombosis risk factors

Cohort studies indicate that in as much as 50% of DVT no identifiable risk factors are found.³ Risk factors (Table 1) can be distinguished as major (strong association with index DVT; likely responsible of index event), intermediate (moderate association with index DVT, probably responsible of index event), or minor (weak association with index VTE; might partly explain index event).⁴ Categorization of index event is important for determining recurrence risk and patient management. An emerging thrombotic risk factor is represented by the coronavirus disease 2019 (COVID-19). COVID-19 infection often results in a hypercoagulable state with high incidence of venous and arterial thromboembolic events, frequently despite antithrombotic prophylaxis.⁵ A recent meta-analysis evaluated 48 observational studies reporting VTE incidence among hospitalized patients for COVID-19.⁶ Based on a pooled sample of 18 093 patients, overall VTE incidence was 17.0%, with 7.1% in patients

admitted to the ward and 27.9% in patients admitted to the intensive care unit.⁶ Therefore, hospitalized patients with COVID-19 infection should be considered at intermediate-high risk for VTE.

Deep vein thrombosis diagnosis

There have been no major changes in this section from the 2017 version.¹ Figure 1 summarizes diagnostic strategies in case of DVT suspicion. In case of concomitant signs suspect for PE, diagnostic strategies should follow the 2019 ESC guidelines on PE diagnosis and management.²

Initial (first days) and long-term (first 3 months) deep vein thrombosis management

Three phases characterize DVT management (Figure 2): initial (first days), long-term (first 3 months), and extended (following the initial 3-month treatment period).¹ Current anticoagulation strategies differ when DVT is diagnosed in cancer patients as compared to those without active cancer.

Table 1 Deep vein thrombosis risk factors

Risk factors	
Strong risk factors (OR ≥ 10)	<ul style="list-style-type: none"> • Major surgery (orthopaedic and neurological)/major trauma • Recent (<3 months) hospitalization for acute heart disease • Prior venous thromboembolism • Antiphospholipid syndrome • Active cancer (depends on type and stage)/chemotherapy
Moderate risk factors (OR 2–9)	<ul style="list-style-type: none"> • Arthroscopic knee surgery • Venous catheters • Oral contraception/hormone replacement therapy/<i>in vitro</i> fertilization (depends on dose and type of hormone) • Pregnancy or postpartum period • Inflammatory and autoimmune diseases • Infections • Active cancer (depends on type and stage)/chemotherapy • Congestive heart or respiratory failure • Genetic thrombophilia • Superficial vein thrombosis (>3 cm from SFJ or PJ and >5 cm length) • Stroke with residual hemiparesis/hemiplegia
Weak risk factors (OR < 2)	<ul style="list-style-type: none"> • Bed rest (>3 days)/immobility (prolonged sitting position, i.e. travel) • Age • Obesity • Superficial vein thrombosis • Varicose veins/chronic vein insufficiency • Laparoscopic surgery

OR, odds ratio.

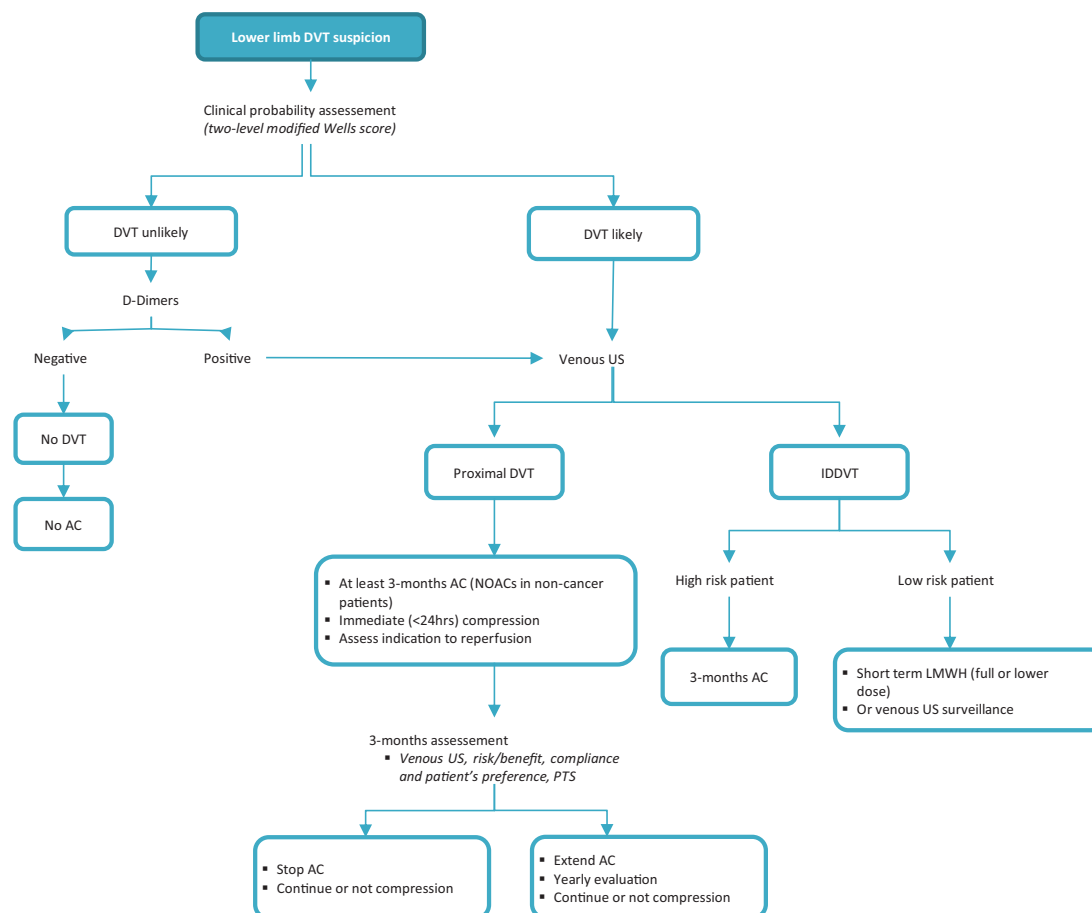


Figure 1 Proposed algorithm for deep vein thrombosis assessment and management. AC, anticoagulation; DVT, deep vein thrombosis; IDDVT, isolated distal DVT; LMWH, low-molecular-weight heparin; NOAC, non-vitamin K antagonists oral anticoagulant; PTS, post-thrombotic syndrome; US, ultrasound.

Anticoagulation in non-cancer patients

For anticoagulation in non-cancer patients, as already reported in the 2017 edition, NOACs should be preferred as first-line anticoagulant therapy in the absence of contraindication.¹ However, for patients with COVID-19 infection, particularly in hospitalized patients NOACs should be avoided and parenteral anticoagulation, with Unfractionated Heparin (UFH) or low-molecular-weight heparin (LMWH), is preferred because of potential high risk of rapid clinical deterioration with multi-organ failure. In addition, concomitant therapy with antiviral agents, immunomodulatory agents, or other investigational treatment have potential drug–drug interactions with NOACs via CYP3A4 and P-gp pathways. Conversely, following the acute phase or in the post-hospital discharge setting, NOACs remain the first choice, in the absence of drug–drug interaction.

Anticoagulation in cancer patients

LMWH appears possibly superior to UFH in the initial phase (first 5–10 days) of VTE treatment in patients with cancer.^{7,8}

For the long-term treatment, the *CLOT trial* represents a cornerstone, showing for the first time that LMWH is more effective than

VKA in reducing risk of recurrent VTE in cancer patients [risk ratio (RR) 0.51, 95% confidence interval (CI) 0.33–0.79] without significant differences in major bleeding risk.⁹ Several meta-analyses confirmed the superiority of LMWH with respect to VKA.^{10–12} Concerning NOACs, a meta-analysis of randomized clinical trials comparing efficacy and safety of long-term NOACs with conventional VKA anticoagulation was performed in a subgroup of patients with cancer.¹³ Overall, no reduction of VTE recurrence [odds ratio (OR) 0.63, 95% CI 0.37–1.10] and major bleeding (OR 0.77, 95% CI 0.41–1.44) were observed in patients receiving NOACs.¹³ Conversely, a second meta-analysis showed statistically significant reduction for VTE recurrence VKA (RR 0.65, 95% CI 0.45–0.95) and major bleeding (RR 0.58, 95% CI 0.45–0.95) with NOACs against VKA.¹¹ However, baseline characteristics of cancer patients in these trials were not comparable to those in specific cancer studies. Also, the comparator, VKA, was not considered adequate, as LMWH was the recommended long-term treatment for cancer patients.

Four recent randomized clinical trials compared efficacy and safety of NOACs vs. LMWH in cancer patients^{14–17} *Hokusai cancer study*¹⁴ compared edoxaban to dalteparin for the long-term treatment (12 months) in cancer patients (98% with active cancer) with acute

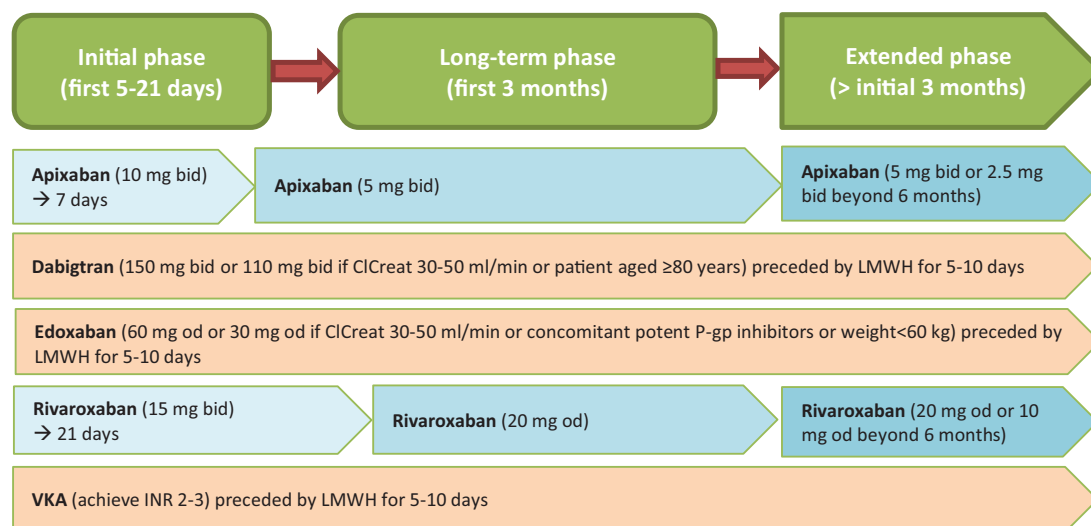


Figure 2 Deep vein thrombosis treatment phases. CrCl, creatinine clearance; LMWH, low-molecular-weight heparin; P-gp inhibitors, glycoprotein-P inhibitors; VKA, vitamin K antagonist.

VTE; >50% of patients had metastatic disease, and >70% received anti-cancer treatment within previous 4 weeks before inclusion. *SELECT-D*¹⁵ was a pilot open-label trial in patients with DVT, comparing rivaroxaban with dalteparin for a total of 6 months (Table 2). In both studies, NOACs were at least not inferior to LMWH for VTE recurrence (rivaroxaban showed superiority) but showed significantly increased bleeding events although primarily confined to patients with gastrointestinal cancer.^{14,15}

Two clinical trials compared apixaban vs. dalteparin.^{16,17} In the largest one, the *Caravaggio study*, ~97% of patients had active cancer; >65% had metastatic disease; and >60% received anti-cancer treatment at time of enrolment (85% within previous 6 months before inclusion). Apixaban showed non-inferiority compared to dalteparin for VTE recurrence at 6 months [5.6% vs. 7.9%, hazard ratio (HR) 0.63 (95% CI 0.37–1.07); $P < 0.001$ for non-inferiority]. Interestingly, and contrary to previous studies, incidence of major bleeding and clinically relevant non-major bleeding events were similar in both groups (HR 0.82; 95% CI 0.40–1.69 and HR 1.42; 95% CI 0.88–2.30, respectively) (Table 2). Notably, a bleeding analysis of *Caravaggio* showed that the gastrointestinal bleeding risk is increased (even with LMWH) if the gastrointestinal cancer is not resected.¹⁸ In addition, patients with primary brain tumours, intracerebral metastases, or acute leukaemia were excluded from study (but not in *Hokusai* and *Select-D*).¹⁷

Patients with cancer experience a high rate of VTE recurrence in spite of anticoagulation. One-year recurrence rate of 20% observed with VKA could almost be reduced by half with long-term administration of LMWH. Based on available evidence for edoxaban or rivaroxaban, the use of NOACs may lead to further VTE recurrences reduction, but at higher risk of major bleeding, particularly in patients with gastrointestinal cancers. Apixaban was at least as safe and as effective as LMWH. However, its use cannot be recommended in patients with primary or metastatic brain cancer or acute leukaemia as these patients were not included in the *Caravaggio study*. LMWH

should be preferred in patients in whom drug–drug interaction is a concern and in those who have undergone surgery involving the upper gastrointestinal tract because absorption of all NOACs occurs in the stomach or proximal small bowel.¹⁹ LMWH should also be preferred in patients with severe thrombocytopenia as well as nausea and vomiting. To summarize, anticoagulation should be individualized based on patient's characteristics and preferences as well as cancer's characteristics and treatment.

Anticoagulation in isolated distal deep vein thrombosis

Whether all isolated distal DVT (IDDVT) should be treated with anticoagulation remains debated. Compared to proximal DVT, risk of VTE recurrence for IDDVT is lower in low-risk patients and similar in high-risk patients.^{20,21} The *CACTUS* trial showed that in low-risk patients with IDDVT, rate of symptomatic VTE at 42 days was not different between LMWH and placebo (3.3% vs. 5.4%, $P = 0.54$); bleeding occurred more frequently in the LMWH group (4% vs. 0%, $P = 0.03$).²² Management of IDDVT should be therefore individualized (Figures 2 and 3). Patients at high risk (Table 4) of VTE may be treated with full-dose anticoagulants for at least 3 months, similar to proximal DVTs.^{20,23,24} Shorter LMWH treatment (4–6 weeks), even at lower doses, or ultrasound (US) surveillance may be effective and safe in low-risk patients (Table 3).^{23,25,26} In the absence of clinical trials, recent results from two prospective registries suggested efficacy and safety of NOACs in patients with IDDVT.^{27,28}

Additional therapeutic options

Thrombolysis/thrombectomy

The *CAVENT* randomized controlled study found modest advantage of catheter-directed *in situ* thrombolysis (CDT) plus anticoagulation over anticoagulation alone with regard to occurrence of PTS up to

Table 2 Randomized clinical trials comparing non-vitamin K antagonists oral anticoagulants vs. low-molecular-weight heparin in cancer patients

Study	Number of patients	Duration therapy	Primary endpoint	Secondary endpoint
Hokusai cancer ¹⁴	Overall: 1046 Edoxaban: 522 Dalteparin: 524	Edoxaban: 211 days (IQR 76–357) Dalteparin: 184 days (IQR 85–341) <i>P</i> < 0.01	Recurrent VTE or MB at 12 months (edoxaban vs. dalteparin) 12.8% vs. 13.5% HR 0.97 (0.70–1.36) (<i>P</i> = 0.006 for non-inferiority)	VTE recurrence (edoxaban vs. dalteparin) 7.9% vs. 11.3% HR 0.71 (0.48–1.06) <i>P</i> = 0.09 MB 6.9% vs. 4.0% HR 1.77 (1.03–3.04) <i>P</i> = 0.04 Clinically relevant non-MB 14.6% vs. 11.1% HR 1.38 (0.98–1.94)
Select-D ¹⁵	Overall: 406 Rivaroxaban: 203 Dalteparin: 203		VTE recurrence at 6 months (rivaroxaban vs. dalteparin) 4% vs. 11% HR 0.43 (0.19–0.99)	MB (rivaroxaban vs. dalteparin) 6% vs. 4% HR 1.83 (0.68–4.96) Clinically relevant non-MB 13% vs. 4% HR 3.76 (1.63–8.69)
Caravaggio ¹⁷	Overall: 1155 Apixaban: 576 Dalteparin: 579	Apixaban: 178 days (IQR 106–183) Dalteparin: 175 days (IQR 79–183) <i>P</i> = 0.15	VTE recurrence at 6 months (apixaban vs. dalteparin) 5.6% vs. 7.9% HR 0.63 (0.37–1.07) <i>P</i> < 0.001 for non-inferiority	MB (apixaban vs. dalteparin) 3.8% vs. 4.0% HR 0.82 (0.40–1.69) <i>P</i> = 0.60 Clinically relevant non-MB 9.0% vs. 6.0% HR 1.42 (0.88–2.30)

HR, hazard ratio; IQR, interquartile range; MB, major bleeding; VTE: venous thromboembolism.

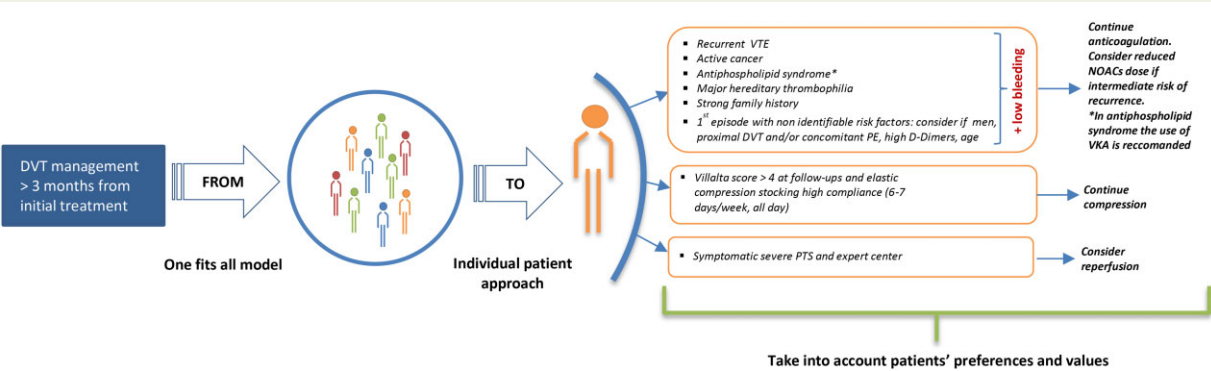


Figure 3 Shift of deep vein thrombosis management: from ‘one fits all’ to an ‘individual patient’ approach. DVT, deep vein thrombosis; NOAC, non-vitamin K antagonists oral anticoagulant; PTS, post-thrombotic syndrome; VKA, vitamin K antagonist; VTE, venous thromboembolism.

2 years (37% vs. 55%, *P* = 0.047); no difference in quality of life was observed.²⁹ However, the large randomized ATTRACT trial³⁰ showed no significant difference in PTS occurrence rates in patients treated with adjuvant CDT (47% vs. 48% in the control group;

P = 0.56). CDT led to more major bleeding within 10 days (1.7% vs. 0.3% of patients, *P* = 0.049); a non-statistically significant difference in recurrent VTE was seen over 24-month follow-up (12% vs. 8%, *P* = 0.09). Patients treated with CDT had lower rates of moderate-

Table 3 Risk factors for venous thromboembolic disease recurrence in patients with isolated distal deep vein thrombosis

IDDVT	Risk factors
Low	<ul style="list-style-type: none"> • Plaster, immobilization, trauma, long trip, etc., provided complete mobilization is achieved • During contraceptive or replacement hormonal therapy (provided therapy has been interrupted)
High	<ul style="list-style-type: none"> • Previous VTE, male, age >50 years, active cancer, unprovoked IDDVT, persistent hampered mobilization, IDDVT involving popliteal trifurcation and/or >1 calf vein, bilateral, presence of predisposing disease (i.e. inflammatory bowel diseases), known genetic thrombophilia, axial vs. muscular IDDVT

IDDVT, isolated distal deep vein thrombosis; VTE, venous thromboembolic disease

to-severe PTS (18% vs. 24%, $P = 0.04$) during the follow-up. PTS severity scores were lower in the CDT group at 6, 12, 18, and 24 months ($P < 0.01$ for the comparison of the Villalta scores at each time point). However, improvement in quality of life did not differ significantly between groups.³⁰ A subgroup analysis of acute iliofemoral thrombosis showed similar results, except for greater improvement in venous disease-specific quality of life at 24 months.³¹ A third study, the CAVA trial, showed that additional US-accelerated catheter-directed thrombolysis does not change PTS risk 1 year after acute iliofemoral DVT compared with standard therapy alone.³² Incidence of PTS was 29% vs. 35% for additional thrombolysis and standard treatment, respectively (OR 0.75, 95% CI 0.38–1.50; $P = 0.42$).³² Major bleeding occurred solely in the CDT group (5% vs. 0%) most within 10 days. A *post hoc* analysis showed significant reduction in symptom severity and improvement of generic quality of life according to the EQ-5D.³³ To note, several baseline characteristics in the CDT group of the three studies were different. Patients in CAVA trial were younger (median age 49 years) than in ATTRACT and CAVENT (52 and 53, respectively). In addition, CAVA trial included >90% of iliofemoral thrombosis (vs. 58% and 42%) and 70% of DVTs were located in the left side (vs. 62% and 60%). Finally, in CAVA trial patients received urokinase (rt-PA, Alteplase in the other two studies). In light of these results, there is no clear benefit of systematic acute proximal DVT reperfusion. Hence, CDT should not be performed routinely. It can be reserved for very severe cases, such as phlegmasia cerulea dolens (Figure 3).

Vena cava filter

There have been no major changes in this section from the 2017 version.¹ Vena cava filter should be considered when anticoagulation is absolutely contraindicated in patients with newly diagnosed proximal DVT or in case of recurrent VTE event under adequate therapeutic anticoagulation. Anticoagulation should be started as soon as contraindications resolve and retrievable filter rapidly removed.¹

Venous compression

Use of immediate (<24 h from diagnosis) compression (elastic compression stockings or multilayer bandaging), associated with early walking exercise, has been shown beneficial in controlling symptoms of acute proximal DVT (swelling, pain, hyperpigmentation, induration, venous enlargement).^{34–36} Moreover, immediate compression was associated with less residual vein occlusion and consequently

reduced PTS development.³⁷ Multilayer bandaging seems more efficient.^{36–38}

Caution is warranted in patients with severe peripheral artery disease (i.e. with ankle-brachial index <0.5 or ankle pressure <60 mmHg).³⁹

Extended phase management (beyond first 3 months)

Anticoagulation beyond initial 3-month phase should be decided after careful assessment of individual recurrence risk, bleeding, patient compliance and preference, and impact of long-term DVT complications (Figure 3 and Table 4).

Recurrence is higher in the first year after treatment discontinuation, it reduces over time but never falls to zero.⁴⁰ Recurrent VTE is a DVT in ~60% and 40% of patients after index DVT or PE, respectively.⁴¹ Once anticoagulation is stopped, VTE recurrence risk differs based on features of index event, it is more than doubled (annual rate $\geq 8\%$, Table 4) in patients without identifiable risk factors vs. those in whom a risk ('provoking') factor is identified.^{42–44} Traditionally, discontinuation of anticoagulation was considered appropriate if risk of recurrence is <5% at 1 year, and <15% at 5 years.⁴⁵ Prolonging anticoagulation reduces recurrence by 80–90%, but exposes to risk of unpredictable bleeding complications. Risk of major bleeding associated with extended NOACs treatment, especially when used in patients at low risk of bleeding and at reduced doses, is lower than that reported with VKA.⁴⁶ This could decrease the recurrence threshold deemed necessary to continue anticoagulation.

Three clinical prediction rules have been proposed to detect low recurrence risk patients;⁴⁷ however, their role is debated in the era of NOACs with low bleeding risk (Table 5). Annualized major bleeding rates in patients continuing anticoagulation can be as high as 3–4%.⁵⁷ No bleeding risk score showed sufficient predictive accuracy or had sufficient validation to be recommended in routine clinical practice.^{58–60} They can serve to identify treatable/reversible bleeding risk factors, and determine frequency of follow-up. New scores for patients on NOACs have recently been proposed⁶¹ (Supplementary material online, Table S2). Factors associated with high bleeding risk are, among others, advanced age, cancer, renal or liver insufficiency,

Table 4 Estimated risk of venous thromboembolic disease recurrence after anticoagulants discontinuation in proximal deep vein thrombosis

Estimated risk of recurrence	Risk factor category for index DVT	Examples
Low (<3%/year)	Major transient/reversible risk factors	<ul style="list-style-type: none">• Surgery with general anaesthesia for longer than 30 min• Confined to bed in hospital (only 'bathroom privileges') for at least 3 days due to an acute illness, or acute exacerbation of a chronic illness• Trauma with fractures
Intermediate (3–8%/year)	Minor transient/reversible risk factors	<ul style="list-style-type: none">• Minor surgery (general anaesthesia for <30 min)• Admission to hospital for <3 days with an acute illness• Obesity (high body mass index)• Ongoing oestrogen therapy• Pregnancy or puerperium• Confined to bed out of hospital for at least 3 days with an acute illness• Leg injury (without fracture) associated with reduced mobility for at least 3 days• Long-haul flight
	Non-malignant persistent risk factors	<ul style="list-style-type: none">• Inflammatory bowel and active autoimmune diseases (risk may change depending on activity and treatment)^a
High (>8%/year)	Major persistent risk factors	<ul style="list-style-type: none">• One or more previous episodes of VTE in absence of a major transient or reversible factor• Active cancer• Antiphospholipid antibody syndrome• Major hereditary thrombophilia^b• Strong family history^c
Variable	First episode with no identifiable risk factors	Higher recurrency risk: men, proximal DVT, concomitant PE, high D-dimers at anticoagulation discontinuation, age

DVT, deep vein thrombosis; PE, pulmonary embolism; VTE, venous thromboembolic disease.
^aAlso at increased bleeding risk.
^bConfirmed antithrombin, protein C or protein S deficiency, homozygous factor V Leiden, homozygous prothrombin G20210A mutation, double heterozygous.
^cFirst-degree relative with personal history of proximal DVT or PE.

concomitant antithrombotic drugs, and history of previous major bleeding.⁵⁷

A summary of data on anticoagulant therapies used for extended management is presented in [Supplementary material online](#). Two studies investigated aspirin 100 mg vs. placebo in patients with VTE without identifiable risk factors who completed initial anticoagulation treatment.^{62,63} Pooled HR for VTE recurrence was 0.68 (95% CI 0.51–0.90) and 1.24 (95% CI 0.46–3.33) for major bleeding.⁶⁴ Thus, aspirin reduces rate of recurrences to a lesser extent than oral anticoagulants and is associated with similar bleeding rate as rivaroxaban 10 mg o.d.^{63,65} Therefore, use of aspirin is not indicated in the era of NOACs.

Duration of anticoagulation in non-cancer and cancer patients

For proximal DVT (with or without concomitant PE), 3-month anticoagulation is the best option if risk of recurrence is low (i.e. major transient/reversible risk factors; [Table 4](#)).^{2,25}

Provided bleeding risk is low, indefinite anticoagulation is the best option for patients with high risk of recurrence (i.e. multiple VTE

episodes in absence of a major transient or reversible factor, VTE familial history, those with major thrombophilia; [Table 4](#)).^{2,25} Patients with DVT without identified risk factors and low bleeding risk are candidates for extended anticoagulation beyond the initial 3 months.^{2,25} Dichotomizing VTE into provoked and unprovoked categories to guide treatment appears simple, but studies showed that patients with provoked VTE are at higher recurrence risk compared to those without VTE history.⁶⁶ Also, recent trials have not shown a clear difference regarding benefit of extended anticoagulation according to the provoked/unprovoked status.⁶⁷ Therefore, optimal DVT management requires a more nuanced approach ([Figure 3](#)). In absence of contraindications, NOACs should be preferred as first-line extended anticoagulant therapy in non-cancer patients, except in patients with antiphospholipid syndrome where only VKA is recommended.⁶⁸ In patients at intermediate risk of recurrence, two RCTs comparing full and reduced dose of apixaban with placebo⁶⁹ or full and reduced dose of rivaroxaban with aspirin⁶⁵ have shown that reduced doses were as effective as full dose with comparable bleeding risk as placebo or aspirine.⁷⁰

Due to high recurrence risk, patients with cancer should be individually evaluated with regard to anticoagulation duration depending

Table 5 Clinical prediction models for venous thromboembolism recurrence after first episode of venous thromboembolic disease

Prediction model	Parameters	Points	Risk categories	Population studied	Low-risk recurrent
VIENNA ^{48–50}	<ul style="list-style-type: none"> D-dimer (after stopping AC) Male sex VTE location (distal DVT, proximal DVT, PE) 	NA	Nomogram	Unprovoked VTE	4.4% (95% CI 2.7–6.2)
HERDOO-2 ^{51,52}	<ul style="list-style-type: none"> Abnormal D-dimer (before stopping AC) Age ≥ 65 years BMI ≥ 30 Hyperpigmentation, oedema and redness 	1 1 1 1	<ul style="list-style-type: none"> Low risk: 0–1 points High risk: ≥ 2 points 	Unprovoked VTE or with minor risk factors	1.6% (95% CI 0.3–4.6) Only applicable in women
DASH ^{53,54}	<ul style="list-style-type: none"> Abnormal D-dimer (after stopping AC) Age < 50 years Men Hormonal therapy 	1 1 1 –2	<ul style="list-style-type: none"> Low risk: ≤ 1 points High risk: ≥ 2 points 	Unprovoked VTE or with minor risk factors	3.1% (95% CI 2.3–3.9)
DAMOVES ^{55,56}	<ul style="list-style-type: none"> Abnormal D-dimer Age Sex Obesity Factor VIII Genetic thrombophilia Varicose veins 	NA	Nomogram	Unprovoked VTE	2.9% (95% CI 2.13–4.35)

AC, anticoagulation; BMI, body mass index; CI, confidence interval; DVT, deep vein thrombosis; PE, pulmonary embolism; VTE, venous thromboembolic disease.

on cancer type, staging, activity, chemotherapy, life expectancy, etc. as well based on presence of active cancer or remission state (Figure 3).²⁵ Risk benefit ratio of continuing anticoagulation needs to be periodically re-assessed, as risk for recurrence and bleeding may vary over time.^{71–73} Prolonged anticoagulation may consist of oral anticoagulants. VTE recurrence in cancer patients on VKA (with adequate INR) requires changing to LMWH. Recurrence on LMWH may be managed by increasing dosing or opting for vena cava filter placement in selected patients.²⁵ Notably, data about prolonged treatment with NOAC in DVT cancer patients are very limited. The only Hokusai study evaluated anticoagulation with NOAC up to 12 months.⁷⁴

Prevention and management of post-thrombotic syndrome

PTS is the most frequent chronic DVT complication, occurring in 30–50% of patients within 2 years after proximal DVT.⁷⁵ In 5–10% of cases, PTS is severe.⁷⁵

Pathophysiology of PTS is yet not completely elucidated. Previous ipsilateral DVT, iliofemoral location, and residual veins obstruction are most significant PTS risk factors.⁷⁶ Three different clinical prediction models were recently proposed.^{77–79} Similarly, there is no gold standard for PTS diagnosis. The Villalta score is the most used tool for diagnosis and treatment evaluation (Supplementary material online, Table S3).⁸⁰ Standard and effective management for PTS prevention and treatment is lacking, a shift from a 'one fit for all' model to a personalized one is warranted (Figure 3). For decades, elastic compression stocking has been the mainstay for PTS management, based on two open-label randomized controlled trials both showing a 50% relative risk reduction in PTS development.^{81,82} In the randomized SOX trial compression stockings were compared to placebo stockings and no difference in PTS was observed. Discrepancy may be explained by the compliance definition (only 56% of patients wearing stockings ≥ 3 days/week), lack of patient education, and low rate of immediate (<24 h post-DVT diagnosis) compression.⁸³ A recent Bayesian meta-analysis showed that it is probable to observe a protective effect of compression stockings when applied in the acute setting of a DVT.⁸⁴ Two recent clinical trials showed that good compliance (wearing ECS for at least 6 days/week) and high adherence rate (>80%) is associated with significantly lower PTS incidence.^{85,86} They also suggest that duration of elastic compression stocking use could be individualized (Figure 3).

PTS pathophysiology relies on the principle of outflow obstruction, partly caused by venous hypertension, leading to valvular damage and venous reflux or insufficiency. Recent technical developments and new dedicated venous stent techniques allow recanalizing even complex chronic venous outflow obstructions. Although first in man safety and efficacy data are promising, well-conducted trials are needed.^{87–89}

Follow-up

Patients should be followed to avoid risk of recurrence as well as DVT-related and anticoagulation-related complications, to review treatment, lab values, and patient information. While on anticoagulation a yearly assessment is indicated. Development of conditions requiring anticoagulation adjustment should be monitored (e.g. renal insufficiency, pregnancy, weight loss, severe hypertension).

Treatment compliance as well as benefit/risk balance should be assessed. Development of PTS should be evaluated. Venous US assessment, prior to anticoagulation discontinuation, is useful in determining baseline residual vein thrombosis not to drive anticoagulant treatment duration, but to differentiate between old and new thrombosis in case of new symptoms. Following anticoagulation discontinuation, information should be given regarding future high thrombotic risk situations.⁹⁰

Special situations

Deep vein thrombosis in pregnancy, oral contraception, and thrombophilia

Pregnancy increases VTE risk by four- to five-fold.⁹¹ VTE risk factors are listed in Table 6. Femoral and/or (isolated) iliac vein thrombosis occurs more often in pregnant than in non-pregnant patients, mainly on the left side due to anatomical reasons. Women have a 42% risk of PTS and 7% of severe PTS after pregnancy-related DVT.⁹² Validity of DVT clinical prediction rules in pregnancy has not yet been tested prospectively.⁹³ The LEfT clinical score was proposed;⁹⁴ however, it remains to be prospectively validated, and integrated into a standardized diagnostic strategy.⁹⁵ Although D-dimers increase during pregnancy, normal values exclude VTE with likelihood similar to non-pregnant women.² Venous US is the primary imaging test and should specifically include imaging of iliac veins.⁹³ If venous US is negative but clinical suspicion high, testing should be repeated at 7–10 days.^{96,97} Rarely, computed tomography (CT) (or magnetic resonance imaging) venography may be considered.⁹⁷ Treatment consists of therapeutic dose heparin (no placenta crossing and not significantly found in breast milk) with a preference of LMWH over UFH.⁹⁷ Anti-Xa monitoring and dose adaptation is not recommended routinely, but may be considered in women of extreme body weight or renal insufficiency.⁹⁷ Whether initial full-dose anticoagulation can be reduced for secondary prevention during ongoing pregnancy has never been investigated.⁹⁸ CDT therapy has not been investigated in pregnant women and should not be added to anticoagulation.⁹⁷ Evidence is insufficient to recommend o.d. over b.i.d. LMWH, but o.d. is more patient friendly. Peripartum management should be approached by a multidisciplinary team and there is large variation in practice with regard to temporary interruption of LMWH, scheduled delivery, and access to neuraxial anaesthesia.^{97,98} Anticoagulation should be continued for at least 6 weeks postpartum and until at least a total of 3 months treatment.⁹⁷ In breastfeeding women, LMWH can be continued for the remainder of the treatment period or be switched to VKA, which is safe as well.⁹⁸ In this case, small vitamin K doses (1 mg/week) should be given to the breast-fed newborn. NOACs are contraindicated in pregnancy/lactation in the absence of safety data.

Use of combined oral contraceptives (OC) increases VTE risk, strongest during the first months but remaining three- to eight-fold increased as compared to non-users.⁹⁹ Presence of thrombophilia further increases risk of hormone-related VTE, sometimes in a multiplicative way.¹⁰⁰ Risk of recurrent VTE in women with hormone-associated VTE is lower than in those with an unprovoked event (HR 0.5, 95% CI 0.3–0.8).¹⁰¹ Hence, 3 months treatment is adequate in most women. OC can be used without increasing recurrence risk if

Table 6 Deep vein thrombosis risk factors during pregnancy

Pre-existing conditions

- Prior venous thromboembolism
- Severe thrombophilia
- Varicosis
- Smoking
- BMI > 30 kg/m²
- Systemic lupus erythematosus

Obstetrical

- Hyperemesis
- Assisted reproductive technology
- Pre-eclampsia
- Preterm delivery
- Caesarean section (specifically in the emergency situation)

Other

- Postpartum infection or haemorrhage
- Transfusion
- Immobilization

BMI, body mass index.

therapeutic anticoagulants are used concomitantly.¹⁰² However, increased risk of DVT persists up to 3 months following OC discontinuation warranting use of low-VTE risk contraception as alternative.¹⁰³

Whether or not to test for thrombophilia is a recurring clinical question in patients with DVT. Testing should be reserved for situations where results would change management (e.g. antiphospholipid antibodies, homozygous mutation for factor V or II, severe composite thrombophilia) based on a patient-specific assessment.

Upper extremities deep vein thrombosis

Upper extremities DVT (UEDVT) accounts for 10% of all DVTs with an annual incidence of 0.4–1.0/10 000 persons.^{104,105} Incidence rises because of increasing use of central venous catheters, cardiac pacemakers, and defibrillators. Complications are similar, although less frequent, to those of lower limb DVT.^{104,105} About 20–30% of UEDVT are primary comprising those caused by anatomic abnormalities or following sustained physical efforts.¹⁰⁶ Secondary DVT include venous catheter- and devices-related complications, cancer, pregnancy, and recent arm/shoulder surgery or trauma. Most common clinical presentation includes pain, swelling, and skin discolouration.

A clinical decision score (Constans score) has been proposed (Supplementary material online, Table S4).¹⁰⁷ D-Dimer showed good negative predictive value in symptomatic DVT.^{108,109} Venous US is the first choice exam for diagnosis.¹¹⁰ A diagnostic algorithm, using Constans score, D-dimer, and Venous US was proposed.¹⁰⁹ Contrast-, CT-, and MR-venography are not recommended for diagnosis but limited to unresolved selected cases.¹⁰⁵ Anticoagulation is similar to that of lower limb DVT.

Thrombolysis is not routinely recommended but limited to selected severe cases.

Uncommon deep vein thrombosis localizations

Splanchnic DVT has been dealt with in the 2017 consensus with no major changes.¹ Concerning cerebral vein thrombosis (CVT), a randomized clinical trial evaluated efficacy and safety of NOAC in 120 patients with CVT.¹¹¹ Patients received therapeutic dose of dabigatran (150 mg bid) or adjusted dose of VKA for 24 weeks, after an initial period of 5–15 days with LMWH or UFH. The study found no difference between groups with respect to recurrent VTE and bleeding suggesting that both drugs may be safe and effective in CVT patients.¹¹¹ A second study, evaluating efficacy and safety of rivaroxaban in patients with CVT is currently ongoing.¹¹²

An international, multicentre, prospective registry evaluating the use of NOACs for treating venous thrombosis in unusual sites is currently ongoing¹¹³ as well as a study evaluating safety and efficacy of rivaroxaban in patients with acute splanchnic vein thrombosis without liver cirrhosis.¹¹⁴

Management of bleeding during anticoagulation

Patients treated with VKAs presenting with severe major bleeding should receive intravenous vitamin K and prothrombin complex concentrates (PCCs) to rapidly reverse anticoagulation. In patients treated with NOACs, idarucizumab is the specific reversal agent currently available in Europe for direct factor IIa inhibitor dabigatran. Following the results of the REVERSE-AD trial, this humanized monoclonal antibody is approved for reversal of dabigatran etexilate in patients with major, life-threatening bleeding, and in patients requiring urgent invasive procedures.¹¹⁵ Reversal agent for direct factor Xa inhibitors is andexanet alfa, a human recombinant factor Xa variant currently approved in the USA by FDA and in Europe by EMA for patients with acute major bleeding. In the ANNEXA4 trial, anti-factor Xa activity of both apixaban and rivaroxaban was reduced by >90% after administering a bolus of andexanet followed by a 2-h infusion.¹¹⁶ In case of reversal agent unavailability, patients treated with direct factor Xa inhibitors and life-threatening bleeding should receive PCCs.^{114,117,118} No data about efficacy and safety of tranexamic acid in patients treated with direct factor Xa inhibitors and life-threatening bleeding are currently available.

Venous thromboembolism during electrophysiology procedures

Femoral veins are the elective route for cardiac catheterization during electrophysiology procedures. However, limited data exist on the VTE risk after such procedures. In a recent systematic review,¹¹⁹ the pooled incidence rates for DVT after non-AF and AF procedures were 0.24% (95% CI 0.08–0.39%) and 0% (95% CI 0–0.0003%), respectively. The lower rates for the latter are plausible linked to the systematic use of anticoagulation during this procedure, with in turn, more frequent significant haematomas in AF (1%) than non-AF (0.3%) ablations.¹¹⁹ Indeed, recent joint consensus document (including EHRA) supports the maintenance of oral anticoagulants (if already under) during the intervention, the use of per-procedural heparin,

and anticoagulation in the post-operative period.¹²⁰ In other procedures, especially in the right-sided chambers not requiring anticoagulation, the use of bolus of heparin during the procedure is optional and differs largely by centres.^{121,122} Further studies are necessary to balance the thrombotic vs. bleeding risk in this setting.

Asymptomatic DVT can be documented up to 20% of cases,¹¹⁹ but its clinical significance is unclear because of the major contrast with very low rates of clinical VTE. Yet, systematic venous US after such procedures is not recommended, unless clinical signs exist.

Supplementary material

Supplementary material is available at *European Journal of Preventive Cardiology* online.

Conflict of interest: none declared.

References

- Mazzolai L, Aboyans V, Ageno W, Agnelli G, Alatri A, Bauersachs R, Brekelmans MPA, Buller HR, Elias A, Farge D, Konstantinides S, Palareti G, Prandoni P, Righini M, Torbicki A, Vlachopoulos C, Brodmann M. Diagnosis and management of acute deep vein thrombosis: a joint consensus document from the European Society of Cardiology working groups of aorta and peripheral vascular diseases and pulmonary circulation and right ventricular function. *Eur Heart J* 2018;**39**:4208–4218.
- Konstantinides SV, Meyer G, Becattini C, Bueno H, Geersing G-J, Harjola V-P, Huisman MV, Humbert M, Jennings CS, Jiménez D, Kucher N, Lang IM, Lankeit M, Lorusso R, Mazzolai L, Meneveau N, Ni Ainle F, Prandoni P, Pruszczyk P, Righini M, Torbicki A, Van Belle E, Zamorano JL; ESC Scientific Document Group. 2019 ESC Guidelines for the diagnosis and management of acute pulmonary embolism developed in collaboration with the European Respiratory Society (ERS): the Task Force for the diagnosis and management of acute pulmonary embolism of the European Society of Cardiology (ESC). *Eur Heart J* 2020;**41**:543–603.
- Heit JA. The epidemiology of venous thromboembolism in the community: implications for prevention and management. *J Thromb Thrombolysis* 2006;**21**:23–29.
- Baglin T, Luddington R, Brown K, Baglin C. Incidence of recurrent venous thromboembolism in relation to clinical and thrombophilic risk factors: prospective cohort study. *Lancet* 2003;**362**:523–526.
- Spyropoulos AC, Weitz JI. Hospitalized COVID-19 patients and venous thromboembolism: a perfect storm. *Circulation* 2020;**142**:129–132.
- Jiménez D, García-Sánchez A, Rali P, Muriel A, Bikdeli B, Ruiz-Artacho P, Le Mao R, Rodríguez C, Hunt BJ, Monreal M. Incidence of venous thromboembolism and bleeding among hospitalized patients with COVID-19: a systematic review and meta-analysis. *Chest* 2021;**159**:1182–1196.
- Robertson L, Jones LE. Fixed dose subcutaneous low molecular weight heparins versus adjusted dose unfractionated heparin for the initial treatment of venous thromboembolism. *Cochrane Database Syst Rev* 2017;**2**:CD001100.
- Hakoum MB, Kahale LA, Tzolakis IG, Matar CF, Yosico VE, Terrenato I, Sperati F, Barba M, Schunemann H, Akl EA. Anticoagulation for the initial treatment of venous thromboembolism in people with cancer. *Cochrane Database Syst Rev* 2018;**1**:CD006649.
- Lee AY, Levine MN, Baker RI, Bowden C, Kakkar AK, Prins M, Rickles FR, Julian JA, Haley S, Kovacs MJ, Gent M; Randomized Comparison of Low-Molecular-Weight Heparin versus Oral Anticoagulant Therapy for the Prevention of Recurrent Venous Thromboembolism in Patients with Cancer (CLOT) Investigators. Low-molecular-weight heparin versus a coumarin for the prevention of recurrent venous thromboembolism in patients with cancer. *N Engl J Med* 2003;**349**:146–153.
- Kahale LA, Hakoum MB, Tzolakis IG, Matar CF, Terrenato I, Sperati F, Barba M, Yosico VE, Schunemann H, Akl EA. Anticoagulation for the long-term treatment of venous thromboembolism in people with cancer. *Cochrane Database Syst Rev* 2018;**6**:CD006650.
- Kirkkiles GI, Kakkos SK, Tzolakis IA. Editor's Choice—a systematic review and meta-analysis of the efficacy and safety of anticoagulation in the treatment of venous thromboembolism in patients with cancer. *Eur J Vasc Endovasc Surg* 2019;**57**:685–701.
- Li A, Garcia DA, Lyman GH, Carrier M. Direct oral anticoagulant (DOAC) versus low-molecular-weight heparin (LMWH) for treatment of cancer associated thrombosis (CAT): a systematic review and meta-analysis. *Thromb Res* 2019;**173**:158–163.
- Vedovati MC, Germini F, Agnelli G, Becattini C. Direct oral anticoagulants in patients with venous thromboembolism and cancer: a systematic review and meta-analysis. *Chest* 2015;**147**:475–483.
- Raskob GE, van Es N, Verhamme P, Carrier M, Di Nisio M, Garcia D, Grosso MA, Kakkar AK, Kovacs MJ, Mercuri MF, Meyer G, Segers A, Shi M, Wang T-F, Yeo E, Zhang G, Zwicker JI, Weitz JI, Büller HR; Hokusai VTE Cancer Investigators. Edoxaban for the treatment of cancer-associated venous thromboembolism. *N Engl J Med* 2018;**378**:615–624.
- Young AM, Marshall A, Thirlwall J, Chapman O, Lokare A, Hill C, Hale D, Dunn JA, Lyman GH, Hutchinson C, MacCallum P, Kakkar A, Hobbs FDR, Petrou S, Dale J, Poole CJ, Maraveyas A, Levine M. Comparison of an oral factor Xa inhibitor with low molecular weight heparin in patients with cancer with venous thromboembolism: results of a randomized trial (SELECT-D). *J Clin Oncol* 2018;**36**:2017–2023.
- McBane RD 2nd, Wysokinski WE, Le-Rademacher JG, Zemla T, Ashrani A, Tafur A, Perepu U, Anderson D, Gundabolu K, Kuzma C, Perez Botero J, Leon Ferre RA, Henkin S, Lenz CJ, Houghton DE, Vishnu P, Loprinzi CL. Apixaban and dalteparin in active malignancy-associated venous thromboembolism: the ADAM VTE trial. *J Thromb Haemost* 2020;**18**:411–421.
- Agnelli G, Becattini C, Meyer G, Muñoz A, Huisman MV, Connors JM, Cohen A, Bauersachs R, Brenner B, Torbicki A, Sueiro MR, Lambert C, Gussoni G, Campanini M, Fontanella A, Vescovo G, Verso M. Apixaban for the treatment of venous thromboembolism associated with cancer. *N Engl J Med* 2020;**382**:1599–1607.
- Agno W, Vedovati MC, Cohen A, Huisman M, Bauersachs R, Gussoni G, Becattini C, Agnelli G. Bleeding with apixaban and dalteparin in patients with cancer-associated venous thromboembolism: results from the Caravaggio study. *Thromb Haemost* 2021;**121**:616–624.
- Lee AYY. Anticoagulant therapy for venous thromboembolism in cancer. *N Engl J Med* 2020;**382**:1650–1652.
- Galanaud JP, Sevestre MA, Pernod G, Genty C, Richelet S, Kahn SR, Boulon C, Terrisse H, Quere I, Bosson JL. Long-term outcomes of cancer-related isolated distal deep vein thrombosis: the OPTIMEV study. *J Thromb Haemost* 2017;**15**:907–916.
- Valerio L, Ambaglio C, Barone M, Ciola M, Konstantinides SV, Mahmoudpour SH, Picchi C, Pieresca C, Trincherio A, Barco S. Recurrence risk after first symptomatic distal versus proximal deep vein thrombosis according to baseline risk factors. *TH Open* 2019;**3**:e58–e63.
- Righini M, Galanaud JP, Guenaguez H, Brisot D, Diard A, Faisse P, Barrellier MT, Hamel-Desnos C, Jurus C, Pichot O, Martin M, Mazzolai L, Choquet C, Accassat S, Robert-Ebadi H, Carrier M, Le Gal G, Mermillod B, Laroche JP, Bounameaux H, Perrier A, Kahn SR, Quere I. Anticoagulant therapy for symptomatic calf deep vein thrombosis (CACTUS): a randomised, double-blind, placebo-controlled trial. *Lancet Haematol* 2016;**3**:e556–e562.
- Robert-Ebadi H, Righini M. Management of distal deep vein thrombosis. *Thromb Res* 2017;**149**:48–55.
- Dentali F, Pegoraro S, Barco S, di Minno MND, Mastroiaco D, Pomero F, Lodigiani C, Bagna F, Sartori M, Barillari G, Mumoli N, Napolitano M, Passamonti SM, Benedetti R, Agno W, Di Nisio M. Clinical course of isolated distal deep vein thrombosis in patients with active cancer: a multicenter cohort study. *J Thromb Haemost* 2017;**15**:1757–1763.
- Kearon C, Akl EA, Ornelas J, Blaivas A, Jimenez D, Bounameaux H, Huisman M, King CS, Morris TA, Sood N, Stevens SM, Vintch JR, Wells P, Woller SC, Moores L. Antithrombotic therapy for VTE disease: CHEST guideline and expert panel report. *Chest* 2016;**149**:315–352.
- Parisi R, Visona A, Camporese G, Verlati F, Lessiani G, Antignani PL, Palareti G. Isolated distal deep vein thrombosis: efficacy and safety of a protocol of treatment. Treatment of Isolated Calf Thrombosis (TICT) Study. *Int Angiol* 2009;**28**:68–72.
- Agno W, Mantovani LG, Haas S, Kreutz R, Monje D, Schneider J, Bugge JP, Gebel M, Turpie AGG. Patient management strategies and long-term outcomes in isolated distal deep-vein thrombosis versus proximal deep-vein thrombosis: findings from XALIA. *TH Open* 2019;**3**:e85–e93.
- Schellong SM, Goldhaber SZ, Weitz JI, Agno W, Bounameaux H, Turpie AGG, Angchaisuksiri P, Haas S, Goto S, Zaghdoun A, Farjat A, Nielsen JD, Kayani G, Mantovani LG, Prandoni P, Kakkar AK. Isolated distal deep vein thrombosis: perspectives from the GARFIELD-VTE registry. *Thromb Haemost* 2019;**119**:1675–1685.
- Enden T, Haig Y, Klow NE, Slagsvold CE, Sandvik L, Ghanima W, Hafsahl G, Holme PA, Holmen LO, Njaastad AM, Sandbaek G, Sandset PM; CaVenT Study Group. Long-term outcome after additional catheter-directed

- thrombolysis versus standard treatment for acute iliofemoral deep vein thrombosis (the CaVenT study): a randomised controlled trial. *Lancet* 2012; **379**:31–38.
30. Vedantham S, Goldhaber SZ, Julian JA, Kahn SR, Jaff MR, Cohen DJ, Magnuson E, Razavi MK, Comerota AJ, Gornik HL, Murphy TP, Lewis L, Duncan JR, Nieters P, Derfler MC, Filion M, Gu CS, Kee S, Schneider J, Saad N, Blinder M, Moll S, Sacks D, Lin J, Rundback J, Garcia M, Razdan R, VanderWoude E, Marques V, Kearon C. Pharmacomechanical catheter-directed thrombolysis for deep-vein thrombosis. *N Engl J Med* 2017; **377**:2240–2252.
 31. Comerota AJ, Kearon C, Gu CS, Julian JA, Goldhaber SZ, Kahn SR, Jaff MR, Razavi MK, Kindzelski AL, Bashir R, Patel P, Sharafuddin M, Schlau MJ, Saad WE, Assi Z, Hofmann LV, Kennedy M, Vedantham S; for the ATTRACT Trial Investigators. Endovascular thrombus removal for acute iliofemoral deep vein thrombosis. *Circulation* 2019; **139**:1162–1173.
 32. Notten P, Ten Cate-Hoek AJ, Arnoldussen C, Strijkers RHW, de Smet A, Tick LW, van de Poel MHW, Wikkeling ORM, Vleming LJ, Koster A, Jie KG, Jacobs EMG, Ebben HP, Coppens M, Toonder I, Ten Cate H, Wittens CHA. Ultrasound-accelerated catheter-directed thrombolysis versus anticoagulation for the prevention of post-thrombotic syndrome (CAVA): a single-blind, multicentre, randomised trial. *Lancet Haematol* 2020; **7**:e40–e49.
 33. Notten P, Arnoldussen C, Brans R, de Smet A, Tick LW, van de Poel MHW, Wikkeling ORM, Vleming LJ, Koster A, Jie KG, Jacobs EMG, Ebben HP, Planken N, Ten Cate H, Wittens CHA, Ten Cate-Hoek AJ. Association of successful ultrasound-accelerated catheter-directed thrombolysis with post-thrombotic syndrome: a post hoc analysis of the CAVA trial. *Thromb Haemost* 2020; **120**:1188–1199.
 34. Partsch H, Blattler W. Compression and walking versus bed rest in the treatment of proximal deep venous thrombosis with low molecular weight heparin. *J Vasc Surg* 2000; **32**:861–869.
 35. Kahn SR, Comerota AJ, Cushman M, Evans NS, Ginsberg JS, Goldenberg NA, Gupta DK, Prandoni P, Vedantham S, Walsh ME, Weitz JI; American Heart Association Council on Peripheral Vascular Disease, Council on Clinical Cardiology, and Council on Cardiovascular and Stroke Nursing. The post-thrombotic syndrome: evidence-based prevention, diagnosis, and treatment strategies: a scientific statement from the American Heart Association. *Circulation* 2014; **130**:1636–1661.
 36. Amin EE, Joore MA, ten Cate H, Meijer K, Tick LW, Middeldorp S, Mostard GJM, ten Wolde M, van den Heiligenberg SM, van Wissen S, van de Poel MHW, Villalta S, Serné EH, Otten H-M, Klappe EH, Prandoni P, ten Cate-Hoek AJ. Clinical and economic impact of compression in the acute phase of deep vein thrombosis. *J Thromb Haemost* 2018; **16**:1555–1563.
 37. Amin EE, Bistervels IM, Meijer K, Tick LW, Middeldorp S, Mostard G, van de Poel M, Serné EH, Otten HM, Klappe EM, Joore MA, Ten Cate H, Ten Wolde M, Ten Cate-Hoek AJ. Reduced incidence of vein occlusion and postthrombotic syndrome after immediate compression for deep vein thrombosis. *Blood* 2018; **132**:2298–2304.
 38. Roumen-Klappe EM, den Heijer M, van Rossum J, Wollersheim H, van der Vleuten C, Thien T, Janssen MC. Multilayer compression bandaging in the acute phase of deep-vein thrombosis has no effect on the development of the post-thrombotic syndrome. *J Thromb Thrombolysis* 2009; **27**:400–405.
 39. Norgren L, Hiatt WR, Dormandy JA, Nehler MR, Harris KA, Fowkes FG; TASC II Working Group. Inter-society consensus for the management of peripheral arterial disease (TASC II). *J Vasc Surg* 2007; **45**(Suppl S):S5–S67.
 40. Heit JA, Mohr DN, Silverstein MD, Petterson TM, O'Fallon WM, Melton LJ 3rd. Predictors of recurrence after deep vein thrombosis and pulmonary embolism: a population-based cohort study. *Arch Intern Med* 2000; **160**:761–768.
 41. Baglin T, Douketis J, Tosetto A, Marcucci M, Cushman M, Kyrle P, Palareti G, Poli D, Tait RC, Iorio A. Does the clinical presentation and extent of venous thrombosis predict likelihood and type of recurrence? A patient-level meta-analysis. *J Thromb Haemost* 2010; **8**:2436–2442.
 42. Prandoni P, Noventa F, Ghirarduzzi A, Pengo V, Bernardi E, Pesavento R, Iotti M, Tormene D, Simioni P, Pagnan A. The risk of recurrent venous thromboembolism after discontinuing anticoagulation in patients with acute proximal deep vein thrombosis or pulmonary embolism. A prospective cohort study in 1,626 patients. *Haematologica* 2007; **92**:199–205.
 43. Iorio A, Kearon C, Filippucci E, Marcucci M, Macura A, Pengo V, Siragusa S, Palareti G. Risk of recurrence after a first episode of symptomatic venous thromboembolism provoked by a transient risk factor: a systematic review. *Arch Intern Med* 2010; **170**:1710–1716.
 44. Kearon C, Ageno W, Cannegieter SC, Cosmi B, Geersing GJ, Kyrle PA; Subcommittees on Control of Anticoagulation, and Predictive and Diagnostic Variables in Thrombotic Disease. Categorization of patients as having provoked or unprovoked venous thromboembolism: guidance from the SSC of ISTH. *J Thromb Haemost* 2016; **14**:1480–1483.
 45. Kearon C, Iorio A, Palareti G; Subcommittee on Control of Anticoagulation of the SSC of the ISTH. Risk of recurrent venous thromboembolism after stopping treatment in cohort studies: recommendation for acceptable rates and standardized reporting. *J Thromb Haemost* 2010; **8**:2313–2315.
 46. Mai V, Bertolotti L, Cucherat M, Jardel S, Grange C, Provencher S, Lega JC. Extended anticoagulation for the secondary prevention of venous thromboembolic events: An updated network meta-analysis. *PLoS One* 2019; **14**:e0214134.
 47. Kyrle PA, Eichinger S. Clinical scores to predict recurrence risk of venous thromboembolism. *Thromb Haemost* 2012; **108**:1061–1064.
 48. Eichinger S, Heinze G, Jandek LM, Kyrle PA. Risk assessment of recurrence in patients with unprovoked deep vein thrombosis or pulmonary embolism: the Vienna prediction model. *Circulation* 2010; **121**:1630–1636.
 49. Eichinger S, Heinze G, Kyrle PA. D-dimer levels over time and the risk of recurrent venous thromboembolism: an update of the Vienna prediction model. *J Am Heart Assoc* 2014; **3**:e000467.
 50. Marcucci M, Iorio A, Douketis JD, Eichinger S, Tosetto A, Baglin T, Cushman M, Palareti G, Poli D, Tait RC, Kyrle PA. Risk of recurrence after a first unprovoked venous thromboembolism: external validation of the Vienna Prediction Model with pooled individual patient data. *J Thromb Haemost* 2015; **13**:775–781.
 51. Rodger MA, Kahn SR, Wells PS, Anderson DA, Chagnon I, Le Gal G, Solymoss S, Crowther M, Perrier A, White R, Vickers L, Ramsay T, Betancourt MT, Kovacs MJ. Identifying unprovoked thromboembolism patients at low risk for recurrence who can discontinue anticoagulant therapy. *CMAJ* 2008; **179**:417–426.
 52. Rodger MA, Scarvelis D, Kahn SR, Wells PS, Anderson DA, Chagnon I, Le Gal G, Gandara E, Solymoss S, Sabri E, Kovacs J, Kovacs MJ. Long-term risk of venous thrombosis after stopping anticoagulants for a first unprovoked event: a multi-national cohort. *Thromb Res* 2016; **143**:152–158.
 53. Tosetto A, Iorio A, Marcucci M, Baglin T, Cushman M, Eichinger S, Palareti G, Poli D, Tait RC, Douketis J. Predicting disease recurrence in patients with previous unprovoked venous thromboembolism: a proposed prediction score (DASH). *J Thromb Haemost* 2012; **10**:1019–1025.
 54. van Hylckama Vlieg A, Baglin CA, Luddington R, MacDonald S, Rosendaal FR, Baglin TP. The risk of a first and a recurrent venous thrombosis associated with an elevated D-dimer level and an elevated thrombin potential: results of the THE-VTE study. *J Thromb Haemost* 2015; **13**:1642–1652.
 55. Franco Moreno AI, García Navarro MJ, Ortiz Sánchez J, Martín Díaz RM, Madroñal Cerezo E, de Ancos Aracil CL, Cabello Clotet N, Perales Fraile I, Gimeno García S, Montero Hernández C, Zapatero Gaviria A, Ruiz Giardin JM. A risk score for prediction of recurrence in patients with unprovoked venous thromboembolism (DAMOVES). *Eur J Intern Med* 2016; **29**:59–64.
 56. Franco Moreno AI, García Navarro MJ, Ortiz SJ, Ruiz GJ. Predicting recurrence after a first unprovoked venous thromboembolism: retrospective validation of the DAMOVES score. *Eur J Intern Med* 2017; **41**:e15–e16.
 57. Ageno W, Donadini M. Breadth of complications of long-term oral anticoagulant care. *Hematology Am Soc Hematol Educ Program* 2018; **2018**:432–438.
 58. Klok FA, Niemann C, Dellas C, Hasenfuß G, Konstantinides S, Lankeit M. Performance of five different bleeding-prediction scores in patients with acute pulmonary embolism. *J Thromb Thrombolysis* 2016; **41**:312–320.
 59. Riva N, Bellesini M, Di Minno MN, Mumoli N, Pomero F, Franchini M, Fantoni C, Lupoli R, Brondi B, Borretta V, Bonfanti C, Ageno W, Dentali F. Poor predictive value of contemporary bleeding risk scores during long-term treatment of venous thromboembolism. A multicentre retrospective cohort study. *Thromb Haemost* 2014; **112**:511–521.
 60. Palareti G, Antonucci E, Mastroiaco D, Ageno W, Pengo V, Poli D, Testa S, Tosetto A, Prandoni P. The American College of Chest Physician score to assess the risk of bleeding during anticoagulation in patients with venous thromboembolism. *J Thromb Haemost* 2018; **16**:1994–2002.
 61. Klok FA, Hosel V, Clemens A, Yollo WD, Tilke C, Schulman S, Lankeit M, Konstantinides SV. Prediction of bleeding events in patients with venous thromboembolism on stable anticoagulation treatment. *Eur Respir J* 2016; **48**:1369–1376.
 62. Becattini C, Agnelli G, Schenone A, Eichinger S, Bucherini E, Silingardi M, Bianchi M, Moia M, Ageno W, Vandelli MR, Grandone E, Prandoni P; WARFASA Investigators. Aspirin for preventing the recurrence of venous thromboembolism. *N Engl J Med* 2012; **366**:1959–1967.
 63. Brighton TA, Eikelboom JW, Mann K, Mister R, Gallus A, Ockelford P, Gibbs H, Hague W, Xavier D, Diaz R, Kirby A, Simes J; ASPIRE Investigators. Low-dose aspirin for preventing recurrent venous thromboembolism. *N Engl J Med* 2012; **367**:1979–1987.
 64. Simes J, Becattini C, Agnelli G, Eikelboom JW, Kirby AC, Mister R, Prandoni P, Brighton TA; INSPIRE Study Investigators (International Collaboration of Aspirin Trials for Recurrent Venous Thromboembolism). Aspirin for the prevention of recurrent venous thromboembolism: the INSPIRE collaboration. *Circulation* 2014; **130**:1062–1071.

65. Weitz JI, Lensing AWA, Prins MH, Bauersachs R, Beyer-Westendorf J, Bounameaux H, Brighton TA, Cohen AT, Davidson BL, Decousus H, Freitas MCS, Holberg G, Kakkar AK, Haskell L, van Bellen B, Pap AF, Berkowitz SD, Verhamme P, Wells PS, Prandoni P. Rivaroxaban or aspirin for extended treatment of venous thromboembolism. *N Engl J Med* 2017; **376**:1211–1222.
66. Heit JA, Spencer FA, White RH. The epidemiology of venous thromboembolism. *J Thromb Thrombolysis* 2016; **41**:3–14.
67. Prins MH, Lensing AWA, Prandoni P, Wells PS, Verhamme P, Beyer-Westendorf J, Bauersachs R, Bounameaux H, Brighton TA, Cohen AT, Davidson BL, Decousus H, Kakkar AK, van Bellen B, Pap AF, Homering M, Tamm M, Weitz JI. Risk of recurrent venous thromboembolism according to baseline risk factor profiles. *Blood Adv* 2018; **2**:788–796.
68. Pengo V, Denas G, Zoppellaro G, Jose SP, Hoxha A, Ruffatti A, Andreoli L, Tincani A, Cenci C, Prisco D, Fierro T, Greslele P, Cafolla A, De Micheli V, Ghirarduzzi A, Tositto A, Falanga A, Martinelli I, Testa S, Barcellona D, Gerosa M, Banzato A. Rivaroxaban vs warfarin in high-risk patients with antiphospholipid syndrome. *Blood* 2018; **132**:1365–1371.
69. Agnelli G, Buller HR, Cohen A, Curto M, Gallus AS, Johnson M, Porcari A, Raskob GE, Weitz JI, Investigators P-E. Apixaban for extended treatment of venous thromboembolism. *N Engl J Med* 2013; **368**:699–708.
70. Vasanthamohan L, Boonyawat K, Chai-Adisaksotha C, Crowther M. Reduced-dose direct oral anticoagulants in the extended treatment of venous thromboembolism: a systematic review and meta-analysis. *J Thromb Haemost* 2018; **16**:1288–1295.
71. Francis CW, Kessler CM, Goldhaber SZ, Kovacs MJ, Monreal M, Huisman MV, Bergqvist D, Turpie AG, Ortel TL, Spyropoulos AC, Pabinger I, Kakkar AK. Treatment of venous thromboembolism in cancer patients with dalteparin for up to 12 months: the DALTECAN Study. *J Thromb Haemost* 2015; **13**:1028–1035.
72. Jara-Palomares L, Solier-Lopez A, Elias-Hernandez T, Asensio-Cruz M, Blasco-Esquival I, Marin-Barrera L, de la Borbolla-Artacho MR, Praena-Fernandez JM, Montero-Romero E, Navarro-Herrero S, Serrano-Gotarredona MP, Sánchez-Díaz JM, Palacios C, Otero R. Tinzaparin in cancer associated thrombosis beyond 6 months: TICAT study. *Thromb Res* 2017; **157**:90–96.
73. Mahe I, Chidiac J, Bertoletti L, Font C, Trujillo-Santos J, Peris M, Perez Ductor C, Nieto S, Grandone E, Monreal M; RIETE Investigators. The clinical course of venous thromboembolism may differ according to cancer site. *Am J Med* 2017; **130**:337–347.
74. Di Nisio M, van Es N, Carrier M, Wang TF, Garcia D, Segers A, Weitz J, Buller H, Raskob G. Extended treatment with edoxaban in cancer patients with venous thromboembolism: a post-hoc analysis of the Hokusai-VTE cancer study. *J Thromb Haemost* 2019; **17**:1866–1874.
75. Prandoni P, Kahn SR. Post-thrombotic syndrome: prevalence, prognostication and need for progress. *Br J Haematol* 2009; **145**:286–295.
76. Rabinovich A, Kahn SR. The postthrombotic syndrome: current evidence and future challenges. *J Thromb Haemost* 2017; **15**:230–241.
77. Rabinovich A, Ducruet T, Kahn SR; SOX Trial Investigators. Development of a clinical prediction model for the postthrombotic syndrome in a prospective cohort of patients with proximal deep vein thrombosis. *J Thromb Haemost* 2018; **16**:262–270.
78. Amin EE, van Kuijk SMJ, Joore MA, Prandoni P, Ten Cate H, Ten Cate-Hoek AJ. Development and validation of a practical two-step prediction model and clinical risk score for post-thrombotic syndrome. *Thromb Haemost* 2018; **118**:1242–1249.
79. Mean M, Limacher A, Alatri A, Aujesky D, Mazzolai L. Derivation and validation of a prediction model for risk stratification of post-thrombotic syndrome in elderly patients with a first deep vein thrombosis. *Thromb Haemost* 2018; **118**:1419–1427.
80. Wik HS, Ender TR, Ghanima W, Engeseth M, Kahn SR, Sandset PM. Diagnostic scales for the post-thrombotic syndrome. *Thromb Res* 2018; **164**:110–115.
81. Brandjes DP, Buller HR, Heijboer H, Huisman MV, de Rijk M, Jagt H, ten Cate JW. Randomised trial of effect of compression stockings in patients with symptomatic proximal-vein thrombosis. *Lancet* 1997; **349**:759–762.
82. Prandoni P, Lensing AW, Prins MH, Frulla M, Marchiori A, Bernardi E, Tormene D, Mosena L, Pagnan A, Girolami A. Below-knee elastic compression stockings to prevent the post-thrombotic syndrome: a randomized, controlled trial. *Ann Intern Med* 2004; **141**:249–256.
83. Kahn SR, Shapiro S, Wells PS, Rodger MA, Kovacs MJ, Anderson DR, Tagalakis V, Houweling AH, Ducruet T, Holcroft C, Johri M, Solymoss S, Miron MJ, Yeo E, Smith R, Schulman S, Kassiss J, Kearon C, Chagnon I, Wong T, Demers C, Hanmiah R, Kaatz S, Selby R, Rathbun S, Desmarais S, Opatryl L, Ortel TL, Ginsberg JS; SOX Trial Investigators. Compression stockings to prevent post-thrombotic syndrome: a randomised placebo-controlled trial. *Lancet* 2014; **383**:880–888.
84. Avila ML, Montoya M, Lumia C, Marson A, Brandao LR, Tomlinson G. Compression stockings to prevent post-thrombotic syndrome in adults, a Bayesian meta-analysis. *Thromb Res* 2019; **182**:20–26.
85. Mol GC, van de Ree MA, Klok FA, Tegelsberg MJ, Sanders FB, Koppen S, de Weerd O, Koster T, Hovens MM, Kaasjager HA, Brouwer RE, Kragten E, Schaar CG, Spiering W, Arnold WP, Biesma DH, Huisman MV. One versus two years of elastic compression stockings for prevention of post-thrombotic syndrome (OCTAVIA study): randomised controlled trial. *BMJ* 2016; **353**:i2691.
86. ten Cate-Hoek AJ, Amin EE, Bouman AC, Meijer K, Tick LW, Middeldorp S, Mostard GJM, ten Wolde M, van den Heiligenberg SM, van Wissen S, van de Poel MH, Villalta S, Serné EH, Otten H-M, Klappe EH, Bistervels IM, Lauw MN, Piersma-Wichers M, Prandoni P, Joore MA, Prins MH, Prins MH, ten Cate H, ten Cate-Hoek AJ, ten Cate H, Joore MA, Prins MH, Amin EE, Bouman AC, Meijer K, Piersma-Wichers M, Tick LW, Nijziel MR, Middeldorp S, Lauw M, Cheung YW, Mostard GJM, ten Wolde M, Bistervels IM, van den Heiligenberg SM, van Wissen S, van de Poel MHW, Otten H-M, Serné EH, Klappe EH, Prandoni P, Vedovetto V, Villalta S. Individualised versus standard duration of elastic compression therapy for prevention of post-thrombotic syndrome (IDEAL DVT): a multicentre, randomised, single-blind, allocation-concealed, non-inferiority trial. *Lancet Haematol* 2018; **5**:e25–e33.
87. Lichtenberg MKW. [Endovascular recanalization of chronic venous outflow obstructions]. *Dtsch Med Wochenschr* 2019; **144**:478–483.
88. Shamimi-Noori SM, Clark TWI. Venous stents: current status and future directions. *Tech Vasc Interv Radiol* 2018; **21**:113–116.
89. Lichtenberg M, de Graaf R, Erbel C. Standards for recanalisation of chronic venous outflow obstructions. *Vasa* 2018; **47**:259–266.
90. Bistervels IM, Scheres LJJ, Hamulyak EN, Middeldorp S. Sex matters: practice SP's when treating young women with venous thromboembolism. *J Thromb Haemost* 2019; **17**:1417–1429.
91. James AH, Jamison MG, Brancaccio LR, Myers ER. Venous thromboembolism during pregnancy and the postpartum period: incidence, risk factors, and mortality. *Am J Obstet Gynecol* 2006; **194**:1311–1315.
92. Wik HS, Jacobsen AF, Sandvik L, Sandset PM. Long-term impact of pregnancy-related venous thrombosis on quality-of-life, general health and functioning: results of a cross-sectional, case-control study. *BMJ Open* 2012; **2**:e002048.
93. Le Gal G, Kercet G, Ben Yahmed K, Bressollette L, Robert-Ebadi H, Riberdy L, Louis P, Delluc A, Labalette ML, Baba-Ahmed M, Bounameaux H, Mottier D, Righini M; EDVIGE Study Group. Diagnostic value of single complete compression ultrasonography in pregnant and postpartum women with suspected deep vein thrombosis: prospective study. *BMJ* 2012; **344**:e2635.
94. Chan WS, Lee A, Spencer FA, Crowther M, Rodger M, Ramsay T, Ginsberg JS. Predicting deep venous thrombosis in pregnancy: out in "LEFT" field? *Ann Intern Med* 2009; **151**:85–92.
95. Le Moigne E, Genty C, Meunier J, Arnoult AC, Righini M, Bressollette L, Bosson JL, Le Gal G; OPTIMEV Investigators. Validation of the LEFT score, a newly proposed diagnostic tool for deep vein thrombosis in pregnant women. *Thromb Res* 2014; **134**:664–667.
96. Chan WS, Spencer FA, Lee AY, Chunilal S, Douketis JD, Rodger M, Ginsberg JS. Safety of withholding anticoagulation in pregnant women with suspected deep vein thrombosis following negative serial compression ultrasound and iliac vein imaging. *CMAJ* 2013; **185**:E194–E200.
97. Bates SM, Rajasekhar A, Middeldorp S, McLintock C, Rodger MA, James AH, Vazquez SR, Greer IA, Riva JJ, Bhatt M, Schwab N, Barrett D, LaHaye A, Rochwerf B. American Society of Hematology 2018 guidelines for management of venous thromboembolism: venous thromboembolism in the context of pregnancy. *Blood Adv* 2018; **2**:3317–3359.
98. Middeldorp S. How I treat pregnancy-related venous thromboembolism. *Blood* 2011; **118**:5394–5400.
99. Stegeman BH, de Bastos M, Rosendaal FR, van Hylckama Vlieg A, Helmerhorst FM, Stijnen T, Dekkers OM. Different combined oral contraceptives and the risk of venous thrombosis: systematic review and network meta-analysis. *BMJ* 2013; **347**:f5298.
100. Bleker SM, Coppens M, Middeldorp S. Sex, thrombosis and inherited thrombophilia. *Blood Rev* 2014; **28**:123–133.
101. Douketis J, Tositto A, Marcucci M, Baglin T, Cosmi B, Cushman M, Kyrle P, Poli D, Tait RC, Iorio A. Risk of recurrence after venous thromboembolism in men and women: patient level meta-analysis. *BMJ* 2011; **342**:d813.
102. Martinelli I, Lensing AW, Middeldorp S, Levi M, Beyer-Westendorf J, van Bellen B, Bounameaux H, Brighton TA, Cohen AT, Trajanovic M, Gebel M, Lam P, Wells PS, Prins MH. Recurrent venous thromboembolism and abnormal uterine bleeding with anticoagulant and hormone therapy use. *Blood* 2016; **127**:1417–1425.
103. Stam-Slob MC, Lambalk CB, van de Ree MA. Contraceptive and hormonal treatment options for women with history of venous thromboembolism. *BMJ* 2015; **351**:h4847.

104. Kucher N. Clinical practice. Deep-vein thrombosis of the upper extremities. *N Engl J Med* 2011;**364**:861–869.
105. Grant JD, Stevens SM, Woller SC, Lee EW, Kee ST, Liu DM, Lohan DG, Elliott CG. Diagnosis and management of upper extremity deep-vein thrombosis in adults. *Thromb Haemost* 2012;**108**:1097–1108.
106. Thompson JF, Winterborn RJ, Bays S, White H, Kinsella DC, Watkinson AF. Venous thoracic outlet compression and the Paget-Schroetter syndrome: a review and recommendations for management. *Cardiovasc Intervent Radiol* 2011;**34**:903–910.
107. Constans J, Salmi L-R, Sevestre-Pietri M-A, Perusat S, Nguon M, Degeilh M, Labarere J, Gattolliat O, Boulon C, Laroche J-P, Le Roux P, Pichot O, Quéré I, Conri C, Bosson J-L. A clinical prediction score for upper extremity deep venous thrombosis. *Thromb Haemost* 2008;**99**:202–207.
108. Sartori M, Migliaccio L, Favaretto E, Cini M, Legnani C, Palareti G, Cosmi B. D-dimer for the diagnosis of upper extremity deep and superficial venous thrombosis. *Thromb Res* 2015;**135**:673–678.
109. Kleinjan A, Di Nisio M, Beyer-Westendorf J, Camporese G, Cosmi B, Ghirarduzzi A, Kamphuisen PW, Otten H-M, Porreca E, Aggarwal A, Brodmann M, Guglielmi MD, Iotti M, Kaasjager K, Kamvissi V, Lerede T, Marschang P, Meijer K, Palareti G, Rickles FR, Righini M, Rutjes AWS, Tonello C, Verhamme P, Werth S, van Wissen S, Büller HR. Safety and feasibility of a diagnostic algorithm combining clinical probability, d-dimer testing, and ultrasonography for suspected upper extremity deep venous thrombosis: a prospective management study. *Ann Intern Med* 2014;**160**:451–457.
110. Di Nisio M, Van Sluis GL, Bossuyt PM, Buller HR, Porreca E, Rutjes AW. Accuracy of diagnostic tests for clinically suspected upper extremity deep vein thrombosis: a systematic review. *J Thromb Haemost* 2010;**8**:684–692.
111. Ferro JM, Coutinho JM, Dentali F, Kobayashi A, Alasheev A, Canhao P, Karpov D, Nagel S, Posthuma L, Roriz JM, Caria J, Frassdorf M, Huisman H, Reilly P, Diener HC; for the RE-SPECT CVT Study Group. Safety and efficacy of dabigatran etexilate vs dose-adjusted warfarin in patients with cerebral venous thrombosis: a randomized clinical trial. *JAMA Neurol* 2019;**76**:1457.
112. Wells PS, Anderson DR, Rodger M, Ginsberg JS, Kearon C, Gent M, Turpie AG, Bormanis J, Weitz J, Chamberlain M, Bowie D, Barnes D, Hirsh J. Derivation of a simple clinical model to categorize patients probability of pulmonary embolism: increasing the models utility with the SimpliRED D-dimer. *Thromb Haemost* 2000;**83**:416–420.
113. DOAC in Unusual Site Venous Thrombosis (DUST study). <https://ClinicalTrials.gov/show/NCT03778502> (last accessed 2020).
114. Schulman S, Gross PL, Ritchie B, Nahirniak S, Lin Y, Lieberman L, Carrier M, Crowther MA, Ghosh I, Lazo-Langner A, Zondag M; Study Investigators. Prothrombin complex concentrate for major bleeding on factor Xa inhibitors: a prospective cohort study. *Thromb Haemost* 2018;**118**:842–851.
115. Pollack CV Jr, Reilly PA, van Ryn J, Eikelboom JW, Glund S, Bernstein RA, Dubiel R, Huisman MV, Hylek EM, Kam CW, Kamphuisen PW, Kreuzer J, Levy JH, Royle G, Sellke FW, Stangier J, Steiner T, Verhamme P, Wang B, Young L, Weitz JI. Idarucizumab for dabigatran reversal—full cohort analysis. *N Engl J Med* 2017;**377**:431–441.
116. Connolly SJ, Crowther M, Eikelboom JW, Gibson CM, Curnutte JT, Lawrence JH, Yue P, Bronson MD, Lu G, Conley PB, Verhamme P, Schmidt J, Middeldorp S, Cohen AT, Beyer-Westendorf J, Albaladejo P, Lopez-Sendon J, Demchuk AM, Pallin DJ, Concha M, Goodman S, Leeds J, Souza S, Siegal DM, Zotova E, Meeks B, Ahmad S, Nakamya J, Milling TJ Jr; ANNEXA-4 Investigators. Full study report of andexanet alfa for bleeding associated with factor Xa inhibitors. *N Engl J Med* 2019;**380**:1326–1335.
117. Majeed A, Ågren A, Holmström M, Bruzelius M, Chairati R, Odeberg J, Hempel EL, Magnusson M, Frisk T, Schulman S. Management of rivaroxaban- or apixaban-associated major bleeding with prothrombin complex concentrates: a cohort study. *Blood* 2017;**130**:1706–1712.
118. Arachchilage DRJ, Alavian S, Griffin J, Gurung K, Szydlo R, Karawitige N, Laffan M. Efficacy and safety of prothrombin complex concentrate in patients treated with rivaroxaban or apixaban compared to warfarin presenting with major bleeding. *Br J Haematol* 2019;**184**:808–816.
119. Burstein B, Barbosa RS, Kalfon E, Joza J, Bernier M, Essebag V. Venous thrombosis after electrophysiology procedures: a systematic review. *Chest* 2017;**152**: 574–586.
120. Calkins H, Hindricks G, Cappato R, Kim YH, Saad EB, Aguinaga L, Akar JG, Badhwar V, Brugada J, Camm J, Chen PS, Chen SA, Chung MK, Cosedis Nielsen J, Curtis AB, Davies DW, Day JD, d'Avila A, Natasja de Groot NMS, Di Biase L, Duytschaever M, Edgerton JR, Ellenbogen KA, Ellinor PT, Ernst S, Fenelon G, Gerstenfeld EP, Haines DE, Haissaguerre M, Helm RH, Hylek E, Jackman WM, Jalife J, Kalman JM, Kautzner J, Kottkamp H, Kuck KH, Kumagai K, Lee R, Lewalter T, Lindsay BD, Macle L, Mansour M, Marchlinski FE, Michaud GF, Nakagawa H, Natale A, Nattel S, Okumura K, Packer D, Pokushalov E, Reynolds MR, Sanders P, Scanavacca M, Schilling R, Tondo C, Tsao HM, Verma A, Wilber DJ, Yamane T. 2017 HRS/EHRA/ECAS/APHRS/SOLAECE expert consensus statement on catheter and surgical ablation of atrial fibrillation. *Europace* 2018;**20**:e1–e160.
121. Burstein B, Barbosa RS, Samuel M, Kalfon E, Philippon F, Birnie D, Mangat I, Redfearn D, Sandhu R, Macle L, Sapp J, Verma A, Healey JS, Becker G, Chauhan V, Couto B, Roux JF, Leong-Sit P, Andrade JG, Veenhuyzen GD, Joza J, Bernier M, Essebag V. Prevention of venous thrombosis after electrophysiology procedures: a survey of national practice. *J Interv Card Electrophysiol* 2018;**53**:357–363.
122. Saunderson C, Hickman S, Wilkinson E, Tayebjee M. Current venous thromboembolism prevention practices following endovascular electrophysiological procedures in the UK: a retrospective study. *Sultan Qaboos Univ Med J* 2018;**18**: e374–e378.