



Article scientifique

Article

2019

Published version

Open Access

This is the published version of the publication, made available in accordance with the publisher's policy.

---

## Osteonecrosis of the femoral head: pathophysiology and current concepts of treatment

---

Petek, Daniel Antonino; Hannouche, Didier; Suva, Domizio

### How to cite

PETEK, Daniel Antonino, HANNOUCHE, Didier, SUVA, Domizio. Osteonecrosis of the femoral head: pathophysiology and current concepts of treatment. In: EFORT Open Reviews, 2019, vol. 4, n° 3, p. 85–97. doi: 10.1302/2058-5241.4.180036

This publication URL: <https://archive-ouverte.unige.ch/unige:116836>

Publication DOI: [10.1302/2058-5241.4.180036](https://doi.org/10.1302/2058-5241.4.180036)



# Osteonecrosis of the femoral head: pathophysiology and current concepts of treatment

Daniel Petek<sup>1</sup>  
Didier Hannouche<sup>2</sup>  
Domizio Suva<sup>2</sup>

- Osteonecrosis of the femoral head is a disabling pathology affecting a young population (average age at treatment, 33 to 38 years) and is the most important cause of total hip arthroplasty in this population. It reflects the endpoint of various disease processes that result in a decrease of the femoral head blood flow.
- The physiopathology reflects an alteration of the vascularization of the fine blood vessels irrigating the anterior and superior part of the femoral head. This zone of necrosis is the source of the loss of joint congruence that leads to premature wear of the hip.
- Several different types of medication have been developed to reverse the process of ischemia and/or restore the vascularization of the femoral head. There is no consensus yet on a particular treatment.
- The surgical treatments aim to preserve the joint as far as the diagnosis could be made before the appearance of a zone of necrosis and the loss of joint congruence. They consist of bone marrow decompressions, osteotomies around the hip, vascular or non-vascular grafts.
- Future therapies include the use of biologically active molecules as well as implants impregnated with biologically active tissue.

**Keywords:** femoral head; avascular necrosis; osteonecrosis

Cite this article: *EFORT Open Rev* 2019;4:85-97.  
DOI: 10.1302/2058-5241.4.180036

## Introduction

Osteonecrosis (ON), also defined as avascular necrosis or aseptic necrosis, is characterized as bone cell death that follows an impairment of the blood flow to the bone from a traumatic or non-traumatic origin.<sup>1</sup> ON most often happens in the hip joint (femoral head) but may also

occur in other anatomical locations (e.g. shoulder, knee and ankle). The observed incidence of ON in a study population in the UK between 1989 and 2003 was in the range of 1.4 to 3.0 per 100 000. The hip joint was mostly involved, accounting for 75.9% of cases.<sup>2</sup>

In the United States, epidemiological data have reported an incidence of ON of the femoral head (ONFH) in the general population between 300 000 and 600 000 cases in the early 2000s.<sup>3</sup> The onset of the disease remains stable and represents about 10 000 to 20 000 new cases each year.<sup>4</sup> These values are comparable with other countries as an analysis of the Japanese population has shown an incidence rate of 1.9 per 100 000.<sup>5</sup> The average age of the affected patients is 47 years and there is a male to female ratio of 3:1.

The Canadian, Swedish and Australian registries have demonstrated that this diagnosis accounts for about 2.8% to 6% of all primary total hip replacements. Early diagnosis is therefore critical as it affects essentially the young and middle-aged population and because a progression of the disease to a collapse of the femoral head is seen in up to 80% of patients if left untreated.<sup>6</sup> In addition, this condition may affect both hips in 40% to 70% of cases, depending on the series published.<sup>7</sup>

As stated, ONFH is characterized by a compromised subchondral microcirculation, especially in the small retinacular vessels, which ultimately leads to necrosis of bone.<sup>8</sup> An accumulation of microfractures is seen and, as there is no bone remodelling, a collapse of the subchondral bone occurs.

The clinical presentation is quite aspecific and mainly concerns groin pain irradiating to the knee.<sup>9</sup> There is some limited hip range of motion seen, especially in internal forced rotation. Therefore, a patient history is crucial to raise the suspicion of the disease and to investigate the opposite side, as it may also be affected.

The aim of this article is to present the pathophysiology of the ONFH and understand its underlying causes. The different pharmacological and surgical treatment options will also be reviewed as well as future strategies.

## Pathophysiology

Most theories point towards an alteration in the intravascular blood flow<sup>10</sup> as the potential mechanism of ON initiation. These alterations may occur either from a traumatic or a non-traumatic cause or be a consequence of some well-accepted risk factors. Regarding the traumatic cause, it is important to notice that the majority of the blood supplied originates from the retinacula arteries supplying the superolateral weight-bearing portion of the femoral head.<sup>11</sup> These retinacular vessels originate from the lateral epiphyseal artery which is a branch of the medial circumflex arteries. Among traumatic causes, physical trauma, decompression sickness or radiation may be cited. In the non-trauma cases, two theories are disputed: the first concerns the occurrence of an intravascular coagulation and the second one attributes the ischaemia to extravascular compression.

Intravascular coagulation can occur as the end result of local vascular impairment; vascular occlusion occurs because of thrombus formation due to abnormally shaped red blood cells as seen in sickle cells anaemia or fat or nitrogen embolism.<sup>12,13</sup> Extravascular compression may arise secondary to damaged femoral head vessels that permit the accumulation of fat and blood in the extravascular space which leads to alterations in blood flow through local compression.

Moreover, it is nowadays admitted that the pathophysiological mechanism arises from an interaction between vascular impairment, altered bone-cell physiology, risk factors as well as genetics.<sup>14</sup> Vascular impairment appears as the end result of coagulation disorders seen in hypercoagulable conditions such as sickle cell anaemia, hereditary thrombophilia, antiphospholipid antibodies, malignancy and inflammatory bowel disease. An altered cell-bone physiology is often proposed as being part of the osteonecrotic process and the hypothesis is that ON appears secondary to impaired mesenchymal differentiation which leads to a damage of the bone structure. Under physiological conditions, it needs about three months to build new bone with effective mechanical properties whereas it needs three weeks for osteoclast to affect mechanical strength of the trabecular bone. So, any dysfunction of the mesenchymal cell that lead to changes in osteogenic differentiation and alterations in blood flow through an increased adipogenic volume would ultimately support the ON of the femoral head.

The most often cited risk factors are corticoid administration<sup>15-18</sup> and alcohol intake.<sup>19-21</sup> Corticoid administration induces a vasoconstriction and leads to an increase of a procoagulant factor production. It also increases adipogenesis, decreases osteogenesis and downregulates osseous repair and remodelling through

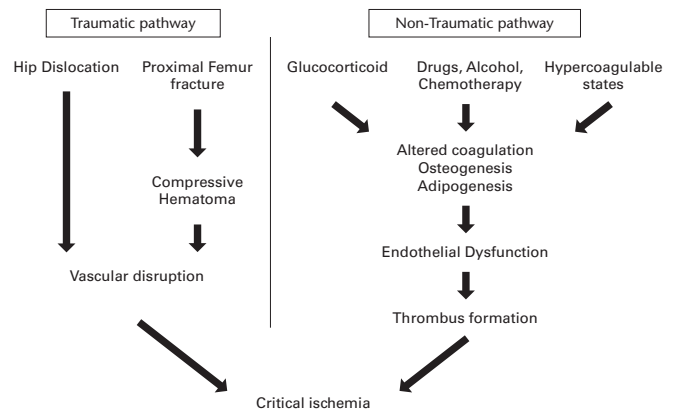


Fig. 1 Different pathways participating in ONFH.

fatty emboli production. In a recent review article, Wang et al listed five major theories about the pathogenesis of steroid-induced ONFH (SONFH): lipid metabolism disorders; decreased osteogenesis potential; insufficient blood supply; cell apoptosis; and gene polymorphism. The authors concluded that SONFH is the end result of a combined action of multiple mechanisms related to steroid use.<sup>22</sup> Various reports have concluded that cortisone may be described as an independent variable especially in high doses and that it increases the risk of osteonecrosis up to 20 times.<sup>23</sup> Alcohol consumption would alter the mesenchymal differentiation and many studies had shown that there is a reduced ability to differentiate toward an osteoblastic lineage.<sup>24</sup> Therefore, both cortisone and alcohol have a profound effect on bone marrow differentiation and blood supply. However, these studies do not explain why the vast majority of patients who abuse alcohol never develop the disease. There is a hypothesis of a genetic participation in the disease and some authors have identified a 3-family's lineage in which an autosomal dominant inheritance of ON has been described. That autosomal dominant gene mutation is mapped to chromosome 12-13 and is associated with type II collagen abnormalities which participate in the occurrence of OFNH.<sup>14</sup> However, until now there are no screening markers available (Fig. 1).

Whatever the underlying cause, all forms of ON of the femoral head are related to blood flow impairments. After the onset of ischaemia, histological signs of marrow necrosis and osteocyte death become apparent within 24 to 72 hours. Then, a saponification of free fatty acids appears within the extracellular matrix as well as a calcium ion expression that leads to an inflammatory response. Finally, the acellular trabecular bone is replaced by inferior woven bone that does not tolerate normal loading and collapse may occur.

## Imaging and evaluation

As OFNH is an evolving disease, its diagnosis may need different radiological modalities, which range from standard radiograph, MRI and CT to radionuclide examinations. Radiolucency, sclerosis or bone resorption are best seen on MRI and CT whereas degenerative changes due to collapse are easily seen on plain films (Fig. 2). Still, CT scans show the necrotic changes in more advanced stages and are less sensitive than MRI for early stages.<sup>25</sup> Radionuclide studies may be used for early diagnosis of ONFH. From all the different radionuclide modalities, positron emission tomography (PET) provides a real-time image of the bony physiology. It is assumed that PET scans detect ON even earlier than MRI and also help predict the progression of the disease.<sup>26</sup>

MRI remains the gold standard in detecting pre-collapse lesions and allows differentiating ONFH from diagnosis such as a transitioned osteopenia of the femoral head or bone bruises. MRI has a sensitivity and specificity of about 99%. The T1 sequences would point out an infarcted area which is hypodense surrounded by a single hyperdense line separating normal from osteoporotic bone. T2 sequences will show ‘another line within that first line’, representing an increased vascularity in granulation tissues. (Fig. 3). The issue of the imaging evaluation concerns the integrity of the femoral head, the size of the lesion, the presence of a depression of the femoral head or an acetabular involvement of the present of a bone marrow oedema.

The integrity of the femoral head allows defining *versus* post-collapse lesions and if the integrity is lost due to mechanical failure the ‘crescent sign’ will appear (Fig. 4). The size of the lesion also helps to predict the outcome as described by Kerboul,<sup>27</sup> who measured the necrotic angle value seen on coronal and sagittal views. In another publication, 37 hips were measured and it was demonstrated that all hips with a value of 240° or more collapsed, all hips

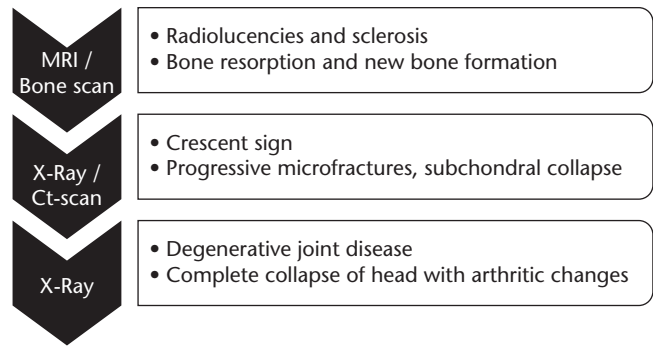


Fig. 2 Radiological aspects according to modality.

with a value < 180° survived and 4/8 hips between 190° and 240° collapsed.<sup>28</sup>

A femoral head depression is described when there is a change in the femoral head contour of > 2 mm which may lead to a worse prognosis.<sup>29</sup> This fact is supported by a cross-sectional study of 68 hips (52 patients) suffering from ONFH. It has been seen that 22/24 hips (92%) with a head depression < 2 mm required a total hip arthroplasty (THA). In addition, if the MRI shows an implication of the acetabular wall, the treatments for femoral head savings have been demonstrated to be unsuccessful (Fig 5).<sup>4</sup> Those cases require a THA.

An essential factor that has been associated with progression of the symptoms is the presence or appearance of bone marrow oedema. In a series of 83 asymptomatic or minimalist symptomatic hips (63 patients) that have been analysed prospectively with MRI on a mean follow-up of 60 months, it appears that 27/28 hips that became symptomatic presented the presence of bone marrow oedema. Those that stayed asymptomatic (36/83 hips) did not show the presence or appearance of bone oedema. The study concluded that appearance of bone oedema on MRI is correlated with worsening of hip pain. However, the authors pointed out the need to distinguish ONFH from the other differential diagnoses that cause bone marrow oedema.<sup>30</sup>

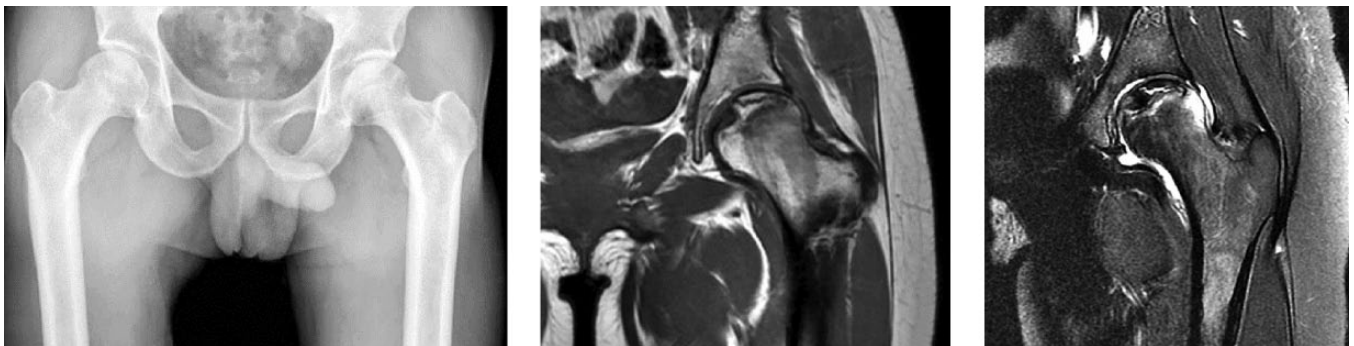


Fig. 3 Grade I ONFH on a) plain radiograph, b) T1 and c) T2.

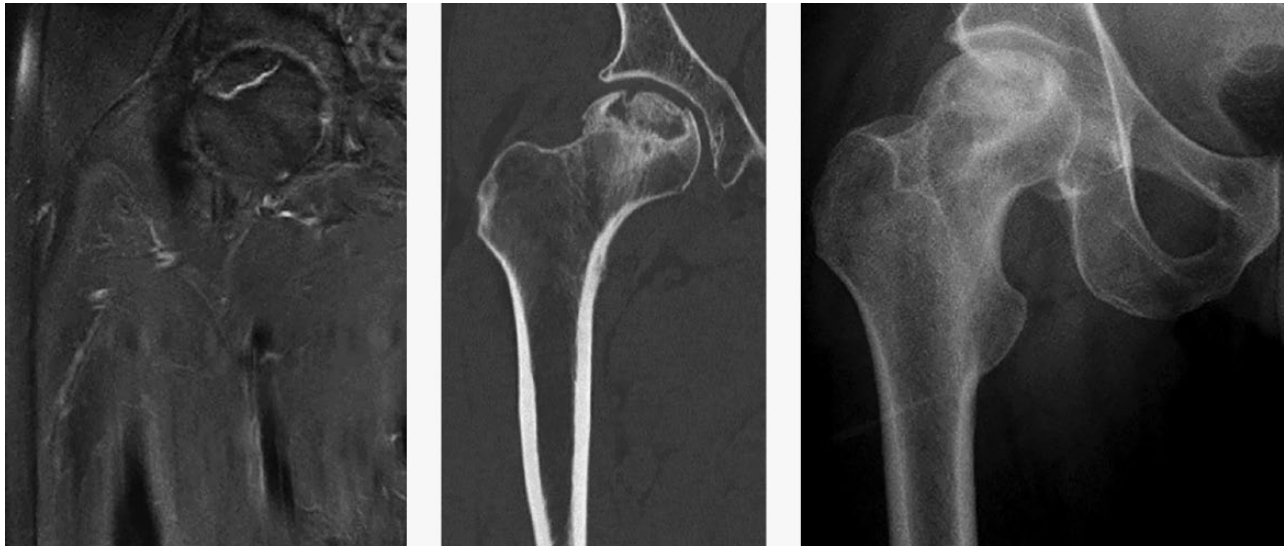

Fig. 4 Crescent sign on a) MRI T2, b) CT scan c) radiograph.

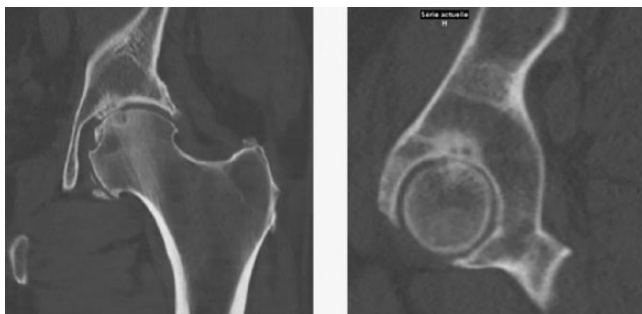


Fig. 5 Involvement of the acetabulum.

### Classification

In the literature, there have been more than 16 different classifications described for ONFH, most of them based on MRI and radiographs. The disease classification allows determining a prognosis and gives an orientation in the treatment options. The most commonly used classifications in the literature are Ficat and Arlet (63% of studies; Table 1), Steinberg (20%; Table 2), Association Research Circulation Osseous (ARCO) (12%) and the Japanese Orthopedic Association (5%).<sup>7</sup>

Despite its popularity, the Ficat classification (Table 1) lacks intra-observer and inter-observer reliability. It does not consider the size and location of the necrotic area. The ARCO classifications include the missing parameters from the Ficat classification in terms of location and quantitation (percentage of area involvement, length of crescent, percentage of surface collapse and dome depression). However, its inter-observer and intra-observer reliability remains poor to fair. The Steinberg classification (Table 2) includes the symptomatology especially in terms of worsening or

Table 1. Ficat and Arlet classification

Stage	Findings
1	Normal radiograph
2	Normal femoral head sphericity. Some signs of bone remodelling such as cysts or osteosclerotic regions
3	Subchondral collapse or flattening of the femoral head
4	Degenerative changes are seen in the acetabulum with narrowing of the joint space

persistent pain, which may be used to differentiate the pre-collapse from post-collapse lesion.<sup>31</sup>

Basically, all those classifications aim to differentiate the pre-collapse lesion which allows conservative treatment or aim to have a conservative surgery that preserves the femoral head from the post-collapse lesion which tend to be treated with THA.

### Treatment

Conservative treatment including restricted weight-bearing activities of the hip joint has been described as primary treatment of ONFH. Conservative treatment has been proposed only for early stages with very small lesions or among patients where surgical management is contra-indicated. It therefore concerns essentially the cases staged 0 and 1 after Steinberg's classification or 0 and 1 after ARCO's classification. In a meta-analysis of 21 studies concerning 819 hips, there was no difference between full, partial or non-weight bearing groups.<sup>32</sup> In their conclusions, the authors stated that weight-bearing modifications which would aim to reduce the joint reactive forces towards the femoral head did not delay the progression of the disease and are thus not to

**Table 2. Steinberg classification**

Stage	Findings
0	No symptoms Normal radiograph MRI non-specific
1	Mild pain in the affected hip, or pain with internal rotation Normal radiograph MRI diagnostic
2	Worsening or persistent pain Increased sclerosis or cysts in the femoral head
3	Subchondral collapse (crescent sign)
4	Flattening of the femoral head Normal joint space
5	Narrowing of the joint space with/without femoral head involvement
6	Advanced degenerative changes

be considered as a beneficial trial treatment for ONFH. However, in a more recent randomized prospective study, physical therapy alone appeared to be as effective as hip core decompression (CD) followed by physical therapy in improving hip function and delaying additional surgeries.<sup>33</sup> This study was conducted in a specific sub-group of patients with sickle cell disease and therefore more controlled trials need to be conducted to evaluate the benefits of conservative treatments.

It is of interest to notice that in a study published by Villa et al, the authors pointed out that half of the cases may be anticipated as the vast majority of cases concern the use of steroids and alcohol. Therefore, an interdisciplinary approach for those patients is recommended because when symptomatic the evolution towards a collapse within the six months is inevitable.<sup>34</sup>

## Pharmacological agents

As described previously, both traumatic pathways and non-traumatic pathways have been described to lead to critical ischaemia of the retinacular vessels of the femoral head (Fig.1). The traumatic pathway concerns essentially hip dislocation or femoral neck fractures and needs to be treated surgically in order to decompress the intracapsular hematoma and to restore the blood flow in the femoral head as soon as possible. On the non-traumatic pathway, there are some medications that have been proposed to be started before critical ischaemia occurs and these consist of the use of statins or enoxaparin to prevent, first, endothelial dysfunction and, second, thrombosis formation. Statins reduce the bone marrow adipocyte size and protect against corticoid-induced ON. However, there is no high-level evidence to support the routine use of statins for high-risk patients. In a study of more than 2881 transplanted patients under cortisone, there was no significant evidence between those receiving or not receiving statins, even if ONFH developed in 4.4% of patients receiving statins and in 7.0% in those not receiving statins.<sup>35</sup> Regarding enoxaparin, there is no evidence of a superior

outcome from patients receiving this medication to prevent thrombosis formation from those who do not. However, in specific hyper coagulable states, the use of enoxaparin gives positive results as demonstrated by Glueck et al, who evaluated 20 patients with Ficat stages I or II at a mean follow-up of two years. From the group receiving enoxaparin, only one hip progressed to necrosis.<sup>36</sup> To be able to reach a conclusion about these two products, more specific subgroup studies are needed.

Once critical ischaemia has occurred, there are some medications that are aimed to prevent osteoblastic and osteocyte necrosis. Iloprost, a prostaglandin analogue that causes a systemic dilatation and inhibits platelet aggregation in order to decrease the bone marrow oedema, is often used for treatment. Disch et al concluded, in a study of 40 patients in a pre-collapse state treated with iloprost, that no surgery was needed and there was no collapse seen in the follow-up of 25 months. All patients had improvement in terms of pain and clinical function; however, in these early stages it is difficult to be clearly objective of the ONFH diagnosis from the above-mentioned differential diagnosis.<sup>37</sup>

Hyperbaric oxygen therapy (HBO) has been postulated to reverse cellular ischaemia and to diminish the inflammatory response for the symptomatic early stage ONFH. HBO is supposed to facilitate the oxygenation of hypoxic bony tissue and to reduce the oedema by creating a high concentration of dissolved oxygen. By doing so, the extracellular fluid will be saturated with diffused oxygen which will induce an oxygenation of the ischemic bone cells. The bone cells will therefore not need to rely on circulating haemoglobin. A study published by Camporesi et al showed positive results in a randomized controlled trial (RCT) concerning 20 oxygen treatments in a hyperbaric chamber. All the patients remained asymptomatic in the seven years of follow-up.<sup>38</sup> In a review of the current literature, eight clinical studies have been analysed. The authors concluded that, as part of the studies were either small-scale, heterogeneous or methodology weak, it was not possible to draw firm conclusions. However, the authors accepted that there is a place for HBO therapy in the management of ONFH but further RCTs are required.<sup>39</sup>

Bisphosphonates belong to a class of drug that has an effect on bone resorption by preventing the formation of woven bone as they reduce bone turnover and remodelling. They are supposed to increase osteoclast apoptosis and reduce osteocyte and osteoblast apoptosis and are usually used to treat diseases involving bone resorption progression, such as osteoporosis, Paget's disease and fibrous dysplasia. In a RCT of 44 hips treated for two months published by Lai et al, a diminished rate of progression of the disease has been described.<sup>40</sup> However, in a multicentre double-blind study of 65 treated hips, there were no differences shown between the alendronate and

placebo regarding the rate of progression to THA or quality of life after two years of follow-up.<sup>41</sup> This failure to improve the radiological and functional outcome of the bisphosphonate has also been reported by a review of RCTs comparing bisphosphonate *versus* controlled treatment.<sup>34</sup> In that study, Villa et al concluded that there is a lowering of the risk of femoral head collapse in patients treated with CD associated with bone marrow mononuclear cells (BMMCs) when compared with CD alone or with the use of bisphosphonates. On the other hand, and based on the outcomes of a recent meta-analysis conducted by Li et al, the authors found the mean epiphyseal quotient that stands for the height at the centre of the femoral head over the width, was improved in the bisphosphonate group. One of their conclusions was that the use of bisphosphonates exerts effects on protecting the femoral head morphology. At the same time, the bone volume, trabecular number, trabecular thickness and trabecular separation factors used to assess bone mass of the femoral head in the animal model were all significantly improved by bisphosphonate use, a finding that was very encouraging. Still, those results were not correlated to either symptomatology or end-stage complications.<sup>42</sup>

Extracorporeal shockwave therapy (ESWT), which was initially developed for breaking renal stones, has shown to increase the density of bone around the pelvis. This is postulated through the increase of the osteoblastic activity and stimulation of BNP-2 and VEGF factors. Encouraging results about this technique have been postulated in a review of five studies published by Alves et al.<sup>43</sup> Still, the authors stated that there were no controlled or double-blind studies about the efficacy of ESWT in the treatment of ONFH. Recently, Russo et al published a review of > 600 hips with Ficat stages I and II treated with ESWT. They noted a disappearance of pain in 36% of cases, a stable reduction of pain of at least 70% in 43% of cases and no improvement in 21% of cases.<sup>44</sup> As it is not widely used in standard practice, more RCTs assessing that therapy are required.

### Surgical procedures

On a simple base, the surgical procedures that are used to treat ONFH may be separated between the femoral head sparing procedures and the arthroplasty procedures. As a matter of fact, as long as the sub-chondral bone has collapsed, there are no other surgeries suggested but the implementation of a THA (Fig. 6).

For all other pre-collapsed lesions and due to the young age of most patients, femoral head sparing procedures shall be emphasized (Fig. 7). These conservative procedures may be described as follows: CD; non-vascularized bone grafting; vascularized bone grafting; and proximal femoral osteotomies.

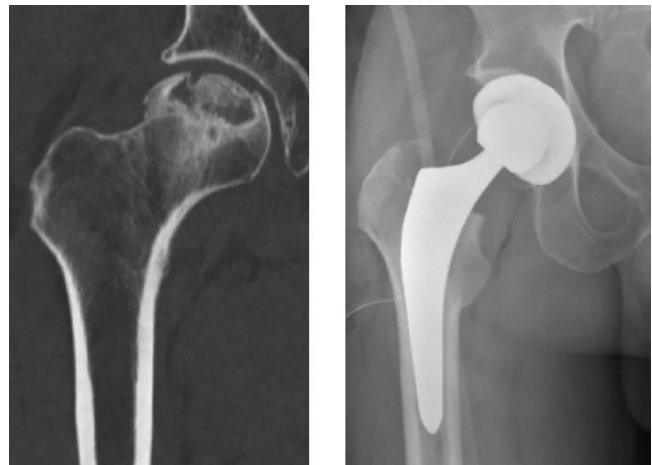

Fig. 6 Total hip replacement in advanced femoral head collapse after ONFH.

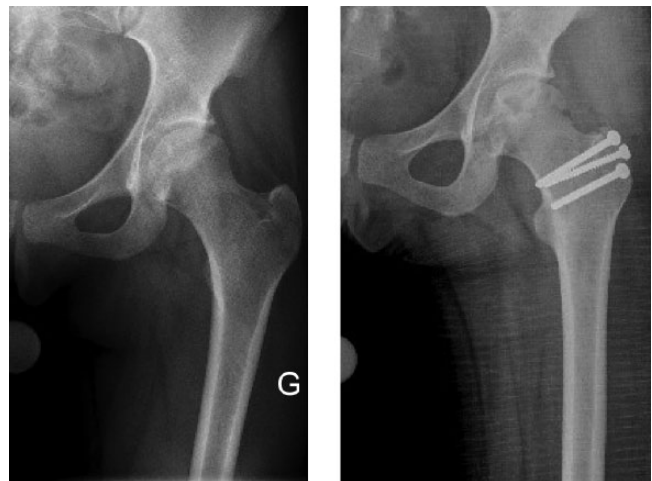

Fig. 7 Conservative surgery consisting of hip dislocation and non-vascular bone grafting.

The above-mentioned procedures are aimed at treating pre-collapse lesions and have been used for many years to try to reverse the adverse effects of the disease. The evolution of practice has nowadays integrated human mesenchymal cells as well as bone morphogenetic proteins (BMPs) to enhance the results of surgery. Some of those new approaches consist of: bone graft enhanced with mesenchymal cells; bone graft enhanced with BMP; and use of porous tantalum.

### Core decompression

CD was initially developed in order to acquire biopsy specimens to allow diagnosis making. It was described by Ficat and is a commonly used method for treating pre-collapse lesions. It is supposed to reduce the intraosseous pressure

as well as to restore the vascular inflow of the femoral head. Ficat et al have described, in their original study of 133 hips, that good results were obtained in 90% of all patients with grade I and II of the disease<sup>45</sup> and that minimal disease progression has been described after a mean follow-up of 9.5 years. In a meta-analysis published by Mont et al in 1996 and consisting of 24 reports where 1206 hips had been treated with CD, the overall clinical success rate reached 63.5%. Less than 33% required further surgery.<sup>32</sup> On the other hand, from the 819 hips treated non-operatively, only 22.7% showed a satisfactory outcome. It should be noted that the hips treated operatively with CD were mixed between CD with or without cancellous bone grafting.

The surgical technique of CD initially consists of using 8 to 10 mm trephines which are used to drill multiple holes in the femoral neck in order to give easier access to the anterior portion of the femoral head as well as to lower the risk of cartilage lesion and to decrease the risk of fracture. Also, CD, through the canal created in the bone, allows, if needed, the insertion of adjuvants such as bone marrow cells or expanded mesenchymal cells. Some authors have tried to compare the use of bone marrow cells during the CD procedure. For instance, in 2004 Gangji et al published a study of 24 hips staged I and II that were randomized into a treatment of CD alone or CD associated with bone marrow transplant. They concluded that there was a longer time needed to show signs of osseous collapse in the group of CD associated with bone marrow. However, there were no differences in surgical timing for an eventual conversion to a THA.<sup>46</sup> In 2012, Zhao et al published the use of mesenchymal cells (harvested from a subtrochanteric bone at the time of CD) that were then expanded and reinjected. The authors concluded that the injected hips exhibited less post-operative pain and had a lower progression rate of the disease at five years.<sup>47</sup> No statement was made regarding the time to THA.

The actual recommendations about CD are that it is a more cost-effective choice than observation alone. It produces best results in hips without evidence of subchondral collapse and it is the first line treatment for Ficat stages I and II. However, the indications are not actually clear after > 40 years despite extensive amounts of literature about this procedure.

### Non-vascularized bone graft

Bone grafting is theoretically supposed to be superior to CD because it gives a structural support to the remaining subchondral bone. Several techniques such as cortical autografts, cancellous autografts and also allografts have been described.

Phemister popularized the filling of the CD tract with cortical autografts harvested from ilium bone, tibia or

fibula. In a series published by Keizer et al in 2006 concerning 80 hips comparing CD and tibia autograft and CD with fibular allograft, the authors showed that the autograft group had a significantly better survival time at six years (70% compared with 48%,  $p = 0.002$ ).<sup>48</sup> In 2010, Wang et al published the light-bulb technique described by Merle D'Aubignié and inserted cancellous autograft from the iliac crest through a cortical window at the femoral head-neck junction. This retrospective series of 110 hips concerns Ficat stages I and II. Their follow-up is about three to four years and the results showed a survival rate of 100% if the head involvement was < 15%, a survival rate of 93% if the head involvement was 15% to 30%, and a survival rate of 54% if the head involvement was > 30%.<sup>49</sup>

As there are no published prospective comparisons, the recommendations about this technique are limited. Moreover, there is no general consensus concerning the use of non-vascularized bone grafting. Still, some authors advocate its use when there is < 2 mm of head depression and < 30% of head involvement.<sup>50</sup>

### Vascularized fibular graft

In this technique, the central portion of the fibular bone and its nutrient artery is used. The vascular pedicle is anastomosed to branches of the lateral circumflex femoral artery. The graft is inserted into the core decompression canal and held in place with a K-Wire. The commonly cited indications are: no evidence of osseous collapse; articular depression of < 3 mm; and < 50% of the head involvement as described by Aldridge et al in 2007.<sup>51</sup> According to Korompilias et al, the success of this technique is related to a good decompression of the femoral head, the excision of the necrotic bone, the buttressing of the overlying articular surface and the protection of the construct through limited weight-bearing during the first weeks. The authors also point out the need for microsurgery skills.<sup>52</sup>

In 2008, Yoo et al published a series of 135 patients (151 hips) with a mean follow-up of 13.9 years (124 hips). The mean Harris Hip Score (HHS) rose from 72 to 88 and 13 hips (10.5%) needed conversion to THA. The authors concluded that this technique is effective for improving hip function and delaying disease progression.<sup>53</sup> This long-term preservation of the hip joint is also stated in other studies and has a better outcome when compared with non-vascularized grafts. The authors also described limitations or risks of the technique and concluded that the location, size and age of the patient have an influence on survival autograft. Also, this technique requires microvascular surgery expertise. The main complication described is the clawing of the big toe (17 in the latter study), followed by peroneal nerve palsy and the subtrochanteric fracture.

This procedure might therefore be a supplemental technique following CD failure and may be used to treat ACRO stages I and II or ACRO III with minimal collapse and small size lesions. The articular collapse shall be  $< 3$  mm and the involvement of the femoral head shall not be  $> 50\%$ .

### Proximal femoral osteotomies

Proximal femoral osteotomies are techniques that have been used in adults in the early part of the 20th century for the treatment of hip dysplasia and osteoarthritis. Varus- and valgus-producing osteotomies were aimed to improve joint congruity and to redistribute the weight-bearing load across the femoral head to a less affected area. Historically, the best results were obtained in patients with long-standing deformities, including Perthes disease, coxa vara or developmental dysplasia.<sup>54</sup> The implant used is typically a fixed-angle device ( $95^\circ$  or  $130^\circ$  blade plate to allow angular stability) and the procedure is performed through an open surgical approach. Once the plate is in place, no post-operative adjustments are possible. The approach is lateral, centred over the proximal femur and greater trochanter, and the osteotomy line runs through the metaphyseal region to allow better healing conditions.

For the treatment of ONFH, the aim is to offload the osteonecrotic segment in order to decrease the intramedullary pressure and to preserve the blood flow in the femoral head to preserve the hip joint mechanism. The choice of osteotomy depends on the location and size of the necrotic segment. Mont et al published the different osteotomies that may be used around the proximal femur.<sup>55</sup> They mainly consist of the intertrochanteric osteotomies (valgus-flexion and varus) as well as transtrochanteric (rotation) osteotomies.

The anterolateral lesions of the femoral head need a valgus-flexion osteotomy in order to transfer the weight medially and posteriorly.<sup>55</sup> The medial lesions will be treated with a varus osteotomy but there is then a need to preserve the lateral column of the femoral head and the patient shall keep  $> 30^\circ$  of adduction.<sup>32</sup> In a series published by Scher, 48 patients with a small anterolateral lesion underwent a valgus-flexion osteotomy procedure. This was associated with improvement of HHS and 87% of patients avoided a THA at five years of follow-up.<sup>56</sup> These positive results are confirmed in a study by Mont et al, where 37 hips of ARCO stages II and III were studied at a follow-up of 11 years. Of those patients, 76% had a good to excellent result after a varus osteotomy of the proximal femur.<sup>55</sup>

Transtrochanteric osteotomies are used to treat antero-superior lesions and positive results have been described essentially in Japan where the survival rate of the femoral heads at 3 to 18 years reaches 70% to 80% in the study by Sugioka et al.<sup>57</sup> The results outside Asia were not so

positive, with Market et al publishing a survival rate at five years  $< 40\%$ .<sup>50</sup> Morphometric differences between Asians and Caucasians and a more lax capsule in the Asians may be an explanation for better outcomes after rotational OT differences in Asians. However, these authors have also postulated that the results have more to do with indications and surgical technique than with these morphometric differences.

Recommendations for proximal femoral osteotomy concern patients that are aged  $< 40$  years, ACRO stage II and III, that have a combined Kerboul angle of  $< 200^\circ$ , no acetabular pathology and a normal hip range of motion. The results after such surgeries in well-selected patients are similar to those treated with a total hip joint in terms of quality of life.<sup>58</sup> It is also to be mentioned that if a THA follows an osteotomy, the outcome is less favourable and will increase the operating time, blood loss and also increase the risk of femoral shaft fracture.

### Anecdotal surgical options

With the aim of improving the overall survival rate of the femoral head and delaying an arthroplasty procedure, some surgeons over the years have described different surgical alternatives which did not find any favourable clinical or functional issue. Among those, osteochondral grafting of the necrotic segment has been proposed (Fig. 8).

Another technique consisted of filling the necrotic area with polymethyl-methacrylate cement and has been described by Hernigou et al. The authors reported ten patients with sickle cell anaemia who all had a positive crescent sign. At a mean follow-up of five years, two hips had been converted to THA (Fig. 9).<sup>59</sup>

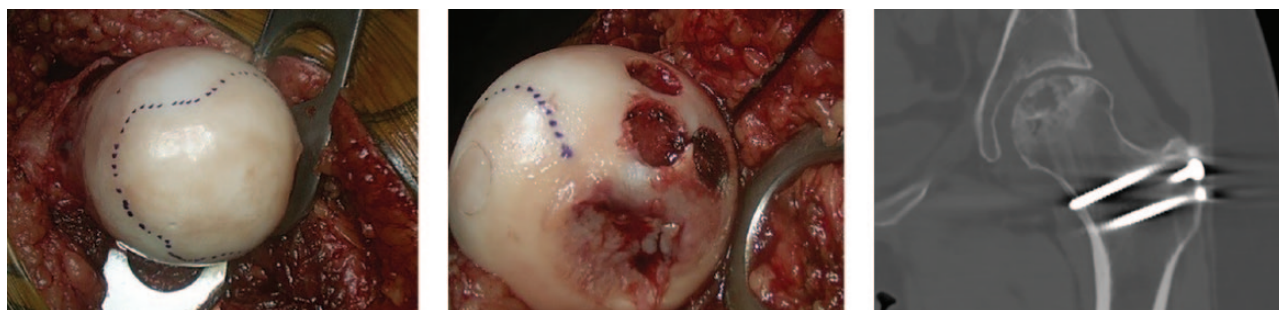Both these techniques neither stopped progression towards hip arthritis nor improved the quality of life of the patients and have therefore been abandoned.

### Novel strategies

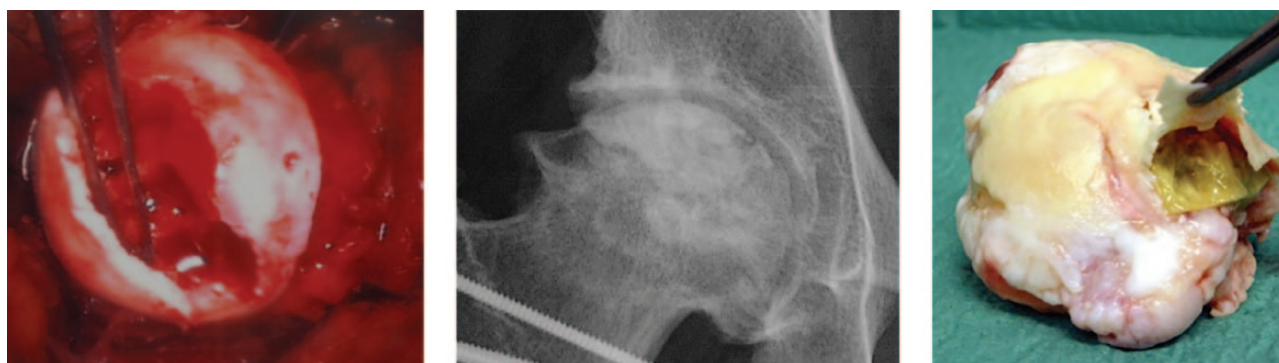Novel strategies concern essentially modifications of CD techniques that include the use of osteo-inductive and osteogenic factors. In that sense, adjunction of mesenchymal stem cells (MSCs) or the use of BMP has been studied. In addition, new implants such as porous titanium rods, believed to stimulate bone ingrowth, have been developed and implanted.

#### *Cell therapy*

Cell therapy has been promoted among the therapeutic arsenal that could aid bone formation and remodelling in the early, pre-collapse stages of ONFH. Therefore, the addition of multipotential MSCs to the above-mentioned surgical techniques has been investigated because of their ability to maintain mitotic multiplication while being



**Fig. 8** a) Necrotic head portion, b) osteochondral transfer, c) CT scanner at one-year follow-up.



**Fig. 9** a) Debridement of the femoral head and PMMA filling of the defect, b) radiograph at five-year follow-up, c) aspect of the femoral head at time of arthroplasty, at 12 years of follow-up.

capable of differentiating into various cellular types, such as osteoblasts, osteocytes, chondrocytes and adipocytes. The hypothesis is that MSCs would repopulate the bony trabeculae of the necrotic segment and from that point enhance remodelling and regeneration of the necrotic area. CD was the first surgical technique associated with MSCs that was studied with the bone marrow aspirate being injected into the necrotic area through the canal of the previous decompression.<sup>60</sup> In a RCT, Sen et al described 51 osteonecrotic hips divided into two treatment groups. The first group (25 hips) was treated with CD alone whereas the second group (26 hips) received an autologous bone marrow cell instillation into the core tract after CD. Clinical scores, MRI and survival analysis were performed at 12 and 24 months. The authors concluded that instillation of MSCs can result in better clinical outcome and hip survival. This improvement would be more marked in patients with poor prognostic factors (low HHS, radiographic changes, oedema/effusion on MRI).<sup>61</sup> Gangji et al published a double blind study of 19 patients over 60 months divided into CD alone and CD associated with bone marrow concentrate. The authors reported that the use of bone marrow cells associated with CD for the early stages of ONFH could be an efficacious agent to delay disease progression and relieve symptoms even in long-term follow-up. However, the authors also pointed

out that further studies are necessary to document the volume and concentration of mesenchymal cells that are used.<sup>62</sup> In a systematic review of seven studies, the authors concluded that implantation of MSCs into the core decompression track, particularly when employed at pre-collapse stages of ONFH, would improve the survivorship of femoral heads and reduce the need for THA.<sup>63</sup> In another systematic review of 11 articles out of 1483 published by Piuizzi et al, the authors aimed to assess clinical efficiency, structural modifying effect (radiological study), revision rate and safety of the procedure using cell therapy. The authors noticed that there was heterogeneity of the studies and the cell-based therapy use. However, the authors also concluded that the results are promising, showing an improvement of clinical outcome, a decrease of radiological progression and a decrease in revision rates. Their recommendations are to invest further in blinded, RCTs and clinical effectiveness trials that embrace rigorous standards.<sup>64</sup> In another study published by Villa et al, the authors reviewed 12 RCTs of CD or CD with bone marrow stem cells or with bisphosphonate treatment. There was a decreased risk of femoral head collapse in CD associated to bone marrow stem cells compared with CD alone. There was no evidence to determine the effect on functional outcome. The authors also concluded that there was a decreased risk of femoral head collapse in a

**Table 3.** Treatment options according to ARCO classification

Radiographic stage	Symptoms	Treatment options	Further approaches
I and II	Asymptomatic	Conservative, possible CD ± non- / vascularized bone grafting	Pharmacological
I(A-B-C), II(A-B-C)	Symptomatic	CD ± non- / vascularized bone grafting	Pharmacological Biologic adjuvant
IC, IIC, III(A-B-C), IVA	Symptomatic	CD ± non- / vascularized bone grafting Osteotomy, THA	Pharmacological Biologic adjuvant
IV(B-C), V, VI	Symptomatic	THA	Resurfacing arthroplasty

group of CD and BMSC compared with CD alone in terms of risk ratio for femoral head collapse.<sup>34</sup>

*Bone morphogenetic protein*

The use of BMP is associated with CD. It consists of creating a trap door on the femoral neck at the head and neck junction which allows trimming of the femoral head in order to remove all the necrotic bone and ensures the bleeding of the bony surface before proceeding. This debridement and autogenous bone grafting is associated with osteoprogesterone I. It was analysed in a retrospective study of 39 hips by Seyler et al. At a follow-up of 24 months, no further surgery for 25/30 hips was noted and 2/9 hips (larger lesions) were converted to THA. The authors concluded that these results are quite similar to standard procedure but need an extensive approach in surgical dissection.<sup>65</sup>

Lieberman et al studied the use of an alloy implant with purified human BMP in 15 patients (17 hips) at a mean follow-up of 43 months. There was no radiologic progression in 14/17 hips with a HSS of > 80. Out of the three hips that showed progression of the disease, all had a head collapse before the procedure. The implant used was an alloimplant with purified human BMP.<sup>66</sup> The results of these two last studies suggest that core decompression may be more effective when combined with an osteo-inductive agent.

*Porous tantalum rods*

Technically, a tantalum rod is inserted into the femoral neck after a CD instead of a vascularized fibular bone graft and has the role of support of the femoral head. It might be done in combination with bone grafting or the use of bone marrow mesenchymal cells. In a study by Pakos et al, the rods were impregnated with bone marrow cells and the authors followed 48 patients, 58 hips, for five years of follow-up. They noted seven progressions of the disease and four needed a conversion to THA. However, there was a shorter operation time with less blood loss.<sup>67</sup> In a meta-analysis by Zhang et al, the authors made a

pooling of six studies and could conclude that was a significantly improved HHS compared with non-vascularized bone grafts. There also appears to be an improvement in the survival rates. However, the authors concluded that there was no standard protocol described and the conversion for further surgery might be difficult.<sup>68</sup> Tanzer et al published a study of 17 failed porous rods out of 113 implanted (15%). The patients all had a pre-collapse lesion and a retrieval analysis of the material showed little bone ingrowth. At an average of 13 months, all failed cases have occurred.<sup>69</sup> Finally, Ma et al published a study of 104 consecutive hips treated with a porous tantalum rod plus bone grafting between 2008 and 2013 with a mean follow-up of 42 months. The survival rate was 52.9 months at follow-up. The problem reported by the author is that ARCO stage III was also included.<sup>70</sup>

As described above, there are many different treatment options that are possible to treat ONFH, depending on the time of diagnosis and progression of the disease. They may be related to the ACRO classification (Table 3). However, because of all these different results obtained in literature with different surgical or non-surgical procedures, long-term studies remain necessary.

**Conclusion**

Femoral head necrosis has no particular clinical features and radiographic findings may only appear after a delay of several months to years following the onset of symptoms. Groin pain is usually the initial presentation and may be either sharp or intermittent. The possible causes frequently cited for ONFH include the idiopathic form, alcoholism, thromboembolism in a blood vessel feeding the femoral head or fat embolism. Additional causes include decompression illness due to the appearance of gas bubbles that occlude the femoral vessels, Gaucher disease, traumatic impairment of arterial supply to the femoral head, obstruction of venous drainage, vasculitis or intramedullary haemorrhage. The pathogenesis of ONFH remains unclear, but an imbalance of bone metabolism is considered one of the most important causes. Interruption of the blood supply to the affected bone causes osteocytes to begin losing their viability within 12 hours and only later in the course of the disease is bone marrow oedema recognized on MRI. Because remodelling is a slower process, radiographic changes are not evident until two months after injury. In the adult, the involved segment usually never fully revascularizes and the earliest radiographic sign on plain radiographs (crescent sign) corresponds to a separation between the bony subchondral layer and the underlying necrotic bone. This represents the initial collapse of the femoral head which invariably evolves towards hip joint destruction because of the loss of congruency. Most of these patients with a

collapse of the femoral head will not do well with the head saving procedure and need a THA. In those cases, the use of non-cemented implants is favoured as well as short stems.

If a joint-preserving procedure is indicated, early diagnosis is essential and preventing femoral head collapse is the most important treatment goal. CD combined with a vascularized bone graft is a secure and well-established option. The results published until now show the influence of the size of the lesion, its location and the presence of risk factors. Even if there are a high number of publications about this pathology, there is a need for more standardized protocols to allow a reproducibility of the techniques. Cell therapy offers a promising future as well as the use of osteogenic and osteo-inductive agents, both of which also need more RCTs.

#### AUTHOR INFORMATION

<sup>1</sup>Clinic of Orthopaedics and Trauma Surgery, HFR-Fribourg District Hospitals, Fribourg, Switzerland.

<sup>2</sup>Clinic of Orthopaedics and Trauma Surgery, Geneva University Hospitals, Geneva, Switzerland.

Correspondence should be sent to: D. Petek, Clinic of Orthopaedics and Trauma Surgery, HFR-Fribourg District Hospitals, Pensionnats 4, Fribourg 1700, Switzerland.

Email: daniel.petek@h-fr.ch

#### FUNDING STATEMENT

No benefits in any form have been received or will be received from a commercial party related directly or indirectly to the subject of this article.

#### ICMJE CONFLICT OF INTEREST STATEMENT

None declared.

#### LICENCE

© 2019 The author(s)

This article is distributed under the terms of the Creative Commons Attribution-Non Commercial 4.0 International (CC BY-NC 4.0) licence (<https://creativecommons.org/licenses/by-nc/4.0/>) which permits non-commercial use, reproduction and distribution of the work without further permission provided the original work is attributed.

#### REFERENCES

- Mankin HJ. Nontraumatic necrosis of bone (osteonecrosis). *N Engl J Med* 1992;326:1473-1479.
- Cooper C, Steinbuch M, Stevenson R, Miday R, Watts NB. The epidemiology of osteonecrosis: findings from the GPRD and THIN databases in the UK. *Osteoporos Int* 2010;21:569-577.
- Lieberman JR, Berry DJ, Mont MA, et al. Osteonecrosis of the hip: management in the 21st century. *Instr Course Lect* 2003;52:337-355.
- Aldridge JM III, Urbaniak JR. Avascular necrosis of the femoral head: etiology, pathophysiology, classification, and current treatment guidelines. *Am J Orthop* 2004;33:327-332.
- Ikeuchi K, Hasegawa Y, Seki T, et al. Epidemiology of nontraumatic osteonecrosis of the femoral head in Japan. *Mod Rheumatol* 2015;25:278-281.
- Min BW, Song KS, Cho CH, Lee SM, Lee KJ. Untreated asymptomatic hips in patients with osteonecrosis of the femoral head. *Clin Orthop Relat Res* 2008;466:1087-1092.
- Carli A, Albers A, Seguin C, Harvey EJ. The medical and surgical treatment of ARCO Stage-I and II osteonecrosis of the femoral head: a critical analysis review. *JBJS Rev* 2014;2:1-10.
- Gautier E, Ganz K, Krugel N, Gill T, Ganz R. Anatomy of the medial femoral circumflex artery and its surgical implications. *J Bone Joint Surg [Br]* 2000;82-B:679-683.
- de Seze S. [Aseptic, primary osteonecrosis of the femur head]. *Acta Orthop Belg* 1972;38:507-515.
- Moya-Angeler J, Gianakos AL, Villa JC, Ni A, Lane JM. Current concepts on osteonecrosis of the femoral head. *World J Orthop* 2015;6:590-601.
- Rego P, Mascarenhas V, Collado D, et al. Arterial topographic anatomy near the femoral head-neck perforation with surgical relevance. *J Bone Joint Surg [Am]* 2017;99-A:1213-1221.
- Shah KN, Racine J, Jones LC, Aaron RK. Pathophysiology and risk factors for osteonecrosis. *Curr Rev Musculoskelet Med* 2015;8:201-209.
- Atsumi T, Kuroki Y. Role of impairment of blood supply of the femoral head in the pathogenesis of idiopathic osteonecrosis. *Clin Orthop Relat Res* 1992;277:22-30.
- Liu YF, Chen WM, Lin YF, et al. Type II collagen gene variants and inherited osteonecrosis of the femoral head. *N Engl J Med* 2005;352:2294-2301.
- Mont MA, Pivec R, Banerjee S, et al. High-dose corticosteroid use and risk of hip osteonecrosis: meta-analysis and systematic literature review. *J Arthroplasty* 2015;30:1506-12 e5.
- Fukushima W, Fujioka M, Kubo T, et al. Nationwide epidemiologic survey of idiopathic osteonecrosis of the femoral head. *Clin Orthop Relat Res* 2010;468:2715-2724.
- Zhang NF, Li ZR, Wei HY, Liu ZH, Hernigou P. Steroid-induced osteonecrosis: the number of lesions is related to the dosage. *J Bone Joint Surg [Br]* 2008;90-B:1239-1243.
- Kubo T, Ueshima K, Saito M, et al. Clinical and basic research on steroid-induced osteonecrosis of the femoral head in Japan. *J Orthop Sci* 2016;21:407-413.
- Yoon BH, Kim TY, Shin IS, et al. Alcohol intake and the risk of osteonecrosis of the femoral head in Japanese populations: a dose-response meta-analysis of case-control studies. *Clin Rheumatol* 2017;36:2517-2524.
- Simon L, Bertrand L, Michel H, Blotman F., Claustre . [Osteonecrosis, alcoholism and liver steatosis]. *Rev Rhum Mal Osteoartic* 1975;42:103-108.
- Gold EW, Cangemi PJ. Incidence and pathogenesis of alcohol-induced osteonecrosis of the femoral head. *Clin Orthop Relat Res* 1979;143:222-226.
- Wang A, Ren M, Wang J. The pathogenesis of steroid-induced osteonecrosis of the femoral head: A systematic review of the literature. *Gene*. 2018;671:103-109.
- Sakaguchi M, Tanaka T, Fukushima W, et al. Impact of oral corticosteroid use for idiopathic osteonecrosis of the femoral head: a nationwide multicenter case-control study in Japan. *J Orthop Sci* 2010;15:185-191.
- Hirota Y, Hirohata T, Fukuda K, et al. Association of alcohol intake, cigarette smoking, and occupational status with the risk of idiopathic osteonecrosis of the femoral head. *Am J Epidemiol* 1993;137:530-538.

- 25. Conway WF, Totty WG, McEnery KW.** CT and MR imaging of the hip. *Radiology* 1996;198:297-307.
- 26. Dasa V, Abdel-Nabi H, Anders MJ, Mihalko WM.** F-18 fluoride positron emission tomography of the hip for osteonecrosis. *Clin Orthop Relat Res* 2008;466:1081-1086.
- 27. Kerboul M, Thomine J, Postel M, Merle d'Aubigne R.** The conservative surgical treatment of idiopathic aseptic necrosis of the femoral head. *J Bone Joint Surg [Br]* 1974;56-B:291-296.
- 28. Ha YC, Jung WH, Kim JR, et al.** Prediction of collapse in femoral head osteonecrosis: a modified Kerboul method with use of magnetic resonance images. *J Bone Joint Surg [Am]* 2006;88-A(suppl 3):35-40.
- 29. Ficat RP, Arlet J.** *Functional investigation of bone under normal conditions.* Baltimore: Williams and Wilkins; 1980.
- 30. Ito H, Matsuno T, Minami A.** Relationship between bone marrow edema and development of symptoms in patients with osteonecrosis of the femoral head. *AJR Am J Roentgenol* 2006;186:1761-1770.
- 31. Steinberg ME, Brighton CT, Bands RE, Hartman KM.** Capacitive coupling as an adjunctive treatment for avascular necrosis. *Clin Orthop Relat Res* 1990;261:11-18.
- 32. Mont MA, Carbone JJ, Fairbank AC.** Core decompression versus nonoperative management for osteonecrosis of the hip. *Clin Orthop Relat Res* 1996;324:169-178.
- 33. Neumayr LD, Aguilar C, Earles AN, et al.** Physical therapy alone compared with core decompression and physical therapy for femoral head osteonecrosis in sickle cell disease. Results of a multicenter study at a mean of three years after treatment. *J Bone Joint Surg [Am]* 2006;88-A:2573-2582.
- 34. Villa JC, Husain S, van der List JP, Gianakos A, Lane JM.** Treatment of pre-collapse stages of osteonecrosis of the femoral head: a systematic review of randomized control trials. *HSS J* 2016;12:261-271.
- 35. Ajmal M, Matas AJ, Kuskowski M, Cheng EY.** Does statin usage reduce the risk of corticosteroid-related osteonecrosis in renal transplant population? *Orthop Clin North Am* 2009;40:235-239.
- 36. Glueck CJ, Freiberg RA, Sieve L, Wang P.** Enoxaparin prevents progression of stages I and II osteonecrosis of the hip. *Clin Orthop Relat Res* 2005;(435):164-170.
- 37. Disch AC, Matziolis G, Perka C.** The management of necrosis-associated and idiopathic bone-marrow oedema of the proximal femur by intravenous iloprost. *J Bone Joint Surg [Br]* 2005;87-B:560-564.
- 38. Camporesi EM, Vezzani G, Bosco G, Mangar D, Bernasek TL.** Hyperbaric oxygen therapy in femoral head necrosis. *J Arthroplasty* 2010;25:118-123.
- 39. Uzun G, Mutluoglu M, Ersen O, Yildiz S.** Hyperbaric oxygen therapy in the treatment of osteonecrosis of the femoral head: a review of the current literature. *Undersea Hyperb Med* 2016;43:189-199.
- 40. Lai KA, Shen WJ, Yang CY, et al.** The use of alendronate to prevent early collapse of the femoral head in patients with nontraumatic osteonecrosis. A randomized clinical study. *J Bone Joint Surg [Am]* 2005;87-A:2155-2159.
- 41. Chen CH, Chang JK, Lai KA, et al.** Alendronate in the prevention of collapse of the femoral head in nontraumatic osteonecrosis: a two-year multicenter, prospective, randomized, double-blind, placebo-controlled study. *Arthritis Rheum* 2012;64:1572-1578.
- 42. Li D, Yang Z, Wei Z, Kang P.** Efficacy of bisphosphonates in the treatment of femoral head osteonecrosis: A PRISMA-compliant meta-analysis of animal studies and clinical trials. *Sci Rep* 2018;8:1450.
- 43. Alves EM, Angrisani AT, Santiago MB.** The use of extracorporeal shock waves in the treatment of osteonecrosis of the femoral head: a systematic review. *Clin Rheumatol* 2009;28:1247-1251.
- 44. Russo S, Sadile F, Esposito R, et al.** Italian experience on use of E.S.W. therapy for avascular necrosis of femoral head. *Int J Surg* 2015;24:188-190.
- 45. Ficat RP.** Idiopathic bone necrosis of the femoral head. Early diagnosis and treatment. *J Bone Joint Surg [Br]* 1985;67-B:3-9.
- 46. Gangji V, Hauzeur JP, Matos C, et al.** Treatment of osteonecrosis of the femoral head with implantation of autologous bone-marrow cells. A pilot study. *J Bone Joint Surg [Am]* 2004;86-A:1153-1160.
- 47. Zhao D, Cui D, Wang B, et al.** Treatment of early stage osteonecrosis of the femoral head with autologous implantation of bone marrow-derived and cultured mesenchymal stem cells. *Bone* 2012;50:325-330.
- 48. Keizer SB, Kock NB, Dijkstra PD, Taminiau AH, Nelissen RG.** Treatment of avascular necrosis of the hip by a non-vascularised cortical graft. *J Bone Joint Surg [Br]* 2006;88-B:460-466.
- 49. Wang BL, Sun W, Shi ZC, et al.** Treatment of nontraumatic osteonecrosis of the femoral head using bone impaction grafting through a femoral neck window. *Int Orthop* 2010;34:635-639.
- 50. Marker DR, Seyler TM, McGrath MS, et al.** Treatment of early stage osteonecrosis of the femoral head. *J Bone Joint Surg [Am]* 2008;90-A:175-187.
- 51. Aldridge JM III, Urbaniak JR.** Avascular necrosis of the femoral head: role of vascularized bone grafts. *Orthop Clin North Am* 2007;38:13-22. v.
- 52. Korompilias AV, Beris AE, Lykissas MG, Kostas-Agnantis IP, Soucacos PN.** Femoral head osteonecrosis: why choose free vascularized fibula grafting. *Microsurgery* 2011;31:223-228.
- 53. Yoo MC, Kim KI, Hahn CS, Parvizi J.** Long-term followup of vascularized fibular grafting for femoral head necrosis. *Clin Orthop Relat Res* 2008;466:1133-1140.
- 54. Roberts DW, Saglam Y, De La, Rocha A, et al.** Long-term outcomes of operative and nonoperative treatment of congenital coxa vara. *J Pediatr Orthop* 2018;38:193-201.
- 55. Mont MA, Fairbank AC, Krackow KA, Hungerford DS.** Corrective osteotomy for osteonecrosis of the femoral head. *J Bone Joint Surg [Am]* 1996;78-A:1032-1038.
- 56. Scher MA, Jakim I.** Late follow-up of femoral head avascular necrosis managed by intertrochanteric osteotomy & bone grafting. *Acta Orthop Belg* 1999;65:73-77.
- 57. Sugioka Y, Hotokebuchi T, Tsutsui H.** Transtrochanteric anterior rotational osteotomy for idiopathic and steroid-induced necrosis of the femoral head. Indications and long-term results. *Clin Orthop Relat Res* 1992;277:111-120.
- 58. Seki T, Hasegawa Y, Masui T, et al.** Quality of life following femoral osteotomy and total hip arthroplasty for nontraumatic osteonecrosis of the femoral head. *J Orthop Sci* 2008;13:116-121.
- 59. Hernigou P, Bachir D, Galacteros F.** Avascular necrosis of the femoral head in sickle-cell disease. Treatment of collapse by the injection of acrylic cement. *J Bone Joint Surg [Br]* 1993;75-B:875-880.
- 60. Hernigou P, Beaujean F.** Treatment of osteonecrosis with autologous bone marrow grafting. *Clin Orthop Relat Res* 2002;405:14-23.
- 61. Sen RK, Tripathy SK, Aggarwal S, et al.** Early results of core decompression and autologous bone marrow mononuclear cells instillation in femoral head osteonecrosis: a randomized control study. *J Arthroplasty* 2012;27:679-686.

- 62. Gangji V, De Maertelaer V, Hauzeur JP.** Autologous bone marrow cell implantation in the treatment of non-traumatic osteonecrosis of the femoral head: five year follow-up of a prospective controlled study. *Bone* 2011;49:1005-1009.
- 63. Papakostidis C, Tosounidis TH, Jones E, Giannoudis PV.** The role of “cell therapy” in osteonecrosis of the femoral head. A systematic review of the literature and meta-analysis of 7 studies. *Acta Orthop* 2016;87:72-78.
- 64. Piuze NS, Cahla J, Jiandong H, et al.** Analysis of cell therapies used in clinical trials for the treatment of osteonecrosis of the femoral head: a systematic review of the literature. *J Arthroplasty* 2017;32:2612-2618.
- 65. Seyler TM, Marker DR, Ulrich SD, Fatscher T, Mont MA.** Nonvascularized bone grafting defers joint arthroplasty in hip osteonecrosis. *Clin Orthop Relat Res* 2008;466:1125-1132.
- 66. Lieberman JR, Conduah A, Urist MR.** Treatment of osteonecrosis of the femoral head with core decompression and human bone morphogenetic protein. *Clin Orthop Relat Res* 2004;429:139-145.
- 67. Pakos EE, Megas P, Paschos NK, et al.** Modified porous tantalum rod technique for the treatment of femoral head osteonecrosis. *World J Orthop* 2015;6:829-837.
- 68. Zhang Y, Li L, Shi ZJ, Wang J, Li ZH.** Porous tantalum rod implant is an effective and safe choice for early-stage femoral head necrosis: a meta-analysis of clinical trials. *Eur J Orthop Surg Traumatol* 2013;23:211-217.
- 69. Tanzer M, Bobyn JD, Krygier JJ, Karabasz D.** Histopathologic retrieval analysis of clinically failed porous tantalum osteonecrosis implants. *J Bone Joint Surg [Am]* 2008;90:1282-1289.
- 70. Ma J, Sun W, Gao F, et al.** Porous tantalum implant in treating osteonecrosis of the femoral head: still a viable option? *Sci Rep* 2016;6:28227.