



Article scientifique

Article

2014

Accepted version

Open Access

This is an author manuscript post-peer-reviewing (accepted version) of the original publication. The layout of the published version may differ .

---

## The use of self-expandable metallic stents in the airways in the adult population

---

Dutau, Herve; Musani, Ali I; Plojoux, Jérôme Pierre Olivier; Laroumagne, Sophie; Astoul, Philippe

### How to cite

DUTAU, Herve et al. The use of self-expandable metallic stents in the airways in the adult population. In: Expert review of respiratory medicine, 2014, vol. 8, n° 2, p. 179–190. doi: 10.1586/17476348.2014.880055

This publication URL: <https://archive-ouverte.unige.ch/unige:79229>

Publication DOI: [10.1586/17476348.2014.880055](https://doi.org/10.1586/17476348.2014.880055)



## The use of self-expandable metallic stents in the airways in the adult population

Herve Dutau, Ali I Musani, Jerome Plojoux, Sophie Laroumagne & Philippe Astoul

**To cite this article:** Herve Dutau, Ali I Musani, Jerome Plojoux, Sophie Laroumagne & Philippe Astoul (2014) The use of self-expandable metallic stents in the airways in the adult population, Expert Review of Respiratory Medicine, 8:2, 179-190

**To link to this article:** <http://dx.doi.org/10.1586/17476348.2014.880055>



Published online: 22 Jan 2014.



Submit your article to this journal [↗](#)



Article views: 48



View related articles [↗](#)



View Crossmark data [↗](#)

EXPERT  
REVIEWS

## The use of self-expandable metallic stents in the airways in the adult population

*Expert Rev. Respir. Med.* 8(2), 179–190 (2014)

Herve Dutau<sup>\*1</sup>,  
Ali I Musani<sup>2</sup>,  
Jerome Plojoux<sup>1</sup>,  
Sophie Laroumagne<sup>1</sup>  
and Philippe Astoul<sup>1</sup>

<sup>1</sup>North University Hospital, Thoracic Oncology, Pleural Diseases and Interventional Pulmonology, Marseille, 13015 France

<sup>2</sup>Department of Medicine, Division of Pulmonary, Sleep, Allergy and Immunology, National Jewish Health, Interventional Pulmonology, Denver, CO, USA

\*Author for correspondence:  
hdutau@ap-hm.fr

The airway stents restore patency in the face of luminal compromise from intrinsic and/or extrinsic pathologies. Luminal compromise beyond 50% often leads to debilitating symptoms such as dyspnea. Silicone stents remain the most commonly placed stents worldwide and have been the “gold standard” for the treatment of benign and malignant airway stenoses over the past 20 years. Nevertheless, silicone stents are not the ideal stents in all situations. Metallic stents can serve better in some selected conditions. Unlike silicone stents, there are large and increasing varieties of metallic stents available on the market. The lack of prospective or comparative studies between various types of metallic stents makes the choice difficult and expert-opinion based. International guidelines are sorely lacking in this area.

**KEYWORDS:** airway stenting • benign airway stenosis • bronchoscopy • central airway obstruction • self-expandable metallic stent

Dumon was the first physician to place a dedicated and specially designed airway stent in 1987 in Marseille. This dedicated stent consisted of a silicone tube with small studs on the external surface to reduce migration [1]. Consequently, several companies started to develop other airway stents with silicone and metal. In the last 20 years, numerous reports have been published about the use of self-expanding and balloon expandable metal stents for the treatment of tracheobronchial malignant and benign stenoses, tracheobronchomalacia (TBM), fistulas and dehiscences [2–16].

Self-expandable stents are made of a shape-memory alloy, generally nitinol (nickel-titanium). When the stent is released, it expands spontaneously to reach its original shape and diameter. On the other hand, balloon expandable metallic stents (the first generation of airway metallic stents) were made of metal (steel) meshes that did not possess a memory shape. A balloon was then necessary to deploy them. Most of these stents had originally been developed for use in the vascular system but were found to be adequate for placement in the central airways after only minor modifications, if any at all. The latest developments include stents made of shape memory alloys and composite stents made from metals and

polymers [17–19]. But, so far, the Dumon stent (Tracheobronxane®, Novatech, La Ciotat, France) remains the most commonly placed stent worldwide. Dumon stents have been the ‘gold standard’ for the treatment of benign and malignant airway stenoses over the past 20 years [20,21], with two specific designs: straight and Y-shaped (for disease involving the carina) [22]. By the way, it is interesting to notice that, in the Thoracic Endoscopy Unit of Marseille, where the Dumon stent was conceptualized and used, the percentage of silicone stent placement has dropped from 100% in 2000 to 65% in 2013. The remaining 35% of the stents used are now fully covered, self-expandable, metallic stents (SEMS). This goes to prove that the Dumon stents are not the ideal stents in all situations and that metallic stents can serve better in some selected conditions.

### Usual indications for airway stents

The main purpose of stents designed for use in the central airways (trachea, mainstem bronchi and, in select cases, lobar bronchi) is to restore patency of the airway to as close to a normal caliber as possible. Any endoluminal pathology responsible for debilitating symptoms such as dyspnea and associated with a



**Figure 1.** The Ultraflex stent (Boston Scientific, Natick, MA, USA).

significant reduction in airway luminal diameter (>50%) may be an indication for airway stents [20,21]. Three major indications have been established:

- Palliation of malignant extrinsic compression and endoluminal intrinsic lesions
- Treatment of benign airway stenosis and TBM
- Treatment of airway fistulas and dehiscences

In life-threatening situations, there are no absolute contraindications for stent placement. However, other techniques should be considered before a stent is placed. For instance, endoluminally growing tumors should be first treated with laser resection (or some other form of ablative therapy) and then a stent should be placed if it is still necessary. Treating benign lesions requires particular caution as stents may be harmful in the long run even if early benefit is often noted [21]. In general, only removable stents should be used for these indications until a multidisciplinary team has determined inoperability [21] and all other options are exhausted.

Airway stents are generally divided into two types: the silicone stents and the metallic stents [17]. Only metallic stents will be addressed in this review.

#### **Metallic stents: overview**

##### **The Ultraflex stent (Boston Scientific, Natick, MA, USA)**

Made from nitinol, this stent has replaced the former Strecker stent, which was made from tantalum [23]. The knitted design permits axial and radial movements of the wire filaments. Thus, an Ultraflex stent can adapt well to the irregular contours of the airways [24]. Uncovered and partially covered

(polyurethane) versions are available. The last 5 mm on each end of the partially covered stents are uncovered and hold the stent in place; this type is the most popular (FIGURE 1). They have been used for the treatment of malignant and benign stenoses [25–29]. As the expansion force of the knitted nitinol stent is not very high [24,30], sufficient pre-dilatation is required to accomplish good airway patency. It has also been used to seal airway fistulas to the esophagus or the pleural cavity. The stent is mounted on a semi-rigid catheter with the Crochet knotting technique. Over a guidewire, it can be placed and deployed under fluoroscopic or direct vision with flexible endoscopes. Distal and proximal release stents are available. They can be pulled up with any grabbing or biopsy forceps, in case they have been released too distally. Pushing such a stent further down is more difficult.

##### **The Aero stent (Merit Medical, Maastricht, The Netherlands)**

This stent is the successor of the Alveolus stent (Alveolus, Charlotte, NC, USA), which was the first fully covered metal stent, introduced in 2007. It has been shown that this stent can be deployed easily with a flexible bronchoscope under conscious sedation like the Ultraflex stent mentioned above. Positioning of this stent under direct endoscopic vision is extremely precise. The Aero stent is dumbbell shaped so that the ends cannot pinch into the mucosa. The stent is cut from a tube of nitinol and covered with polyurethane (FIGURE 2). It does not change its length under compression. The resistance against foreshortening is accomplished by internal bridges between the filaments. It adds stability to the stent but it does impair its ability to adapt to anatomical changes in diameter (main bronchus to bronchus intermedius) or angulation. The stent cannot be bent as much as the Ultraflex stent and tends to keep a straight form. While granulation tissue formation seems to be less of an issue with this stent, migration is seen more often. However, it is the first metallic stent that can be replaced or removed with flexible instruments at any time [31].

##### **The Micro-Tech stent (Micro-Tech, Nanjing, China) & the Aerstent (Leufen, Germany) [21]**

These stents are woven from a nitinol wire. Their basic shape is similar to that of the Aero stent with a straight middle section and enlarged edges. The edges are smooth and the inner surface is hydrophobic for the Micro-Tech stent and hydrophilic for the Aerstent. It has an expansion force that is twice as high as the Ultraflex stent. The stent is completely covered with thin-walled silicone. It is released from a semi-rigid catheter under fluoroscopic or endoscopic vision but, unlike the Aero stent, it has some foreshortening, which is similar to the Ultraflex stent. Sizing and positioning is slightly more critical. While pulling up the stent is easy, bringing it further down once it has been released can hardly be accomplished with flexible instruments. The stent is suitable for slightly curved airways. In tapered airways, migration is a common problem. This stent is available as a Y shape (FIGURE 3) as well as J shape [32].

This newly developed stent is deployed out of a semi-rigid introducer requiring good skills in rigid bronchoscopy. The stent is self-expanding with relatively high expansion force. A unique feature is that it can be custom-made in various combinations of tracheal and bronchial diameters and lengths. These stents are even three-dimensionally shaped for complex problems with distorted airways. The edges and inner surface are smooth but problems with retained secretions and material failure, such as disintegration of the flexible covering, have been observed.

**The NiTi-stent (Taewoong Medical, Seoul, North Korea) & the Hanaro stent (M.I.Tech, Seoul, North Korea)** [21]

These stents are also made from nitinol wires. Placement of this catheter-preloaded stent is possible with flexible instruments. The stents are fully covered with polytetrafluoroethylene, a material known to be resistant to sticky mucus. The shape of these stents with funnel-shaped ends is similar to an esophageal stent (FIGURE 4, panels A and B). The smooth but expanding ends of the stents should prevent migration, but it remains to be seen whether granulation tissue formation will occur more often. Both stents have retrieval drawstrings like the Ultraflex stent which facilitates repositioning, if necessary.

**The Silmet stent (Novatech, La Ciotat, France)**

This stent is self-expandable; made of nitinol, with memory shape effect mesh. Depending on the design, it has straight or tapered ends. It is also available in a conical shape. The clamps connecting the meshes are made of an elgiloy (an alloy of cobalt, chrome and nickel). It is available in a covered or uncovered version (FIGURE 5). The coverage is supplied with and extra-thin polyester tissue. Custom-made stents according to physician's specifications are available. Radio-opaque gold markers are placed on the mesh. The stents are fully handcrafted.

**The Bonastent (Sewoon Medical, Cheonan, South Korea)**

It is a new SEMS made of nitinol (FIGURE 6). It presents with a hook and cross wire structure, a polygon mesh and flare ends. The cover is made of performance-formulated silicone. The manufacturer states low rate of shortening, segmental compression to reduce the risk of migration and a reduced delivery device diameter.

**Metallic airway stenting according to indications**

**Malignant extrinsic compression & endoluminal intrinsic lesions**

Bronchial obstruction is frequently encountered during the course of bronchial carcinoma. More than 30% of bronchial carcinomas present as a central airway obstruction [33]. Malignant airway obstruction is often classified based on the type of airway involvement [34]. Airway involvement can be intrinsic (limited to endoluminal involvement), extrinsic (entirely extraluminal compression) or mixed (with both intra- and extraluminal obstruction of the airways) [30]. Purely intrinsic involvement can often be managed with debulking techniques




**Figure 2. The Aero stent (Merit Medical, Maastricht, The Netherlands).**

to remove the endoluminal tumor [34]. On occasions, a stent may be placed as a bridge to chemo-radiotherapy or alternatively may be considered as a permanent palliative solution when the risk of local recurrence is high. Extrinsic compression without intraluminal disease is readily treated with dilatation followed by stenting. Mixed (intrinsic and extrinsic) obstruction



**Figure 3. The Micro-Tech Y stent (Micro-Tech, Nanjing, China).**





**Figure 4. Funnel-shaped ends self-expandable metallic stents. (A)** The NiTi-stent (Taewoong Medical, Seoul, North Korea) and **(B)** the Hanaro stents (M.I.Tech, Seoul, North Korea).



**Figure 5. The Silmet stents (Novatech, La Ciotat, France).**

treatment is usually multimodality with debulking and stent insertion (FIGURE 7).

An efficient endoscopic treatment allows for oncologic treatments to be done in better conditions with reduced complications and improve subjective respiratory symptoms, lung function [35], performance status, survival [36–39] and quality of life [40]. Life expectancy of patients presenting with symptomatic obstruction successfully treated is equal to that of asymptomatic patients for equivalent stage of the disease [41]. Usually, benefits noted after successful bronchoscopic treatment of obstruction last for 2–3 months [36]. Benefit duration after stent placement is generally reported to be around 4 months [42].

In malignant conditions, silicone stents or SEMS show an identical efficacy and safety profile [22,29,43] because of the too short life expectancy to discern any significant differences in long-term complications caused by different types of stents. In addition, removability of stents, unlike in benign indications, is not the objective in malignancy where palliation is the goal.

Other indications for endobronchial treatment include endobronchial metastases (e.g., esophageal, thyroid, renal cell carcinoma, colon and melanoma) or alternatively low-grade primary tumors (e.g., adenoid cystic carcinomas, typical or atypical carcinoids).

### **Benign airway stenosis**

Post-intubation or post-tracheostomy tracheal stenosis

Even if surgical repair (sleeve resection) is the best definitive solution, approximately 50% of patients present with acute respiratory distress prompting emergent less invasive endoscopic treatments as a bridge to surgery. A significant number of patients are deemed poor surgical candidates for a myriad of clinical and technical reasons making bronchoscopic management the only alternative [44].

One can divide post-intubation or post-tracheostomy tracheal stenosis (PITTS) into two different types: the web-like PITTS (disease of the tracheal mucosa sparing the cartilaginous rings) and the complex PITTS (involving deterioration of the cartilaginous support) [45]. The web-like PITTS is generally successfully treated by radial mucosal incisions followed by mechanical dilation [46]. The rate of success is close to 90%, in one to three sessions [47]. For the complex PITTS, mechanical dilation alone is often not sufficient [45]. In case of surgical contraindication, the next step would be the placement of a stent in order to maintain the long-term patency of the tracheal lumen and prevent recurrence [45].

The choice of the stent is important. Not fully covered SEMS have shown to make potentially operable PITTS inoperable because of the severe complications (such as expeditious fibrosis and scarring) associated with the technique [48].

In addition, they are more difficult to remove because of the re-epithelialization of their uncovered parts. These facts prompted the US FDA to issue recommendations to limit the use of SEMS in benign tracheal stenosis [49]. Metallic tracheal stents should only be considered in patients with benign airway disorders if and when all other treatment options (such as

tracheal surgical procedures or placement of silicone stents) have been considered and not deemed possible. Using metallic tracheal stents as a bridge to other therapies is not recommended, because removal of the metallic stent can result in serious complications. If a metallic tracheal stent is the only option for a patient, only an experienced physician, well versed in metallic stenting should perform the procedure. If removal is necessary, a physician trained and experienced in removing metallic tracheal stents with rigid bronchoscopy should undertake that [50,51].


Despite these recommendations, some authors continue to use SEMS in benign PTTs [52]. We think that the main reason for still using partially covered or uncovered SEMS rather than silicone or fully covered stents, in this situation, is the lack of skills and training in rigid bronchoscopy [53].

Silicone stents or fully covered SEMS are more suitable because of their easy removability and are not likely to jeopardize a future surgery. A paper investigating fully covered SEMS (FIGURE 8) in benign tracheal stenosis found a rate of complications (mainly migration) too high for the authors [19]. Another paper on the use of fully covered SEMS found that temporary placement was safe and effective with an optimal duration of stent placement within 4–8 months [54].

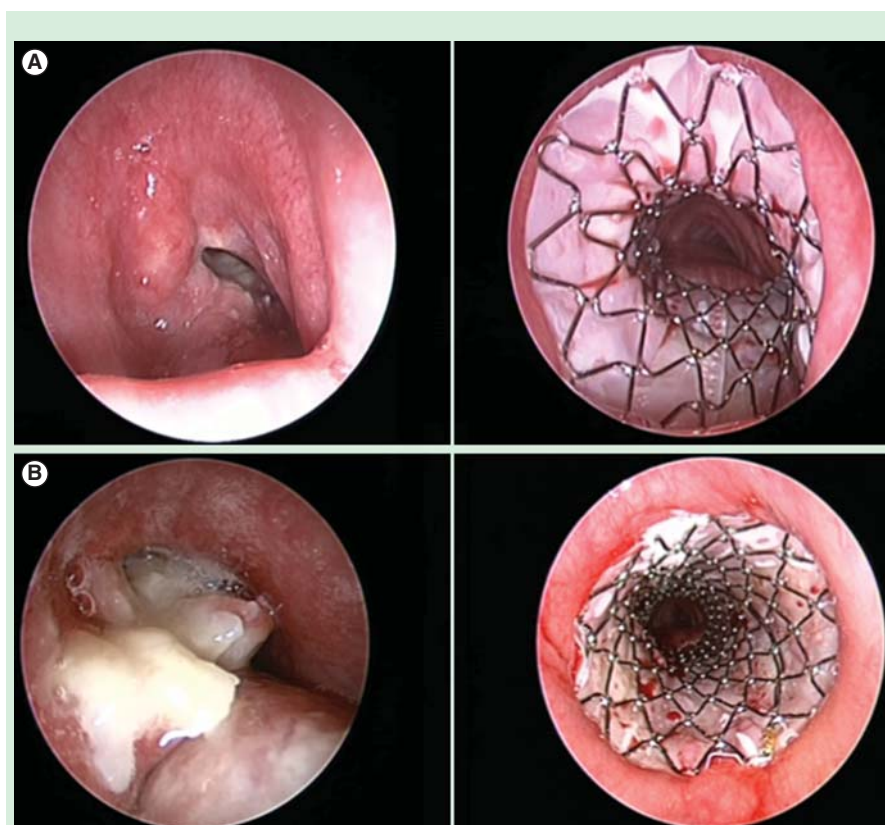
#### Bronchial stenosis following lung transplantation

After lung transplantation (LT), stent placement can be considered for bronchomalacia, bronchial stenosis, combined stenosis and malacia or bronchial dehiscence, when these conditions are responsible for respiratory symptoms, persistent decline in lung function or post-obstructive complications such as mucus retention and/or infection.

SEMS in bronchial stenosis allow immediate and long-term maintenance of airway luminal dimensions in 80 and 45% of cases, respectively in one study [55]. Immediate dyspnea relief is expected in up to 94% of patients after stent deployment [56,57]. Concerns regarding long-term complications of SEMS for benign airway diseases have been raised [58,59]. Previous reports have shown an overall 54% incidence of complications, of which 16–33% are due to infection, 12–36% due to granulation tissue formation and 5% due to stent migration [55,56,58]. Stent colonization has been described in up to 78% of patients, occasionally, with biofilms formation. Other complications include halitosis and metal fatigue. SEMS, once deployed, become very difficult or impossible to remove if

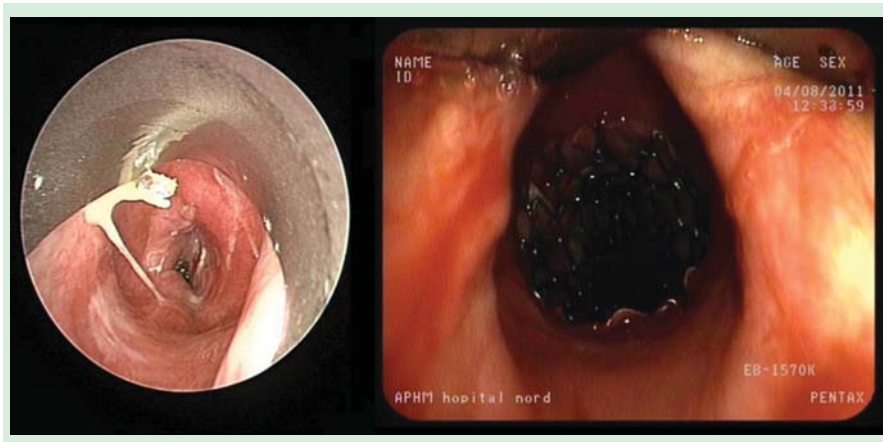


**Figure 6.** The Bonastent (Sewoon Medical, Cheonan, South Korea).



**Figure 7.** Stenting in malignancy. (A) Tracheal invasion from a thyroid cancer before and after mechanical debulking and Silmet stent placement. (B) Tracheal invasion from an esophageal cancer before and after mechanical debulking and Silmet stent placement.





**Figure 8. Benign post-tracheostomy tracheal stenosis before and after Silmet stent placement.**

left in place for a long enough time. Consequently, their use in benign disease should be cautious [58]. Recently, a new fully covered SEMS has been used with some success in post-LT anastomotic stenosis [59], but others failed to demonstrate any therapeutic advantage [60].

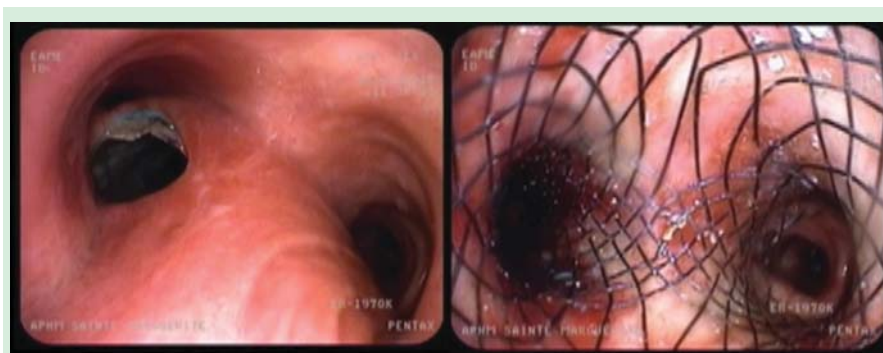#### Tracheobronchomalacia

Adult TBM is traditionally defined as a localized or diffuse expiratory reduction >50% of the airway lumen [61–64]. During recent years, various stents have been used for this indication [61,65]. It is difficult, however, to draw conclusions about the efficacy of endoluminal stents pertaining only to TBM and excessive dynamic airway collapse based on available data [61]. Pulmonary function tests improve significantly after stenting. More than one stent may be required if the symptoms persist after stenting presumably because of distally migrated choke points [66,67]. Nowadays, most endoscopists have become reluctant about the use of permanent stent placement for malacia because of the high rate of long-term complications. Therefore, a trial and error approach can be considered and a temporary stent can be placed in order to determine whether patients might benefit from internal splinting. In case of improvement, surgery using external stenting techniques can be considered or,

life but can fails to seal the fistula. Furthermore, the esophageal stent can protrude into the lumen of the airway and compromise ventilation (FIGURE 9) [71]. Placement of an airway stent can prevent airway obstruction from the esophageal stent and can help in sealing the fistula [72–74].

#### Post-lung transplantation anastomotic dehiscences

Dehiscence often responds to medical and bronchoscopic treatment. Partial dehiscence is often treated conservatively, mainly with close surveillance and aggressive antibiotic therapy, if needed, and with the understanding that some may develop strictures, bronchomalacia or excessive granulation tissue [75–77]. Successful management of life-threatening dehiscence with the temporary placement of uncovered SEMS has been reported [76]. SEMS are also known to cause excessive granulation tissue, which provides a platform for the healing of the dehiscence. Anastomotic healing can be noticed as early as 1 week after the deployment. The stents are usually removed at 6–8 weeks after the healing and prior to their epithelialization. The mean time to stent removal was 37.5 days [76]. Uncovered SEMS are recommended to allow drainage of mediastinal and bronchial secretion and ventilation of all involved lobes and avoiding the possibility of bacterial colonization of the polyurethane coating [77].



**Figure 9. Tracheoesophageal fistula created by the protrusion of an esophageal stent before and after Micro-Tech Y stent placement.**

alternatively, the stent may be left in place if tolerated and if surgery is deemed contraindicated or not technically feasible [68].

#### Fistulas & dehiscences

##### Malignant tracheobronchial fistulas

Esophageal carcinomas show airway infiltration in up to 30% of cases [69]. Fewer than half of these patients are resectable. If an esophago-airway fistula develops, a rapid decline of the overall condition with distressing cough and aspiration pneumonia is usually observed. In rare cases, primary bronchogenic carcinomas invade the esophagus causing similar problems [70]. Insertion of an esophageal stent improves the quality of

##### Post-thoracic surgery stump dehiscence

Post-pneumonectomy or post-lobectomy stump fistulas are severe complications of thoracic surgery. Its incidence ranges from 4.5 to 20% [78]. The incidence is lower for benign conditions compared with patients with a known malignancy. Management depends on a number of factors including the underlying etiology, size, time of onset of the fistula post-surgery and health status of the patient. Surgery is the treatment of choice for this condition but endoscopic techniques have been advocated as an option when



surgery is not possible or has to be postponed [79]. There are very few papers in the literature reporting the use of stents in cases with a post-lobectomy or post-pneumonectomy bronchopleural fistula (BPF). Li *et al.* treated eight patients with a post-lobectomy or pneumonectomy fistula using two types of covered, retrievable, metallic hinged stents and reported permanent closure of the BPF in seven cases (87.5%) [80]. Madden *et al.* treated two patients with post-pneumonectomy fistulas using a covered SEMS. However, the outcome was poor (two deaths) [81]. There are four case reports in the literature using two different types of SEMS, which described successful closure of the post-surgical BPF [82–85]. Our group also published a retrospective study investigating a conical custom-made SEMS to treat large post-pneumonectomy stump dehiscences (FIGURE 10). Initial air leak sealing was effective in all the patients but long-term results were jeopardized by underlying diseases and comorbidities [86].

Recently, Wu *et al.* have published their experience of the treatment of right BPFs with a novel, Y-shaped, single-plugged, covered, metallic airway stent [87].

### Physical properties of metallic stents

A stent is used to establish and maintain recanalization of the airways against the intrinsic and extrinsic compression caused by tumors and other pathologies. Rarely is the extrinsic compression so strong that a stent does not expand provided that it has been selected and released properly. Commercially available airway stents behave differently in a stress–strain test [21,24]. Looking at the chart displaying stress–strain curves of currently popular stents, it is obvious that we still do not know how much expansion force is really required for particular airway problems [21,24]. The silicone stents radial force is higher than the metallic stents. Among metallic stents, the Nanjing stent has the highest radial force and the Ultraflex has the lowest (the Aero stent being in between) [21,24]. Another consideration is the behavior of a stent during coughing. Dynamic compression is essential in normal airways in order to achieve the high-flow velocities required to drain secretions. The stent will deform under these pressure swings, meaning it has to be soft. However, it is known that repetitive deformation results in fatigue fractures. It is necessary to keep these limitations and possible risks in mind before and after stent insertion.

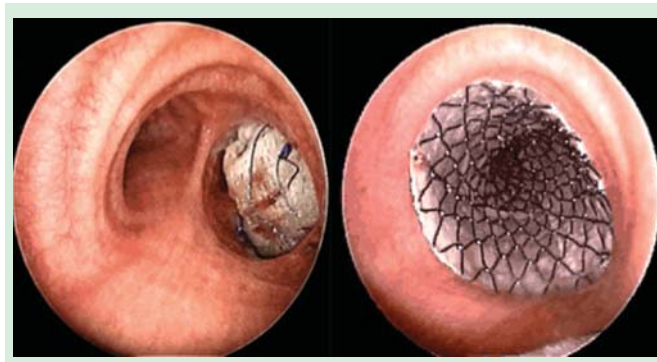
### Complications of metallic airway stents

#### Mucostasis & halitosis

Halitosis (bad smell) results from colonization of the stent with bacteria and fungi [21]. Synthetic materials and polymer used to develop stents frequently develop biofilms. Mucostasis (FIGURE 11) is the most frequent side effect of the airway stents and is observed in at least a third of all stent patients [21].

#### Migration

Stent migration is a common problem, especially in longer, straighter airways such as trachea. Less often, bifurcated stents and the stents in smaller airways can migrate as well [21]. Due to variable airway caliber in different situations such as during



**Figure 10. Complete dehiscence of the stump after right pneumonectomy before and after placement of a conical Silmet stent.**

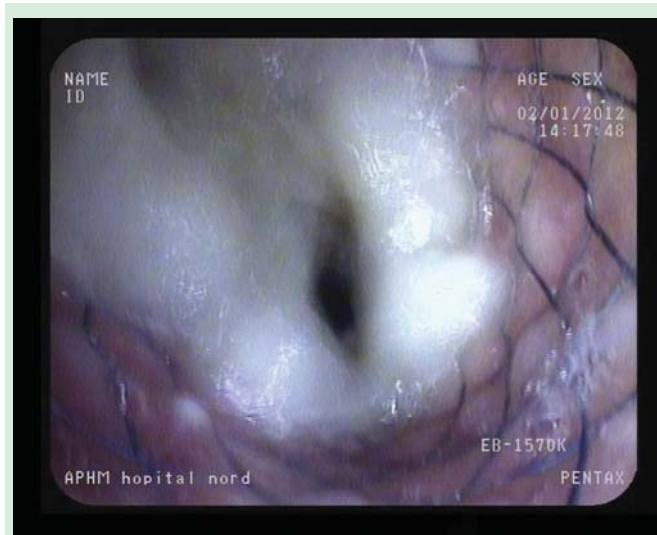
the procedure while the patient is lying flat under sedation or anesthesia versus ambulation and spontaneously breathing, even the well-placed and properly sized stents can migrate. Uncovers or partially covered SEMS have a lower migration rate than fully covered stents.

#### Granulation tissue formation

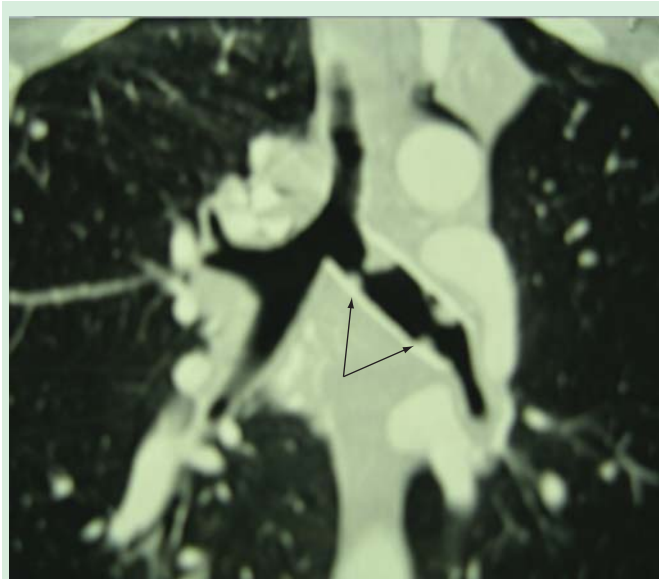
Granulation tissue formation occurs in more than half of all patients with stents to some degree. In about a quarter of all patients it becomes clinically significant, especially if bare metal stents are placed (FIGURE 12) [88,89]. Besides granuloma formation, scarring and shrinking is often seen around the edges of the stent. Repeated scratching of sharp edges of stents over the mucosa as well as oversizing of stents can result in the development of secondary stenoses. Patients with immunosuppressive therapy, such as transplant recipients, develop less granulations [90,91].

#### Fractures & stent failures

Cyclic compressions can deform and fracture airway stents. The airways are under constant repetitive pressure swings from

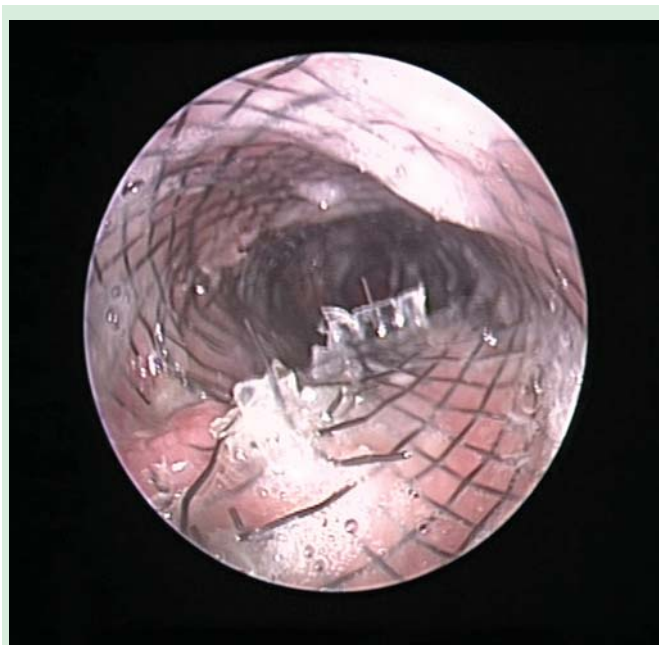

**Figure 11. Mucostasis in a tracheal Bonastent.**



**Figure 12.** Granulations creating two stenoses (black arrows) at the level of the two uncovered tips of an Ultraflex stent placed for a benign left main stem bronchus stenosis.

breathing. Coughing creates considerable deformation and typical metal stents are compressed down to half of their resting diameter during cough [24,92,93]. Despite the claims made by most manufacturers, typical fatigue fractures are often found in metallic stents, regardless of their design or material. From our personal experience, SEMS placed in the trachea are more prone to fractures than those in the bronchi where mechanical forces are not as intense (FIGURE 13). A broken stent can lose its



**Figure 13.** Fracture of the tracheal branch of a Micro-Tech Y stent.

infrastructure and consequently, function due to its inability to withstand radial forces. Broken wire filaments can function as sharp spikes damaging the mucosa with respiratory movement of the airways promoting granulation tissue formation. The coverings of metallic stents can sometimes become loose with time and complex contours of the airways. Separation of the membrane from the wire frame or metal mesh can allow growth of the granulation tissue or tumors through the stent resulting in stent/airway obstruction. Mucus can also get trapped between the wire mesh and the membrane compromising stent lumen.

#### **Bronchovascular fistulas**

This is a potentially fatal complication of bronchovascular fistula arising from SEMS placement. In a retrospective study, Choudhary *et al.* found five patients who developed tracheo/bronchovascular fistulas for a total of 483 SEMS placed [94]. True incidence and precise time interval between the insertion of stent and onset of this complication is unknown. Additional therapeutic modalities to maintain stent patency may enhance the risk of fistula formation.

#### **Advantages & disadvantages of metallic stents compared with silicone stents**

##### **Advantages**

The possibility to insert and to remove [95] metallic stents in the airway under conscious sedation with a flexible bronchoscope has been promoted as one of the major advantages by some authors. It is also possible to place them with laryngeal mask airways [96].

On the other hand, the necessity of rigid bronchoscopy and general anesthesia for the placement of silicone stents is considered by some as a disadvantage. However, in our opinion this should not be the case. The skills/resources to perform rigid bronchoscopy are essential for the management of potential complications that may result during and after the insertion or removal of metallic stents [97].

Due to pliability of the silicone stent, curvilinear airway obstructions are not an ideal indication for its use. In these situations, the stent may either fold centrally resulting in obstruction or even migrate due to the tendency to maintain its straight tubular shape. SEMS in such situation are a better choice.

The tubular structure with external studs of the Dumon stent may limit its ability to achieve a complete apposition of stent to the airway wall, leading to incomplete seal in the case of a fistula and anastomotic dehiscence. This leads to a possibility of small leak around the stent. Therefore, in our practice, fully covered SEMS is the first choice to treat fistulas and dehiscences.

In case of very large airways such as in tracheobronchomegaly, a custom-made SEMS of up to 28 mm can be placed [98] whereas, due to the size limitations of the silicone stent rigid delivery system, the largest silicone stent that can be inserted is 20 mm.

### Disadvantages

Unlike silicone stents, which are indicated for the vast majority malignant and benign indications, metal stents are only indicated in malignant diseases and in very few benign diseases when all other options are exhausted [21]. In benign conditions, removability of the stent is mandatory. Silicone stents are time tested and proven to be the easiest stents to remove. The new fully covered metal stents may turn out to be better than uncovered and partially covered stents in terms of removal but jury is still out on if they will perform nearly as good as silicone stents.

Unlike silicone stents, SEMS have a relatively weak radial force that leads to secondary compression in cases of severe external airway pressure.

Silicone stents can readily be manipulated and repositioned within the airway without any concern of airway damage [21]. Silicone stents can also be tailored on site to allow ventilation of specific lobes while maintaining its radial force and the patency of the airways. Specially designed instrument allows crafting a window in the wall of the silicone stent for such indications [99], which is impossible in metallic stents.

### Conclusion

Airway stents have changed the course of central airway diseases. It cannot be overemphasized that airway stenting represent palliative, as opposed to curative interventions, irrespective of the underlying etiology. Palliation means that it should be considered only after all medical or surgical options have been exhausted. However, stenting can be considered as a primary treatment in some cases as a bridge toward the definitive management. 'A stent is a foreign body and no foreign body is perfect', so after placement, one should expect and be ready to manage stent-related complications that often require multiple serial interventions. In malignancy, the concept of 'palliation' is particularly relevant, as unfortunately patients typically die before stent-related complications have a chance to occur. In the case of benign diseases, however, the choice of the stent is critical in limiting the occurrence of stent-related complications. The only guideline ever published regarding interventional bronchoscopy is the British Thoracic Society guideline

for advanced diagnostic and therapeutic flexible bronchoscopy in adults [100]. In the summary of recommendations, the chapter regarding airway support with stents (evidence-based level D) is reported in the key issues section.

### Expert commentary

Airway stenting is one of the primary focuses of interventional pulmonology: the near absence of prospective and comparative studies has resulted in very low levels of evidence-based medicine in this area. In addition, administrative requirements from regulatory bodies for commercialization of medical devices (such as stents) are much lower than for drugs. As a result, close to 10 SEMS are currently available on the market without any proven advantages or disadvantages of one over the other. Hence, airway stenting is almost entirely anecdotal and based on expert opinion.

### Five-year view

Randomized and prospective clinical studies are mandatory to clarify indications, patient selection and proper choice of stents for specific situations. In the future, stents will be much more than just a passive inert body providing structural support. There will be biodegradable and drug-eluting stents that will probably increase the indications and applications of stents.

### Acknowledgements

*The authors would like to thank L Freitag (Essen, Germany) for sharing his huge knowledge and experience in airway stenting.*

### Financial & competing interests disclosure

*H Dutau is a consultant for Novatech SA. AI Musani is a consultant for Boston Scientific, USA. The authors have no other relevant affiliations or financial involvement with any organization or entity with a financial interest in or financial conflict with the subject matter or materials discussed in the manuscript. This includes employment, consultancies, honoraria, stock ownership or options, expert testimony, grants or patents received or pending or royalties.*

*No writing assistance was utilized in the production of this manuscript.*

### Key issues

- The use of self-expanding metallic stents (SEMS) may be considered for the treatment of malignant central airway obstruction due to extrinsic disease.
- SEMS may be used to maintain airway patency following endobronchial debulking techniques.
- SEMS can be used to restore or maintain airway patency in conjunction with other treatments such as external beam radiotherapy.
- Patients require careful specialist follow-up after stent insertion.
- Stents should be used with caution in non-malignant disease, considering their long-term complications. SEMS may be difficult to remove following long-term placement.
- SEMS should only be used in benign disease after all other therapeutic options have been exhausted.
- A risk-benefit assessment should be performed, incorporating immediate and long-term implications, prior to selecting any particular type of stent.



## References

- Dumon JF. A dedicated tracheobronchial stent. *Chest* 1990;97(2):328-32
- Pagliaro KM, Shepherd MP. Use of stainless-steel wire coil prosthesis in treatment of anastomotic dehiscence after cervical tracheal resection. *J Thorac Cardiovasc Surg* 1974;67(6):932-5
- Filler RM, Buck JR, Bahiric A. Treatment of segmental tracheomalacia and bronchomalacia by implantation of an airway splint. *J Pediatr Surg* 1982;17(5):597-603
- Goddard JM, Booker PD. The use of bronchial stents in the management of bronchomalacia. *Anaesthesia* 1987;42(5):534-5
- Simonds AK, Irving JD, Clarke SW, et al. Use of expandable metal stents in the treatment of bronchial obstruction. *Thorax* 1989;44(8):680-1
- Varela A, Maynar M, Irving D, et al. Use of Gianturco self-expandable stents in the tracheobronchial tree. *Ann Thorac Surg* 1990;49(5):806-9
- Mair EA, Parsons DS, Lally KP. Treatment of severe bronchomalacia with expanding endobronchial stents. *Arch Otolaryngol Head Neck Surg* 1990;116(9):1087-90
- Spatenka J, Khaghani A, Irving JD, et al. Gianturco self-expanding metallic stents in treatment of tracheobronchial stenosis after single lung and heart transplantation. *Eur J Cardiothorac Surg* 1991;5(12):648-52
- Nashef SA, Dromer C, Velly JF, et al. Expanding wire stents in benign tracheobronchial disease: indications and complications. *Ann Thorac Surg* 1992;54(5):937-40
- Do YS, Song HY, Lee BH, et al. Esophagorespiratory fistula associated with esophageal cancer: treatment with a Gianturco stent tube. *Radiology* 1993;187(3):673-7
- Rousseau H, Dahan M, Lauque D. Self-expandable prostheses in the tracheobronchial tree. *Radiology* 1993;188(1):199-203
- Dunne JA, Sabanathan S. Use of metallic stents in relapsing polychondritis. *Chest* 1994;105(3):864-7
- Kim YH, Shin JH, Song HY, et al. Tracheal stricture and fistula: management with a barbed silicone-covered retrievable expandable nitinol stent. *AJR Am J Roentgenol* 2010;194(2):W232-7
- Shin JH, Song HY, Kim KR, et al. Radiologic and clinical outcomes with special reference to tumor involvement pattern after stent placement for malignant bronchial obstructions. *Acta Radiol* 2009;50(9):1011-18
- Lee KE, Shin JH, Song HY, et al. Management of airway involvement of oesophageal cancer using covered retrievable nitinol stents. *Clin Radiol* 2009;64(2):133-41
- Kim JH, Shin JH, Song HY, et al. Use of a retrievable metallic stent internally coated with silicone to treat airway obstruction. *J Vasc Interv Radiol* 2008;19(8):1208-14
- Nakamura T, Shimizu Y, Ito Y, et al. A new thermal shape memory Ti-Ni alloy stent covered with silicone. *ASAIO J* 1992;38:347-50
- Gildea TR, Downie G, Eapen G, et al. A prospective multicenter trial of a self-expanding stent in malignant airway obstruction. *J Bronchol* 2008;15(4):221-4
- Dooms C, De Keukeleire T, Janssens A, et al. Performance of fully covered self-expanding metallic stents in benign airway strictures. *Respiration* 2009;77(4):420-6
- Wood De, Liu YH, Vallieres E, et al. Airway stenting for malignant and benign tracheobronchial stenosis. *Ann Thorac Surg* 2003;76(1):167-74
- Freitag L. Airway stents. In: Strausz J, Bolliger CT, editors. *Interventional pulmonology*. European Respiratory Society; 2010. 18: p. 190-217
- Dutau H, Toubanc B, Lamb C, et al. Use of the Dumon Y-stent in the management of malignant diseases involving the carina: a retrospective review of 86 patients. *Chest* 2004;126(3):951-8
- Strecker EP, Liermann D, Barth KH, et al. Expandable tubular stents for treatment of arterial occlusive diseases: experimental and clinical results. *Radiology* 1990;175(1):97-102
- Freitag L, Eicker K, Donovan TJ, et al. Mechanical properties of airway stents. *J Bronchol* 1995;2(4):270-8
- Miyazawa T, Yamakido M, Ikeda S, et al. Implantation of Ultraflex nitinol stents in malignant tracheobronchial stenoses. *Chest* 2000;118(4):959-65
- Chhajed PN, Malouf MA, Tamm M, et al. Ultraflex stents for the management of airway complications in lung transplant recipients. *Respirology* 2003;8(1):59-64
- Saad CP, Murthy S, Krizmanich G, et al. Self-expandable metallic airway stents and flexible bronchoscopy: long-term outcomes analysis. *Chest* 2003;124(5):1993-9
- Husain SA, Finch D, Ahmed M, et al. Long-term follow-up of Ultraflex metallic stents in benign and malignant central airway obstruction. *Ann Thorac Surg* 2007;83(4):1251-6
- Breitenbucher A, Chhajed PN, Brutsche MH, et al. Long-term follow-up and survival after Ultraflex stent insertion in the management of complex malignant airway stenoses. *Respiration* 2008;75(4):443-9
- Hautmann H, Rieger J, Huber RM, et al. Elastic deformation properties of implanted endobronchial wire stents in benign and malignant bronchial disease: a radiographic in vivo evaluation. *Cardiovasc Intervent Radiol* 1999;22(2):103-8
- Fernandez-Bussy S, Akindipe O, Kulkarni V, et al. Clinical experience with a new removable tracheobronchial stent in the management of airway complications after lung transplantation. *J Heart Lung Transplant* 2009;28(7):683-8
- Gompelmann D, Eberhardt R, Schuhmann M, et al. Self-expanding Y stents in the treatment of central airway stenosis: a retrospective analysis. *Ther Adv Respir Dis* 2013;7(5):255-63
- Minna JD, Higgins GA, Glatstein EJ. Cancer of the lung. In: De Vita VT, Hellman S, Rosenberg SA, editors. *Cancer principles and practice of oncology*. 3rd edition JB Lippincott Co; Philadelphia, PA, USA: 1989. p. 591-705
- Vergnon JM. Les traitements endoscopiques du cancer bronchique. *Rev Mal Respir* 2008;25:3S160-6
- Mohsenifar Z, Jasper A, Koerner S. Physiologic assessment of lung function in patients undergoing laser photoresection of tracheobronchial tumors. *Chest* 1988;93(1):65-9
- Eichenhorn MS, Kvale PA, Miks VM, et al. Initial combination therapy with yag laser photoresection and irradiation for inoperable non small cell carcinoma of the lung. *Chest* 1986;89(6):782-5
- Desai SJ, Mehta AC, Medendorp SV, et al. Survival experience following Nd Yag laser photoresection for primary bronchogenic carcinoma. *Chest* 1988;94(5):939-44
- Ross DJ, Mohsenifar Z, Koerner SK. Survival characteristics after Nd-Yag laser photoresection in advanced lung cancer. *Chest* 1990;98(3):581-5
- Macha HN, Becker KO, Kemmer HP. Pattern of failure and survival in endobronchial laser resection. A match pair study. *Chest* 1994;105(6):1668-72



40. Oviatt PL, Stather DR, Michaud G, et al. Exercise capacity, lung function, and quality of life after interventional bronchoscopy. *J Thorac Oncol* 2011;6(1):38-42
41. Chhahed PN, Baty F, Pless M, et al. Outcome of treated advanced non-small cell lung cancer with and without central airway obstruction. *Chest* 2006;130(6):1803-7
42. Vergnon J-M, Costes F, Bayon MC, et al. Efficacy of tracheal and bronchial stent placement on respiratory functional tests. *Chest* 1995;107(3):741-6
43. Saji H, Furukawa K, Tsutsui H, et al. Outcomes of airway stenting for advanced lung cancer with central airway obstruction. *Interact Cardiovasc Thorac Surg* 2010;11(4):425-8
44. Baignee PE, Marquette CH, Ramon P, et al. Endoscopic treatment of post-intubation tracheal stenosis. A propos of 58 cases. *Rev Mal Respir* 1995;12(6):585-92
45. Brichet A, Verkindre C, Dupont J, et al. Multidisciplinary approach to management of post-intubation tracheal stenoses. *Eur Respir J* 1999;13(4):888-93
46. Mehta AC, Lee FY, Cordasco EM, et al. Concentric tracheal and subglottic stenosis. Management using Nd-YAG laser for mucosal sparing followed by gentle dilatation. *Chest* 1993;104(3):673-7
47. Galluccio G, Lucantoni G, Battistoni P, et al. Interventional endoscopy in the management of benign tracheal stenoses: definitive treatment at long-term follow up. *Eur J Cardiothorac Surg* 2009;35(3):429-33
48. Gaissert HA, Grillo HC, Wright CD, et al. Complication of benign tracheobronchial strictures by self-expanding metal stents. *J Thorac Cardiovasc Surg* 2003;126(3):744-7
49. US FDA. FDA public health notification: Complications from metallic tracheal stents in patients with benign airway disorders; 29 July 2005. Available from: [www.fda.gov/MedicalDevices/Safety/AlertsandNotices/PublicHealthNotifications/UCM062115](http://www.fda.gov/MedicalDevices/Safety/AlertsandNotices/PublicHealthNotifications/UCM062115)
50. Ranu H, Evans J, Sheth A, et al. Removal of long-term tracheal stents with excellent tracheal healing. *Ann Thorac Surg* 2010;89(2):598-9
51. Noppen M, Stratakis G, D'Haese J, et al. Removal of covered self-expandable metallic airway stents in benign disorders: indications, technique, and outcomes. *Chest* 2005;127(2):482-7
52. Charokopos N, Foroulis CN, Rouska E, et al. The management of post-intubation tracheal stenoses with self-expandable stents: early and long-term results in 11 cases. *Eur J Cardiothorac Surg* 2011;40(4):919-24
53. Dutau H. Airway stenting for benign tracheal stenosis: what is really behind the choice of the stent? *Eur J Cardiothorac Surg* 2011;40(4):924-5
54. Chen G, Wang Z, Liang X, et al. Treatment of cuff-related tracheal stenosis with a fully covered retrievable expandable metallic stent. *Clin Radiol* 2013;68(4):358-64
55. De Gracia J, Culebras M, Alvarez A, et al. Bronchoscopic balloon dilatation in the management of bronchial stenosis following lung transplantation. *Respir Med* 2007;101(1):27-33
56. Kapoor BS, May B, Panu N, et al. Endobronchial stent placement for the management of airway complications after lung transplantation. *J Vasc Interv Radiol* 2007;18(5):629-32
57. Saad CP, Ghamande SA, Minai OA, et al. The role of self-expandable metallic stents for the treatment of airway complications after lung transplantation. *Transplantation* 2003;75(9):1532-8
58. Madden BP, Loke TK, Sheth AC. Do expandable metallic airway stents have a role in the management of patients with benign tracheobronchial disease? *Ann Thorac Surg* 2006;82(1):274-8
59. Xie BX, Zhu YM, Chen C, et al. Outcome of TiNi stent treatments in symptomatic central airway stenoses caused by *Aspergillus fumigatus* infections after lung transplantation. *Transplant Proc* 2013;45(6):2366-70
60. Tan JH, Fidelman N, Durack JC, et al. Management of recurrent airway strictures in lung transplant recipients using AERO covered stents. *J Vasc Interv Radiol* 2010;21(12):1900-4
61. Murgu SD, Colt HG. Complications of silicone stent insertion in patients with expiratory central airway collapse. *Ann Thorac Surg* 2007;84(6):1870-7
62. Baxter JD, Dunbar JS. Tracheomalacia. *Ann Otol Rhinol Laryngol* 1963;72:1013-23
63. Murgu SD, Colt HG. Tracheobronchomalacia and excessive dynamic airway collapse. *Respirology* 2006;11(4):388-406
64. Carden KA, Boisselle PM, Waltz DA, et al. Tracheomalacia and tracheobronchomalacia in children and adults: an in-depth review. *Chest* 2005;127(3):984-1005
65. Ernst A, Odell DD, Michaud G, et al. central airway stabilization for tracheobronchomalacia improves quality of life in patients with chronic obstructive pulmonary disease. *Chest* 2011;140(5):1162-8
66. Miyazawa T, Miyazu Y, Iwamoto Y, et al. Stenting at the flow-limiting segment intracheobronchial stenosis due to lung cancer. *Am J Respir Crit Care Med* 2004;169(10):1096-102
67. Ernst A, Majid A, Feller-Kopman D, et al. Airway stabilization with silicone stents for treating adult tracheobronchomalacia: a prospective observational study. *Chest* 2007;132(2):609-16
68. Murgu SD, Colt HG. Tracheobronchoplasty for severe tracheobronchomalacia. *Chest* 2009;135(5):1403-4
69. Gudovsky LM, Koroleva NS, Biryukov YB, et al. Tracheoesophageal fistulas. *Ann Thorac Surg* 1993;55(4):868-75
70. Buset M, Des Marez B, Cremer M. Endoscopic palliative intubation of the esophagus invaded by lung cancer. *Gastrointest Endosc* 1990;36(4):357-9
71. Colt HG, Meric B, Dumon JF. Double stents for carcinoma of the esophagus invading the tracheo-bronchial tree. *Gastrointest Endosc* 1992;38(4):485-9
72. Freitag L, Tekolf E, Steveling H, et al. Management of malignant esophago-tracheal fistulas with airway stenting and double stenting. *Chest* 1996;110(5):1155-60
73. Paganin F, Schouler L, Cuissard L, et al. Airway and esophageal stenting in patients with advanced esophageal cancer and pulmonary involvement. *PLoS One* 2008;3:e3101
74. Oida T, Mimatsu K, Kano H, et al. Double stents: airway stenting after esophageal-stent implantation for esophageal cancer. *Hepatogastroenterology* 2011;58(112):1985-8
75. Schmid RA, Boehler A, Speich R, et al. Bronchial anastomotic complications following lung transplantation: still a major cause of morbidity? *Eur Respir J* 1997;10(12):2872-5
76. Mughal MM, Gildea TR, Murthy S, et al. Short-term deployment of self-expanding metallic stents facilitates healing of bronchial dehiscence. *Am J Respir Crit Care Med* 2005;172(6):768-71
77. Usuda K, Gildea T, Pandya C, et al. Bronchial dehiscence. *J Bronchol* 2005;12(3):164-5
78. Cerfolio RJ. The incidence, etiology and prevention of postresectional bronchopleural

- fistula. *Semin Thorac Cardiovasc Surg* 2001;13(1):3-7
79. Lois M, Noppen M. Bronchopleural fistulas. An overview of the problem with a special focus on endoscopic management. *Chest* 2005;128(6):3955-65
  80. Li YD, Han XW, Li MH, et al. Bronchial stump fistula treatment with covered, retrievable, expandable, hinged stents – preliminary clinical experience. *Acta Radiol* 2006;47(9):922-6
  81. Madden BP, Loke TK, Sheth AC. Do expandable metallic stents have a role in the management of patients with benign tracheobronchial disease? *Ann Thorac Surg* 2006;82(1):274-8
  82. García Franco CE, Flandes Aldeyturriaga J, Zapatero Gaviria J. Ultraflex expandable metallic stent for the treatment of bronchopleural fistula after pneumonectomy. *Ann Thorac Surg* 2005;79(1):386
  83. Madden BP, Sheth A, Ho TB, et al. A novel approach to the management of persistent postpneumonectomy bronchopleural fistula. *Ann Thorac Surg* 2005;79(6):2128-30
  84. Jones NC, Kirk AJ, Edwards RD. Bronchopleural fistula treated with a covered wall stent. *Ann Thorac Surg* 2006;81(1):364-6
  85. Takahashi M, Takahashi H, Itoh T, et al. Ultraflex expandable stents for the management of air leaks. *Ann Thorac Cardiovasc Surg* 2006;12(1):50-2
  86. Dutau H, Breen DP, Gomez C, et al. The integrated place of tracheobronchial stents in the multidisciplinary management of large post-pneumonectomy fistulas: our experience using a novel customized conical self expandable metallic stent. *Eur J Cardio Thorac Surg* 2011;39(2):185-9
  87. Wu G, Li ZM, Han XW, et al. Right bronchopleural fistula treated with a novel, Y-shaped, single-plugged, covered, metallic airway stent. *Acta Radiol* 2013;54(6):656-60
  88. Grewe PH, Muller KM, Lindstaedt M, et al. Reaction patterns of the tracheobronchial wall to implanted noncovered metal stents. *Chest* 2005;128(2):986-90
  89. Chung FT, Lin SM, Chou CL, et al. Factors leading to obstructive granulation tissue formation after Ultraflex stenting in benign tracheal narrowing. *Thorac Cardiovasc Surg* 2010;58(2):102-7
  90. Braidy J, Breton G, Clement L. The effect of corticosteroids on post-intubation tracheal stenosis. *Chest* 1989;96(1):178-80
  91. Shlomi D, Peled N, Shitrit D, et al. Protective effect of immunosuppression on granulation tissue formation in metallic airway stents. *Laryngoscope* 2008;118(8):1383-8
  92. Chung FT, Lin SM, Chen HC, et al. Factors leading to tracheobronchial self-expandable metallic stent fracture. *J Thorac Cardiovasc Surg* 2008;136(5):1328-35
  93. Hautmann H, Rieger J, Huber RM, et al. Elastic deformation properties of implanted endobronchial wire stents in benign and malignant bronchial disease: a radiographic in vivo evaluation. *Cardiovasc Intervent Radiol* 1999;22(2):103-8
  94. Choudhary C, Bandyopadhyay D, Salman R, et al. Broncho-vascular fistulas from self-expanding metallic stents: a retrospective case review. *Ann Thorac Med* 2013;8(2):116-20
  95. Fruchter O, Raviv Y, Fox BD, et al. Removal of metallic tracheobronchial stents in lung transplantation with flexible bronchoscopy. *J Cardiothorac Surg* 2010;5:72
  96. Fuehner T, Wiesner O, DeWall C, et al. Self-expanding metallic stent placement with laryngeal mask in lung transplant recipients. *Transplant Proc* 2010;42(10):4595-9
  97. Redmond J, Diamond J, Dunn J, et al. Rigid bronchoscopic management of complications related to endobronchial stents after lung transplantation. *Ann Otol Rhinol Laryngol* 2013;122(3):183-9
  98. Dutau H, Cavailles A, Fernandez-Navamuel I, et al. Tracheal compression in a patient with Marfan's syndrome-associated tracheomegaly treated by a XXL Stent: the largest diameter airway stent ever placed in a previously undescribed airway condition. *Respiration* 2009;77(1):97-101
  99. Breen DP, Dutau H. On-site customization of silicone stents: towards optimal palliation of complex airway conditions. *Respiration* 2009;77(4):447-53
  100. Du Rand IA, Barber PV, Goldring J, et al. British Thoracic Society guideline for advanced diagnostic and therapeutic flexible bronchoscopy in adults. *Thorax* 2011;66(11):1014-15