



Article scientifique

Article

1998

Published version

Open Access

This is the published version of the publication, made available in accordance with the publisher's policy.

Genotype-phenotype correlations in attenuated adenomatous polyposis coli

Soravia, Claudio; Berk, T; Madlensky, L; Mitri, A; Cheng, H; Gallinger, S; Cohen, Z; Bapat, B

How to cite

SORAVIA, Claudio et al. Genotype-phenotype correlations in attenuated adenomatous polyposis coli. In: American journal of human genetics, 1998, vol. 62, n° 6, p. 1290–1301. doi: 10.1086/301883

This publication URL: <https://archive-ouverte.unige.ch/unige:74254>

Publication DOI: [10.1086/301883](https://doi.org/10.1086/301883)

Genotype-Phenotype Correlations in Attenuated Adenomatous Polyposis Coli

Claudio Soravia,^{1,3} Terri Berk,³ Lisa Madlensky,³ Angela Mitri,² Hong Cheng,² Steven Gallinger,^{1,3} Zane Cohen,^{1,3} and Bharati Bapat^{2,3}

Departments of ¹Surgery and ²Pathology and Laboratory Medicine and ³Familial Gastrointestinal Cancer Registry, Mount Sinai Hospital, University of Toronto, Toronto

Summary

Germ-line mutations of the tumor suppressor *APC* are implicated in attenuated adenomatous polyposis coli (AAPC), a variant of familial adenomatous polyposis (FAP). AAPC is recognized by the occurrence of <100 colonic adenomas and a later onset of colorectal cancer (age >40 years). The aim of this study was to assess genotype-phenotype correlations in AAPC families. By protein-truncation test (PTT) assay, the entire coding region of the *APC* gene was screened in affected individuals from 11 AAPC kindreds, and their phenotypic differences were examined. Five novel germ-line *APC* mutations were identified in seven kindreds. Mutations were located in three different regions of the *APC* gene: (1) at the 5' end spanning exons 4 and 5, (2) within exon 9, and (3) at the 3' distal end of the gene. Variability in the number of colorectal adenomas was most apparent in individuals with mutations in region 1, and upper-gastrointestinal manifestations were more severe in them. In individuals with mutations in either region 2 or region 3, the average number of adenomas tended to be lower than those in individuals with mutations in region 1, although age at diagnosis was similar. In all AAPC kindreds, a predominance of right-sided colorectal adenomas and rectal polyp sparing was observed. No desmoid tumors were found in these kindreds. Our data suggest that, in AAPC families, the location of the *APC* mutation may partially predict specific phenotypic expression. This should help in the design of tailored clinical-management protocols in this subset of FAP patients.

Introduction

Familial adenomatous polyposis (FAP) is an inherited, autosomal dominant syndrome caused by germ-line mutations of the adenomatous polyposis coli (*APC*) gene, *APC* (Grodén et al. 1991; Kinzler et al. 1991). Clinical diagnosis of FAP is usually based on the presence of >100 colonic adenomas (Bussey 1975), which, if left untreated, progress to colorectal cancer (CRC), typically at age ≤40 years (Gardner 1951). Other features include variable age at onset of polyposis (age 10–40 years) and variable expressivity (Grodén et al. 1993; Giardiello et al. 1994). Extracolonic manifestations in FAP include the occurrence of desmoids, congenital hypertrophic retinal pigment-epithelial lesions (CHRPE), upper-gastrointestinal (UGI) polyps, and cancers of the thyroid, brain, and hepatobiliary tract. In previous studies, association of colonic polyposis and CRC with osteomas, fibromas, or epidermoid cysts has been described as a distinct entity, “Gardner syndrome” (Gardner and Richards 1953). That FAP and Gardner syndrome are the same genetic entity became apparent with the discovery of the *APC* gene and the identification of germ-line *APC* mutations in patients with those syndromes.

APC is a large (~300 kD) multifunctional protein and consists of distinct sequence motifs that specify its interactions with diverse protein partners (Polakis 1997). The majority of germ-line *APC* mutations cause truncated products and predominantly occur in the first half of the gene (Nagase et al. 1992a). Some phenotypic variants of FAP have been specifically associated with distinct mutation patterns in the *APC* gene. Thus, the occurrence of CHRPE is correlated with *APC* mutations in the region spanning exons 9–15 (Olschwang et al. 1993b), and the desmoid tumors are correlated with mutations in the region spanning codons 1444–1578 (Caspari et al. 1995). With regard to colonic adenomatous polyposis, a “sparse” phenotype (1,000–2,000 polyps) has been correlated with germ-line *APC* mutations in the region spanning codons 213–1597 (Nagase et al. 1992a); whereas a “profuse” (>5,000 polyps) phenotype has been demonstrated to segregate with *APC* mutations

Received February 12, 1998; accepted for publication April 16, 1998; electronically published May 15, 1998.

Address for correspondence and reprints: Dr. Bharati Bapat, Department of Pathology and Laboratory Medicine, Suite 600-20, Mount Sinai Hospital, 600 University Avenue, Toronto, Ontario, M5G 1X5, Canada. E-mail: bapat@mshri.on.ca

© 1998 by The American Society of Human Genetics. All rights reserved. 0002-9297/98/6206-0006\$020.00

in the region spanning codons 1250–1464 (Nagase et al. 1992b; Caspari et al. 1994; Gayther et al. 1994).

Recognition of such genotype-phenotype associations, along with the identification of distinct structural motifs, has provided important insights into APC's function. For example, APC carries a series of β -catenin-binding sites in the region associated with profuse polyposis. Using these sites, APC regulates intracellular turnover of β -catenin (Su et al. 1993), a protein involved in cellular adhesion, communication, and cell signaling pathways that affect apoptosis and cell growth (Hülsken et al. 1994; Morin et al. 1996, 1997; Peifer 1996; Rubinfeld et al. 1996; Korinek et al. 1997). Thus, mutant APC transcripts with deletions of the β -catenin-binding region function by mediating an imbalance of cell division over cell death, which likely results in an aggressive polyposis phenotype. Another functional domain, localized to the first 55 residues of APC, is involved in the protein-dimerization process (Joslyn et al. 1993). Mutation analyses have shown this domain to be almost always retained in the truncated mutant APC transcripts, which suggests that the dimerization domain is critical to APC's function.

Attenuated APC (AAPC) is a variant of FAP (Leppert et al. 1990) and also has been described as "hereditary flat adenoma syndrome" (Lynch et al. 1988, 1995). AAPC differs phenotypically from classical FAP, in the number of colonic adenomas (usually <100) that tend to be located proximal to the splenic flexure (van der Luijt et al. 1996; Giardiello et al. 1997; Gardner et al. 1997). These adenomas may present with a flat (rather than polypoid) morphology. Gastric fundic polyps and duodenal adenomas are also seen, and, in contrast to what is seen in FAP, CHRPE lesions and desmoid tumors rarely have been described in AAPC (Lynch et al. 1995; Scott et al. 1995). The average age at onset of CRC is later in AAPC (average age 55 years) than in classical FAP (average age 39 years) (Lynch et al. 1995). Furthermore, some AAPC families may phenotypically overlap with the hereditary nonpolyposis CRC syndrome (HNPCC), in which adenomas also are located on the right side of the colon (Jass et al. 1994). Alternatively, in some small nuclear AAPC families, the lack of accurate documentation regarding the number and/or the location of polyps may lead to a misdiagnosis of sporadic CRC.

In 1992, the attenuated variant was localized to the APC gene locus by molecular-genetic linkage analysis (Spirio et al. 1992). These observations were subsequently confirmed by the identification of four distinct germ-line mutations occurring at the 5' end of the APC gene (Spirio et al. 1993). Several reports have described AAPC families with unique APC mutations (Cama et al. 1994; Dobbie et al. 1994; Smith-Ravin et al. 1994; Varesco et al. 1994; van der Luijt et al. 1995; Giardiello

et al. 1997); however, only a few studies have investigated genotype-phenotype associations in AAPC (Spirio et al. 1993; Giardiello et al. 1997). In the present study, we used molecular-genetic characterization of APC to better classify kindreds that have a familial predisposition to colonic adenomas and CRC and that have phenotypic features not typical of FAP or HNPCC.

Subjects and Methods

Selection of Patients

Eleven unrelated kindreds with hereditary predisposition to colonic adenomas and CRC were identified, from the Familial Gastrointestinal Cancer Registry located at our institution. Most affected individuals had >10 but <100 adenomas, and 9 of 11 families had a history of CRC. Endoscopic, operative, and histopathological data were collected retrospectively. Complete follow-up information was obtained as well. Predictive genetic testing was offered to affected individuals, with pre- and posttest counseling (Soravia et al. 1997a). Patient accrual, sample collection, and genetic screening were performed according to guidelines of the Human Ethics Committee of the University of Toronto.

Molecular-Genetic Analysis

The protein-truncation test (PTT) assay was used to screen for APC germ-line mutations (Powell et al. 1993; van der Luijt et al. 1994). Blood samples were obtained from affected individuals, and lymphoblastoid Epstein-Barr virus-transformed cell lines were established for some of these patients. RNA and DNA extraction was performed by use of TRIzol[®] and DNazol[®], according to the manufacturer's protocol (Life Technologies). Reverse-transcription PCR was performed by use of standard techniques. In brief, cDNA was generated from total RNA (2–5 μ g) by use of random hexamers, 1 \times first-strand buffer, 0.5 mM of deoxynucleotide triphosphate, 10 mM DTT, and 200 units of Superscript II reverse transcriptase (Bethesda Research Laboratories). cDNA and genomic DNA were amplified under the following conditions: initial denaturation at 95°C for 2 min; 35–40 cycles, each consisting of denaturation at 95°C for 30 s, annealing at 63°C–65°C for 1 min 30 s, and extension at 70°C for 2 min; and a final extension at 70°C for 5 min. Five-microliter aliquots of PCR products were electrophoresed on a 1.5% agarose gel, in order to confirm amplification.

The in vitro-synthesized PTT assay was performed by use of a commercial kit (TNT7 T7 Quick Coupled Transcription/Translation System; Promega), according to the manufacturer's protocol. In brief, APC exon 15 was amplified in four overlapping segments, as described elsewhere (Powell et al. 1993). Exons 1–14 were amplified

Table 1**Characterization of APC Mutations**

Kindred(s)	Exon	Nucleotide Change	Consequence
1-3	4	Exon 4 deletion	Frameshift deletion (premature truncation) with TGA stop at nucleotide 551 (exon 5)
4	4	CAG→TAG	C→T substitution, Gln→stop, nucleotide 487
5	9	ATGT→TGT	Deletion of A, frameshift; termination at nucleotide 1014
6	9	CGA→TGA	C→T substitution, Arg→stop, nucleotide 994
7	15	TCCG→TCG	Deletion of C, frameshift, termination at nucleotide 6218

in two overlapping segments: 1A (exons 1-9) and 1B (exons 8-14). The 5' end of each forward primer had a T7 promoter sequence and a translation-initiation site for coupled *in vitro* transcription and translation. PCR products were separated on 12.5% polyacrylamide gels. Positive PTT results were confirmed by two independent PCR reactions.

For sequence determination, PCR products of the putative positive-PTT samples were electrophoresed on a 1.5% agarose gel for 45-60 min at 100 V and were stained with ethidium bromide. The band of interest was excised with a sterile scalpel blade, and DNA was extracted by use of the QIAquick Gel Extraction Kit (QIAGEN). The dideoxy-mediated chain-termination method was used for DNA sequencing (Sanger et al. 1977). For this purpose, we used α [³³P] dideoxynucleotide and a ThermoSequenase radiolabeled terminator sequencing kit (Amersham Life Science); sequencing was performed according to the manufacturer's protocol. Finally, the gel was autoradiographed by use of BioMax MR film (Kodak) for 24-48 h at room temperature. Additional confirmation was obtained by genomic DNA sequencing. Primers used for PTT-PCR and sequencing reactions are available on request.

Results

In 7 of the 11 kindreds, putative truncating mutations were identified as novel transcripts, by PTT analysis. Sequence characterization revealed five germ-line APC mutations in these seven families (table 1). To the best of our knowledge, all five APC mutations are novel (Béroud and Soussi 1996; De Vries et al. 1996). In three AAPC kindreds, a truncated-protein product of ~16 kD was identified, in addition to the wild-type protein for

APC segments 1 (codons 1-811; fig. 1A, lanes 3 and 4) and 1A (codons 1-379; figs. 1A, lanes 1 and 2, and 1B, lanes 5-7). Sequence analysis revealed this truncation to be caused by exon 4 deletion, leading to a frameshift mutation and resulting in a stop codon (TGA) at nucleotide 551 (codon 184). In kindred 4, the size of the novel PTT product was ~20 kD (fig. 1B, lane 5). DNA sequence analysis revealed a C→T transversion at nucleotide 487 (exon 4, codon 163), resulting in a substitution of glycine by a stop codon (CAG→TAG). In kindreds 5 and 6, the truncated proteins showed a similar pattern (doublet), ~46 kD in size (fig. 2A). Subsequent characterization by sequencing identified two distinct APC germ-line mutations within exon 9. Specifically, in kindred 5, the mutation occurred at nucleotide 988 (deletion A), resulting in a frameshift leading to a stop codon (TAG) at nucleotide 1014, and, in kindred 6, a C→T transversion at nucleotide 994 resulted in a substitution of arginine by a stop (GCA→TGA) at codon 332. Finally, in kindred 7, the size of the truncated protein was ~48 kD (fig. 2B). By sequence analysis, the mutation was identified to be a 1-bp frameshift deletion (C) at APC nucleotide 6138 (codon 2047), leading to a stop codon (TGA) at nucleotide 6218.

Tables 2-4 summarize phenotypic and clinical data on the seven kindreds, according to the location of the APC mutations. Kindred 2 is a large AAPC family and spans four generations with 27 affected individuals. In this family, a variability was observed with respect to the number of colorectal adenomas (mean 142, range 2-580). A predominance of right-sided colonic polyps with rectal sparing was observed in all AAPC families. In kindreds with 5'-end APC mutations (table 2), the mean age at polyposis diagnosis was 42 years (range 39.5-45.2 years), with a mean of 96 polyps (range

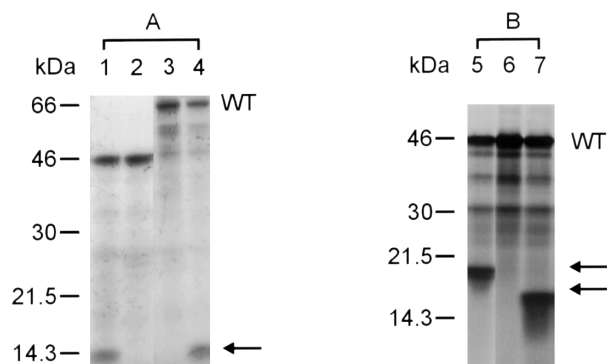


Figure 1 Representative PTT analysis for APC segment 1A (codons 1-379) (lanes 1, 2, and 5-7) and APC segment 1 (codons 1-811) (lanes 3 and 4). The size of the protein marker is shown. The single arrow in the left-hand panel indicates truncated mutant protein. Lanes 2, 3, and 6, Non-FAP controls. Lane 1, Kindred 1. Lane 4, Kindred 2. Lane 7, Kindred 3. Lane 5, Kindred 4. WT = wild type.

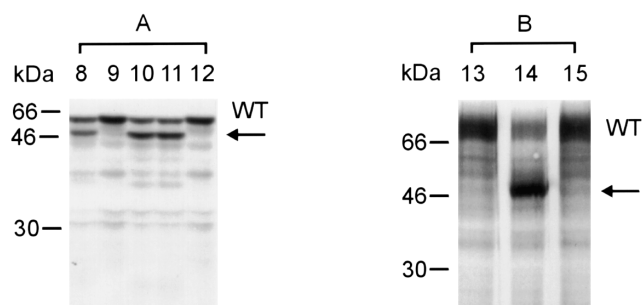


Figure 2 Representative PTT analysis for *APC* segment 1A (codons 1–379) (lanes 8–12) and *APC* segment 4 (codons 1555–2256) (lanes 13–15). The size of the protein marker is shown. The single arrow in the left-hand panel indicates truncated mutant protein. Lanes 9, 12, 13, and 15, Non-FAP controls. Lane 8, Kindred 5. Lanes 10 and 11, Kindred 6. Lane 14, Kindred 7. WT = wild type.

1–580), and the mean age at CRC diagnosis was 58.1 years (range 29–76). In the group with mutations in *APC* exon 9, although both the mean age at polyposis diagnosis (39.7 years [range 12–64]) and the mean age at CRC diagnosis (54.2 years [range 42–67]) were comparable to those in the first group, the average number of polyps (22 [range 1–150]) was less (table 3). In the AAPC kindred with 3'-end *APC* mutations, mean age at polyposis diagnosis was 49 years (range 41–65), and mean number of colonic polyps was 14 (range 1–36); thus far, no CRC has been diagnosed in this family (table 4).

Discussion

In this study, we have shown that AAPC is caused by mutations in three distinct regions of the *APC* gene—that is, at the 5' end, in the region spanning exons 4 and 5; in exon 9; and at the extreme 3' end. Phenotypic expression in these three groups of kindreds is variable but is definitely milder than that in classical FAP, indicating modified clinical-management protocols for affected AAPC patients and their at-risk relatives. Our data demonstrate that AAPC families carrying 5' germ-line *APC* mutations exhibit greater variability with regard to the frequency and age at onset of polyposis, such that the phenotypes of some affected patients are quite similar to that of classical FAP. Furthermore, duodenal adenomas occur with an increased severity in these families.

We have identified four AAPC kindreds with *APC* mutations located proximal to codon 168. Of these four kindreds, three carry the same *APC* mutation, and the fourth carries a truncating mutation within *APC* exon 4. To date, 13 AAPC families with germ-line *APC* mutations proximal to codon 168 have been described (Spirio et al. 1993; Olschwang et al. 1993a; Giardiello et

al. 1997). 5' *APC* mutations predict the synthesis of proteins shorter than those predicted from the *APC* mutations commonly associated with classical FAP (Horii et al. 1993; Samowitz et al. 1995). Therefore, different properties of the two types of mutant *APC* proteins may be expected (Fodde and Meera Khan 1995). Short *APC* peptides may be unable to compete with other peptide complexes, because of a lack of essential sequence motifs required for such protein-protein interaction. Alternatively, such alleles are likely to be unstable and may result in null alleles.

Two AAPC kindreds carry *APC* mutations in exon 9. This exon is usually alternatively spliced. Germ-line mutations in *APC* exons 6 and 9A, including those causing a splice-site defect, have been reported in AAPC families (Cama et al. 1994; Smith-Ravin et al. 1994; Varesco et al. 1994; van der Luijt et al. 1995). Mutations occurring in alternatively spliced regions of *APC* would support the haploinsufficiency model, in which an unstable truncated mutant protein with a reduced amount of normal *APC* induces a less severe phenotype (Fodde and Meera Khan 1995; Yang et al. 1997). Furthermore, the splice-site mutations of such *APC* exons are thought to provoke inefficient exon skipping, which may be responsible for the delay in the development of colonic polyposis (Varesco et al. 1994). In the present study, although the mutations in exon 9 were located outside the alternatively spliced region, the phenotypes of these two kindreds are typical of AAPC (table 3). Average age at diagnosis of polyposis is 40 years, and usually there are <100 right-sided colonic adenomas, with rectal-polyp sparing; gastric/duodenal manifestations were not observed in these families.

We found one kindred with a germ-line *APC* mutation at codon 2047, which appears to be one of the most 3' mutations reported in AAPC. In this kindred, the colonic phenotype is very mild, with <40 polyps, no CRC, and rectal-polyp sparing (table 4). Previous studies have shown that germ-line mutations at the distal 3' end of *APC* correlate with the AAPC phenotype (Scott et al. 1995; Friedl et al. 1996; van der Luijt et al. 1996; Gardner et al. 1997). Such mutant *APC* transcripts are likely to be proficient in β -catenin binding, thereby mediating signals that are important for cell adhesion and turnover (Friedl et al. 1996). Alternatively, 3'-mutant *APC* proteins are likely to form stable homodimers and to retain partial function, as in the case of “leaky” mutant alleles (Spirio et al. 1993). Kindreds with desmoid tumors but with almost no colonic manifestations have been reported recently (Eccles et al. 1996; Scott et al. 1996). These families are noteworthy for having *APC* mutations in the 3' region of the gene. This variant of FAP has been termed “hereditary desmoid disease” and previously had been classified as “familial infiltrative fibromatosis” (MIM 135290). In these kindreds, CRC oc-

Table 2

Clinical Data on Kindreds 1–4

Kindred and Subject (Sex)	Age at Diagnosis (Age at Death) [years]	CRC Status (Location)	No. (Location) of Adenomas	Surgery	Extracolonic Manifestations	Postsurgical Follow-up
1:						
II-1 (F)	59	Absent (...)	Multiple (both sides of colon [more on right side])	Ileo-rectal anastomosis	Not reported	...
III-1 (M)	55	Present (right side [two])	...	Right-side colectomy	Not reported	...
III-3 (F)	64	Absent (...)	Multiple (both sides of colon [approximately equal amounts])	Proctocolectomy with end ileostomy	Not reported	...
III-5 (M)	48 (57)	Absent (...)	Multiple (both sides of colon [more on right side])	Ileo-rectal anastomosis	Not reported	Rectum clear (4 years)
III-7 (F)	43	Absent (...)	150 (both sides of colon [approximately equal amounts])	Ileo-rectal anastomosis	Ampullectomy	Rectum clear (20 years)
III-8 (F)	41	Absent (...)	384 (both sides of colon [approximately equal amounts])	Ileo-rectal anastomosis	Not reported	...
IV-2 (F)	33	Absent (...)	25 (both sides of colon [more on right side])	Ileo-rectal anastomosis	Not reported	...
IV-5 (M)	42	Absent (...)	5 (both sides of colon [more on right side])	Ileo-rectal anastomosis	Not reported	...
IV-26 (F)	40	Absent (...)	20 (both sides of colon [more on right side])	None	UGI normal	...
IV-30 (M)	24	Absent (...)	28 (both sides of colon [more on right side])	Ileo-rectal anastomosis	Not reported	Rectum clear (13 years)
IV-32 (M)	36	Absent (...)	100 (both sides of colon [approximately equal amounts])	Ileo-rectal anastomosis	Not reported	...
V-28 (F)	19	Absent (...)	41 (both sides of colon [approximately equal amounts])	Ileo-rectal anastomosis	UGI normal	Rectum clear (2 years)
2:						
III-2 (F)	57	Absent (...)	<100 (both sides of colon [approximately equal amounts])	Ileo-rectal anastomosis	UGI normal	...
III-6 (M)	59	Present (left side of colon)	Multiple (left side of colon)	Ileo-rectal anastomosis	Not reported	...
III-12 (M)	67 (83)	Present (rectum)	<100 (both sides of colon [approximately equal amounts])	Proctocolectomy with end ileostomy	Not reported	...
III-15 (F)	68 (72)	Present (right side of colon, rectum)	<100 (both sides of colon [approximately equal amounts])	Ileal pouch–anal anastomosis	Not reported	Local cancer recurrence
IV-1 (F)	41	Absent (...)	Multiple (both sides of colon [approximately equal amounts])	Ileo-rectal anastomosis	Not reported	...
IV-2 (M)	39 (42)	Present (right side of colon)	>500 (both sides of colon [approximately equal amounts])	Ileal pouch–anal anastomosis	Duodenal cancer	Liver metastases
IV-3 (F)	38	Absent (...)	Multiple (both sides of colon [more on right side])	Ileo-rectal anastomosis	UGI normal	...
IV-4 (M)	37	Absent (...)	<100 (both sides of colon [more on right side])	Ileo-rectal anastomosis	UGI normal	Rectum clear (12 years)
IV-6 (F)	26	Absent (...)	1	Ileo-rectal anastomosis	UGI normal	Rectum clear (4 years)

(continued)

Table 2 (continued)

Kindred and Subject (Sex)	Age at Diagnosis (Age at Death) [years]	CRC Status (Location)	No. (Location) of Adenomas	Surgery	Extracolonic Manifestations	Postsurgical Follow-up
IV-8 (M)	27	Absent (...)	Multiple (both sides of colon [more on right side])	Ileo-rectal anastomosis	Not reported	...
IV-19 (M)	49	Absent (...)	<100 (both sides of colon [approximately equal amounts])	Ileo-rectal anastomosis	Duodenal adenomas	...
IV-23 (F)	37	Absent (...)	<150 (both sides of colon [approximately equal amounts])	Ileo-rectal anastomosis	Not reported	Rectum clear (4 years)
IV-29 (F)	29 (46)	Present (left side of colon)	...	Left-side colectomy	Not reported	...
IV-30 (M)	43	Present (right side of colon)	2 (right side of colon)	Right-side colectomy	Not reported	Retroperitoneal metastases
IV-37 (F)	46	Present (rectum)	Multiple (both sides of colon [approximately equal amounts])	Abdominal perineal resection	Ampullectomy	Right-adrenal tumor
IV-43 (F)	46 (49)	Absent (...)	69 (both sides of colon [more on right side])	Ileo-rectal anastomosis	Not reported	...
IV-45 (M)	50 (53)	Present (right side of colon)	Multiple (both sides of colon [more on right side])	Ileo-rectal anastomosis	Not reported	Liver metastases
IV-47 (M)	44	Present (left side of colon)	Multiple (both sides of colon [approximately equal amounts])	...	UGI normal	Liver metastases
IV-51 (M)	38	Present (right side of colon)	<100 (both sides of colon [approximately equal amounts])	Ileo-rectal anastomosis	Not reported	...
IV-51 (M)	38	Present (left side of colon)	<100 (both sides of colon [more on right side])	Ileo-rectal anastomosis	Dysplastic adenomas of the stomach: partial gastrectomy	...
V-7 (M)	20	Absent (...)	7	None	Not reported	...
V-21 (F)	37	Absent (...)	<100 (both sides of colon [more on right side])	Ileo-rectal anastomosis	Not reported	...
V-25 (M)	29	Absent (...)	<200 (both sides of colon [approximately equal amounts])	Ileo-rectal anastomosis	UGI normal	Rectum clear (2 years)
V-32 (F)	23	Absent (...)	580 (both sides of colon [more on right side])	Ileo-rectal anastomosis	Not reported	...
V-34 (F)	38	Absent (...)	300 (both sides of colon [approximately equal amounts])	Ileo-rectal anastomosis	Not reported	...
V-37 (F)	33	Absent (...)	200 (both sides of colon [more on right side])	Ileo-rectal anastomosis	UGI normal	...
V-40 (F)	28	Absent (...)	<100 (both sides of colon [approximately equal amounts])	Ileo-rectal anastomosis	UGI normal	Rectum clear (1 year)
V-59 (M)	19	Absent (...)	6 (both sides of colon [approximately equal amounts])	None	UGI normal	...
3: I-1 (F)	76 (77)	Present (left side of colon)	Not reported	Left-side colectomy	Not reported	...
II-1 (M)	66 (72)	Present (left side of colon)	Not reported	Left-side colectomy	Not reported	Multiple myeloma

(continued)

Table 2 (continued)

Kindred and Subject (Sex)	Age at Diagnosis (Age at Death) [years]	CRC Status (Location)	No. (Location) of Adenomas	Surgery	Extracolonic Manifestations	Postsurgical Follow-up
3:						
II-2 (F)	71 (71)	Present (right side of colon)	Not reported	Right-side colectomy	Not reported	Liver metastases
II-3 (F)	64	Present (left side of colon)	Not reported	Left-side colectomy	Not reported	...
III-4 (F)	52	Absent (...)	100 (both sides of colon [more on right side])	Ileo-rectal anastomosis	UGI normal	...
III-9 (F)	51/52	Absent (...)	200 (both sides of colon [more on right side])	Ileo-rectal anastomosis	Not reported	...
III-12 (M)	33	Absent (...)	3, right side of colon	Right-side colectomy	Not reported	...
4:						
I-1 (M)	(60)	Present (not reported)	Not reported	Colostomy	Not reported	...
II-1 (M)	35 (69)	Present (left side of colon)	Not reported	Ileal pouch–anal anastomosis	UGI normal	...
II-3 (F)	66	Absent (...)	50 (both sides of colon [more on right side])	Ileo-rectal anastomosis	Duodenal polypectomy	...
II-7 (M)	58	Absent (...)	100 (both sides of colon [approximately equal amounts])	Left-side colectomy	Not reported	6 Polyps, right side of colon
III-2 (M)	37	Absent (...)	40 (both sides of colon [more on right side])	Right-side colectomy	Not reported	Normal colonoscopy
III-10 (M)	30	Absent (...)	1, excised (right side of colon)	...	Not reported	Normal colonoscopy

Table 3**Clinical Data on Kindreds 5 and 6**

Kindred and Subjects (Sex)	Age at Diagnosis (Age at Death) [years]	CRC Status (Location)	No. (Location) of Adenomas	Surgery	Extracolonic Manifestations	Postsurgical Follow-up
5:						
III-2 (M)	60	Present (left side of colon [two])	Not reported	Ileo-rectal anastomosis	Not reported	...
	64 (64)	Present (rectum)	Not reported	Proctocolectomy with end ileostomy	Not reported	Liver metastases
III-3 (M)	50	Present (left side of colon)	Not reported	Not reported	Not reported	...
III-4 (M)	55 (71)	Absent (...)	Multiple (both sides of colon [approximately equal amounts])	Ileo-rectal anastomosis	UGI normal	Lung cancer
III-5 (M)	43	Present (right side of colon)	...	Right-side colectomy	Not reported	...
	58	Absent (...)	21 (left side of colon)	Left-side colectomy	UGI normal	...
III-6 (M)	53	Absent (...)	8 (both sides of colon [more on left side])	Ileo-rectal anastomosis	UGI normal	Rectum clear (26 years)
III-9 (F)	44	Absent (...)	Multiple (both sides of colon [approximately equal amounts])	Ileo-rectal anastomosis	UGI normal	Rectum clear (24 years)
IV-2 (M)	39	Absent (...)	Multiple (both sides of colon [approximately equal amounts])	Ileo-rectal anastomosis	Not reported	Rectum clear (23 years)
IV-9 (M)	41 (47)	Absent (...)	2, right side of colon	Ileo-rectal anastomosis	Not reported	Esophageal cancer
IV-10 (F)	36	Absent (...)	150 (both sides of colon [more on right side])	Ileo-rectal anastomosis	UGI normal	Rectum clear (13 years)
IV-11 (F)	50	Absent (...)
IV-12 (M)	37	Absent (...)	2 (both sides of colon [approximately equal amounts])	...	Not reported	...
IV-17 (F)	27	Absent (...)	20 (both sides of colon [more on right side])	Ileo-rectal anastomosis	UGI normal	Rectum clear (23 years)
IV-18 (M)	16	Absent (...)	Multiple (both sides of colon [approximately equal amounts])	Ileo-rectal anastomosis	UGI normal	Rectum clear (24 years)
IV-20 (M)	41	Absent (...)	2 (left side of colon)	...	Not reported	...
V-1 (M)	36	Absent (...)	28 (both sides of colon [more on right side])	Ileo-rectal anastomosis	Not reported	Rectum clear (1 year)
V-7 (M)	35	Absent (...)	Multiple (both sides of colon [approximately equal amounts])	Ileo-rectal anastomosis	Not reported	Rectum clear (4 years)
V-10 (F)	12	Absent (...)	1 (left side of colon)	...	Not reported	...
6:						
II-1 (F)	67	Present (left side of colon)	None	Left-side colectomy	Not reported	...
III-1 (F)	42	Present (left side of colon)	27 (both sides of colon [more on right side])	Left-side colectomy	UGI normal	Cervical metastases
III-2 (F)	43	Absent (...)	43, right side of colon	Ileo-rectal anastomosis	Not reported	Rectum clear (1 year)
III-4 (F)	35	Absent (...)	20	Ileo-rectal anastomosis	Not reported	...
IV-1 (M)	25	Absent (...)	10 (both sides of colon [more on right side])	...	Not reported	...
IV-2 (F)	30	Absent (...)	2 (both sides of colon [approximately equal amounts])	...	Not reported	...

Table 4**Clinical Data on Kindred 7**

Subject (Sex)	Age at Diagnosis (years)	CRC Status (Location)	No. (Location) of Adenomas	Surgery	Extracolonic Manifestations	Postsurgical Follow-up
III-7 (F)	65	Absent (...)	36 (both sides of colon [more on right side])	Ileo-rectal anastomosis	UGI adenomas	Rectum clear (1 year)
IV-9 (M)	47	Absent (...)	1 (left side of colon)	...	Not reported	...
IV-12 (F)	43	Absent (...)	2, excised (right side of colon)	...	UGI adenomas	...
IV-13 (M)	41	Absent (...)	20 (both sides of colon [more on right side])	Ileo-rectal anastomosis	Not reported	...

asionally occurs without obvious polyposis. This subset of kindreds could therefore also be considered an AAPC variant with predominance of desmoid tumors. Indeed, in classical FAP, families with desmoid tumors and without CHRPE have been reported to have germ-line mutations in the region of *APC* codons 1445-1578 (Hodgson et al. 1994; Caspari et al. 1995). In our AAPC kindreds, desmoid tumors have not been identified.

A germ-line *APC* mutation was not identified in 4 of 11 kindreds. There are a number of possible explanations: the PTT assay may be unable to detect all mutations in these genes; the mutations may be located in a gene region (e.g., intronic or promoter regions) that was not investigated, or a mutation in a gene(s) other than *APC* may be the underlying defect in these families.

Two phenotypic features of our AAPC families are worth emphasizing: (1) we observed rectal-polyp sparing in patients who underwent total colectomy and ileo-rectal anastomosis, after a mean follow-up period of 11.7 years (range 1-26 years); and (2) we also observed an increased trend toward development of gastric and duodenal adenomas, with the occurrence of duodenal cancer in one case, as reported elsewhere (Soravia et al. 1997b; Zwick et al. 1997). Clinical review of AAPC families with 5'-end *APC* mutations (table 2) demonstrates that, although the number of colorectal adenomas usually is <100, in some cases variability is observed with regard to the number of colonic polyps (i.e., there are >100), with a predominance of polyps located on the right side, as has been described elsewhere (Burt et al. 1995). In families described here, the average age at CRC diagnosis is ~58 years, whereas the average age at polyposis diagnosis is 42 years; these observations are in agreement with other reports (Dobbie et al. 1994; Lynch et al. 1995; Giardiello et al. 1997).

Differences in the *APC* mutation sites alone cannot completely account for intra- and interfamilial variation

in the polyposis phenotypes in these families. Another likely explanation for phenotypic variability is the presence of a modifier gene(s) that may influence the phenotypic expression of the *APC* gene. Such a gene is probably comparatively polymorphic, since phenotypic variability occurs both within and between families. For example, a modifier gene located on chromosome 1p35-36 may influence the severity of duodenal polyposis in FAP (Tomlinson et al. 1996; Dobbie et al. 1997). It is also likely that environmental factors, such as diet, play an important role in AAPC, as has been demonstrated in the mouse models of FAP (Hioki et al. 1997).

The use of molecular-genetic testing has been suggested as an aid in decision making with respect to the type of surgical procedure (total colectomy vs. restorative proctocolectomy) based on the risk of rectal cancer in FAP (Vasen et al. 1996). This suggestion has been challenged by others (Gareth et al. 1997), because few relevant clinical data had been given to support it. The lifetime risk for development of CRC has not yet been estimated in AAPC. Therefore, clinical decision making with respect to the type of surgical procedure should rely on a combination of factors, including age at AAPC diagnosis, number of adenomas (>20), location of polyps (right-side colon), frequency of polyp recurrence, and polyp morphology (confluent vs. scattered polyps). A patient's compliance with the clinical-surveillance regimen should also be taken into account. Finally, this information needs to be correlated with the molecular diagnosis of AAPC in affected and/or presymptomatic individuals of such kindreds.

In view of our experience, the following information seems relevant for the clinical management of AAPC kindreds: (1) predictive genetic testing can be offered to presymptomatic relatives in AAPC families with a known germ-line mutation; (2) colonoscopy, as opposed to sigmoidoscopy, should be advised for endoscopic sur-

veillance, because of the right-side location of colorectal adenomas; (3) UGI endoscopic surveillance is warranted in an attempt to detect premalignant gastric or duodenal tumors; and (4) individuals affected with AAPC may require total colectomy with ileo-rectal anastomosis only when prophylactic colectomy is advised. Finally, the rare occurrence of rectal polyps in AAPC is noteworthy; however, further clinical studies with longer follow-up are needed in order to prove that the risk of rectal cancer is lower in AAPC than in classical FAP (Nugent and Phillips 1992).

Acknowledgments

We thank Mrs. Helena Rossiter and Mrs. Julie Precious for technical assistance in the preparation of the manuscript. We thank Dr. T. Hiruki for reviewing the histologic sections of the resected colon specimen. We acknowledge FAP patients who participated in this study. C.S. is the recipient of a Postdoctoral Research Fellowship from the Geneva University Hospital, Geneva.

Electronic-Database Information

Accession numbers and URLs for data in this article are as follows:

Online Mendelian inheritance in man (OMIM), <http://www.ncbi.nlm.nih.gov/Omim> (for hereditary desmoid disease, or familial infiltrative fibromatosis [MIM 135290])

References

- Bérout C, Soussi T (1996) *APC* gene: database of germline and somatic mutations in human tumors and cell lines. *Nucleic Acids Res* 24:121–124
- Burt R, Kuwada S, Kerber R, Slattery M, DiSario J, White R, Leppert M (1995) The predominance of proximal colonic neoplasms in attenuated adenomatous polyposis coli. *Gastroenterology* 108:A453
- Bussey H (1975) *Familial polyposis coli: families studies, histopathology, differential diagnosis, and results of treatment.* John Hopkins Yale University Press, Baltimore
- Cama A, Esposito DL, Palmirota R, Curia MC, Ranieri A, Ficari F, Valanzano R, et al (1994) A novel mutation at the splice junction of exon 9 of the *APC* gene in familial adenomatous polyposis. *Hum Mutat* 3:305–308
- Caspari R, Friedl W, Mandl M, Möslein G, Kadmon M, Knapp M, Jacobasch KH, et al (1994) Familial adenomatous polyposis: mutation at codon 1309 and early onset of colon cancer. *Lancet* 343:629–632
- Caspari R, Olschwang S, Friedl W, Mandl M, Boisson C, Böker T, Augustin A, et al (1995) Familial adenomatous polyposis: desmoid tumours and lack of ophthalmic lesions (CHRPE) associated with *APC* mutations beyond codon 1444. *Hum Mol Genet* 4:337–340
- De Vries EM, Ricke DO, De Vries TN, Hartmann A, Blaszyk H, Liao D, Soussi T, et al (1996) Database of mutations in the *p53* and *APC* tumor suppressor genes designed to facilitate molecular epidemiological analyses. *Hum Mutat* 7: 202–213
- Dobbie Z, Heinimann K, Bishop D, Müller H, Scott R (1997) Identification of a modifier gene locus on chromosome 1p35-36 in familial adenomatous polyposis. *Hum Genet* 99: 653–657
- Dobbie Z, Spycher M, Hürlimann R, Ammann R, Ammann T, Roth J, Müller A, et al (1994) Mutational analysis of the first 14 exons of the adenomatous polyposis coli (*APC*) gene. *Eur J Cancer* 30:1709–1713
- Eccles DM, van der Luijt R, Breukel C, Bullman H, Bunyan D, Fisher A, Barber J, et al (1996) Hereditary desmoid disease due to a frameshift mutation at codon 1924 of the *APC* gene. *Am J Hum Genet* 59:1193–1201
- Fodde R, Meera Khan P (1995) Genotype-phenotype correlations at the adenomatous polyposis coli (*APC*) gene. *Crit Rev Oncogenesis* 6:291–303
- Friedl W, Meuschel S, Caspari R, Lamberti C, Krieger S, Sengteller M, Propping P (1996) Attenuated familial adenomatous polyposis due to a mutation in the 3' part of the *APC* gene: a clue for understanding the function of the *APC* protein. *Hum Genet* 97:579–584
- Gardner EJ (1951) A genetic and clinical study of intestinal polyposis, a predisposing factor for carcinoma of the colon and rectum. *Am J Hum Genet* 3:167–176
- Gardner EJ, Richards RC (1953) Multiple cutaneous and subcutaneous lesions occurring simultaneously with hereditary polyposis and osteomatosis. *Am J Hum Genet* 5:139–147
- Gardner RJ, Kool D, Edkins E, Walpole I, Macrae F, Nasioulas S, Scott J (1997) The clinical correlates of a 3' truncating mutation (codons 1982–1983) in the adenomatous polyposis coli gene. *Gastroenterology* 113:326–331
- Gareth R, Evans D, Hill J, Dudding T, Burn J, Maher E (1997) Molecular genetic tests in surgical management of familial adenomatous polyposis. *Lancet* 350:1777
- Gayther S, Wells D, SenGupta S, Chapman P, Neale K, Tsioupra K, Delhanty J (1994) Regionally clustered *APC* mutations are associated with a severe phenotype and occur at a high frequency in new mutation cases of adenomatous polyposis coli. *Hum Mol Genet* 3:53–56
- Giardiello F, Brensiger J, Luce M, Petersen G, Cayouette M, Krush A, Bacon J, et al (1997) Phenotypic expression of disease in families that have mutations in the 5' region of the adenomatous polyposis coli gene. *Ann Intern Med* 126: 514–519
- Giardiello F, Krush A, Petersen G, Booker S, Kerr M, Tong L, Hamilton S (1994) Phenotypic variability of familial adenomatous polyposis in 11 unrelated families with identical *APC* gene mutation. *Gastroenterology* 106:1542–1547
- Groden J, Gelbert L, Thliveris A, Nelson L, Robertson M, Joslyn G, Samowitz W, et al (1993) Mutational analysis of patients with adenomatous polyposis: identical inactivating mutations in unrelated individuals. *Am J Hum Genet* 52: 263–272
- Groden J, Thliveris A, Samowitz W, Carlson M, Gelbert L, Albertsen H, Joslyn G, et al (1991) Identification and characterization of the familial adenomatous polyposis coli gene. *Cell* 66:589–600
- Hioki K, Shivapurkar N, Oshima H, Alabaster O, Oshima M,

- Taketo M (1997) Suppression of intestinal polyp development by low-fat and high-fiber diet in *Apc* Δ 716 knockout mice. *Carcinogenesis* 18:1863-1865
- Hodgson SV, Bishop DT, Jay B (1994) Genetic heterogeneity of congenital hypertrophy of the retinal pigment epithelium (CHRPE) in families with familial adenomatous polyposis. *J Med Genet* 31:55-58
- Horii A, Nakatsuru S, Ichii S, Nagase H, Nakamura Y (1993) Multiple forms of the *APC* gene transcripts and their tissue-specific expression. *Hum Mol Genet* 2:283-287
- Hülsken J, Birchmeier W, Behrens J (1994) E-cadherin and APC compete for the interaction with β -catenin and the cytoskeleton. *J Cell Biol* 127:2061-2069
- Jass J, Smyrk T, Stewart S, Lane M, Lanspa S, Lynch H (1994) Pathology of hereditary non-polyposis colorectal cancer. *Anticancer Res* 14:1631-1634
- Joslyn G, Richardson DS, White R, Alber T (1993) Dimer formation by an N-terminal coiled-coil in the APC protein. *Proc Natl Acad Sci USA* 90:11109-11113
- Kinzler K, Nilbert M, Su L, Vogelstein B, Bryan T, Levy B, Smith K, et al (1991) Identification of FAP locus genes from chromosome 5q21. *Science* 253:661-665
- Korinek V, Barker N, Morin P, van Wichen D, de Weger R, Kinzler K, Vogelstein B, et al (1997) Constitutive transcriptional activation by a β -catenin-Tcf complex in APC $-/-$ colon carcinoma. *Science* 275:1784-1787
- Leppert M, Burt R, Hughes J, Samowitz W, Nakamura Y, Woodward S, Gardner E, et al (1990) Genetic analysis of an inherited predisposition to colon cancer in a family with a variable number of adenomatous polyps. *N Engl J Med* 322:904-908
- Lynch HT, Smyrk T, Lanspa S, Marcus JN, Driegler M, Lynch JF, Appelman HD (1988) Flat adenomas in a colon cancer-prone kindred. *J Natl Cancer Inst* 80:278-282
- Lynch HT, Smyrk T, McGinn T, Lanspa S, Cavaliere J, Lynch J, Slominski-Castor S, et al (1995) Attenuated familial adenomatous polyposis (AFAP): a phenotypically and genotypically distinctive variant of FAP. *Cancer* 76:2427-2433
- Morin P, Sparks A, Korinek V, Barker N, Clevers H, Vogelstein B, Kinzler K (1997) Activation of β -catenin-Tcf signaling in colon cancer by mutations in β -catenin or APC. *Science* 275:1787-1790
- Morin P, Vogelstein B, Kinzler K (1996) Apoptosis and APC in colorectal tumorigenesis. *Proc Natl Acad Sci USA* 93:7950-7954
- Nagase H, Miyoshi Y, Horii A, Aoki T, Petersen GM, Vogelstein B, Maher E, et al (1992a) Screening for germ-line mutations in familial adenomatous polyposis patients: 61 new patients and a summary of 150 unrelated patients. *Hum Mutat* 1:467-473
- Nagase H, Miyoshi Y, Horii A, Ogawa M, Utsunomiya J, Baba S, Sasazuki T, et al (1992b) Correlation between the location of germ-line mutations in the *APC* gene and the number of colorectal polyps in familial adenomatous polyposis patients. *Cancer Res* 52:4055-4057
- Nugent K, Phillips R (1992) Rectal cancer risk in older patients with familial adenomatous polyposis and an ileorectal anastomosis: a cause for concern. *Br J Surg* 79:1204-1206
- Olschwang S, Laurent-Puig P, Groden J, White R, Thomas G (1993a) Germ-line mutations in the first 14 exons of the adenomatous polyposis coli (APC) gene. *Am J Hum Genet* 52:273-279
- Olschwang S, Tiret A, Laurent-Puig P, Muleris M, Parc R, Thomas G (1993b) Restriction of ocular fundus lesions to a specific subgroup of *APC* mutations in adenomatous polyposis coli patients. *Cell* 75:959-968
- Peifer M (1996) Regulating cell proliferation: as easy as APC. *Science* 272:974-975
- Polakis P (1997) The adenomatous polyposis coli (APC) tumor suppressor. *Biochim Biophys Acta* 1332:F127-F147
- Powell SM, Petersen GM, Krush AJ, Booker S, Jen J, Giardiello FM, Hamilton SO, et al (1993) Molecular diagnosis of familial adenomatous polyposis. *N Engl J Med* 329:1982-1987
- Rubinfeld B, Albert I, Porphyria E, Fill C, Manumits S, Polakis P (1996) Binding of GSK3 β to the APC- β -catenin complex and regulation of complex assembly. *Science* 272:1023-1026
- Samowitz WS, Thliveris A, Spirio LN, White R (1995) Alternatively spliced adenomatous polyposis coli (APC) gene transcripts that delete exons mutated in attenuated APC. *Cancer Res* 55:3732-3734
- Sanger F, Nicklen S, Coulson A (1977) DNA sequencing with chain-terminating inhibitors. *Proc Natl Acad Sci USA* 74:5463-5467
- Scott R, Froggatt N, Trembath R, Evans D, Hodgson S, Maher E (1996) Familial infiltrative fibromatosis (desmoid tumours) (MIM 135290) caused by a recurrent 3' *APC* gene mutation. *Hum Mol Genet* 5:1921-1924
- Scott R, van der Luijt R, Spycher M, Mary J, Müller A, Hoppler T, Haner M, et al (1995) Novel germline *APC* gene mutation in a large familial adenomatous polyposis kindred displaying variable phenotypes. *Gut* 36:731-736
- Smith-Ravin J, Pack K, Hodgson S, Tay S, Phillips R, Bodmer W (1994) *APC* mutation associated with late onset of familial adenomatous polyposis. *J Med Genet* 31:888-890
- Soravia C, Bapat B, Cohen Z (1997a) Familial adenomatous polyposis (FAP) and hereditary nonpolyposis colorectal cancer (HNPCC): a review of clinical, genetic and therapeutic aspects. *Schweiz Med Wochenschr* 127:682-690
- Soravia C, Berk T, Haber G, Cohen Z, Gallinger S (1997b) Management of advanced duodenal polyposis in familial adenomatous polyposis. *J Gastrointest Surg* 1:474-478
- Spirio L, Olschwang S, Groden J, Roberston M, Samowitz W, Joslyn G, Gelbert L, et al (1993) Alleles of the *APC* gene: an attenuated form of familial polyposis. *Cell* 75:951-957
- Spirio L, Otterud B, Stauffer D, Lynch H, Lynch P, Watson P, Lanspa S, et al (1992) Linkage of a variant or attenuated form of adenomatous polyposis coli to the adenomatous polyposis coli (APC) locus. *Am J Hum Genet* 51:92-100
- Su L, Vogelstein B, Kinzler KW (1993) Association of the APC tumor suppressor protein with catenins. *Science* 262:1734-1737
- Tomlinson I, Neale K, Talbot I, Spigelman A, Williams C, Phillips R, Bodmer W (1996) A modifying locus for familial adenomatous polyposis may be present on chromosome 1p35-36. *J Med Genet* 33:268-273
- van der Luijt R, Meera Khan P, van Leeuwen C, Tops C, Roest P, den Dunnen J, Fodde R (1994) Rapid detection of translation-terminating mutations at the adenomatous polyposis

- coli (*APC*) gene by direct protein truncation test. *Genomics* 20:1–4
- van der Luijt R, Meera Khan P, Vasen H, Breukel C, Tops C, Scott R, Fodde R (1996) Germline mutations in the 3' part of *APC* exon 15 do not result in truncated proteins and are associated with attenuated adenomatous polyposis coli. *Hum Genet* 98:727–734
- van der Luijt R, Vasen H, Tops C, Breukel C, Fodde R, Meera Khan P (1995) *APC* mutation in the alternatively spliced region of exon 9 associated with late onset familial adenomatous polyposis. *Hum Genet* 96:705–710
- Varesco L, Gismondi V, Presciuttini S, Groden J, Spirio L, Sala P, Rossetti C, et al (1994) Mutation in a splice-donor site of the *APC* gene in a family with polyposis and late age of colonic cancer death. *Hum Genet* 93:281–286
- Vasen H, van der Luijt R, Slors J, Buskens E, de Ruiter P, Baeten C, Schouten W, et al (1996) Molecular genetic tests as a guide to surgical management of familial adenomatous polyposis. *Lancet* 348:433–435
- Yang K, Edelman W, Fan K, Lau K, Kolli V, Fodde R, Meera Khan P, et al (1997) A mouse model of human familial adenomatous polyposis. *J Exp Zool* 277:245–254
- Zwick A, Munir M, Ryan C, Gian J, Burt R, Leppert M, Spirio L, et al (1997) Gastric adenocarcinoma and dysplasia in fundic gland polyps of a patient with attenuated adenomatous polyposis coli. *Gastroenterology* 113:659–663