



Article scientifique

Article

2013

Published version

Open Access

This is the published version of the publication, made available in accordance with the publisher's policy.

The history and historical treatments of deep vein thrombosis

Galanaud, J-P; Laroche, J-P; Righini, Marc Philip

How to cite

GALANAUD, J-P, LAROCHE, J-P, RIGHINI, Marc Philip. The history and historical treatments of deep vein thrombosis. In: Journal of thrombosis and haemostasis, 2013, vol. 11, n° 3, p. 402–411. doi: 10.1111/jth.12127

This publication URL: <https://archive-ouverte.unige.ch/unige:32984>

Publication DOI: [10.1111/jth.12127](https://doi.org/10.1111/jth.12127)

HISTORICAL SKETCH

The history and historical treatments of deep vein thrombosis

J.-P. GALANAUD,* J.-P. LAROCHE* and M. RIGHINI†

**Department of Internal Medicine, Montpellier University Hospital, Montpellier, France; and †Division of Angiology and Hemostasis, Geneva University Hospital and faculty of Medicine, Geneva, Switzerland*

To cite this article: Galanaud J-P, Laroche J-P, Righini M. The history and historical treatments of deep vein thrombosis. *J Thromb Haemost* 2013; 11: 402–11.

Summary. Deep vein thrombosis (DVT) is a common disease. However, unlike that of varicose veins, which have been depicted since antiquity in art and literature, its description was more recent in the history of medicine. The first well-documented case of DVT was reported during the Middle Ages: in 1271, Raoul developed a unilateral edema in the ankle, which then extended to the leg. The number of reported DVT cases steadily increased thereafter, particularly in pregnant and postpartum women. During the first half of the 20th century, well before the discovery of anticoagulants, many therapeutic approaches were used, and arose from the pathologic hypotheses that prevailed at their time. Despite the development of anticoagulants, and the fact that they were thought to dramatically decrease DVT mortality, numerous complementary treatments have also been developed during the last 50 years: they include vena cava clips and surgical thrombectomy, and are intended to decrease mortality or to prevent late complications. Most of these treatments have now been abandoned, or even forgotten. In this review, we recall also the discovery and the use of vitamin K antagonists and heparin, which have constituted the mainstay of treatment for decades. We also bring some perspective to historical aspects of this disease and its treatment, notably regarding elastic compression and early mobilization, but also abandoned and complementary treatments. In these times of change regarding DVT treatment, mainly marked by the arrival of new oral anticoagulants, efforts of physicians through the ages to treat this common disease provide a beautiful example of the history of knowledge.

Keywords: deep vein thrombosis, heparin, history, thrombolysis, vena cava filter, vitamin K antagonist.

Introduction

The recently published 9th American College of Chest Physicians/ISTH guidelines recommend the use in routine practice of various new oral anticoagulant drugs, including dabigatran and rivaroxaban, for the treatment of deep vein thrombosis (DVT) and pulmonary embolism (PE) [1]. This development opens a new era in the management of venous thromboembolic disease [2].

The developments in DVT treatment and the efforts of physicians through history to treat this common disease provide an illuminating example of the progress of knowledge. It is of interest to look back at the history of DVT treatment. Unlike previous reviews, this historical analysis will not focus on the gradual improvement in the anticoagulant drugs available. It aims to present a comprehensive history of the therapeutic management of DVT since the first reported case seven centuries ago, with particular attention to additional and/or abandoned treatments [3–6]. We will not address the treatment of PE, which has its own history and has been reviewed separately, or the history of new oral anticoagulant agents, which is just beginning [7].

From the first case of DVT to the pre-anticoagulant era (1271–1920s)

First cases and treatments of DVT (1271–1700s)

Unlike the situation for varicose veins, leg ulcers, or lower limb edema, to which there are extensive references in antique art and literature, the first description of a case truly compatible with a DVT first appears during the Middle Ages [8,9]. In the manuscript of Guillaume de Saint Pathus entitled ‘La vie et les miracles de Saint Louis’, it is reported that, in 1271, Raoul, a 20-year-old Norman cobbler suffered unilateral pain and swelling of the right calf that subsequently extended up to the thigh (Fig. 1) [9]. Raoul’s surgeon, Henri de Perche, advised him to wait and see. Unfortunately, the patient’s symptoms worsened, and he developed a leg ulcer. He visited St Eloi’s shrine, without any improvement. After additional unsuccessful unspecified treatment attempts, Raoul

Correspondence: Marc Righini, Division of Angiology and Hemostasis, Geneva University Hospital and Geneva Faculty of Medicine, 4, rue Gabrielle-Perret-Gentil, 1211 Geneva 14, Switzerland.
Tel. +41 22 372 92 94; fax: +41 22 372 92 99.
E-mail: Marc.Righini@hcuge.ch



Fig. 1. Raoul, the first case of deep vein thrombosis (1271) [9].

was advised to visit the tomb of King Saint Louis. He spent several days praying to the saint, and then he decided to collect the dust that he found below the stone that covered the tomb, and he applied it directly to the ulcer. The story reports that he was miraculously healed after this direct application, and was still alive 11 years later. Thus, this first reported case of effective treatment of DVT might not be the most reproducible. In antiquity, neither famous Greek physicians such as Hippocrates and Oribasius, nor Roman physicians such as Galen or Caelius Aurelianus, reported a case suggesting a diagnosis of DVT; this is also true of the art of ancient Egypt, Persia, and South America. Nevertheless, it is likely that this disease is as old as humankind, and it may have affected famous historical figures: on the basis of writings from the New Testament, Brenner surmised that Jesus Christ himself may have suffered from a PE, but this hypothesis is debated [10–12]. The oriental scientist Avicenna (980–1037) warned against the risk of ‘particle migration’ in cases of vein surgery, consistent with embolization of a DVT, but provided no formal description [13,14]. Thus, although venous thrombosis is a frequent disease, it appears that no cases clearly compatible with the diagnosis of DVT were reported before the description of the case of Raoul.

After this first unquestionable description by Guillaume de Saint Pathus, the number of reported cases of DVT increased rapidly, and the first pathologic hypotheses arose, leading to the first treatment attempts. During the Renaissance, physicians hypothesized that pregnancy-related DVT, which was the leading, or even only, cause

of reported DVT at that time, was the consequence of retention of ‘evil humors’ [15]. It was also thought that postpartum DVT was caused by retention of unconsumed milk in the legs (‘milk leg’). Thus, in the late 1700s, breast-feeding was encouraged to prevent DVT [16–18]. Of course, the most frequent and popular method among physicians to discharge evil humors during the 17th century was bloodletting, as immortalized in Moliere’s theatre play ‘The Imaginary Invalid (1673)’ [19]. This technique was used to treat DVT and many other diseases until the end of the 19th century [20,21].

First pathologic evidence-based treatment of DVT (1784 to early 1920s)

From the 17th century, the humoral theory, which was previously used to explain DVT pathophysiology, was gradually abandoned. In 1676, Wiseman suggested that DVT was the consequence of an alteration of blood, and then, in 1793, Hunter hypothesized that it was an occlusion of the vein by blood clots [15]. In 1784, well before Virchow demonstrated the relationship between DVT and fatal PE (1856), Hunter had performed venous ligations above thromboses, to prevent extension of clots [22,23]. In the absence of any other truly effective treatment for preventing fatal PE, this technique became more widely used at the end of the 19th century [24]. It was assumed to be of ‘immense value in reducing the incidence of PE’ [25]. The ligation could be performed at the femoral, common femoral, iliac and inferior vena cava (IVC) levels in cases of proximal thromboses, and more rarely in cases

of distal thromboses, although this latter therapeutic intervention remained controversial [25,26]. This surgical treatment was still widely used until the mid-20th century in association with, or instead of, anticoagulants [7,27]. For fear of thrombus migration, strict bed rest was prescribed, and constituted, at least from the end of the 19th century, the cornerstone of DVT treatment. Thus, in cases of DVT, the patient's lower limbs were set in iron splints to prevent any movement (Fig. 2A) [28–30]. Special, reclining, orthopedic beds were also used to favor venous return (Fig. 2B) [28].

However, during the 19th century, the most commonly accepted underlying mechanism for DVT was the inflammation of the vein wall provoked by and/or provoking an infectious phenomenon [31]. This was consistent with the observation that DVT is, in many cases, associated with fever, and frequently occurred postpartum, after – septic – surgical procedures, or during bed rest for an infectious disease. Consequently, the treatments prescribed involved anti-inflammatory medication and the prevention and treatment of infection [20,29]. Bloodletting, sometimes via application of leeches, which was popular in these times, was thought to be one of the most effective methods to relieve lower limb congestion and to treat inflammation [20,32]. Apart from bloodletting, other therapeutic options consisted of: (i) cupping, purging, applying ice or prescribing cold baths or blisters to treat inflammation; and (ii) preventing and treating infections with general antiseptic agents such as zinc chloride, or with antiseptic agents or drugs targeting specific diseases, such as quinquona (*Cinchona officinalis*, quinine) for malaria-related DVT, mercury for syphilis-related DVT, or autumn crocus (*Colchicum autumnale*, colchicine) for gout-related DVT [20,29,33]. These therapeutic attitudes, based on the theory of inflammation and infection, started to become obsolete in the early 1900s.

Overall, prior to the 1930s, before the introduction of anticoagulants, the most common treatment for DVT

mainly relied on: (i) bed rest to fix the thrombus in place; (ii) elevation of the extremity involved to favor venous return; and (iii) application of heat with warm compresses to reduce vasospasm and to increase collateral circulation [22,25,34,35]. Because major risk factors for DVT had already been identified, most currently used thromboprophylactic measures were already known and applied in hospitalized cases. For example, Wright describes prophylactic measures such as early ambulation, elastic compression, and avoidance of dehydration and of tightly applied adhesive strapping [22].

From the discovery to the development of anticoagulants (1920s–1950)

By the middle of the 19th century, the major pathologic mechanisms of venous thrombosis had been discovered. They were first summarized in the famous Virchow's triad (1856), theorized by Andral in 1831 and which Virchow probably never described [36]. However, it was only towards the 1920s that a consensus appeared regarding the three factors contributing to thrombosis: stasis, vessel wall alteration, and hypercoagulability. During this period, a number of therapeutic breakthroughs, most of them discovered by accident, revolutionized DVT treatment.

First anticoagulants

Heparin The first isolated anticoagulant was hirudin, obtained in 1884 by Haycraft [32]. It was extracted from the saliva of leeches. However, it could not be used as a potent anticoagulant agent until its production by genetic engineering in 1986. Thus, the first anticoagulant that could be effectively used for the treatment of DVT was heparin. It was discovered in 1916 by McLean, at that time a medical student, while he was studying the procoagulant properties of crude ether and alcohol

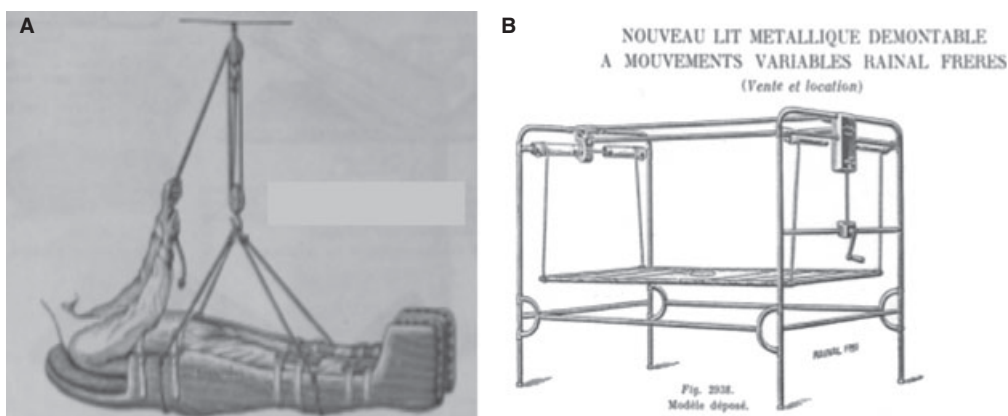


Fig. 2. Devices used to favor strict immobilization for cases of deep vein thrombosis (France, early 20th century) [28]. (A) Gouttière de Bonnet. (B) Reclining iron bed.

extracts of the brain, liver and heart under the supervision of Howell [37]. Indeed, during World War I, scientists were more interested in the development of procoagulant than of anticoagulant substances [4]. McLean noticed that these extracts, and more particularly heparphosphatide, became anticoagulant agents after long-term exposure to air [37]. In 1918, Howell renamed heparphosphatide, which was a mixture of phospholipids, 'heparin' [3]. Four years later, he discovered true heparin, a water-soluble mucopolysaccharide from dog liver. A dispute over the paternity of the discovery started between the two scientists. However, this dispute might well have been vain, as it emerged later that the anticoagulant isolated years earlier in 1911 by Doyon after peptone shock was, in fact, heparin [3].

In 1933, Charles and Scott succeeded in producing pure crystalline heparin, allowing its use in humans, which began in 1935 [38]. The severity of DVT and the absence of convincing effective treatment were probably the main reasons for the rapid spread of this innovative drug. As was the case for today's modern anticoagulants, the first indication for heparin was thromboprophylaxis in surgical patients: in 1937, Murray and Crafoord published the first series of patients [39,40], and this was followed in the next year by a series of patients treated for acute venous thromboembolism (VTE) [41]. Despite the absence of randomized placebo-controlled trials, the effectiveness of heparin was almost immediately considered to be unquestionable: in Bauer's comparative historical series of patients (1929–1938 vs. 1940–1949), mortality from PE among inpatients with symptomatic DVT dropped from 18% to 0.4% after the introduction of anticoagulants [42]. Therefore, in the early 1940s, heparin was already widely used, when available. The duration of heparin treatment varied between centers, but was usually 7–10 days [34,42]. The introduction of oral vitamin K antagonists (VKAs) for this indication in 1941 allowed treatments to be prolonged [5].

VKAs The story of VKAs begins in the in the prairies of North Dakota and Alberta at the beginning of the 20th century. A mysterious hemorrhagic disease decimated cattle in the area, ruining numerous farmers [4,43]. In 1921, Schoefield, a Canadian veterinary pathologist, showed that the disease was caused by spoiled sweet clover [3]. It could be prevented by withdrawal of the spoiled clover from food, and could be treated by blood transfusion. In 1939, Link and his co-workers provided evidence that coumarin, a non-pathogenic agent, was oxidized to dicoumarol in moldy bay, and they demonstrated that the effects of both dicoumarol and spoiled clover could be reversed by vitamin K [43]. Two years later, dicoumarol was used for the first time to treat DVTs [44]. In 1945, while Link was, as he puts it, 'vegetating in a sanatorium', he read articles on the history of rodent control [43]. The proliferation of

rats was a public health concern; rodent behavior, and particularly their habit of eating small pieces of foodstuff and the presence of tasters among them, made eradication by fast-acting poisons poorly effective. Link decided to test the anticoagulant power of all coumarins that had been synthesized in his laboratory between 1940 and 1944 to develop the optimal rodenticide. Here started the story of warfarin, initially launched in 1948 as the ideal rat poison and considered to be too toxic for human use (Fig. 3) [3]. However, the unsuccessful suicide attempt of a navy inductee with 567 mg of warfarin (absorbed in 5 days) demonstrated that this molecule was not as toxic as initially believed [43]. This opened the way to its commercialization as a therapeutic agent in 1954 [3]. Interestingly, heparin and VKAs never really competed with each other for the treatment of VTE. Physicians quickly realized that the two drugs were complementary: heparin is parenteral and immediately effective, whereas VKAs are taken orally, allowing longer courses of treatment [25]. Thus, only a few years after the first use of VKAs to treat VTE, the classic sequential use of heparin followed by VKAs was already prescribed: in the Jorpes series of 445 cases of DVT managed in Sweden from 1945 to 1948, most patients benefited from this type of therapeutic scheme; at the same time, in the absence of contraindications to anticoagulants (bleeding,



Fig. 3. Warfarin, its discoverer, and its original indication (warfarin, discovered by Link, was initially launched in 1948 as the ideal rodenticide, and was considered to be too toxic for human use) [43].

or renal or hepatic insufficiency), 31 of 37 patients hospitalized for DVT at Cleveland university hospital were prescribed heparin followed by dicoumarol [25,42].

Abandoned treatments

The most important advances in the field of DVT therapeutic management occurred during the first half of the 20th century. However, numerous other therapeutic options, sometimes surprising, were tried during this period and later abandoned because of insufficient efficacy: antibiotics (sulfanilamide, sulfapyradine, and sulfathiazole), application of leeches, X-ray therapy, mecholyl iontophoresis, and anesthesia of the paravertebral lumbar sympathetic system [22]. This last technique, developed by Debaquey in 1939, was used during the 1940s. In Holden's series of 37 patients treated for DVT, eight were treated with paravertebral block in association with venous ligation (6/8) or with anticoagulants (2/8) [25]. The underlying pathophysiologic rationale for the use of lumbar sympathetic block was based on images of venographic series, which suggested that DVT was accompanied by severe vasospasm [22,25]. Another debated issue, which arose around the 1940s, concerned whether or not patients should be mobilized during the acute phase of DVT [22,34]. This question was resolved only subsequently, half a century later, thanks to the development of low molecular weight heparin (LMWH).

The modern era: ambulatory management of DVT and the development of complementary treatments (since 1950)

Unlike the previous period, the last 60 years have been characterized by major progress in the field of diagnostics rather than therapeutic management. This has dramatically modified DVT presentation and management. Indeed, thanks to venography, which, although developed by Berberich and Hirsch in 1923, has been widely used only since the 1970s after the standardization of the procedure, physicians no longer treat clinically suspected DVT but objectively confirmed DVT [5,45]. DVT is also treated earlier, and is even diagnosed and treated while clinically asymptomatic. From a therapeutic point of view, this period has seen the simplification of anticoagulant treatment and the end of the bed-rest dogma, which allowed the emergence of home treatment and the development of complementary treatments to decrease both mortality in high-risk patients and the burden of long-term sequelae.

LMWH, early ambulation, and home treatment of DVT

Before the anticoagulant era, bed rest was usually prescribed for 6 weeks for cases of DVT [34]. This attitude was based on pathophysiologic data. Indeed, during the first 6 weeks, namely the 'acute phase' of DVT, the

thrombus was considered to not be adherent to the vessel wall and therefore at high risk of migration. The duration of bed rest was also based on more practical considerations: as diagnosis of DVT was clinical, only the most symptomatic/proximal cases were recognized, and bed rest was the most effective analgesic available. However, prolonged immobilization was often associated with serious adverse consequences, including ankle or knee ankylosis, and amyotrophy [29,30,46]. To prevent such outcomes, Dagron, in 1905, suggested reducing strict bed rest in a splint to the first 10 days after apyrexia [47]. In the 1930s, a growing number of authors started to raise serious doubts about this management, and pleaded in favor of early ambulation and the use of compression stockings to fix the thrombus in place [22,34]. It is likely that the concomitant spread of the use of heparin may have contributed to the popularity of early ambulation, thanks to its anti-inflammatory/analgesic effect and the associated large decrease in mortality [42]. Since then, bed rest has been shortened, being recommended only during heparin treatment (~ 10 days) or even only as long as the pain lasts [42,48]. However, in the absence of clear evidence of its harmlessness, most physicians remained reluctant to recommend immediate mobilization, for fear of thrombus migration. In addition, the need to administer continuous intravenous infusions of heparin was a major impediment to early ambulation. This explains why bed rest, lasting for 5–7 days, was still included in DVT treatment as late as the beginning of the 1990s [49–52].

The most significant step in the simplification of anticoagulant treatment was the development of LMWH, which, in most cases, does not require monitoring. Those molecules were introduced in Europe at the beginning of the 1980s, and their use was widespread within 10 years [53]. In 1996, Levine demonstrated that LMWH given at home was as safe and effective as unfractionated heparin administered in the hospital to treat proximal DVT [49]. This was confirmed by Boccalon in the Vascular Midi-Pyrenees study, in which home treatment with LMWH was as effective as inpatient treatment with LMWH [54]. In the same year, Partsch's small randomized trial provided evidence that, relative to bed rest, early ambulation with compression stockings improved pain and counteracted swelling without increasing the risk of PE [50]. These studies were rapidly followed by widespread implementation of early ambulation with compression stockings in outpatient settings, which has now become the standard and, indeed, recommended management [1,55]. Thus, DVT became an ambulatory disease. The era of novel anticoagulants could start.

The development of complementary treatments

Medical treatments: compression therapy The use of compression therapy was reported during antiquity: Hippocrates, in his *Corpus Hippocraticum* (450–350 BC),

prescribed compression bandages to treat leg ulcers [56]. In his treatise entitled *Chirurgica Magna*, which remained a standard reference in Europe for almost four centuries, Guy de Chauliac, a French surgeon, recommended treating varicose veins with bandages [57]. It is only from the late 19th century, after observing that superficial vein thromboses disappeared rapidly after application of compression bandages, that Fischer and Lasker, two German phlebologists, started prescribing compression bandages to their patients with DVT [57]. However, the prolonged bed rest imposed on patients with DVT at that time prevented the diffusion of this approach to DVT treatment. Compression bandages started to be more widely used when anticoagulants became available. They were usually prescribed at the end of heparin treatment, once ambulation was authorized [42]. A demonstration of their usefulness in preventing post-thrombotic syndrome (PTS) was provided by Brandjes in 1997 [58].

Surgical and endovascular treatments (Fig. 4) Heparin was the treatment of choice for DVT in the 1950s, but surgery was still used, notably in cases of severe VTE [26]. The surgical procedure was mainly bilateral, femoral or IVC ligation; IVC ligation was associated with a high fatality rate (14%) [24]. To reduce surgery-related adverse outcomes, various devices were proposed from the mid-1950s onwards for temporary or partial interruption of

the IVC: temporary exclusion of the IVC with removable metal or plastic clips; temporary ligation of the IVC with absorbable catgut; and plication or compartmentalization of the IVC with a mechanical stapler, dividing it into multiple small channels [59–66] (Fig. 4).

However, these devices did not provide substantial clinical improvement, and were associated with a rate of IVC thrombosis narrowing of 30% [24]. In 1958, De Weese constructed the first intraluminal ‘harpgrip’ filter, which could block the transit of emboli without significantly disturbing the function or dynamics of the venous system [56]. It showed promising results in preventing PE, but its placement still required major surgery and general anesthesia. This problem was solved with the Mobin–Uddin umbrella (1967, and released for general clinical use in 1970), which could be installed with a simple catheter under local anesthesia [67,68]. In addition to potential migration, one of the major and most frequent complications of this filter was gradual obstruction of the IVC. This was finally partially prevented by coating the device with heparin [67]. In 1981, Greenfield developed the first true percutaneous filter, which did not necessitate any venotomy [69]; this was followed by a rapid increase in the indications for and number of implantations of IVC filters [24]. In 1998, the PREPIC trial showed no clear benefit of additional IVC filters in patients with DVT and without contraindications to anticoagulants, largely

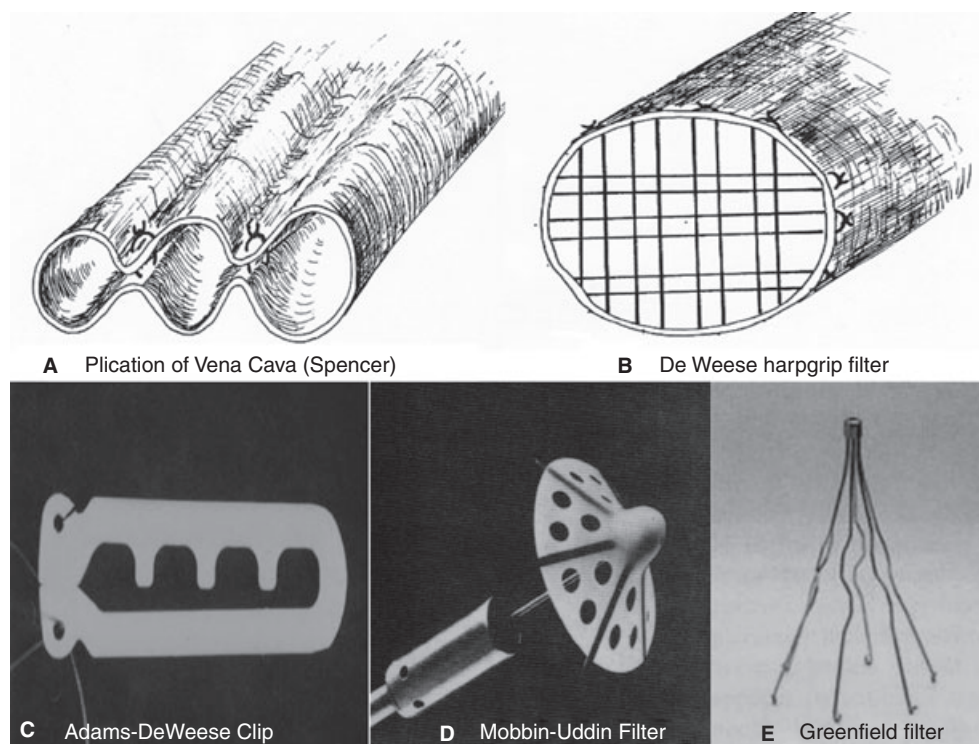


Fig. 4. Various surgical and endovascular treatments of deep vein thrombosis (20th century). (A) Plication of the vena cava; Spencer's technique (1960) [61]. (B) First harpgrip filter (DeWeese), which did not significantly disturb the function or dynamics of the venous system (1958) [56]. (C) Adams–Deweese vena cava clip (1966) [66]. (D) Mobbin–Uddin filter, the first endovascular filter that could be placed without general anesthesia (1967) [68]. (E) Greenfield filter, the first percutaneous filter that did not necessitate venotomy (1981) [69].

because of high late thrombosis rates in the filter group [70]. From that moment, the indications for, and interest in, IVC filters decreased, at least in Europe. Temporary caval filtration in the acute phase of DVT is a possible alternative to permanent IVC filters [24,71]. Indeed, it has the potential to decrease short-term VTE mortality in high-risk DVT patients without increasing the risk of long-term adverse outcomes (VTE recurrence and PTS). The concept was first developed by Eichelster in 1968, with his removable, umbrella-tipped catheter tied to the femoral vein [72]. However, truly retrievable filters (without a catheter and without persisting venous access) became available for clinical use only two decades ago [24]. Therapeutic trials are currently underway.

From thrombectomy to thrombolysis to decrease the PTS burden Other treatments complementary to anticoagulants have been developed, with the aim of preventing long-term morbidity – thanks to early thrombus removal – rather than of lowering mortality. The first venous thrombectomy, without ligation of the upper extremity of the thrombosed venous segment, was performed by L  wen in 1938 [73]. Twenty years later, Mahorner and Fontaine improved the technique, following the surgical procedure with a course of anticoagulant treatment to prevent rethrombosis [74,75]. Thrombi were removed at the iliac level by abdominal pressure and by the passage of tubes through the femoral

venotomy, and at the calf level by massaging or by elevating and compressing the leg [56]. However, thrombectomy was rarely performed, owing to the persistent risk of fatal intraoperative embolism and a high rethrombosis rate [56]. Despite subsequent progress, such as the use of Fogarty balloons (1963) or the creation of a transient arteriovenous fistula (1974) to prevent early rethrombosis, surgical thrombectomy is now not recommended for the routine treatment of proximal DVT [1,73,76]. In current practice, early thrombus removal mainly relies on the use of pharmacologic thrombolytic agents. Recently, a randomized study suggested that thrombolysis was slightly superior to anticoagulants and compression stockings alone in preventing PTS [77]. However, confirmatory studies are still ongoing.

The fibrinolytic properties of human urine (Von Brucke 1861) and then of old blood clots (Dastre 1893) were reported as early as the second half of the 19th century; nevertheless, thrombolytic agents became available only half a century ago [3,78]. In 1947, Christensen succeeded in producing – partially (10%) – purified streptokinase [79]. Although such thrombolytic agents were initially developed to treat vascular thrombosis and, more particularly, myocardial infarction, their toxicity precluded their systemic use [3,78]. Consequently, streptokinase was first prescribed locally, to treat various pneumologic conditions (acute postpneumonic, chronic emphysema, and pharmlologic debriding of infected tissue spaces), and

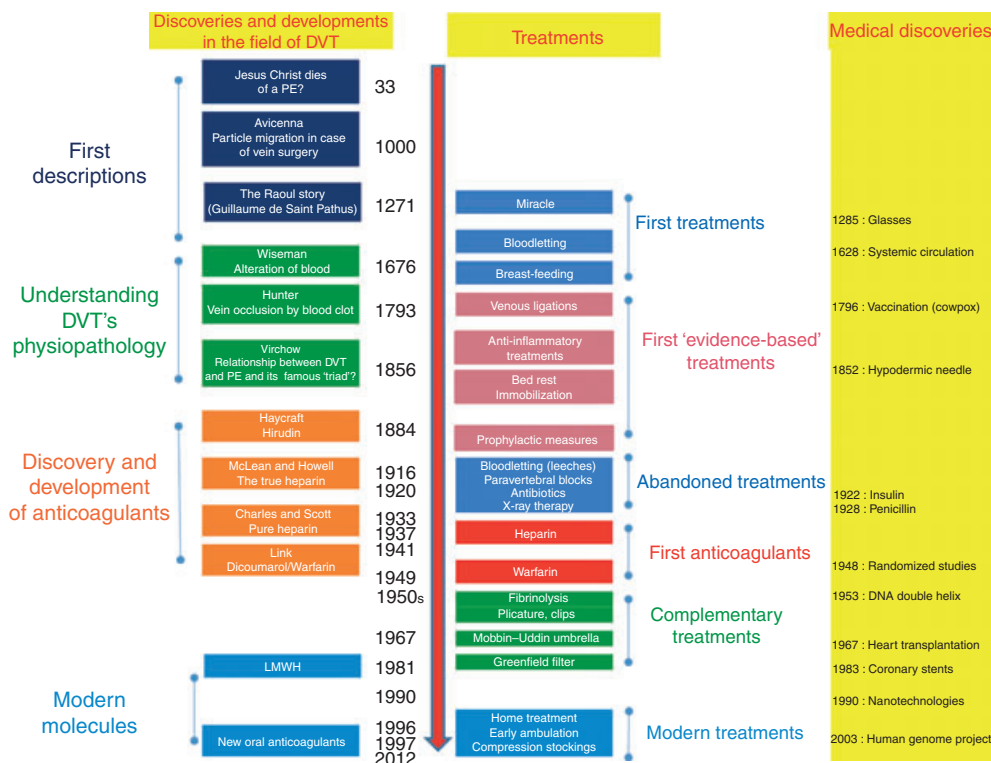


Fig. 5. Brief summary of deep vein thrombosis (DVT) history and treatment. LMWH, low molecular weight heparin; PE, pulmonary embolism.

also to liquefy tracheobronchial secretions and to treat hemothorax, for example [78–82]. From 1953, Clifton started to administer plasmin by intravascular infusion to treat acute thromboses, including isolated DVTs [82]. This treatment was initially given only to volunteers suffering from advanced malignancies. In the same year, Ambrus also reported the use of streptokinase to treat a DVT [83]. This treatment had similarly been prescribed to a multimetastatic patient, who died a few days later from a massive PE; it had been preferred to anticoagulants because they were contraindicated, owing to active bleeding. It will be many years before the appropriate indications (isolated iliofemoral DVT only) and contraindications (five contraindications in Kakkar's study published in 1969 vs. 15 in Enden's 2012 Cavent trial) are rigorously defined, and the optimal approach (catheter-directed vs. systemic administration) to thrombolysis is identified, allowing the selection of the population at highest risk of PTS and lowest risk of bleeding [77,84–86]. Nevertheless, it is likely that the long-term results, despite being promising, will not dramatically modify the routine management of DVT.

Conclusion

The history of DVT treatment started more than 700 years ago, and has involved medical and surgical treatments (Fig. 5). All major breakthroughs have been made during the last 100 years. During the first half of the last century, anticoagulants were discovered, shifting the issue from the fear of death to less severe and less frequent complications: VTE recurrence and major bleeding. The second half of the century was characterized by the simplification of anticoagulant treatment, which allowed ambulatory treatment of the disease and the end of the bed-rest dogma. Complementary treatments were developed, but have not provided sufficiently good results to justify their use in routine practice. The next steps in the improvement of DVT treatment will probably focus on decreasing DVT morbidity, such as PTS, for which therapeutic options are currently limited [87]. New oral anticoagulants might have the potential to decrease this morbidity through safer and longer duration of treatment [88,89]. Another option under development is the use of microbubbles for safe early thrombus removal [90]. Finally, the main treatments for atherothrombosis, antiplatelet agents and statins, could be used to reinforce the DVT therapeutic arsenal in the coming years. Indeed, both drugs have recently been demonstrated to prevent VTE effectively [91,92]. This is a therapeutic confirmation of the suspected pathophysiologic link between VTE and atherothrombotic diseases [93]. The numerous ongoing therapeutic trials assessing various promising potential treatments for DVT are clear evidence of the dynamism of venous thrombosis research.

Disclosure of Conflict of Interests

The authors state that they have no conflict of interest.

References

- 1 Kearon C, Akl EA, Comerota AJ, Prandoni P, Bounameaux H, Goldhaber SZ, Nelson ME, Wells PS, Gould MK, Dentali F, Crowther M, Kahn SR. Antithrombotic therapy for VTE disease. Antithrombotic therapy and prevention of thrombosis, 9th ed: American College of Chest Physicians Evidence-Based Clinical Practice Guidelines. *Chest* 2012; **141**(Suppl. 2): 419–94.
- 2 Buller HR, Shone M, Middeldorp S. Treatment of venous thromboembolism. *J Thromb Haemost* 2005; **3**: 1554–60.
- 3 Mueller RL, Scheidt S. History of drugs for thrombotic disease. Discovery, development, and directions for the future. *Circulation* 1994; **89**: 432–49.
- 4 Wardrop D, Keeling D. The story of the discovery of heparin and warfarin. *Br J Haematol* 2008; **141**: 757–63.
- 5 Deykin D. Antithrombotic therapy in historical perspective. *Am J Cardiol* 1990; **65**: 2C–6C.
- 6 Ansell JE. Oral anticoagulant therapy 50 years later. *Arch Intern Med* 1993; **153**: 586–96.
- 7 Dalen JE. Pulmonary embolism: what have we learned since Virchow?: treatment and prevention. *Chest* 2002; **122**: 1801–17.
- 8 Dexter L. The chair and venous thrombosis. *Trans Am Clin Climatol Assoc* 1973; **84**: 1–15.
- 9 de Saint Pathus G. *La vie et les Miracles de Saint Louis*. Paris: Bibliothèque National de France, 1330–50.
- 10 Brenner B. Did Jesus Christ die of pulmonary embolism? *J Thromb Haemost* 2005; **3**: 2130–1.
- 11 Saliba WR. Did Jesus Christ die of pulmonary embolism? *J Thromb Haemost* 2006; **4**: 891–2.
- 12 Ur Rehman H. Did Jesus Christ die of pulmonary embolism? A rebuttal. *J Thromb Haemost* 2005; **3**: 2131–3.
- 13 Avicenna (Translated by Abdorrahman Sharafkandi). *Avicenna's Canon of Medicine, 1025*, 5th edition. Teheran: Soroush Publications, 2008.
- 14 Bikedli B, Sharif-Kashani B. Venous thromboembolism: a Persian Perspective to Prevention, Diagnosis, and Treatment. North American Thrombosis Forum 2010. <http://www.natfonline.org/media/15133/persianvteperspectiveformat.pdf>. Accessed 20 September 2012.
- 15 Mannucci PM. Venous thrombosis: the history of knowledge. *Pathophysiol Haemost Thromb* 2002; **32**: 209–12.
- 16 Deslandes M. *Traité des Accouchements*. Paris: M Puzos Desaint et Saillant, 1759.
- 17 White CW. *An inquiry into the nature and cause of that swelling in one or both of the lower extremities which sometimes happen to in-lying women together with the propriety of drawing the breasts of those who do and also who do not give suck*. London: Warrington, 1784.
- 18 Rosendaal FR. Causes of venous thrombosis. In: van Beek EJ, Büller HR, Oudkerk M, eds. *Deep Vein Thrombosis and Pulmonary Embolism*. Chichester: John Wiley & Sons, 2009.
- 19 Moliere JB. *Le Malade imaginaire* (1673). http://www.inlibroveritasnet/telecharger/pdf_domaine_public/oeuvre377htm. Accessed 20 September 2012.
- 20 Piorry P. *Traité de Médecine Pratique et de pathologie iatrique ou Médicale*. Paris: Librairie Pourchet, 1842.
- 21 Parapia LA. History of bloodletting by phlebotomy. *Br J Haematol* 2008; **143**: 490–5.
- 22 Wright IS. Thrombophlebitis. *Bull N Y Acad Med* 1941; **17**: 348–72.
- 23 Bagot CN, Ayra R. Virchow and his triad: a question of attribution. *Br J Haematol* 2008; **143**: 180–90.

- 24 Barral F. Vena cava filters: why, when, what and how? *J Cardiovasc Surg* 2008; **49**: 35–49.
- 25 Holden WD. Treatment of deep venous thrombosis with reference to subcutaneous injection of heparin and use of dicumarol. *Arch Surg* 1947; **54**: 183–7.
- 26 Albright HL. Thrombophlebitis, the problem of treatment. *N Engl J Med* 1947; **236**: 928–33.
- 27 Crane C. Deep venous thrombosis and pulmonary embolism; experience with 391 patients treated with heparin and 126 patients treated by venous division, with a review of the literature. *N Engl J Med* 1957; **257**: 147–57.
- 28 Rainal Frères (experts de l'assistance publique). *Catalogue général 1825–1934*. Paris: Bouttin, 1934.
- 29 Amat C. Leçons de Clinique thérapeutique du Professeur Albert Robin: le traitement des phlébites. *Bulletin général de thérapeutique médicale, chirurgicale, obstétricale et pharmaceutique* 1905; **149**: 692–736.
- 30 Vaquez LH. Conduite à tenir dans les cas de phlébite. *Gazette hebdomadaire de médecine et de Chirurgie* 1900; **93**: 556.
- 31 Breschet G. Traité des maladies des artères et des veines de J Hodgson. Traduit de l'anglais et augmenté d'un grand nombre de notes. *Nouveau Journal de Médecine, Pharmacie* 1819; **6**: 279–83.
- 32 Whitaker IS, Izadi D, Oliver DW, Monteath G, Butler PE. Historical article: Hirudo medicinalis: ancient origins of, and trends in the use of medicinal leeches throughout history. *Br J Oral Maxillofac Surg* 2004; **42**: 133–7.
- 33 Dance D. Phlébite générale et phlébite utérine. *Archives générales de Médecine* 1828; **1**: 286–9.
- 34 Bauer G. Thrombosis; early diagnosis and abortive treatment with heparin. *Lancet* 1946; **1**: 447–54.
- 35 Homans J. Thrombophlebitis of the lower extremities. *Ann Surg* 1928; **87**: 641–51.
- 36 Dickinson B. Virchow's triad? *South Med J* 2004; **97**: 915–16.
- 37 McLean J. The discovery of heparin. *Circulation* 1959; **19**: 75–8.
- 38 Charles AF, Scott DA. Studies on heparin: observations on the chemistry of heparin. *Biochem J* 1936; **30**: 1927–33.
- 39 Murray DW, Jaques LB, Perrett TS, Best CH. Heparin and thrombosis of the veins following injury. *Surgery* 1937; **2**: 163–87.
- 40 Crafoord C. Preliminary report on post-operative treatment with heparin as a preventive of thrombosis. *Acta Chir Scand* 1937; **79**: 407–26.
- 41 Murray GD, Best CH. The use of heparin in thrombosis. *Ann Surg* 1938; **108**: 163–77.
- 42 Bauer G. Nine years' experience with heparin in acute venous thrombosis. *Angiology* 1950; **1**: 161–9.
- 43 Link KP. The discovery of dicumarol and its sequels. *Circulation* 1959; **19**: 97–107.
- 44 Prandoni A, Wright I. The anti-coagulants: heparin and the dicoumarin-3,3'-methylene-Bis-(4-hydroxycoumarin). *Bull N Y Acad Med* 1942; **18**: 433–58.
- 45 Meissner MH, Moneta G, Burnand K, Gloviczki P, Lohr JM, Lurie F, Mattos MA, McLafferty RB, Mozes G, Rutherford RB, Padberg F, Sumner DS. The hemodynamics and diagnosis of venous disease. *J Vasc Surg* 2007; **46**: 4S–24S.
- 46 Schwartz A. La semaine du clinicien. Affections inflammatoires: les phlébites. *Paris Médical* 1924; **51**: 445–6.
- 47 Maladies du Cœur et des vaisseaux; le traitement des phlébites par une nouvelle méthode. *Bulletin général de thérapeutique médicale, chirurgicale, obstétricale et pharmaceutique* 1905; **150**: 316–17.
- 48 Marks J, Truscott BM, Withycombe JF. Treatment of venous thrombosis with anticoagulants; review of 1135 cases. *Lancet* 1954; **267**: 787–91.
- 49 Levine M, Gent M, Hirsh J, Leclerc J, Anderson D, Weitz J, Ginsberg J, Turpie AG, Demers C, Kovacs M. A comparison of low-molecular-weight heparin administered primarily at home with unfractionated heparin administered in the hospital for proximal deep-vein thrombosis. *N Engl J Med* 1996; **334**: 677–81.
- 50 Partsch H, Blättler W. Compression and walking versus bed rest in the treatment of proximal deep venous thrombosis with low molecular weight heparin. *J Vasc Surg* 2000; **32**: 861–9.
- 51 Schellong S, Schwarz T, Kropp J, Prescher Y, Beuthien-Baumann B, Daniel WG. Bed rest in deep vein thrombosis and the incidence of scintigraphic pulmonary embolism. *Thromb Haemost* 1999; **82**: 127–9.
- 52 Aschwanden M, Labs KH, Engel H, Schwob A, Jeanneret C, Mueller-Brand J, Jaeger KA. Acute deep vein thrombosis: early mobilization does not increase the frequency of pulmonary embolism. *Thromb Haemost* 2001; **85**: 42–6.
- 53 Hyers TM. Management of venous thromboembolism: past, present, and future. *Arch Intern Med* 2003; **163**: 759–68.
- 54 Boccalon H, Elias A, Chalé JJ, Cadène A, Gabriel S. Clinical outcome and cost of hospital vs home treatment of proximal deep vein thrombosis with a low-molecular-weight heparin: the Vascular Midi-Pyrenees study. *Arch Intern Med* 2000; **160**: 1769–73.
- 55 Blättler W, Gerlach HE. Implementation of outpatient treatment of deep-vein thrombosis in private practices in Germany. *Eur J Vasc Endovasc Surg* 2005; **30**: 319–24.
- 56 DeWeese J. Treatment of venous disease – the innovators. *J Vasc Surg* 1994; **20**: 675–83.
- 57 Hohlbaum G-G. Historique de la compression Médicale. In: Gardon-Mollard C, Ramelet AA, eds. *La compression Médicale*. Paris: Abrégés de Médecine Editions Masson, 2006.
- 58 Brandjes DP, Buller HR, Heijboer H, Huisman MV, de Rijk M, Jagt H, ten Cate JW. Randomised trial of effect of compression stockings in patients with symptomatic proximal-vein thrombosis. *Lancet* 1997; **349**: 759–62.
- 59 Moretz WH, Nasibitt PF, Stevenson GP. Experimental studies on temporary occlusion of the inferior vena cava. *Surgery* 1954; **36**: 384–98.
- 60 Dale WA, Pualwan F, Bauer FM. Ligation of the inferior vena cava with absorbable gut. *Surg Gynecol Obstet* 1956; **102**: 517–30.
- 61 Spencer FC. An experimental evaluation of partitioning of the inferior vena cava to prevent pulmonary embolism. *Surg Forum* 1960; **10**: 680–4.
- 62 Gardner AM, Harse HR. A self-releasing inferior vena caval clip. *Lancet* 1967; **7486**: 368.
- 63 Ravitch MM, Snodgrass E, McEnany T, Rivarola A. A compartmentalization of the vena cava with the mechanical stapler. *Surg Gynecol Obstet* 1966; **122**: 561–4.
- 64 Miles RM, Chapell F, Renner O. A partially occluding vena caval clip for prevention of pulmonary embolism. *Am Surg* 1964; **30**: 40–7.
- 65 Moretz WH, Rhode C, Shephard MH. Prevention of pulmonary emboli by partial occlusion of the inferior vena cava. *Am Surg* 1959; **25**: 617–26.
- 66 Adams JT, DeWeese JA. Partial interruption of the inferior vena cava with a new plastic clip. *Surg Gynecol Obstet* 1966; **123**: 1087–8.
- 67 Cain PG. Comment on 'Treatment of venous disease – the innovators'. *J Vasc Surg* 1995; **22**: 341–3.
- 68 Mobin-Uddin K, Smith PE, Martinez LO, Lombardo CR, Jude JR. A vena caval filter for the prevention of pulmonary embolus. *Surg Forum* 1967; **18**: 209–11.
- 69 Greenfield LJ. Historical reminiscence: origin of the Greenfield filter. *Am Surg* 2010; **76**: 1319–20.
- 70 Decousus H, Leizorovicz A, Parent F, Page Y, Tardy B, Girard P, Laporte S, Faivre R, Charbonnier B, Barral FG, Huet Y, Simonneau G. A clinical trial of vena caval filters in the prevention of pulmonary embolism in patients with proximal deep-vein

- thrombosis. Prevention du Risque d'Embolie Pulmonaire par Interruption Cave Study Group. *N Engl J Med* 1998; **338**: 409–15.
- 71 Kaufman JA. Optional vena cava filters: what, why, and when. *Vascular* 2007; **15**: 304–13.
 - 72 Eichelter P, Schenk W Jr. Prophylaxis of pulmonary embolism. A new experimental approach with initial results. *Arch Surg* 1968; **97**: 348–56.
 - 73 Eklöf B. Charles Rob, Alfred Nobel and Aphrodite: the development of surgery for venous thromboembolism. *Cardiovasc Surg* 1994; **2**: 187–94.
 - 74 Mahorner H, Castelberry JW, Coleman WO. Attempts to restore function in major veins which are the site of massive thrombosis. *Ann Surg* 1957; **146**: 510–22.
 - 75 Fontaine R. Remarks concerning venous thrombosis and its sequelae. *Surgery* 1957; **41**: 6–25.
 - 76 Fogarty TJ, Cranley JJ, Krause RJ, Strasser ES, Hafner CD. A method for extraction of arterial emboli and thrombi. *Surg Gynecol Obstet* 1963; **116**: 241–4.
 - 77 Ender T, Haig Y, Kløw NE, Slagsvold CE, Sandvik L, Ghanima W, Hafsahl G, Holme PA, Holmen LO, Njaastad AM, Sandbæk G, Sandset PM, CaVenT Study Group. Long-term outcome after additional catheter-directed thrombolysis versus standard treatment for acute iliofemoral deep vein thrombosis (the CaVenT study): a randomised controlled trial. *Lancet* 2012; **379**: 31–8.
 - 78 Sherry S. The origin of thrombolytic therapy. *J Am Coll Cardiol* 1989; **14**: 1085–92.
 - 79 Christensen LR. Protamine purification of streptokinase and effect of pH and temperature on reversible inactivation. *J Gen Physiol* 1947; **30**: 465–73.
 - 80 Tillett W, Sherry S, Christensen LR, Johnson A, Hazlehurst G. Streptococcal enzymatic debridement. *Ann Surg* 1949; **131**: 12–22.
 - 81 Tillett WS, Sherry S, Read CT. The use of streptokinase-streptodornase in the treatment of postpneumonic empyema. *J Thorac Surg* 1951; **21**: 275–97.
 - 82 Clifton E. The use of plasmin in humans. *Ann N Y Acad Sci* 1957; **30**: 209–29.
 - 83 Ambrus JL, Ambrus CM, Back N, Sokal JE, Collins GL. Clinical and experimental studies on fibrinolytic enzymes. *Ann N Y Acad Sci* 1957; **68**: 97–136.
 - 84 Marder V. Historical perspective and future direction of thrombolysis research: the re-discovery of plasmin. *J Thromb Haemost* 2011; **9**: 364–73.
 - 85 Kakkar VV, Flanc C, Howe CT, O'Shea M, Flute PT. Treatment of deep vein thrombosis. A trial of heparin, streptokinase, and arvin. *Br Med J* 1969; **1**: 806–10.
 - 86 Schulman S, Granqvist S, Juhlin-Dannfelt A, Lockner D. Long-term sequelae of calf vein thrombosis treated with heparin or low-dose streptokinase. *Acta Med Scand* 1986; **219**: 349–57.
 - 87 Kahn SR. How I treat postthrombotic syndrome. *Blood* 2009; **114**: 4624–31.
 - 88 Prandoni P. Healthcare burden associated with the post-thrombotic syndrome and potential impact of the new oral anticoagulants. *Eur J Haematol* 2012; **88**: 185–94.
 - 89 Baglin T. Prevention of post-thrombotic syndrome: a case for new oral anticoagulant drugs or for heparins? *J Thromb Haemost* 2012; **10**: 1702–3.
 - 90 Birnbaum Y, Luo H, Nagai T, Fishbein MC, Peterson TM, Li S, Kricsfeld D, Porter TR, Siegel RJ. Noninvasive *in vivo* clot dissolution without a thrombolytic drug: recanalization of thrombosed iliofemoral arteries by transcutaneous ultrasound combined with intravenous infusion of microbubbles. *Circulation* 1998; **97**: 130–4.
 - 91 Becattini C, Agnelli G, Schenone A, Eichinger S, Bucherini E, Silingardi M, Bianchi M, Moia M, Ageno W, Vandelli MR, Grandone E, Prandoni P, WARFASA Investigators. Aspirin for preventing the recurrence of venous thromboembolism. *N Engl J Med* 2012; **366**: 1959–67.
 - 92 Glynn RJ, Danielson E, Fonseca FA, Genest J, Gotto AM Jr, Kastelein JJ, Koenig W, Libby P, Lorenzatti AJ, MacFadyen JG, Nordestgaard BG, Shepherd J, Willerson JT, Ridker PM. A randomized trial of rosuvastatin in the prevention of venous thromboembolism. *N Engl J Med* 2009; **360**: 151–61.
 - 93 Prandoni P, Bilora F, Marchiori A, Bernardi E, Petrobelli F, Lensing AW, Prins MH, Girolami A. An association between atherosclerosis and venous thrombosis. *N Engl J Med* 2003; **348**: 1435–41.