



Article scientifique

Article

2016

Published version

Open Access

This is the published version of the publication, made available in accordance with the publisher's policy.

Pigmented villonodular synovitis of the hip

Steinmetz, Sylvain; Rougemont-Pidoux, Anne-Laure; Peter, Robin

How to cite

STEINMETZ, Sylvain, ROUGEMONT-PIDOUX, Anne-Laure, PETER, Robin. Pigmented villonodular synovitis of the hip. In: EFORT Open Reviews, 2016, vol. 1, n° 6, p. 260–266. doi: 10.1302/2058-5241.1.000021

This publication URL: <https://archive-ouverte.unige.ch/unige:98383>

Publication DOI: [10.1302/2058-5241.1.000021](https://doi.org/10.1302/2058-5241.1.000021)

© The author(s). This work is licensed under a Creative Commons Public Domain (CC0)

<https://creativecommons.org/publicdomain/zero/1.0/>



Pigmented villonodular synovitis of the hip

Sylvain Steinmetz
Anne-Laure Rougemont
Robin Peter

- Pigmented villonodular synovitis (PVNS) is a rare disease that can affect any joint, bursa or tendon sheath.
- The hip is less frequently affected than the knee, and hence is less discussed in scientific journals.
- PVNS of the hip mainly occurs in young adults, requiring early diagnosis and adequate treatment to obtain good results.
- There is no consensus on the management of PVNS of the hip in current literature.
- We will discuss the options for surgical intervention in hip PVNS using a literature review of clinical, biological, etiological, histological and radiographic aspects of the disease.

Keywords: pigmented villonodular synovitis; PVNS; hip; hyperplasia

Cite this article: Steinmetz S, Rougemont A-L, Peter R. Pigmented villonodular synovitis of the hip. *EFORT Open Rev* 2016;1:260-266. DOI: 10.1302/2058-5241.1.000021.

Introduction

Pigmented villonodular synovitis (PVNS) is a rare disease that can affect any joint, bursa or tendon sheath. It is characterised by a villous or nodular hyperplasia of the synovium. It was first described in 1852 by Chassaignac,¹ but it is to Jaffe that we owe the name of villonodular synovitis (1941).² It is defined by a proliferation of the synovial membrane which may affect the joints, testicles or tendons.

This lesion belongs to the tenosynovial giant-cell tumours group. Three categories are described: a localised form or nodular tenosynovitis, and two more forms including diffuse-type (extra-articular) giant-cell tumour and PVNS. The diffuse-type tenosynovial giant cell tumour can be either purely extra-articular, located in the soft tissues, or represent the extra-articular component of a PVNS. The histological aspects of these three tumours are relatively similar.

PVNS is rare, affecting 1.8 per million inhabitants.³ In intra-articular forms, the large joints are the most

affected: the knee (70%), hip (15%) and then the ankle, shoulder and elbow. PVNS in the hip mainly occurs between the second and third decade. The youngest reported case was of a seven-year-old,⁴ and the oldest, 78 years.⁵ There is no consensus in the literature regarding gender prevalence. The average time between the onset of the disease and the diagnosis can be lengthy, as has been reported by multiple authors.^{6,7}

We will discuss PVNS by way of a literature review of the clinical, biological, etiological, histological and radiographic aspects of the disease, with emphasis on the possible surgical options in case of hip joint involvement.

There are few articles on PVNS of the hip which provide information and sufficient follow-up in the literature found in PubMed since its first mention in 1852. The series of Della Valle,⁶ Flipo⁷ and Vastel⁸ involved several cases that identified important elements requiring attention, and established the fundamental principles of treatment and management.

Clinical features

Clinical presentation of PVNS is non-specific and its diagnosis therefore requires a high index of suspicion. Pain is its main symptom.⁷ The pain progresses in intensity and duration with the evolution of the disease. Pain may be localised throughout the area of the hip, but the groin is still mentioned most frequently. The involvement is often mono-articular,⁷ but rare cases of multi-joint forms may exist.⁶

Other clinical signs have been described, such as chronic swelling which is usually painful, of intra- or extra-articular origin which can be associated with a limitation of joint mobility, causing joint stiffness.⁷ The functional limitation appears later when the intracapsular space reduces secondarily to the synovial invasion. Tolerance to pain, the slowness of its development, the variation of the symptoms, the difficulty of palpation of the hip and the normal appearance of the radiographs at the early stage of the disease create a non-specific syndrome, which often causes a delay in the diagnosis. The average time between the onset of the disease and the diagnosis is four years.^{6,7}

Based on the three major series, the mean age for the initiation of medical care is 36.5 years.

Biology

Usually the biology is non-specific, without an inflammatory syndrome.⁹ There are no associated coagulation disorders.

Aetiology

The aetiology of PVNS is poorly understood. Several aetiologies have been suggested, such as a trauma or neoplasia, a genetic predisposition or an anomaly of lipid metabolism.

A synovial proliferation due to a chronic inflammation secondary to haemarthrosis, or to chronic trauma was suspected. Experiments were undertaken to demonstrate this theory, including repeated autologous injections of blood into the joints of dogs over several months by Young and Hudacek.¹⁰ The concept of prior trauma is common (53% in Myers' series),³ but exceptional (3% in Flipo's report).⁷

More recently, chromosomal anomalies including trisomy 5 and 7 or monoclonalities were reported in some cases of PVNS.¹¹ Furthermore, recurring translocations involving the colony-stimulating factor-1 (*CSF1*) gene have been described in PVNS, the most frequent being the t(1;2)(p13;q37) translocation, resulting in a *COL6A3-CSF1* fusion transcript. An overexpression of *CSF1* was observed in the neoplastic cells of PVNS, independently of the identification of a translocation t(1;2)(p13;q37) in the tumour. This overexpression is responsible for a recruitment of inflammatory cells, within the tumour, expressing the receptor in *CSF1*.¹² These results open the way for targeted therapies. The hypothesis of a lipid metabolic disorder associated with an anomaly of the local lipid metabolism is a possible aetiology.^{13,14}

Histology

Tenosynovial giant-cell tumours can be divided into two categories, depending on their location (intra- and extra-articular) and their growth mode (diffuse and localised forms). These entities appear to present common pathogenic mechanisms, whilst differing in terms of clinical and biological behaviour. This group of lesions includes a localised form of giant-cell tumour of tendon sheath and PVNS, which is more diffuse and locally destructive.¹⁵

The localised form of giant-cell tumour of the tendon sheath results in a well-defined nodule, including in particular the tenosynovial sheath of the hand. The diffuse form develops more readily in large joints. The extra-articular form of PVNS is rare. Because of their very

similar histological appearances, a differential diagnosis between giant-cell tumour of the tendon sheaths and PVNS can be difficult on a biopsy. Integration with clinical and radiological data is then essential.

PVNS produces mostly infiltrative tumours, comprising different groups of diffuse cells of which the cell density is variable depending on the area. The localised form is well-defined, lobulated and surrounded by a fibrous capsule.

The tumour is composed of layers of round or polygonal mononuclear cells with pale cytoplasm and a nucleus that is sometimes kidney-shaped and notched, considered as representing the true tumour component. They mingle with osteoclast-like multi-nucleated giant cells and with xanthomatous histiocytes or pigments, the latter being more numerous in the localised form than in PVNS (Fig. 1).

Foamy histiocytes tend to form clusters in the periphery of the nodules, and can be associated with cholesterolae clefts. Some tumours present with very few multi-nucleated giant cells, and are thus more difficult to diagnose. In principle, mitotic activity is observed in the mononuclear cell component, but without atypical mitoses. Necrosis is rarely present, and hyalinisation of the stroma is more abundant in the localised form. Upon immunohistochemical examination, the mononuclear cells express clusterin and can be positive for the muscle marker desmin. The smaller mononuclear cells express the macrophage/histiocytic markers CD68 and CD163, as well as CD45. The multi-nucleated cells present an osteoclast-type expression profile, being positive for the CD68, CD45 and the tartrate-resistant acid phosphatase (TRAP) in particular.¹⁵

Imaging features

Radiology is important for diagnosis, treatment planning and monitoring. Radiograph images, CT and MRI are useful to achieve these objectives. Scintigraphy provides no useful information as the binding is diffuse and non-specific.⁷

Plain film radiography remains the primary diagnostic examination. Radiographs are often normal at the early stage of the disease. At an advanced stage, the destructive nature of PVNS results in bone erosions with sharp edges, deficiencies or multiple and dispersed subchondral cysts⁷ (Fig. 2).

We find these osteolytic alterations again in the femoral neck or the cup, more specifically along the axis of the joint capsule or near the fovea.¹⁶ Unlike in osteoarthritis, the lytic changes are not only secondary to a bone invasion of the outside of the weight-bearing area, but also due to intra-articular hyperpressure. The thick capsule that is physiologically present in the hip probably contributes to this invasion because it prevents any expansion of the joint space.

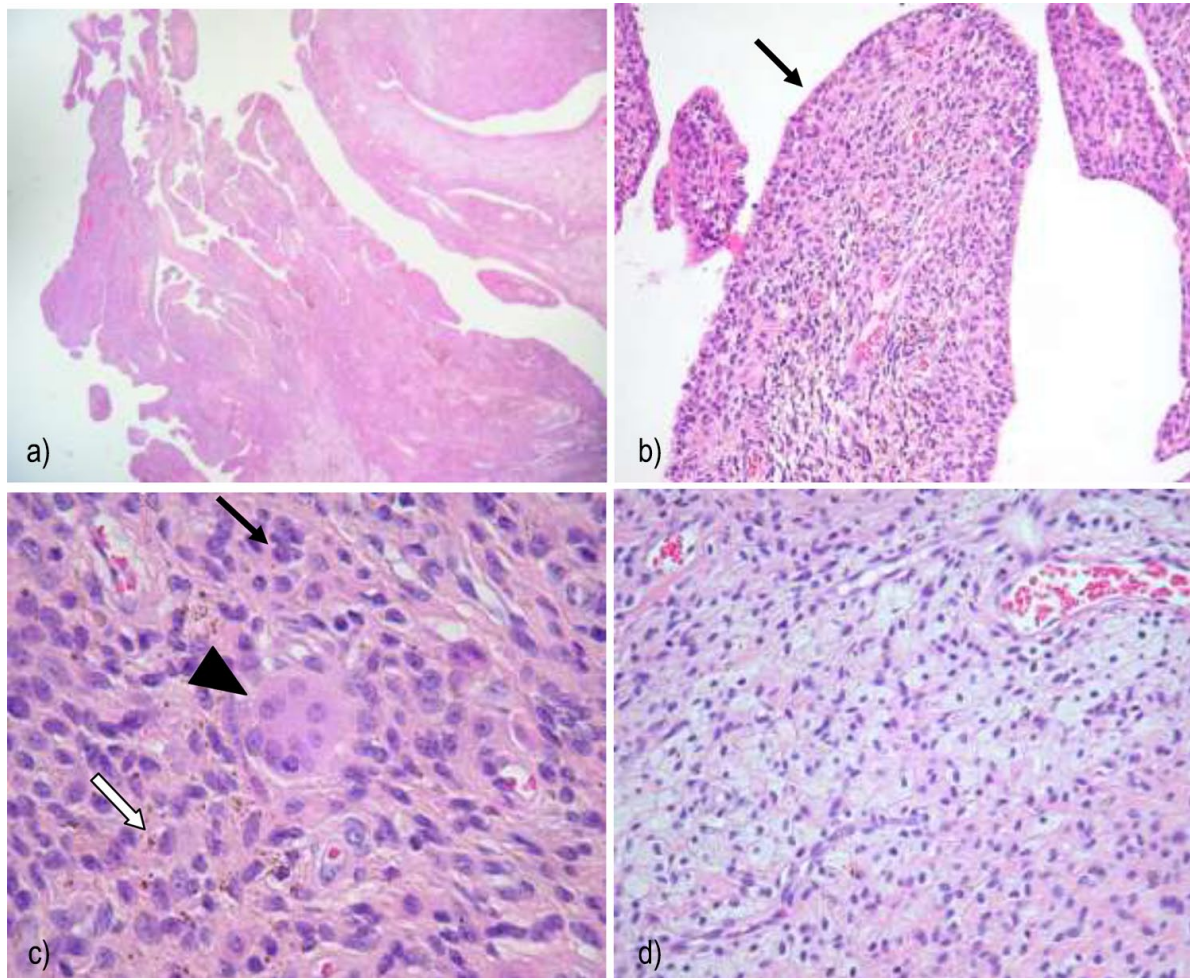


Fig 1 Histology. a) Upon histological evaluation, the synovial villi are elongated and enlarged. b) Synoviocytes line the villi (arrow). c) The tumor is composed of sheets of mononuclear cells (black arrow), intermingled with osteoclast-like multinucleated giant (arrowhead) and siderophages (white arrow). (d) Sheets of xanthoma cells are also seen.

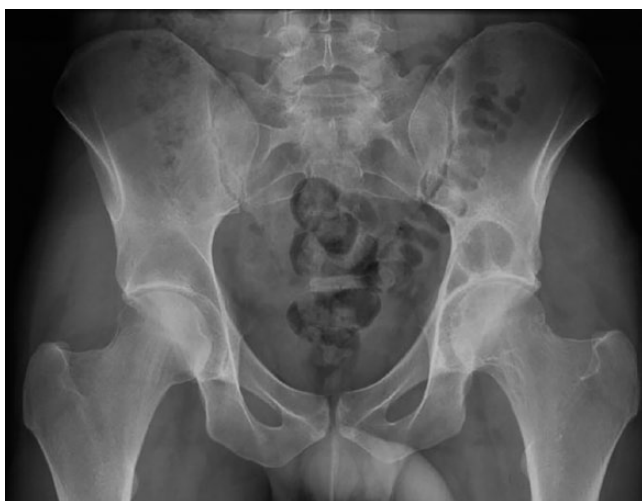

Fig 2 Radiography AP of the hip: at an advanced stage, the destructive nature of PVNS results in multiple and dispersed subchondral cysts.

Two authors have proposed a radiological classification. The first, described in 1980 by Lequesne,¹⁷ defines three stages:

- The initial stage has been described as ‘evocative’ of the disease, including large hip subchondral cysts with or without joint space narrowing.
- The second is named ‘pseudo-coxitis’, with a radiological appearance of localised narrowing of the joint space in the weight bearing segment, with deep ulcerations or erosions of the head and/or of the acetabulum, with possible subchondral cysts outside the area of hyperpressure.
- The third is ‘pseudo-coxarthrosis’, advancing secondarily to a localised narrowing due to expansion of subchondral cysts.

Respectively, these forms represent 62%, 16% and 14% of cases.

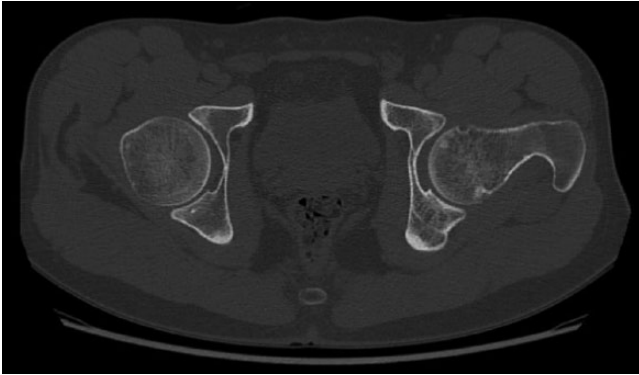


Fig 3 CT of the hip: the small erosions like at the femoral neck.

The second classification was proposed by Gitelis,⁹ also in three stages:

- The first stage is a normal appearance without obvious signs of abnormality.
- The second is a change with lytic lesions but no joint space narrowing.
- The third includes the joint space narrowing associated with lytic lesions.

In Della Valle's article,⁶ we respectively find a proportion of 2% in the first 47% in the second, and 51% in the third group. Rarely, destructive forms leading to complete osteo-articular destruction within a few months can occur.

CT scanning is an additional examination

Allowing clarification of the extension of bone subchondral cysts,^{6,7,17} and visualisation of the small erosions not visible on the radiograph images such as those at the femoral neck¹⁸ (Fig. 3). However, CT remains less efficient in evaluating the synovium and the surrounding soft tissues.

A major advantage of CT is the possibility of a CT-guided synovial puncture biopsy in order to definitively establish the diagnosis.

MRI has become the preferred examination⁸

It was useful for diagnosis in 83% of the cases in Ottaviani's series, including 122 cases of PVNS.¹⁹ MRI has advantages: by clarifying the location of the lesions, it facilitates both the diagnosis and pre-treatment assessment. MRI is also the most precise method of post-treatment imaging in the early and late aftermath to assess the effectiveness of the treatment and follow any recurrence.^{18,20} It also allows the visualisation of any post-surgical aseptic necrosis. The MRI should include T1-weighted sequences with and without gadolinium injections, and T2-weighted sequences.

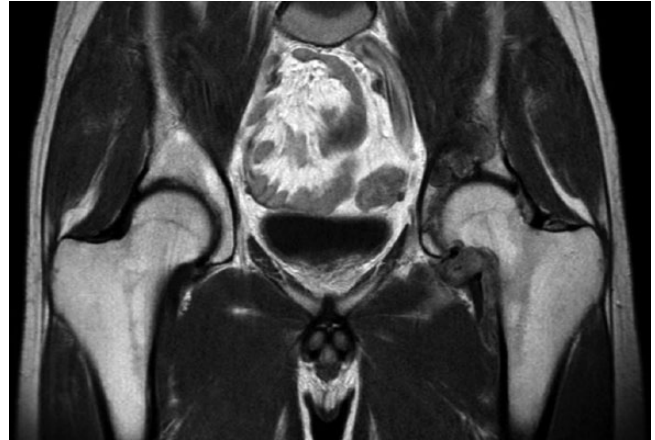

Fig 4 MRI of the hip: the synovium is diffuse at the hip with bone invasion. Synovium appears as hyposignal on T1-weighted sequence and enhances after the gadolinium injection.

Intra-articular effusion

Intra-articular effusion is very common but not specific of PVNS, giving increased *signal* intensity on T2 sequences.

Thickening of the hip synovium

The thickening is diffuse and accompanied by bone invasion (Fig. 4). The synovium appears as a hyposignal on the T1-weighted sequence and is enhanced after gadolinium injection. On the T2-weighted sequence, it is heterogeneous either with areas showing no signal, an intermediate signal or a hypersignal indicating inflammatory lesions.

Specific lesions of PVNS

Lesions found through haemosiderin deposits in tissues and are virtually pathognomonic of the PVNS^{8,20,21} by a hyposignal on T1, persistent on T2 unlike the fatty areas which appear by a hypersignal. After a gadolinium injection, fibrosis and haemosiderin deposit areas remain as hyposignals. The signal enhancement after the gadolinium injection indicates the highly vascular nature of the lesions.⁷ MRI can also identify a possible extension of the synovial process in to soft-tissues.⁷

Treatment

We will report the various treatment options based on the large series available in the literature: Della Valle,⁶ Flipo⁷ and Vastel.⁸

It is currently agreed that PVNS treatment must be surgical. However, in the specific context of hip PVNS, the surgical approach remains poorly defined. There is no widely agreed upon therapeutic strategy.⁸ To the extent that it is possible (given the level of destruction), joint-preserving surgery is preferred for younger patients.

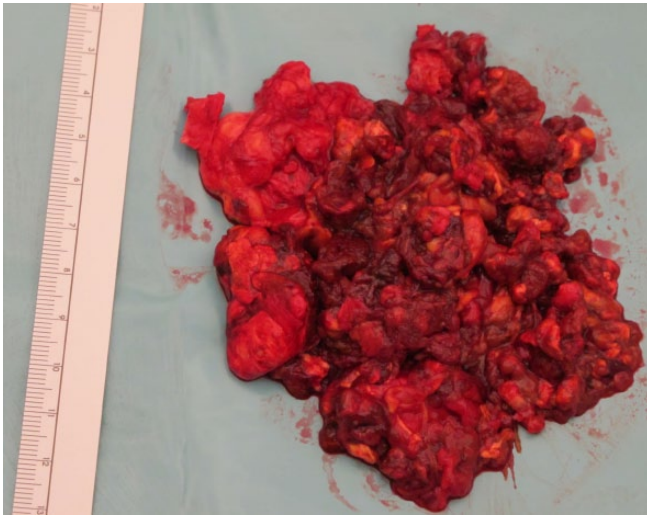


Fig 5 PVNS of the hip.

The goal of treatment is a synovectomy of the diseased synovium, as completely as possible, to prevent the destruction and loss of function of the hip joint.

We must keep in mind that a total synovectomy is a solution providing better results than a partial one. Flipo's series illustrated that partial synovectomy led to more failures (five failures out of eight cases), compared to total synovectomy (two failures out of 12 with synovectomy alone). Della Valle reported similar results.⁶

Total synovectomy is performed in non-arthritic cases. However, some authors have also opted for such treatment in cases with pre-existing degenerative signs in young patients, as described by Vastel.⁸ No recurrence was histologically proven in his two patients.

Synovectomy can be performed either by arthroscopy or open surgery.

Arthroscopy plays only a small role in the treatment of the hip, as localised forms of PVNS are rare. The literature does not recommend arthroscopy in diffuse forms⁷ because it does not permit the exploration of the entire synovium in order to achieve a total synovectomy. Yet arthroscopy may be a useful alternative for diagnostic biopsy.⁷

Open surgery is still the best way to optimise total synovectomy (Fig. 5). Only surgical hip dislocation can expose all synovial recesses, including in the acetabular depths.^{9,17} Moreover, only open surgery allows curettage of the juxta-articular subchondral cysts also containing pathological synovial tissue.

The transplantation of these subchondral cysts with homologous or autologous cancellous bone improves the local mechanical conditions and reduces the risk of recurrence of bone invasion by PVNS.

The exposure of the hip joint by surgical dislocation can be achieved by several approaches, anterior or posterior. Undoubtedly the surgical dislocation according to the technique described by Ganz,²² using an approach

described as 'trochanterotomy digastric' or 'trochanteric flip' which allows the best exposure of the entire joint, femoral head, neck and depths of the acetabular cup, while preserving the vascularisation of the femoral head.

Ganz published his experience with this technique in 213 patients, some of whom had PVNS, without aseptic necrosis of the femoral head. The absence of necrosis was confirmed on 23 hips treated with this technique, including one for PVNS by Sung Jin Shin.²³

The main risks identified by Ganz²² in these 213 cases included neuroapraxia (two cases, 1%), a loosening of the trochanter (three cases, 1.5%) and some heterotopic ossification (79 cases, 37%, including 68 cases of class 1 according to Brooker).

Other conventional approaches allow exposure to the hip synovium. These are the anterior Smith-Peterson and the posterior Kocher-Langenbeck approaches. With the anterior Smith-Peterson the bottom of the acetabulum is hardly accessible because it is hidden by the femoral head and the posterior surface of the femoral neck is almost inaccessible. With the Kocher approach, the risk of injuring the sciatic nerve is important as well as the risk of avascular necrosis of the head.

In Flipo's series,⁷ there was a single osteonecrosis of the femoral head which occurred nine months after a partial synovectomy with curettage and osmic acid synoviorrhesis. The approach is not specified in this review.

In Della Valle's series,⁶ six patients benefitted from a dislocated hip for their synovectomy without aseptic necrosis of the femoral head complications after a three-year follow-up. In his experience,⁶ the surgical approach should be dictated by pre-operative imaging.

In Vastel's series,⁸ the surgical procedure was performed via a lateral approach by trochanteric osteotomy with anterior dislocation following Ganz's technique, without preservation of the distal muscle attachment (digastric) over the greater trochanter. The osteotomy was modified for cases of synovectomy alone to preserve the deep fibres of the gluteus medius and piriformis and to protect the medial circumflex artery. No patient in this series had osteonecrosis of the femoral head following the transtrochanteric approach.

Regarding the type of bone substitute used for the filling of the juxta-articular cysts, the published series do not specify which type of graft was used. We know that in Flipo's series, total synovectomy was associated on nine occasions with curettage and filling of bone lesions, but the nature of graft used is not specified. Therefore it's difficult to assess the effectiveness of the different methods available.

Total hip arthroplasty

Total hip arthroplasty (THA) is the primary solution for confirmed osteoarthritis when conservative surgical treatment has failed. Even if radical synovectomy seems to be

effective to prevent recurrence, according to Vastel it does not delay the development of secondary osteoarthritis,⁸ requiring a THA procedure.

The choice of a primary treatment by a THA must obviously be retained in cases with significant joint destruction. This solution gives excellent results, as shown in Flipo's series⁷ of 13 cases with a mean follow-up of three years, and four cases in Vastel's series⁸ with a follow-up of 16.7 years. The only failure listed after THA is found in Della Valle's series⁶ among 24 patients who underwent synovectomy and arthroplasty. In very young patients, primary arthroplasty must however remain a second-best option reserved for advanced affections with loss of joint space or bone fragility associated with the destruction of the femoral neck or the acetabulum.

An interesting observation is to correlate the therapeutic choice with the radiological grading system by Gitelis as in Della Valle's series. Thus we note that THA was selected for seven patients from the second group, and 17 patients from the third, while synovectomy was performed in one patient from the first, 17 from the second and eight from the third group. We retain that the further advanced the radiologic stage, the greater the indication for primary THA.

In Della Valle's series, with a mean follow-up of 3.6 years, ten patients had a recurrence (19%; 10 of 52), nine in the synovectomy group (35%; 9 of 26; five patients from radiographic Group 2 and 4 patients from Group 3) and one in the joint replacement group (4%; 1 of 24).

Thus, the recurrence rate is 28% in both the first and second group with synovectomy (five of 18) and 50% in the third group (four cases of eight).

Total hip arthroplasty (THA), as first-line treatment in the case of major osteo-articular destruction⁶ provided good results, as reported in Yoo's 2010 series.²⁴ He followed eight patients with a mean age of 34.8 years (range 20-68 years) with hip PVNS, who underwent a cementless THA associated with a synovectomy. The mean follow-up was 8.9 years (range 4.3-13.5 years). The Harris hip score improved from 49.3 to 96.6 points, and all patients were able to resume regular activities of daily life. No patient presented with recurrences of PVNS. The option of THA in a young patient must obviously remain a second choice, despite the good results of Yoo's series.²⁴

Radiotherapy

Radiotherapy alone is not effective, as demonstrated by the case illustrated in Flipo's series,⁷ where those who received only radiotherapy ended in treatment failure. In addition, it puts the patients at risk of osteonecrosis and fractures,²⁵ secondary to a weakened femoral neck. There is no study assessing with radiotherapy alone, or combined with a hip surgery permits definitive conclusions,

but studies on other joints show that it can be a complement to surgery.^{25,26}

Other treatments

The osmic acid or isotopic synoviorthesis alone described in Flipo's series, had bad results in 14 cases.

Chemical synovectomy with osmic acid was given for the first time in 1951 by Von Reis and Swensson, according to Menkès,²⁷ in the treatment of rheumatoid arthritis. It gave disappointing results in creating irreversible cartilage damage, as showed by Guaydier-Souquière et al,²⁸ and later Menkès.²⁷ Currently this technique is not recommended.

Arthroplasty with interposition of a cup with synovectomy shows a 50% rate of failure in the Flipo, and Vastel, series.⁸ A cephalic arthroplasty was performed following a femoral neck fracture in one patient in De Vastel's series, but this case has a limited follow-up, allowing no judgement. Arthrodesis remains the ultimate and rare solution. It probably results in less recurrence because of the destruction of the joint space, but definitely complicates the functional prognosis.

Treatment in cases of recurrence or osteoarthritis

The choice of treatment in cases of failure, avascular necrosis, femoral neck fracture or osteoarthritis is preferentially THA, as shown in Flipo's series with nine THAs *versus* two total synovectomies. The reasons for failure are a proven recurrence in five cases, strongly suspected recurrences in two other cases and one case of an osteonecrosis of the femoral head after a partial synovectomy combined with curettage and an osmic acid synoviorthesis.

In Della Valle's article,⁶ the treatment of recurrence was required in only six cases out of ten, with four THA and two arthrodesis as the therapeutic options.

In Vastel's article,⁸ nine of the 16 patients required revision surgery. Only one case suffered a recurrent synovitis detected during an anatomic-pathology examination 14 years after the synovectomy and cup arthroplasty treatment. Secondary osteoarthritis developed in eight patients treated only with synovectomy, and four of them required a total hip arthroplasty during the follow-up period.

Conclusions

Publications concerning the management of PVNS are still scarce because of the low incidence of this disease.

In the absence of arthritic signs, complete synovectomy appears to be effective in preventing recurrence, but seems less able to prevent the development of secondary osteoarthritis.

The challenge for clinicians is to recognise PVNS as the possible aetiology of mechanical hip pain, especially in young people. In young patients, who are the most frequent targets of this affection, an early and well-conducted total synovectomy is highly recommended, allowing in most cases a resolution of the pathology. A late diagnosis with disease management at an advanced stage worsens the prognosis of conservative surgical approach to the hip joint, and is a potential indication for primary total hip arthroplasty.

AUTHOR INFORMATION

Geneva University Hospitals, Geneva, Switzerland.

Correspondence should be sent to: S. Steinmetz, Orthopedic Surgery Service, Geneva University Hospitals, Rue Gabrielle-Perret-Gentil 4, Geneva 1211, Switzerland. Email: steinmetzsylvain@gmail.com

CONFLICT OF INTEREST

None declared.

FUNDING STATEMENT

No benefits in any form have been received or will be received from a commercial party related directly or indirectly to the subject of this article.

LICENCE

© 2016 The author(s)

This article is distributed under the terms of the Creative Commons Attribution-NonCommercial 4.0 License (<http://www.creativecommons.org/licenses/by-nc/4.0/>) which permits non-commercial use, reproduction and distribution of the work without further permission provided the original work is attributed.

REFERENCES

- Chassaignac M.** Cancer de la gaine des tendons [Cancer of the tendon sheath]. *Gazette des hôpitaux civils et militaires* 1852;47:185-186.
- Jaffe HL, Lichtenstein L, Sutro CJ.** Pigmented villonodular synovitis, bursitis, and tenosynovitis. *Arch Path* 1941;31:731-765.
- Myers BW, Masi AT.** Pigmented villonodular synovitis and tenosynovitis: a clinical epidemiologic study of 166 cases and literature review. *Medicine (Baltimore)* 1980;59:223-238.
- Higuchi C, Ohno I, Yoshikawa H.** Hip joint pigmented villonodular synovitis in a young girl: a case report. *J Pediatr Orthop B* 2012;21:335-338. PMID:22433958.
- Hussenstein J, Delaneau J, Jobard P, Moniere L.** A propos de 4 nouveaux cas de synovite villo-nodulaire. *Rev Chir Orthop Reparatrice Appar Mot* 1961;47:38-49.
- González Della Valle A, Piccaluga F, Potter HG, Salvati EA, Pusso R.** Pigmented villonodular synovitis of the hip: 2- to 23-year followup study. *Clin Orthop Relat Res* 2001;388:187-199.
- Flipo RM, Desvigne-Noulet MC, Cotten A, et al.** La synovite villo-nodulaire pigmentée de la hanche. Résultats d'une enquête nationale à propos de 58 observations. *Rev Rhum Mal Osteoartic* 1994;61:85-95.
- Vastel L, Lambert P, De Pinieux G, et al.** Surgical treatment of pigmented villonodular synovitis of the hip. *J Bone Joint Surg [Am]* 2005;87:1019-1024.
- Gitelis S, Heligman D, Morton T.** The treatment of pigmented villonodular synovitis of the hip. A case report and literature review. *Clin Orthop Relat Res* 1989;239:154-160.
- Young JM, Hudacek AG.** Experimental production of pigmented villonodular synovitis in dogs. *Am J Pathol* 1954;30:799-811.
- Ofluoglu O.** Pigmented villonodular synovitis. *Orthop Clin North Am* 2006;37:23-33.
- Fiocco U, Sfriso P, Lunardi F, et al.** Molecular pathways involved in synovial cell inflammation and tumoral proliferation in diffuse pigmented villonodular synovitis. *Autoimmun Rev* 2010;9:780-784.
- Legré V, Boyer T, Dorfmann H, Lafforgue P.** *Tumeurs et dystrophies de la synoviale. EMC Appareil locomoteur.* Paris: Elsevier Masson SAS; 2007:6-8.
- Murphey MD, Rhee JH, Lewis RB, et al.** Pigmented villonodular synovitis: radiologic-pathologic correlation. *Radiographics* 2008;28:1493-1518.
- Fletcher CDM, Bridge JA, Hogendoorn P, Mertens F.** *WHO classification of tumours of soft tissue and bone.* Fourth ed. Lyon: IARC, 2013:100-103.
- Benoist M, Degott C, Korber L, Bloch-Michel H.** Synovite villo-nodulaire de la hanche à forme xanthomateuse. *Rev Rhum Mal Osteoartic* 1977;44:753-757.
- Lequesne M., Nicolas J.L., Kerboull M., Postel M.** Pigmented villonodular synovitis of the hip joint. A report of six cases with review of the literature. *Int Orthop* 1980;4:133-144. [In French]
- Llauger J, Palmer J, Rosón N, Cremades R, Bagué S.** Pigmented villonodular synovitis and giant cell tumors of the tendon sheath: radiologic and pathologic features. *AJR Am J Roentgenol* 1999;172:1087-1091.
- Ottaviani S, Ayril X, Dougados M, Gossec L.** Pigmented villonodular synovitis: a retrospective single-center study of 122 cases and review of the literature. *Semin Arthritis Rheum* 2011;40:539-546.
- Jelinek JS, Kransdorf MJ, Shmookler BM, Aboulafia AA, Malawer MM.** Giant cell tumor of the tendon sheath: MR findings in nine cases. *AJR Am J Roentgenol* 1994;162:919-922.
- Garner HW, Ortiguera CJ, Nakhleh RE.** Pigmented villonodular synovitis. *Radiographics* 2008;28:1519-1523.
- Ganz R, Gill TJ, Gautier E, et al.** Surgical dislocation of the adult hip a technique with full access to the femoral head and acetabulum without the risk of avascular necrosis. *J Bone Joint Surg [Br]* 2001;83:1119-1124.
- Shin SJ, Kwak HS, Cho TJ, et al.** Application of Ganz surgical hip dislocation approach in pediatric hip diseases. *Clin Orthop Surg* 2009;1:132-137.
- Yoo JJ, Kwon YS, Koo KH, et al.** Cementless total hip arthroplasty performed in patients with pigmented villonodular synovitis. *J Arthroplasty* 2010;25:552-557.
- Berger B, Ganswindt U, Bamberg M, Hehr T.** External beam radiotherapy as postoperative treatment of diffuse pigmented villonodular synovitis. *Int J Radiat Oncol Biol Phys* 2007;67:1130-1134.
- Park G, Kim YS, Kim JH, et al.** Low-dose external beam radiotherapy as a postoperative treatment for patients with diffuse pigmented villonodular synovitis of the knee: 4 recurrences in 23 patients followed for mean 9 years. *Acta Orthop* 2012;83:256-260.
- Menkes CJ.** Is there a place for chemical and radiation synovectomy in rheumatic diseases? *Rheumatol Rehabil* 1979;18:65-77.
- Guaydier-Souquieres C, Beguin J, Ollivier D, Loyau G.** Knee arthroscopy after yttrium or osmic acid injection. *Arthroscopy* 1989;5:70-75.