



Article scientifique

Lettre

2014

Published version

Open Access

This is the published version of the publication, made available in accordance with the publisher's policy.

---

A simple Baker's cyst? Tocilizumab remits paraneoplastic signs and controls growth of IL-6-producing angiomatoid malignant fibrous histiocytoma

---

Villiger, Peter M; Cottier, Silvia; Jonczy, Maciej; Koelzer, Viktor H; Roux-Lombard, Pascale; Adler, Sabine

#### How to cite

VILLIGER, Peter M et al. A simple Baker's cyst? Tocilizumab remits paraneoplastic signs and controls growth of IL-6-producing angiomatoid malignant fibrous histiocytoma. In: Rheumatology, 2014, vol. 53, n° 7, p. 1350–1352. doi: 10.1093/rheumatology/ket452

This publication URL: <https://archive-ouverte.unige.ch/unige:44562>

Publication DOI: [10.1093/rheumatology/ket452](https://doi.org/10.1093/rheumatology/ket452)

## References

- 1 Seror R, Sordet C, Guillemin L *et al.* Tolerance and efficacy of rituximab and changes in serum B cell biomarkers in patients with systemic complications of primary Sjögren's syndrome. *Ann Rheum Dis* 2007;66:351–7.
- 2 Meijer JM, Pijpe J, Vissink A *et al.* Treatment of primary Sjögren syndrome with rituximab: extended follow-up, safety and efficacy of retreatment. *Ann Rheum Dis* 2009; 68:284–5.
- 3 Meiners PM, Arends S, Brouwer E *et al.* Responsiveness of disease activity indices ESSPRI and ESSDAI in patients with primary Sjögren's syndrome treated with rituximab. *Ann Rheum Dis* 2012;71:1297–302.
- 4 Meijer JM, Meiners PM, Vissink A *et al.* Effectiveness of rituximab treatment in primary Sjögren's syndrome: a randomized, double-blind, placebo-controlled trial. *Arthritis Rheum* 2010;62:960–8.
- 5 Pijpe J, van Imhoff GW, Vissink A *et al.* Changes in salivary gland immunohistology and function after rituximab monotherapy in a patient with Sjögren's syndrome and associated MALT lymphoma. *Ann Rheum Dis* 2005;64: 958–60.
- 6 Dass S, Bowman SJ, Vital EM *et al.* Reduction of fatigue in Sjögren syndrome with rituximab: results of a randomised, double-blind, placebo-controlled pilot study. *Ann Rheum Dis* 2008;67:1541–4.
- 7 Devauchelle-Pensec V, Pennec Y, Morvan J *et al.* Improvement of Sjögren's syndrome after two infusions of rituximab (anti-CD20). *Arthritis Rheum* 2007;57:310–7.
- 8 Pijpe J, van Imhoff GW, Spijkervet FKL *et al.* Rituximab treatment in patients with primary Sjögren's syndrome: an open-label phase II study. *Arthritis Rheum* 2005;52: 2740–50.

Rheumatology 2014;53:1350–1352

doi:10.1093/rheumatology/ket452

Advance Access publication 5 February 2014

### A simple Baker's cyst? Tocilizumab remits paraneoplastic signs and controls growth of IL-6-producing angiomatoid malignant fibrous histiocytoma

SIR, A 47-year-old male presented with severe systemic inflammatory response syndrome. A year previously he had noticed a painless swelling in the right fossa poplitea interpreted as Baker's cyst. Laboratory analysis documented CRP (97 mg/l), ESR (102 mm/h), haemoglobin (98 g/l), slightly elevated liver enzymes and hyperferritinaemia (1236 µg/l), but no autoantibodies. Diagnostic workup comprised bone marrow aspiration, liver biopsy, MRI angiography of the thorax and abdomen, temporal artery biopsy, upper and lower gastrointestinal (GI) endoscopy and biopsies to search for Whipple's disease, tuberculosis and malignancy. Differential diagnoses such as adult Still's disease or occult vasculitis were discussed. Short courses of glucocorticoids with 1 mg/kg body weight tapered to 20 mg/day and MTX at 20 mg i.m. weekly

were ineffective. Treatment with infliximab at doses of 3.3 mg/kg body weight (in total 200 mg/kg) at weeks 0, 2 and 6 did not elicit any clinical benefit. CRP remained unchanged (150 mg/l).

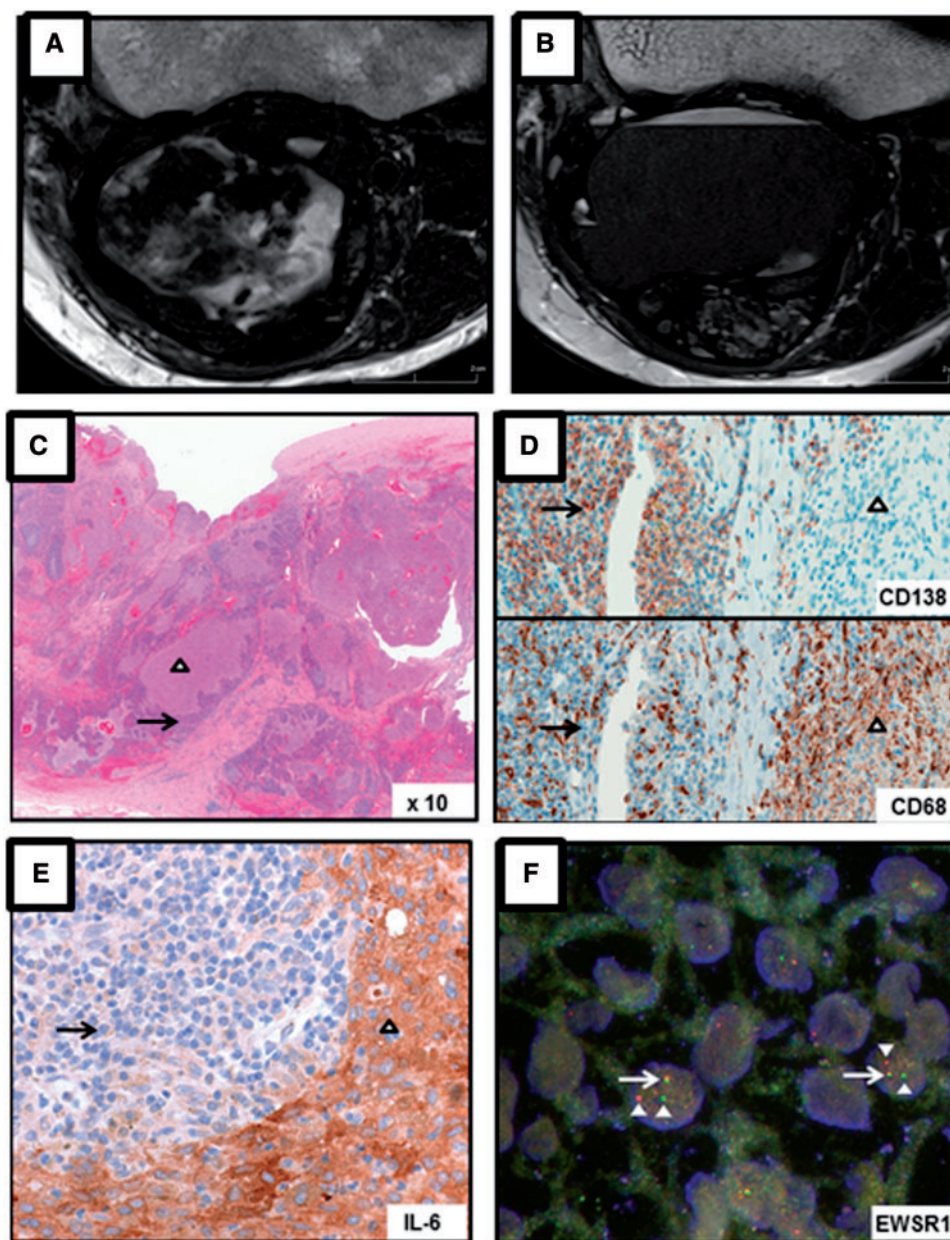
Three years later he was referred to our outpatient clinic. His condition had worsened: haemoglobin 74 g/l, CRP 156 mg/l, ESR 125 mm/h and polyclonal gammopathy had developed (24.9 g; norm <14.6 g/l). Briefly, the patient showed the classical symptoms and signs of uncontrolled IL-6 production [1]. The cellular source of this cytokine remained enigmatic. The only inflammatory tissue to be identified by imaging methods was the Baker's cyst, which was judged by experienced radiologists to be an uncomplicated cyst (Fig. 1A).

The patient agreed to off-label therapy using the IL-6-neutralizing monoclonal antibody tocilizumab. He experienced rapid and full remission. Laboratory parameters and his physical condition normalized within a few weeks. Infusions, the first two given at fortnightly intervals, were continued at 4-week intervals at a dosage of 8 mg/kg body weight.

One year later, in a further attempt to identify the source of IL-6, the MRI of the knee was repeated (Fig. 1B). Surprisingly, the morphology of the Baker's cyst had changed considerably. A substantial part of the heterogeneous tumour was replaced by a large cyst containing homogeneous liquid. We recommended surgical removal, stopped tocilizumab and started to prospectively collect sera for cytokine measurements. Histological analysis documented the unexpected diagnosis of angiomatoid malignant fibrous histiocytoma (aMFH) with production of IL-6 by histiocytoma cells (Fig. 1C–F) [2, 3]. Excision of the neoplasm resulted in complete and lasting remission. Cytokine measurements continuously showed normal concentrations of IL-1, TNF-α and soluble tumour necrosis factor receptor (sTNFR). IL-6 was strongly elevated in synovial fluid and normalized in sera within 8 weeks after surgery.

Many studies have reported elevated systemic levels of proinflammatory cytokines and their antagonists in active autoimmune and inflammatory diseases. Yet clinically it is usually impossible to differentiate between the clinical effects induced by each of the three cytokines. In this case, however, IL-1β, TNF-α and sTNFR-75 remained normal throughout the observation period, while IL-6 was highly elevated until surgery. In addition, blockade of TNF-α using infliximab was completely ineffective with respect to clinical signs as well as control of the acute phase response (e.g. CRP levels), whereas blockade of IL-6 resulted in rapid and lasting complete remission of all pathology findings. In summary the clinical picture and laboratory alterations represent the pleiotropic biological effects of IL-6.

In contrast to its well-characterized effects in inflammation and immunity, the relevance of IL-6 as a mediator of paraneoplastic signs is still unclear. This case is the first to document a remission-inducing effect of IL-6 blockade using tocilizumab in aMFH, thus identifying IL-6 as the key pathogenic factor in the generation of paraneoplasias. In addition to rapid and sustained clinical benefit, a

**Fig. 1** MRI and histology of Baker's cyst

striking finding was the change in morphology of the neoplasm in response to 1 year of IL-6 blockade. The MRI suggested a decrease in aMFH volume replaced by a large cyst. This tumour evolution could best be explained by an autocrine growth effect of IL-6, as described for example for multiple myeloma and prostate cancer [4].

The effect of IL-6 on differentiation of terminal B cells into antibody-producing plasma cells was recognized many years ago [1]. In multiple myelomas, substantial quantities of IL-6 have been shown to be produced in a paracrine fashion by surrounding stromal cells [5]. In our case, immunohistochemistry showed impressive amounts of IL-6 in aMFH cells, clinically reflected by polyclonal

gammopathy. However, IL-6 was virtually absent in plasma cells. This pattern suggests that IL-6 produced and secreted by the aMFH acted as a growth factor for plasma cells as well as tumour cells. Documenting a high density of polyclonal plasma cells in close proximity to tumour cells supports this hypothesis, suggesting an explanation for the formation of one tumour by two cell populations of different origin.

Collectively, the patient's history and described findings show that the signs and symptoms of our case reflect the effects of chronic IL-6 exposure. It identifies IL-6 as the pathogenic factor for paraneoplastic signs and symptoms in aMFH. Finally, it illustrates that complete response to

IL-6 blockade in a case resistant to TNF neutralization should prompt a second diagnostic workup.

#### Rheumatology key message

- Neutralization of IL-6 by tocilizumab induces complete clinical remission and controls the growth of popliteal angiomatoid malignant fibrous histiocytoma.

**Disclosure statement:** The authors have declared no conflicts of interest.

**Peter M. Villiger<sup>1</sup>, Silvia Cottier<sup>1</sup>, Maciej Jonczyk<sup>2</sup>, Viktor H. Koelzer<sup>3</sup>, Pascale Roux-Lombard<sup>4</sup> and Sabine Adler<sup>1</sup>**

<sup>1</sup>Department of Rheumatology, Clinical Immunology and Allergology, <sup>2</sup>Institute of Radiology, University Hospital and University of Bern, <sup>3</sup>Institute of Pathology, University of Bern, Bern and <sup>4</sup>Laboratory for Immunology and Clinical Allergology, University Hospital Geneva, Geneva, Switzerland. Accepted 22 November 2013

Correspondence to: Peter M. Villiger, Department of Rheumatology, Clinical Immunology and Allergology, University Hospital and University of Bern, Freiburgstrasse, 3010 Bern, Switzerland. E-mail: peter.villiger@insel.ch

## References

- 1 Oshugi Y. Recent advances in immunopathophysiology of interleukin-6: an innovative therapeutic drug, tocilizumab (recombinant humanized anti-human interleukin-6 receptor antibody), unveils the mysterious etiology of immune-mediated inflammatory diseases. *Biol Pharm Bull* 2007;30: 2001–6.
- 2 Tanas MR, Rubin BP, Montgomery EA *et al.* Utility of FISH in the diagnosis of angiomatoid fibrous histiocytoma: a series of 18 cases. *Mod Pathol* 2010;23:93–7.
- 3 Hamada T, Komiya S, Hiraoka K *et al.* IL-6 in a pleomorphic type of malignant fibrous histiocytoma presenting high fever. *Hum Pathol* 1998;29:758–61.
- 4 Kawano M, Kuramoto A, Hirano T *et al.* Cytokines as autocrine growth factors in malignancies. *Cancer Surv* 1989;8:905–16.
- 5 Klein B, Bataille R. Cytokine network in human multiple myeloma. *Hematol Oncol Clin North Am* 1992;6:273–84.

*Rheumatology* 2014;53:1352–1353  
doi:10.1093/rheumatology/keu019  
Advance Access publication 7 March 2014

### Fulminant myocarditis and macrophage activation syndrome secondary to adult-onset Still's disease successfully treated with tocilizumab

SIR, Adult-onset Still's disease (AOSD) is a rare multisystem inflammatory condition, the aetiology of which remains unknown. Studies have shown that IL-1 $\beta$ , IL-6, IL-18, IFN- $\gamma$  and TNF play pathogenic roles [1]. Commonly used biologic

agents in AOSD treatment include IL-1 receptor antagonists and TNF- $\alpha$  blockers [2]. Treatment with tocilizumab as both an initial agent and in multirefractory AOSD has been reported [3]. Its use in macrophage activation syndrome (MAS) has not.

Refractory or untreated AOSD may progress to MAS. MAS results in excessive activation and expansion of T lymphocytes and macrophagic histiocytes that exhibit haemophagocytic activity. This leads to a massive systemic inflammatory response associated with three cardinal features: cytopenia, liver dysfunction and coagulopathy. MAS is a life-threatening condition with reported mortality rates of 20–50% [4].

We report the case of a 32-year-old man who presented with recurrent pyrexia and arthralgia. Investigations for infective causes including EBV, CMV and atypical pneumonia were negative. Autoimmune and HIV testing were also negative. Cardiac echo showed a left ventricular ejection fraction (LVEF) of >60%. Over a 4-week period he received numerous courses of i.v. antibiotics, including gentamicin, tazocin, meropenem, metronidazole and teicoplanin. However, he continued to spike temperatures to 41.3°C. CRP > 400 mg/l (normal <5) and a white cell count of  $24 \times 10^9/l$  (normal 4.0–10.0) were persistently elevated. Rheumatology evaluation elicited a rash and synovitis, in keeping with AOSD (as classified using Yamaguchi criteria) [5]. Serum ferritin was 11 683  $\mu g/l$  (normal 1–325).

An initial response was seen with prednisolone 40 mg/day. Over the following 48 h deterioration occurred, with hypertriglyceridaemia, anaemia, thrombocytopenia, tachycardia, hypotension, hypofibrinogenaemia and hyperferritinaemia (peaking at 30 739  $\mu g/l$ ). He required transfer to the intensive care unit, where inotropic support was commenced along with i.v. methylprednisolone and anakinra.

An echocardiograph revealed a severely impaired LVEF of 30%. High-sensitivity cardiac troponin peaked at 154 ng/l (normal <14), with clinical findings suggestive of myocarditis.

A bone marrow biopsy indicated a hypercellular film with myeloid hyperplasia and evidence of a left shift, with reduced erythropoiesis. Plentiful macrophages exhibiting haemophagocytosis were seen, in keeping with MAS. No improvement was noted following 3 days of anakinra. Our patient continued to decline, with increasing inotropic support, worsening lactic acidosis and persistent tachycardia.

Immunoglobulins, 70 g over 3 days, and ciclosporin 3 mg/kg were commenced. Treatment failure necessitated tocilizumab 8 mg/kg. At this point intubation, vasopressor support and dialysis were required. Repeat echocardiography prior to tocilizumab infusion showed an estimated ejection fraction of 20%, with severe global impairment, a moderately dilated right ventricle, severely impaired systolic function and a mildly dilated right atrium. Cardiac arrest occurred within 48 h of the initial infusion of tocilizumab, in the setting of worsening cardiogenic