



Article scientifique

Article

2005

Published version

Open Access

This is the published version of the publication, made available in accordance with the publisher's policy.

Treatment of gastrointestinal hemorrhage

Charbonnet, Pierre; Toman, Jaroslava; Buehler, Leo Hans; Vermeulen, Bernard; Morel, Philippe;
Becker, Christoph; Terrier, François

How to cite

CHARBONNET, Pierre et al. Treatment of gastrointestinal hemorrhage. In: Abdominal imaging, 2005, vol. 30, n° 6, p. 719–726. doi: 10.1007/s00261-005-0314-8

This publication URL: <https://archive-ouverte.unige.ch/unige:39634>

Publication DOI: [10.1007/s00261-005-0314-8](https://doi.org/10.1007/s00261-005-0314-8)

Treatment of gastrointestinal hemorrhage

P. Charbonnet,^{2*} J. Toman,^{1*} L. Bühler,² B. Vermeulen,³ P. Morel,² C. D. Becker,¹
F. Terrier¹

¹Division de Radiodiagnostic et de Radiologie interventionnelle, Hôpital Universitaire de Genève 24, rue Micheli-du-Crest, 1211 Genève 14, Switzerland

²Clinique et Policlinique de Chirurgie digestive, Hôpital Universitaire de Genève, 24, rue Micheli-du-Crest, 1211 Genève 14, Switzerland

³Division des Urgences médico-chirurgicales, Hôpital Universitaire de Genève, 24, rue Micheli-du-Crest, 1211 Genève 14, Switzerland

Abstract

Background: We assessed the value of selective arteriography in the diagnosis and management of acute gastrointestinal hemorrhage.

Methods: We reviewed the records of 107 consecutive patients who had gastrointestinal hemorrhage and underwent selective arteriography between January 1992 and October 2003: 10 had upper gastrointestinal bleeding, 79 had lower gastrointestinal bleeding, and 18 had varicose bleeding with portal hypertension. Selective embolization was attempted in 15 patients to obtain hemostasis. Angiographic findings were reviewed and prospective reports were compared with the final diagnosis and outcome.

Results: Of 129 angiographic studies, 36 correctly revealed the bleeding site and 93 were negative. Extravasation was seen in 24 cases at the level of stomach ($n = 2$), duodenum ($n = 1$), small bowel ($n = 5$), or colon ($n = 16$). Indirect signs of bleeding sources were identified in 12 patients (stomach in one, small bowel in four, large bowel in four, liver in three). Transcatheter embolization induced definitive hemostasis in 11 of 15 patients (73%), namely in the stomach ($n = 2$), small bowel ($n = 3$), colon ($n = 7$), and liver ($n = 3$). Three patients required surgery after embolization.

Conclusion: Abdominal arteriography may localize gastrointestinal bleeding sources in approximately one-third of cases. Selective embolization may provide definitive hemostasis in most instances.

Key words: Gastrointestinal hemorrhage—Selective embolization—Surgery

The diagnosis of the etiology and localization of acute gastrointestinal bleeding is challenging for several reasons: the possible sites of origin involve the digestive tract in its entirety and the bleeding may be intermittent with brisk recurrence and may, notably in case of upper hemorrhage, threaten the patient's life.

In acute upper gastrointestinal bleeding, the bleeding site is by definition proximal to the ligament of Treitz: the patient presents with hematemesis or melena [1]. Its main clinical manifestation is hematemesis. A bleeding site distal to the ligament of Treitz is defined as lower intestinal tract bleeding. Its main clinical manifestations are melena or hematochezia.

The incidence of acute upper gastrointestinal bleeding is 50 to 150 per 100,000 of the population each year [2]. It arises at all ages, generally after age 60 years and concerns mostly the males (two males for each female until age of 75 years) [1]. The incidence of acute lower gastrointestinal bleeding is estimated to be 20 to 30 per 100,000 persons [3], also with a male predominance in those older than 60 years [4]. The Overall mortality rate of upper gastrointestinal bleeding is approximately 14% [1] and that of lower gastrointestinal bleeding lower than 5% [4].

A multidisciplinary approach improves the efficiency of patient care for acute upper or lower gastrointestinal bleeding [5]. Emergency physicians, gastroenterologists, and surgeons have a well-defined role in these situations. Radiologists have been involved since the 1960s, when selective arterial catheterization to identify bleeding sites in the gastrointestinal tract was first described by Nussbaum and Baum [6]. Rosch et al. [7] managed to control an acute gastric hemorrhage by embolization of the

*Both authors contributed equally to this work.

Correspondence to: P. Charbonnet; email: pierre.charbonnet@hcuge.ch

gastroepiploic artery using an autologous clot. During the 1970s, developments in catheter technology and the emergence of new materials for embolization (e.g., Gel-foam [8] and steel spiral coils [9]) boosted interest in embolization.

The place of arteriography in the management algorithm of gastrointestinal bleeding depends on the bleeding site: whereas endoscopy is always the initial investigative option for upper gastrointestinal bleeding after hemodynamic stabilization, mesenteric angiography is often the first step in the management of massive lower gastrointestinal bleeding [10].

This present study evaluated the efficiency and the place of emergency angiography in the management of patients who have acute gastrointestinal bleeding. For this purpose, we reviewed retrospectively all clinical histories and angiographies performed for acute gastrointestinal bleeding in our institution from January 1992 to October 2003.

Materials and methods

The clinical records of all consecutive patients who had confirmed acute upper and/or lower gastrointestinal bleeding and were admitted for an emergency angiography over 11 years (from January 1992 to October 2003) were studied retrospectively. Main indications for arteriography were localization of the bleeding site before surgery and/or embolization.

Arteriography was ordered by abdominal surgeons and performed by a senior radiologist. Embolization was performed during the same examination if the radiologist and the surgeon agreed to do so.

Two radiologists and one surgeon reviewed the angiographies and were blinded to a patient's outcome and they compared retrospectively their conclusions with those of the initial reports.

Our study group included 107 patients (69 men and 38 women). Average age was 56 years (range 17–98 years). At least one significant comorbid condition was found in 75% of the admissions: 23 patients (21%) had cirrhosis, 39 patients (36%) had cardiovascular disease, and 43 patients (40%) were using antiagreggant or anti-coagulation medication.

Fourteen patients (13%) presented with hematemesis, suggesting an upper bleeding site; 91 (85%) with melena or hematochezia, suggesting an upper or a lower bleeding site; and two with hematemesis and hematochezia, suggesting severe upper gastrointestinal bleeding with rapid transit of blood.

Thirty patients (28%) had an endoscopic diagnosis before angiography to definitely localize the ongoing bleeding and/or control by embolization (poor surgical candidates). In 44 patients (41%), the bleeding site remained undiagnosed despite endoscopic investigation. Ten patients (9%) were directly referred to arteriography.

Table 1. Sources of gastrointestinal bleeding

Final diagnosis	No. of patients (%)
Gastrointestinal hemorrhage of unknown origin	28 (26)
Colonic diverticulum	20 (19)
Esophageal varices	15 (14)
Angiodysplasia	9 (8)
Small bowel tumor	6 (6)
Duodenal ulcer	3 (3)
Anastomotic bleeding	3 (3)
Small bowel varices	3 (3)
Small bowel ischemia	2 (2)
Dieulafoy gastric ulcer	2 (2)
Meckel diverticulum	1 (1)
Colonic carcinoma	1
Status post rectal polypectomy	1
Large bowel ulcer	1
Arterioportal fistula	1
Multiple organ failure	1
Duodenal diverticulum	1
Gastric metastasis	1
Portal cavernous angioma	1
Colonic amyloidosis	1
Colonic ischemia	1
Inflammatory bowel disease	1
Rectal hemorrhoids	1
Rectal ulcer	1
Small bowel diverticulum	1
Cholangiocarcinoma	1

For five patients (5%), no data regarding endoscopic examination were retrospectively found. Eighteen patients (17%) had a hemorrhage related to their portal hypertension and arteriography was done to define the bleeding site and assess the possibility of embolization, to check the permeability of a portal shunt, or to determine vascular anatomy before surgery.

Six patients underwent two angiographies during different hospitalization periods. Hemoglobin levels before angiography were higher than 8 g/L (the value at which blood transfusions are generally required) in 66 patients (62%), lower than 8 g/L in 33 patients (31%) and unknown in eight patients. Urea creatinine dissociation (a serum urea nitrogen level disproportionately high in relation to the creatinine level as a sign of upper gastrointestinal bleeding) was observed in only nine patients. More than 90% of patients received more than 2 hemoglobin units (275 ± 75 mL of erythrocytic concentrate). Thirty-six patients (34%) were admitted to the intensive care unit.

All vascular punctures were performed at the levels of the right common femoral artery. After the examination, compression at the puncture site was maintained with the patient at rest in a supine position.

Angiographic criteria to diagnose active bleeding or define the bleeding site were separated into direct and indirect signs. Contrast extravasation is the only direct sign, whereas vascular tuft, arteriovenous fistula, early filling vein, or a hypervascular mass represent an indirect sign.

Table 2. Radiological signs for positive angiographie result

	Radiologic signs	No. of patients	Localization (cases)
Direct sign	Contrast medium extravasation	24	Stomach (2), duodenum (1), small bowel (5), large bowel (16)
Indirect signs	Vascular spot and drainage vein	3	Large bowel
	Arteriovenous fistula	3	Liver
	Hypervascular mass	6	Stomach (1), small bowel (4), large bowel (1)

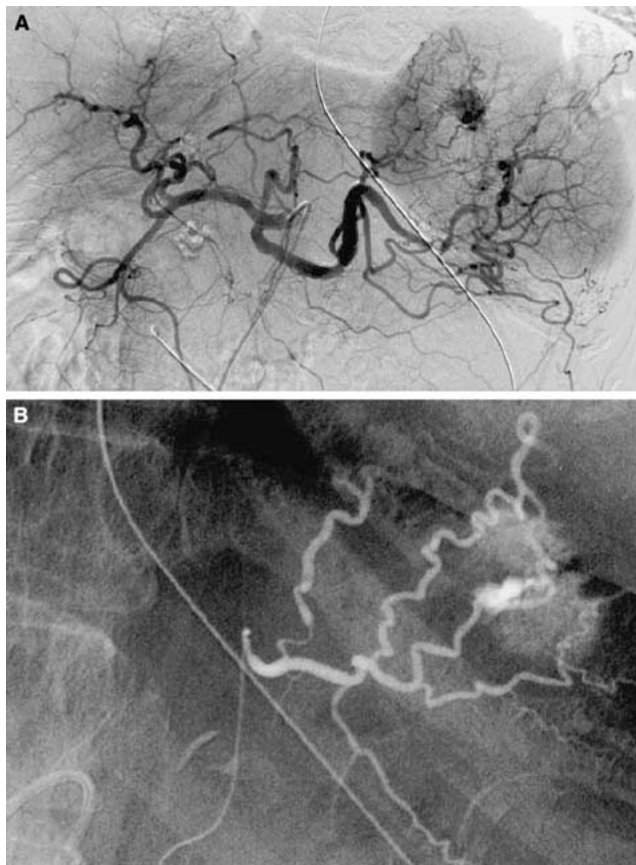


Fig. 1. Patient with a Dieulafoy gastric lesion. **(A)** Selective and **(B)** superselective celiac angiograms show an extravasation of contrast from a branch of the left gastric artery, indicating continuous bleeding.

For embolizations, silk particles, coils, and polyvinyl alcohol particles were employed.

All possible complications (local: hematoma, pseudoaneurysm, infection, or arterial dissection; systemic: acute renal insufficiency, allergic reactions, digestive necrosis, or ischemia) were carefully sought and checked by the radiologist who visited the patient in the hours after the examination.

No provocative angiography (provocation of bleeding with vasodilators, anticoagulants, and/or thrombolytics) was performed (departmental decision).

Radionuclide scanning (commonly the technetium 99m pertechnetate-labeled red blood cell scan) was al-

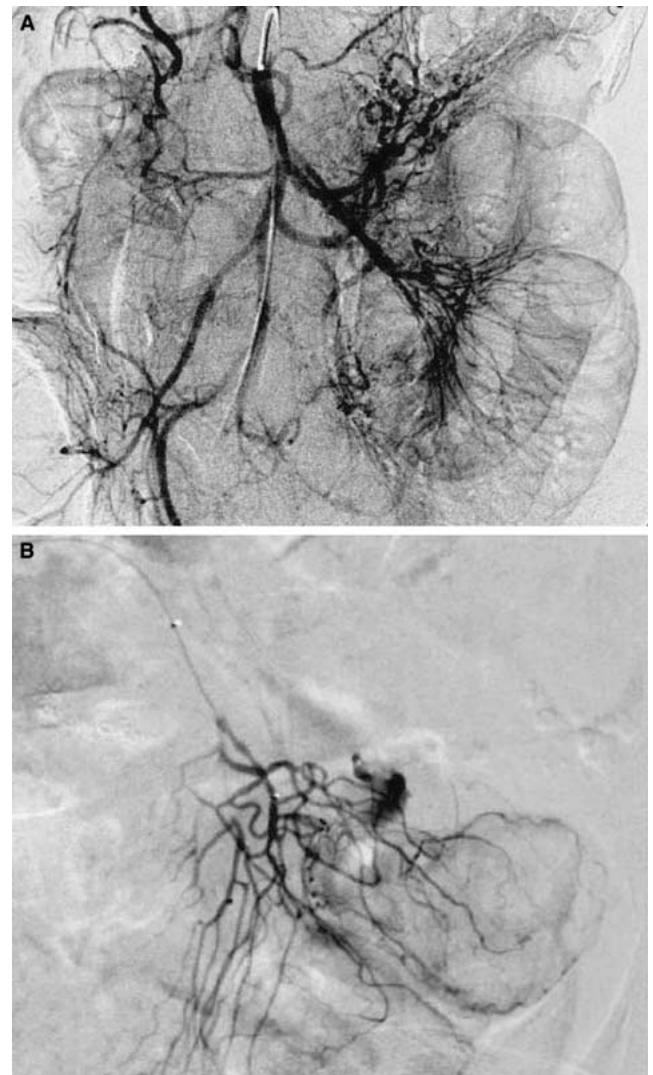


Fig. 2. Bleeding of the small bowel. **A** No extravasation of contrast medium is seen at the first selective superior mesenteric arteriogram. **B** The next day, a superselective jejunal arteriogram clearly shows active extravasation of contrast medium.

ways performed after a negative angiogram, owing to the time required to perform the radioisotopic scan in our institution. Ten patients had a radionuclide scan after a negative angiogram.

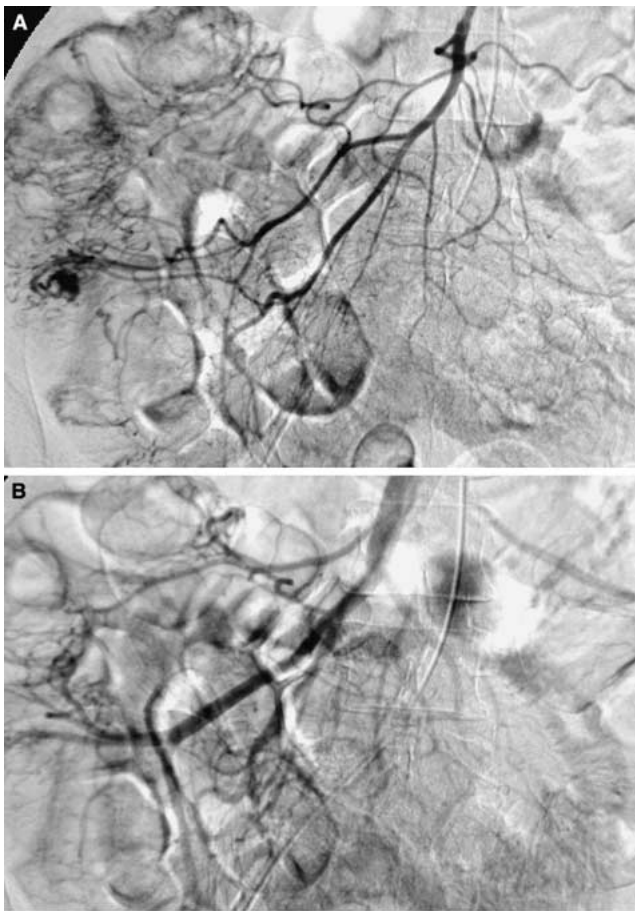


Fig. 3. Angiodysplasia of the cecum. **A** Superior mesenteric artery angiogram shows a hypervascular area in the cecum containing a dense tangle of vessels. **B** Early draining vein, a characteristic finding of angiodysplasia.

Most patients (82%) underwent one arteriography, and 16 patients (15%) underwent two arteriographies, and three patients (3%) underwent three. In total 129 arteriographies were performed.

Results

Ten patients (9%) had upper gastrointestinal bleeding, 79 (74%) had lower gastrointestinal bleeding, 15 (14%) had upper varicose bleeding, and three (3%) had lower varicose bleeding, all with known portal hypertension.

Table 1 summarizes all the final diagnoses, based on the final clinical reports. Angiography was positive in 31% (36 of 118; 11 examinations were performed in patients who had portal hypertension to check shunt permeability or determine vascular anatomy were subtracted from the total number of positive arteriographies; Table 2). Direct or indirect signs were observed in the stomach in three cases (Fig. 1), the liver in three cases, the duodenum in one case, the small bowel in nine cases (Fig. 2), and the large bowel in 20 cases (Fig. 3).

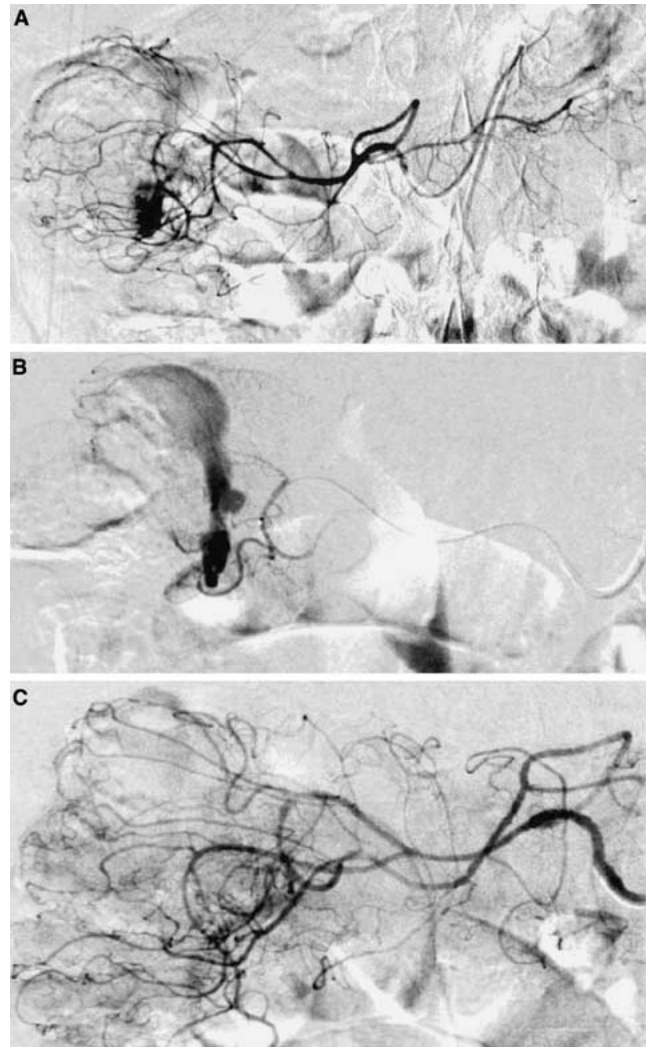


Fig. 4. Embolization of large right colon bleeding from diverticular disease. **A** Selective superior mesenteric arteriogram demonstrates extravasation in the lumen at the right angle of the large bowel. **B** Superselective middle colic arteriogram confirms the intraluminal extravasation at the bleeding site. **C** Result after silk particles placed in the distal middle colic artery by a microcatheter: Extravasation has ceased, without bleeding from other branches.

The most frequent disease associated with a positive arteriogram was diverticulosis. All 24 patients (22%) who had vascular extravasation of contrast medium at angiography had hypotension corresponding to hypovolemic shock. Sixteen embolizations in 15 patients (14%) were performed: twice at the level of the stomach, three times at the level of the small bowel, eight at the level of the large bowel (Fig. 4), and three at the level of the liver. Embolization was the definitive treatment in 11 patients (10%). After embolization, three patients underwent surgery for recurrent bleeding in the stomach ($n = 1$) or small bowel ($n = 2$). In total, 30 patients (28%) were operated upon, 17 after a positive arteriogram that

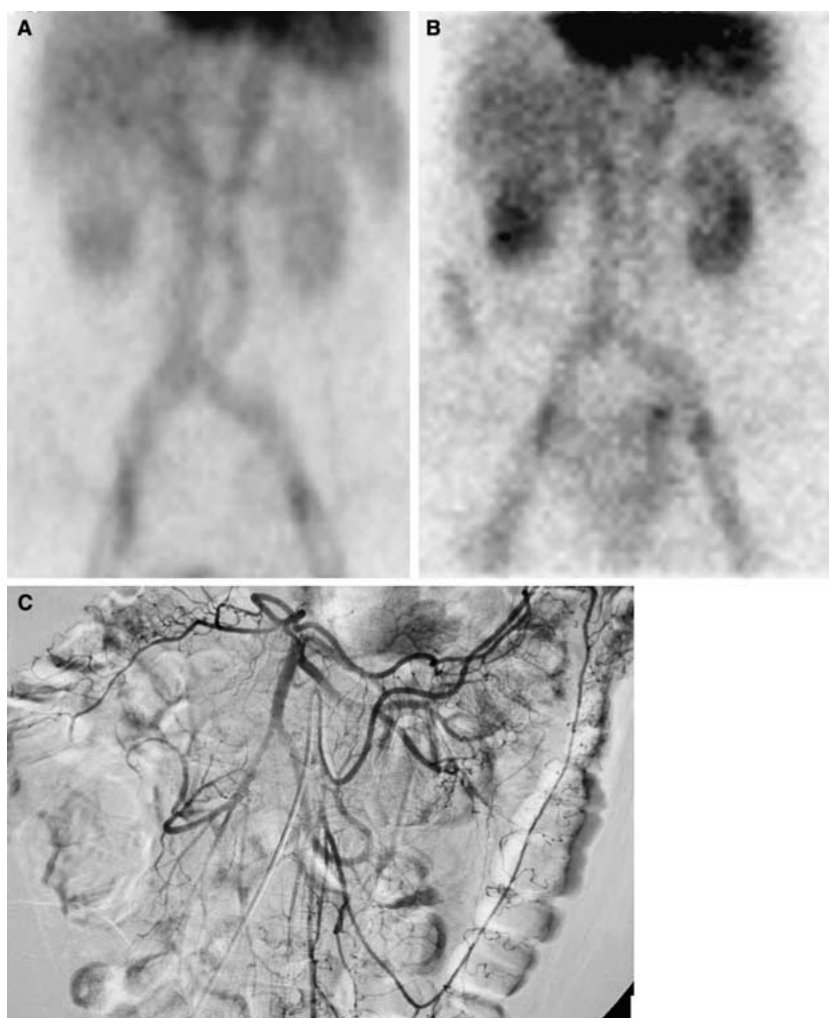

Fig. 5. Immediate and delayed images from a large bowel bleeding demonstrated by technetium 99m-labeled erythrocyte scan. **A** An early image from the scan shows no abnormal extraluminal radioactivity. **B** A late image from the same study displays a focus of increased radioactive uptake in the right midabdomen at the level of the ascending colon. **C** A superior mesenteric arteriogram from the same patient demonstrates no abnormal extravasation of contrast medium.

localized the site, five after a negative arteriogram and a positive radionuclide scan (Fig. 5), and eight after a negative arteriogram and no other radiographic examination (cf. Table 3, Figs. 6, 7)

Twelve patients died consecutively due to hemorrhage (global mortality rate of 11%). Mortality rate was higher in patients who had upper gastrointestinal bleeding (five of 25 compared with seven of 82 patients who had slower gastrointestinal bleeding).

No patient died as a consequence of complications caused by the procedure. Three patients (2%) had local complications related to the catheter manipulation: one distal artery rupture and two pseudoaneurysms. No bowel ischemic event was noticed in this series.

Arteriograms were reviewed, with concordant results in 96%. There were five discordant results: in four cases, the retrospective evaluation demonstrated contrast medium extravasation not observed at the initial interpretation (locations were confirmed according to the final diagnosis); in one case, the retrospective evaluation considered contrast medium extravasation at the level of the left colon, although the interpretation was negative.

Table 3. Surgical interventions for acute bleeding

Interventions	No. of patients
Right colectomy	9
Small bowel resection	7
Portocaval shunt	4
Left hemicolectomy	3
Subtotal colectomy	2
Anastomosis resection	1
Gastrectomy	1
Meckel resection	1
Duodenotomy	1
Resection of a duodenal diverticulum	1

The final diagnosis was cecal angiodysplasia and we concluded that the erroneous retrospective evaluation was due to motion artifacts.

Discussion

Angiography can localize the site of active bleeding to 0.5–1 ml/min [11, 12], which corresponds approximately to 3 U of blood per day [13]. Identification of a focal bleeding point depends on the hemodynamic condition

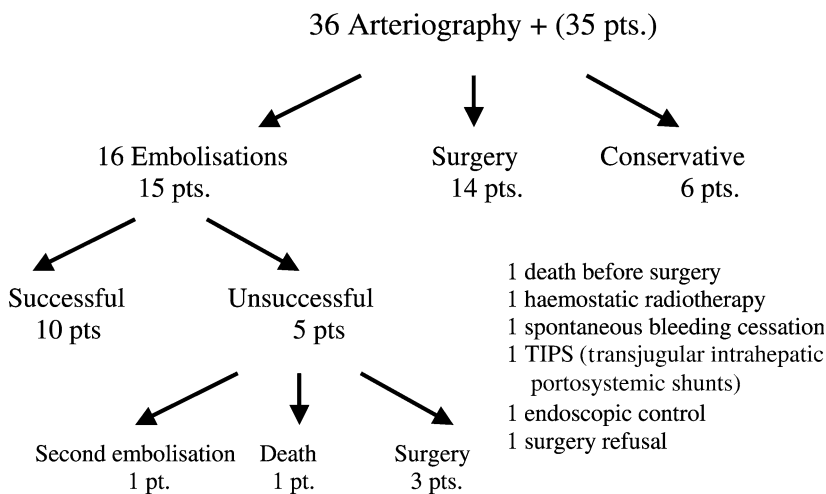


Fig. 6. Treatment modalities for patients with positive arteriogram.

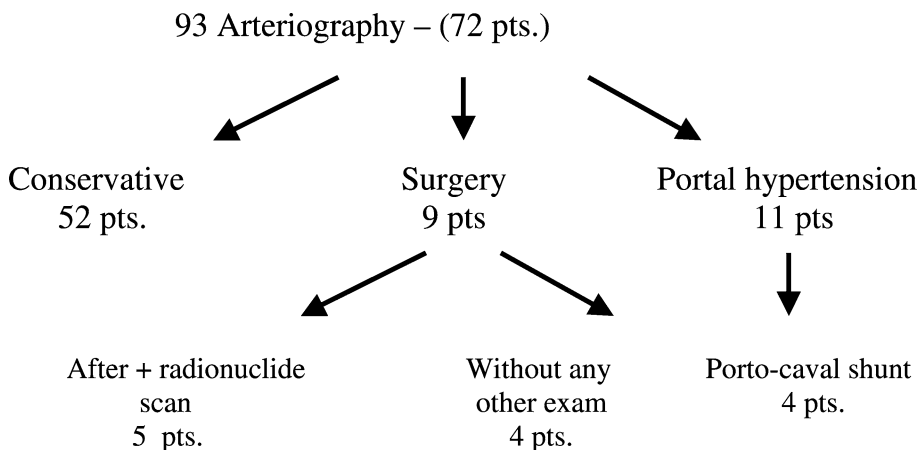


Fig. 7. Treatment modalities for patients with negative arteriogram.

of the patient at the time of angiography [14]. Clinically, an initial heart rate of 100 beats/min or higher, an initial systolic blood pressure of 115 mmHg or lower, and a history of syncope are some of the independent signs of severity in lower gastrointestinal bleeding [3] and signs of shock (class III or IV hemorrhages) [15]. The fact that all patients with a direct angiographic sign had hypotension illustrates this point. In patients with such clinical conditions, the probability that angiography will be positive is the highest. These clinical manifestations are essential considerations in the assessment of patients as candidates for angiography.

The most frequent sign for positive arteriography is contrast medium extravasation (direct sign). This sign was mainly associated with diverticular disease, owing to the prevalence of this disease in the studied population (nearly 50% of the patients who are hospitalized with acute gastrointestinal hemorrhage have bleeding related to diverticulosis [16]). In our study, similar to the indirect sign of an early filling vein, extravasation was most frequently present at the level of the right colon, where angiodysplasia and diverticular bleeding are often localized.

Table 4. Previous series of angiographies in management of acute gastrointestinal bleeding

Reference	Year	No. of patients	% Positive angiograms
Bonacker et al. [28]	2003	37	28
Brackman et al. [17]	2003	31	19
Al Ghahtani et al. [21]	2002	31	19
Nicholson et al. [14]	1998	38	37
Pennoyer et al. [26]	1996	131	28
Leitmani et al. [29]	1989	68	40
Koval et al. [30]	1987	63	78
Browder et al. [31]	1986	27	72
Britt et al. [32]	1983	28	58
Colacchio et al. [33]	1982	98	41

Endoscopy is the first step in the management of upper gastrointestinal bleeding. For lower gastrointestinal bleeding, angiography may be the first diagnostic study in patients with **massive** bleeding [10]. Although angiography was the first diagnostic method in only 1% of patients in the study by Brackman et al. [17], in our series angiography was selected as a first diagnostic choice in nearly 12% of patients with lower gastrointestinal bleeding (10 of 82). Emergency endoscopy for lower gastrointestinal bleeding may be difficult because stool

or blood in the colon may preclude adequate inspection of the mucosa. Although purging may clear retained blood and clots, active bleeding frequently quickly fills up the lumen and handicaps the examination [18]. Moreover, colonoscopy has to be deferred until patients are hemodynamically stable and have adequate colonic preparation [18]. Finally, a source of bleeding in the small bowel (in all cases of gastrointestinal hemorrhage, 3–5% originate from the small intestine [19]) is poorly accessible to endoscopic investigations. Therefore, patients with **massive** lower gastrointestinal bleeding generally require emergency mesenteric angiography to **localize** and/or **control the bleeding** site [19]. Accurate presurgical localization of the bleeding site decreases postoperative rates of morbidity and mortality [20]. With lower gastrointestinal bleeding, 10% to 15% of patients require surgery according to the literature [21]. In our series, 28% who had lower gastrointestinal bleeding (23 of 82) underwent surgery.

We performed 16 embolizations, which were the definitive treatments for 11 patients. Only selective and superselective embolizations were performed (we did not use infusion of intra-arterial vasopressin as an alternative). Three patients underwent surgery for recurrent bleeding after the site of hemorrhage had been localized.

In upper gastrointestinal bleeding, endoscopic therapy will achieve hemostasis in 80% of patients [19]. Patients who have upper gastrointestinal bleeding, who are not surgical candidates (comorbid illness), and in whom endoscopic techniques have failed are candidates for angiographic control of bleeding [22, 23]. In these cases, angiography is often the last therapeutic option. Very few embolizations have been conducted with this indication in our series. Most of our upper hemorrhages were related to **varicose** bleeding without extravasation at arteriography and the results of Ljungdal et al. [24] (embolization and permanent hemostasis achieved in all but one patient who had ulcerative gastric or duodenal disease) are not applicable to our group. In another study [25], arterial embolization for upper gastrointestinal bleeding was effective in 99%, with a periprocedural mortality rate of 35%.

There was no mortality related to arteriography and embolization. The complication rate was 2% and limited to local complications. In the literature, the reported complication rate for diagnostic arteriography in acute gastrointestinal bleeding is approximately 2–4% [20, 26, 27].

Thirty-one percent of angiographies were positive. Although the review by Zuckermann and Prakash [11] reported that the rate of positive angiograms varied from 27% to 77%, our results (concerning a large number of patients) are comparable to those of recent series (Table 4). To increase the positive rate, we could improve the indications by selecting patients who have massive ongoing bleeding early in the course of management.

In conclusion, abdominal arteriography may localize gastrointestinal bleeding sources in approximately one-third of cases. Selective embolization, when indicated, may provide definitive hemostasis in most instances.

References

1. Rockall TA, Logan RFA, Devlin HB, Northfield TC (1995) Incidence of, mortality from acute upper gastrointestinal haemorrhage in the United Kingdom. *BMJ* 311:22–226
2. British Society of Gastroenterology Endoscopy Committee (2002) Non-variceal upper gastrointestinal haemorrhage: guidelines. *Gut* 51:iv1–iv6
3. Strate LL, Orav EJ, Syngal S (2003) Early predictors of severity in acute lower intestinal tract bleeding. *Arch Intern Med* 163:838–843
4. Longstreth GF (1997) Epidemiology and outcome of patients hospitalized with acute lower gastrointestinal haemorrhage: a population-based study. *Am J Gastroenterol* 92:419–424
5. Podila PV, Ben-Menachem T, Batra SK, et al. (2001) Managing patients with acute, nonvariceal gastrointestinal haemorrhage: development and effectiveness of a clinical care pathway. *Am J Gastroenterol* 96:208–219
6. Nusbaum M, Baum S (1963) Radiographic demonstration of unknown sites of gastrointestinal bleeding. *Surg Forum* 14:374–375
7. Rosch J, Dotter CT, Brown MJ (1972) Selective arterial embolisation: a new method for control of acute gastrointestinal bleeding. *Radiology* 102:303–306
8. Carey LS, Grace DM (1974) The brisk bleed: control by arterial catheterization and gelfoam plug. *J Can Assoc Radiol* 25:113–115
9. Gianturco C, Anderson JH, Wallace S (1975) Mechanical devices for arterial occlusion. *AJR* 124:428–435
10. Bar AH, DeLaurentis DA, Parry CE, Keohane RB (1980) Angiography in the management of massive lower gastrointestinal tract haemorrhage. *Surg Gynecol Obstet* 150:226–228
11. Zuckerman GR, Prakash C (1998) Acute lower intestinal bleeding. Part one: clinical presentation and diagnosis. *Gastrointest Endosc* 48:606–615
12. Bloomfield RS, Rockey DC (2000) Diagnosis and management of lower gastrointestinal bleeding. *Curr Opin Gastroenterol* 16:89–97
13. Porter DH, Kim D (1997) Angiographic intervention in upper gastrointestinal bleeding. In: Taylor MB, Gollan JL, Steer ML, (eds). *Gastrointestinal emergencies*. Baltimore: Williams & Wilkins, 163–180
14. Nicholson AA, Ettles DF, Hartley JE, et al. (1998) Transcatheter coil embolotherapy: a safe and effective option for major colonic haemorrhage. *Gut* 43:79–84
15. American College of Surgeons Committee on Trauma (1997) Advanced Trauma Life Support® for doctors (ALS®) Chicago: ATLS, 94–95
16. Gostout CJ (2000) The role of endoscopy in managing acute lower gastrointestinal bleeding. *N Engl J Med* 342:125–127
17. Brackman MR, Gushchin V, Smith L, et al. (2003) Acute lower gastroenteric bleeding retrospective analysis (the ALGEBRA study): an analysis of the triage, management and outcomes of patients with acute lower gastrointestinal bleeding. *Am Surg* 69:145–149
18. Angtuaco TL, Reddy SK, Drapkin S, et al. (2001) The utility of urgent colonoscopy in the evaluation of acute lower gastrointestinal tract bleeding: a 2-year experience from a single center. *Am J Gastroenterol* 96:1782–1785
19. Ghosh S, Watts D, Kinnear M (2002) Management of gastrointestinal haemorrhage. *Postgrad Med J* 78:4–14
20. Zuccaro G (1998) Management of the adult patient with acute lower gastrointestinal bleeding. *Am J Gastrointest* 93:1202–1208
21. Al Gahtani AR, Sathi R, Stern J, Gordon PH (2002) Investigative modalities for massive lower gastrointestinal bleeding. *World J Surg* 26:620–625
22. Gostout CJ (2000) Gastrointestinal bleeding in the elderly patient. *Am J Gastrointest* 95:590–595
23. Lefkowitz Z, Cappell MS, Lookstein R, et al. (2002) Radiologic diagnosis and treatment of gastrointestinal haemorrhage and ischemia. *Med Clin North Am* 86:1357–1399

24. Ljungdahl M, Eriksson LG, Nyman R, Gustavsson S (2002) Arterial embolisation in management of massive bleeding from gastric and duodenal ulcers. *Eur J Surg* 168:384–390
25. Aina R, Oliva VL, Therasse E, et al. (2001) Arterial embolotherapy for upper gastrointestinal haemorrhage: outcome assesment. *J Vasc Interv Radiol* 12:195–200
26. Pennoyer WP, Vignati PV, Cohen JL (1996) Management of angiogram positive lower gastrointestinal haemorrhage: long term follow-up of non-operative treatments. *Int J Colorect Dis* 11:279–282
27. Vernava AM, Moore BA, Longo WE, Johnson FE (1997) Lower gastrointestinal bleeding. *Dis Colon Rectum* 40:846–858
28. Bonacker MJ, Begemann PGC, Dieckmann C, et al. (2003) Stellenwert der Angiography in der Diagnose und Therapie gastrointestinaler Blutungen. *Fortschr Roentgenstr* 175:524–531
29. Leitman IM, Paull DE, Shires T (1989) Evaluation and management of massive lower gastrointestinal haemorrhage. *Ann Surg* 209:175–180
30. Koval G, Benner KG, Rosch J, Kozak BE (1987) Aggressive angiographic diagnosis in acute lower gastrointestinal haemorrhage. *Dig Dis Sci* 32:248–253
31. Browder W, Cerise EJ, Litwin MS (1986) Impact of emergency angiography in massive lower gastrointestinal bleeding. *Ann Surg* 204:530–536
32. Britt LG, Warren L, Moore OF (1983) Selective management of lower gastrointestinal bleeding. *Am Surg* 49:121–125
33. Colacchio TA, Forde KA, Patsos TJ, Nunez D (1982) Impact of modern diagnostic methods on the management of active rectal bleeding. *Am J Surg* 143:607–510