



Article scientifique

Article

2013

Published version

Open Access

This is the published version of the publication, made available in accordance with the publisher's policy.

Combined orthodontic and orthognathic surgical treatment for the correction of skeletal anterior open-bite malocclusion: a systematic review on vertical stability

Solano-Hernández, Belén; Antonarakis, Gregory Stylianos; Scolozzi, Paolo; Kiliaridis, Stavros

How to cite

SOLANO-HERNÁNDEZ, Belén et al. Combined orthodontic and orthognathic surgical treatment for the correction of skeletal anterior open-bite malocclusion: a systematic review on vertical stability. In: Journal of oral and maxillofacial surgery, 2013, vol. 71, n° 1, p. 98–109. doi: 10.1016/j.joms.2012.03.016

This publication URL: <https://archive-ouverte.unige.ch/unige:29244>

Publication DOI: [10.1016/j.joms.2012.03.016](https://doi.org/10.1016/j.joms.2012.03.016)

Combined Orthodontic and Orthognathic Surgical Treatment for the Correction of Skeletal Anterior Open-Bite Malocclusion: A Systematic Review on Vertical Stability

Belén Solano-Hernández, BSH (DDS),*

Gregory Stylianos Antonarakis, GSA (BSc, DDS, MSc),†

Paolo Scolozzi, PS (MD, DMD),‡ and

Stavros Kiliaridis, SK (DDS, PhD)§

Purpose: To evaluate vertical stability after combined orthodontic surgical treatment of skeletal anterior open-bite malocclusion.

Materials and Methods: A literature search was performed to locate studies pertaining to vertical stability after combined orthodontic surgical treatment of skeletal anterior open-bite malocclusion. Data from the identified studies were extracted and assessed for quality. Short-term and long-term changes in the following variables were evaluated: overbite; mandibular plane, palatal plane, and intermaxillary angles; and anterior facial height.

Results: Nine studies, all retrospective, were appropriate for inclusion after review. The postoperative follow-up period ranged from 1 to 18 years. A wide variation was present for post-treatment changes and relapse. Dentally, overbite changes showed a wide variation, with more long-term relapse observed in patients after Le Fort I osteotomy. Skeletally, the mandibular plane and intermaxillary angles showed greater long-term relapse after bimaxillary surgery than after Le Fort I osteotomy. The same trend was seen for the post-treatment increase in anterior facial height. In contrast, the palatal plane seemed to remain rather stable.

Conclusions: Vertical relapse is a characteristic in a certain number of patients after combined orthodontic surgical treatments regardless of surgery type. This can be observed dentally by an opening of the bite and skeletally by an increase in the mandibular plane and intermaxillary angles during long-term follow-up. Long-term skeletal relapse seems to be more common after bimaxillary surgery.

© 2013 American Association of Oral and Maxillofacial Surgeons

J Oral Maxillofac Surg 71:98-109, 2013

Received from the Department of Orthodontics, University of Geneva, Geneva, Switzerland.

*Research Fellow.

†Assistant Professor.

‡Professor and Chair, Department of Oral and Maxillofacial Surgery, University Hospitals of Geneva, Geneva, Switzerland.

§Professor and Chair.

Drs. Solano-Hernández and Antonarakis contributed equally to this work.

Address correspondence and reprint requests to Dr Solano-Hernández: Department of Orthodontics, Dental School, University of Geneva, 19 Rue Barthélemy-Menn, 1205 Geneva, Switzerland; e-mail: belensolanohernandez@gmail.com

© 2013 American Association of Oral and Maxillofacial Surgeons

0278-2391/13/7101-0\$36.00/0

<http://dx.doi.org/10.1016/j.joms.2012.03.016>

The correction of anterior open-bite malocclusion in adult patients is a great challenge in orthodontic therapy.¹ Anterior open bite in children is usually treated by a combination of orthopedic and orthodontic approaches.² However, when the major growth potential of the patient has been completed, the treatment solution consists primarily of a combination approach using orthodontics, surgery, and repositioning of the maxilla and/or the mandible.³

The prevalence of anterior open bite has been found to be 2.9% in an adult Caucasian American population.⁴ The percentage of people in an orthodontic setting who consult an orthodontist and present this problem has been reported to be around 17%. Only about 16% of these patients receive orthognathic surgery.⁵ The etiology of an anterior open bite can be attributed to many factors but most often is caused by an aberrant growth pattern, which implies

a rotation of the jaws or an excessive eruption of posterior teeth. From cephalometric analysis, the major indicators of a skeletal relation that may predispose an individual to acquiring an anterior open bite (the “skeletal open-bite” pattern) are a short mandibular ramus and a downward rotation of the posterior maxilla.³

Numerous surgical techniques have been used for the correction of these types of deformities separately in the maxilla or the mandible or using bimaxillary techniques. It is a general consensus that the procedures used in the treatment of an anterior open bite are more difficult and less predictable than those aimed at rectifying other dentofacial deformities.⁶ In fact, after an initially successful correction of the vertical dimension by a combined orthodontic and orthognathic surgical treatment, some patients with a primary anterior open bite may, after the completion of treatment, exhibit a decrease in the overbite or the reappearance of an anterior open bite.⁷ This phenomenon is referred to as *vertical relapse*. To the best knowledge of the authors, no systematic review has been undertaken aiming to collect the available data in the literature focusing on the correction of an anterior open bite by orthodontics and orthognathic surgery and its potential for relapse.

The cause of vertical relapse is thought to have skeletal and dentoalveolar components, and its etiology is considered multifactorial.⁸ One of the factors that determines the vertical postsurgical relapse potential seems to be the osteotomy fixation technique. In earlier years, maxillary osteotomies were stabilized using intraosseous wires with or without infraorbital, circumzygomatic, or piriform rim suspension wires,⁹⁻¹² and mandibular ramus osteotomies were stabilized using superior and inferior border wiring.¹³ In the 1980s, rigid fixation techniques using miniplates and/or screws were introduced in an attempt to decrease postsurgical relapse.¹⁴⁻¹⁸ The short- and long-term outcomes of different fixation techniques are a topic of interest in the orthodontic literature.

The aim of the present study was to systematically review the published data on vertical stability after combined orthodontic and orthognathic surgical treatment to correct a skeletal anterior open-bite malocclusion using different approaches in surgical techniques and fixation. The specific research questions were:

- What is the amount of relapse (dental or skeletal) after a combined orthodontic and surgical correction of an open-bite deformity in the short- and long-term follow-up periods?
- Does the stability of the treatment outcome depend on the types of surgical techniques used?

- Is there any difference in the outcome and stability resulting from the different approaches to fixation (rigid internal fixation/rigid fixation [RF] vs wire fixation [WF])?

Materials and Methods

Systematic reviews locate, appraise, and synthesize the evidence from scientific studies to provide informative answers to scientific questions by including a comprehensive summary of the available evidence.¹⁹

SEARCH STRATEGY

A literature search was performed to identify published studies examining the outcomes of orthodontics and orthognathic surgery to correct anterior open-bite malocclusion using the following electronic databases:

- PubMed (from 1966 to the first week of September 2010)
- MEDLINE (from 1950 to the first week of September 2010)
- Google Scholar Beta (to the first week of September 2010)
- Scopus (from 1966 to the first week of September 2010)
- Web of Knowledge (from 1900 to the first week of September 2010)
- EMBASE Excerpta Medica (from 1980 to the first week of September 2010)
- CENTRAL of the Cochrane Library (to the 1st week of September 2010)

Free text words and Medical Subject Heading terms were used, and the following terms were included: *open bite*, *bilateral sagittal split osteotomy*, *mandibular surgery*, *maxillary surgery*, *bimaxillary surgery*, and *orthognathic surgery*. The search was expanded using the Related Articles function in PubMed to locate lists of articles consulted and the names of individual investigators who have worked in this field. Reference lists of the studies located were manually searched for additional relevant studies not found in the electronic search.

The titles and abstracts of all potentially relevant articles were reviewed. The full texts of all relevant articles and those with ambiguous titles and abstracts were collected. Each article was reviewed independently by 2 investigators, and the information was compared. Any difference between readers was resolved by rereading and discussion to reach a consensus.

SELECTION CRITERIA

The following inclusion criteria were chosen initially to select potentially relevant articles from the published abstract results: 1) human clinical trials; 2) lateral cephalograms (postoperative and after follow-up) used for assessing vertical stability, with the inclusion of certain measurements; and 3) a follow-up period of at least 12 months. Studies looking at genioplasty were accepted. Studies were excluded if they 1) pertained to syndromic, medically compromised, or otherwise diseased patients or 2) were in the form of case reports, case series, included fewer than 10 patients, or were descriptive studies, review articles, or opinion articles.

Studies were divided into those articles with short-term follow-up and those with long-term follow-up. A 2-year follow-up cutoff value was chosen to differentiate short- from long-term follow-up. In cases where there was more than 1 publication of the same patient group for the same postoperative follow-up period, the most informative and relevant article was included. For studies in which more than 1 report had been published on the same material at different times, only the most recent publication based on the longest follow-up period was included.

DATA EXTRACTION

The data were extracted and methodologically assessed for quality independently by 2 investigators. The data were recorded on specially designed data extraction forms. The abstracts were reviewed without considering the number of patients reported. Articles that apparently fulfilled the inclusion criteria and articles for which the title or abstract did not present enough information to exclude the study were obtained in full text. Subsequently, if the article was to be included in the present study, the following data were extracted from the full-text articles: authors; journal of publication; year of publication; where the study was carried out; study design; length of follow-up period; number and mean age of patients; ethnic background of patients and in what setting they were collected; presence of an error of the method analysis; number of surgeons operating; type of fixation; type of surgery (ie, Le Fort I, bilateral sagittal split osteotomy [BSSO], bimaxillary surgery, or genioplasty); presence of adjunctive orthodontic treatment; use of an intraoperative splint; the presence of postoperative radiographs; type of malocclusion, including the definition of open bite used; and cephalometric changes in the following variables: overbite, mandibular plane angle in reference to the Sella-Nasion (SN) plane, palatal plane angle in reference to the SN plane, intermaxillary angle, anterior facial height, and vertical movement of the upper and lower first molars (in reference to the SN and man-

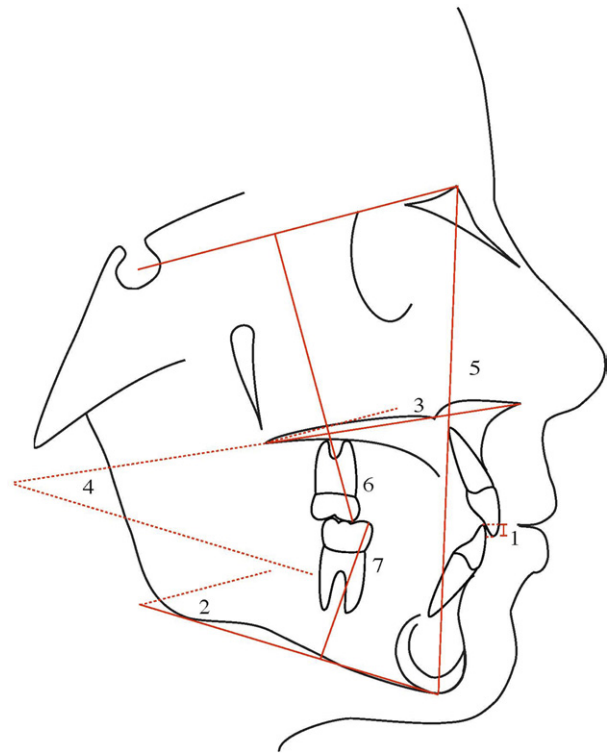


FIGURE 1. Cephalometric variables used to evaluate follow-up changes: 1, overbite; 2, mandibular plane angle; 3, palatal plane angle; 4, intermaxillary angle; 5, anterior facial height; 6, upper first molar; 7, lower first molar.

Solano-Hernández et al. Vertical Stability of Open-bite Treatment. J Oral Maxillofac Surg 2013.

dibular planes, respectively). Changes in molars were included only if the postoperative radiographs were taken after the orthodontic treatment and not after the orthognathic surgical procedure, because postsurgical orthodontics can also affect the position of these teeth. The cephalometric variables investigated are shown in Figure 1.

To assess the methodologic soundness of each article, a quality evaluation was used according to a scoring system developed by the Swedish Council on Technology Assessment in Health Care,²⁰ which is based on the criteria for assessing study quality from the Center for Reviews and Disseminations in the UK.²¹ The external and internal validities and the quality of methodology, statistics, and performance of each study were assessed, and the studies were graded with a score of A to C according to predetermined criteria (Table 1). If there was a discrepancy regarding study inclusion, quality evaluation, or extracted data between the investigators, a consensus decision was reached after discussion.

SEMIQUANTITATIVE ANALYSIS

A semiquantitative analysis of changes was performed where the percentage of patients, collected

Table 1. CRITERIA FOR GRADING OF ASSESSED STUDIES

Grade (Value of Evidence)	Criteria
Grade A—high value of evidence	All criteria should be met: randomized clinical study or prospective study with well-defined control group; defined diagnosis and endpoints; diagnostic reliability tests and reproducibility tests described; blinded outcome assessment
Grade B—moderate value of evidence	All criteria should be met: cohort study or retrospective case series with defined control or reference group; defined diagnosis and endpoints; diagnostic reliability tests and reproducibility tests described
Grade C—low value of evidence	≥1 of the following conditions should be met: large attrition; unclear diagnosis and endpoints; poorly defined patient material

Solano-Hernández et al. Vertical Stability of Open-bite Treatment. J Oral Maxillofac Surg 2013.

from all the studies combined, who showed changes in either direction (positive or negative) was calculated. The patients were divided into the percentages of those who showed a positive change and those who showed a negative change. A difference in 20% of patients, between those showing a positive change and those showing a negative change, was considered important because any value smaller than this was considered part of the normal distribution of changes (mean, approximately 0; no change).

Subsequently, the percentage of patients who showed a change smaller than 2 mm or 2° was calculated. This cutoff value was established after taking into account the error of the method inherent to tracing lateral cephalometric radiographs. A difference in 10% of patients, between those showing a positive change and those showing a negative change larger than 2 mm or 2°, was considered important because any value smaller than this was considered part of the normal distribution of changes (mean, approximately 0; no change).

Results

SEARCH RESULTS

The search strategy resulted in 1,252 articles. The number of abstracts selected according to the appli-

cation of the inclusion and exclusion criteria was 79 (Table 2). This included abstracts that were obtained in duplicate from the various electronic database searches. The titles of the eliminated 1,173 articles were not related or relevant to the topic of interest. A Quality of Reporting Meta-Analyses flow diagram (Fig 2) provides an overview of the selection process. A manual search of the references showed 13 additional studies for examination. Forty-six abstracts were finally selected, 41 of which were derived from the electronic search and another 5 from the manual search. Full-text versions were obtained, and 31 articles were considered appropriate to include. After further appraisal, 22 of these articles were rejected because the patients had undergone other types of surgery or the exact surgical procedure was not described,^{22,23} results for Le Fort I and BSSO surgery were combined,^{24,25} the follow-up period was shorter than 12 months,^{26,27} the studied variables were not exactly those in question,^{9,28-30} insufficient patient and/or surgical data were presented,³¹⁻³⁹ the inclusion criteria were not completely fulfilled,^{40,41} the studies were in the form of cases reports,⁴² or the studies were in the form of reviews of the literature.⁴³ Therefore, 9 suitable studies (8 articles from the electronic database search and 1 article from the manual search) were included.

Table 2. SEARCH RESULTS FROM ELECTRONIC DATABASES

Database	Abstract Series Found	Abstract Series Selected	Abstract Not in PubMed
PubMed	489	64	—
MEDLINE	341	7	0
Google Scholar Beta	99	0	0
EMBASE Excerpta Medica	23	0	0
Scopus	159	4	0
Web of Science	141	4	0
Cochrane	0	0	0
Total	1,252	79	—

Solano-Hernández et al. Vertical Stability of Open-bite Treatment. J Oral Maxillofac Surg 2013.

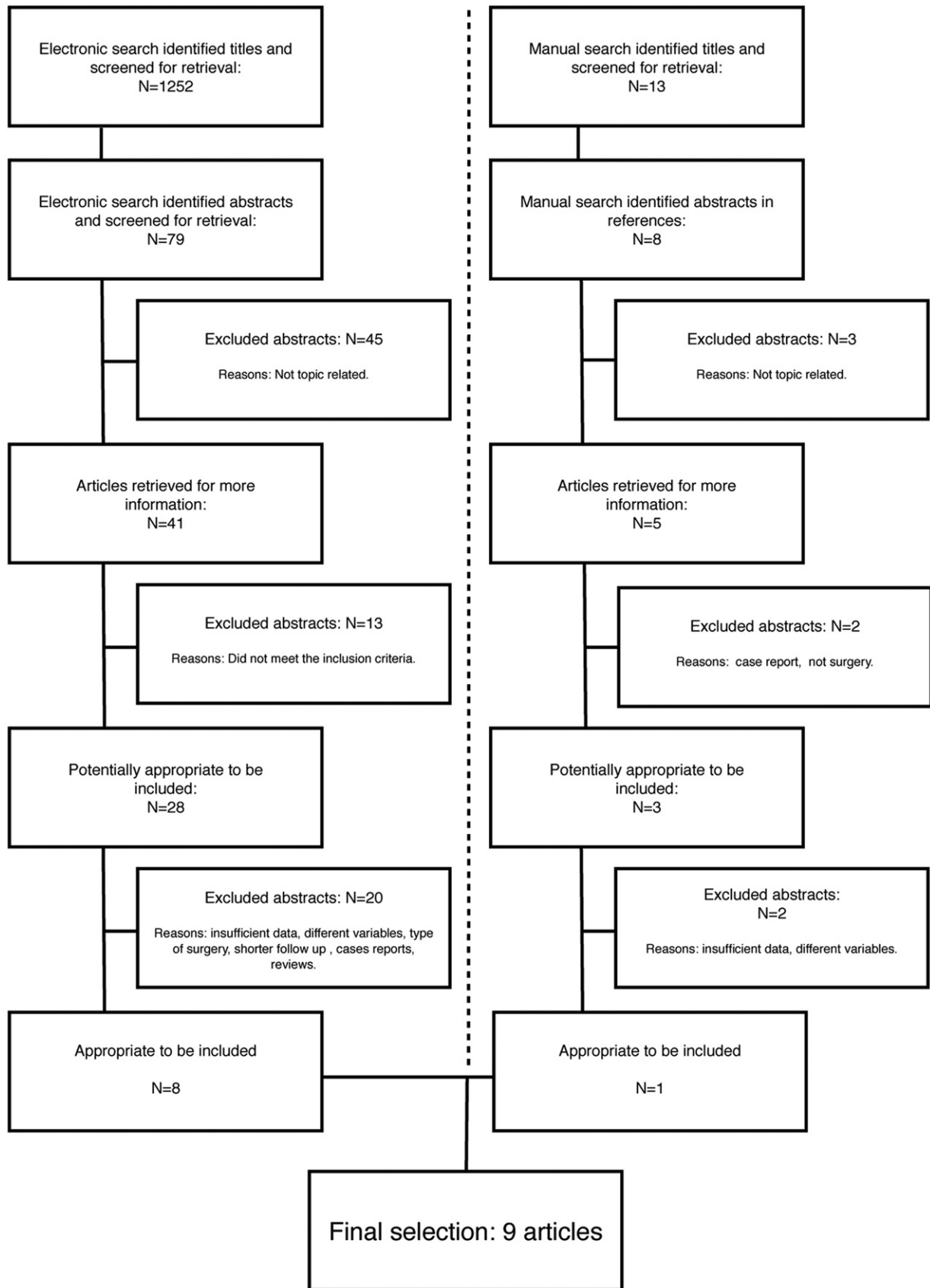


FIGURE 2. Quality of Reporting Meta-Analyses flow diagram.

DATA COLLECTION AND QUALITY ANALYSIS

Details of the 9 included studies and the research quality or methodologic soundness are presented in Table 3.^{6,7,44-50} Using the quality evaluation according to the Swedish Council on Technology Assessment in Health Care,²⁰ most of these studies were scored as grade C (low value of evidence) and only 2 were ranked as B (moderate value of evidence). None were graded as having a high value of evidence (grade A). All studies were retrospective in design. A substantial limitation of most studies was that the samples in general were small. Only the study by Hoppenreijns et al⁶ presented a larger sample (267 patients). This finding implies the low power of the included studies, which was accompanied by other limitations, notably a lack of error of the method analyses, no blinding of measurements, and a deficient or lack of statistical analyses. None of the studies mentioned the use of a power analysis. Five studies were judged to have an adequate sample size (30 to >250).^{6,44-47} The ethnic background of the patients was not available in all the reviewed studies. Four of the studies did not include an error of the method analysis or it was not reported.^{7,44,48,49} None of the studies used blinding in the measurements. When considering the concomitant use of a genioplasty, 6 studies declared that an additional genioplasty was performed in some patients.^{6,44-46,49,50}

FOLLOW-UP PERIOD

The follow-up period was the period from the postoperative (postsurgical or post-treatment) lateral cephalometric radiograph to the lateral cephalometric radiograph after follow-up. The postoperative lateral cephalometric radiographs were taken after surgery and not after orthodontic treatment except for 2 studies^{7,48} that obtained post-treatment lateral cephalograms. The follow-up period was 12 months⁵⁰ for the study using BSSO procedures, ranging from 12 months^{44,47,48} to 69 months⁶ for studies using Le Fort I procedures, and from 12 months⁴⁹ to longer than 72 months⁴⁹ for studies using bimaxillary surgery procedures. For the BSSO group, the long-term follow-up was not recorded.

SEMIQUANTITATIVE ANALYSIS

The amount of dental relapse after a combined orthodontic and surgical correction of an open-bite deformity in the short term, based on overbite changes, was seen in approximately 13% of patients treated with BSSO. The other surgery types showed a normal distribution of changes (mean, approximately 0). Skeletally, there was a short-term relapse in the mandibular plane angle in 60% of patients treated with bimaxillary surgery, but no important short-term

change with the other surgery types. The intermaxillary angle showed a short-term relapse in 23% and 53% of patients after Le Fort I osteotomy and bimaxillary surgery, respectively. Anterior facial height showed an important change in the short term only after bimaxillary surgery, with a decrease seen in approximately 33% of patients. The palatal plane did not show an important relapse in the short term (Tables 4 and 5).

Long-term dental relapse, based on overbite changes, after a combined orthodontic and surgical correction of an open-bite deformity was seen in approximately 16% of patients treated with Le Fort I osteotomy. Bimaxillary surgery showed a normal distribution of changes (mean, approximately 0). Skeletally, there was a long-term relapse in the mandibular plane angle in 37% and 56% of patients treated with Le Fort I osteotomy and bimaxillary surgery, respectively. The intermaxillary angle showed a long-term relapse in 20% and 36% of patients after Le Fort I osteotomy and bimaxillary surgery, respectively. Anterior facial height showed a long-term relapse in 33% of patients after bimaxillary surgery and no important long-term change after Le Fort I surgery. The palatal plane did not show an important long-term change after any type of surgery (Tables 4 and 5).

STABILITY OF TREATMENT OUTCOME

The following post-treatment changes in the individual variables were examined.

Overbite

The short-term overbite changes for Le Fort I surgery ranged from a mean decrease of 1.0 mm⁴⁸ to an increase of 1.3 mm.⁴⁴ For BSSO surgery, only 1 study reported the overbite changes, with a resulting mean decrease of 0.6 mm.⁵⁰ For bimaxillary surgery, this value ranged from a mean decrease of 0.2 mm⁶ to an increase of 1.3 mm.⁴⁹

In the long-term follow-up, the change in overbite ranged from a mean decrease of 0.8 mm⁶ to an increase of 0.5 mm⁴⁴ for Le Fort I surgery. No long-term follow-up data were available for BSSO surgery. For bimaxillary surgery, long-term overbite changes ranged from a mean decrease of 0.5 mm⁴⁶ to an increase of 0.5 mm.⁴⁹

The 2 studies with overbite measurements from after orthodontic treatment to after follow-up showed a mean decrease in overbite of 0.3 mm⁷ in the long term (mean, 4.5 yrs) after orthodontics and bimaxillary procedures and a decrease in overbite of 1 mm⁴⁸ in the long term (median, 3 yrs) after orthodontics and Le Fort I surgical procedures. In the study with orthodontics and bimaxillary surgery, 7 of 19 patients (37%) showed a relapse in overbite (decrease, >1 mm). In the study with orthodontics and Le Fort I surgery, 12 of 28 patients

Table 3. OVERVIEW OF THE DESIGN OF INCLUDED STUDIES

Study	Year	Journal	Country	Study Design	Error of Method	Sample Size	Patient Collection	Age (yr)	Ethnic Background
Denison et al ⁴⁸	1989	<i>Angle Orthod</i>	USA	CT, R	NR	28	UW (private practices of faculty)	24 (12-42.1)	NR
Bailey et al ⁴⁴	1994	<i>Int J Adult Orthodon Orthognath Surg</i>	USA	CT, R	NR	49 (41 F, 8 M)	UNC	23.0 (SD 9.1)	NR
Miguel et al ⁴⁹	1995	<i>Int J Adult Orthodon Orthognath Surg</i>	USA	CT, R	Yes	26 (25 F, 1 M)	UNC	25.92 (14-40)	NR
Hoppenreijns et al ⁶	1997	<i>Int J Oral Maxillofac Surg</i>	Netherlands	CT, R	Yes	267 (210 F, 57 M)	*	23.6 (14.3-45.5)	NR
Arpornmaeklong and Heggie ⁴⁵	2000	<i>Aust Orthod J</i>	Australia	CT, R	Yes	37 (28 F, 9 M)	NR	21.7 (14-47)	NR
Fischer et al ⁴⁶	2000	<i>Eur J Orthod</i>	Sweden	CT, R	Yes	58 (40 F, 18 M)	SH	23 (14-49)	NR
Espeland et al ⁴⁷	2008	<i>Eur J Orthod</i>	Norway, Ireland	CT, R	Yes	40 (24 F, 16 M)	UO, surgery at UU	25.8 (SD 9.5, 16.2-52.2)	NR
Wriedt et al ⁷	2009	<i>J Orofac Orthop</i>	Germany	CT, R	NR	19 (13 F, 6 M)	†	21.2 (17-30)	NR
Stansbury et al ⁵⁰	2010	<i>J Oral Maxillofac Surg</i>	USA	CT, R	Yes	28 (22 F, 6 M)	Oral surgeon's office	29.2 (14.0-54.6)	NR

Abbreviations: BSSO, bilateral sagittal split osteotomy; CT, clinical trial; F, female; LFI, Le Fort I; M, male; NR, not reported; OB, overbite; R, retrospective; RF, rigid fixation; SD, standard deviation; SH, Maxillofacial Surgery Clinic, Sabbatsbergs Hospital, Stockholm, Sweden; UNC, University of North Carolina; UO, Department of Orthodontics, University of Oslo, Oslo, Norway; UU, Ullevaal University Hospital, Oslo, Norway; UW, University of Washington; WF, wire fixation.

*Oral and Maxillofacial Surgery, University Hospital, Nijmegen, Netherlands (n = 72); Rijnstate Hospital, Arnhem, Netherlands (n = 72), or Free University Hospital, Amsterdam, Netherlands (n = 123).

†Departments of Orthodontics and Oral and Maxillofacial Surgery, University Medical Center, Johannes Gutenberg University, Mainz, Germany.

Solano-Hernández et al. Vertical Stability of Open-bite Treatment. *J Oral Maxillofac Surg* 2013.

(43%) showed a decrease in overbite, whereas 6 (21%) showed a reopening of their anterior open bite beyond the incisal overlap.

Molar Position

Changes in the first maxillary and mandibular molars are not included in the semiquantitative analysis because only Denison et al⁴⁸ obtained lateral cephalograms after orthodontic treatment as opposed to after surgery and examined the position of the first molars. They found an average extrusion of 1.3 mm for the maxillary molars and an extrusion of 0.5 mm for mandibular molars after Le Fort I surgery in the long term.

Mandibular Plane Angle

The short-term changes in the mandibular plane angle for Le Fort I surgery were reported in only 1 study, where a mean plane angle closure of 0.4° was found.⁴⁴ Likewise, for BSSO surgery, only 1 study reported changes in the mandibular plane angle in the short term, resulting in a small mean closing of the plane angle of 0.1°.⁵⁰ For bimaxillary surgery, only 1

study reported these changes (mean, 2.9°; opening of the plane angle).⁴⁹

In the long-term follow-up, mean changes in the mandibular plane angle ranged from 1.2°⁴⁵ to 1.4°⁴⁴ for Le Fort I surgery and from 1.4°⁴⁶ to 2.9°⁴⁵ for bimaxillary surgery. All values denote an opening of the plane angle. No data were available concerning long-term changes in the mandibular plane angle after BSSO procedures.

Palatal Plane Angle

The short-term changes in the palatal plane angle for Le Fort I surgery ranged from a mean of -0.3°⁶ to 0.1°.⁴⁴ For BSSO and bimaxillary surgery, only 1 study reported short-term changes in the palatal plane angle for each procedure, with a mean opening of 0.1°⁵⁰ and a mean closing of 0.1°⁶ of the angle, respectively.

In the long-term follow-up, the mean changes ranged from -0.1° (closing)⁶ to 0.6° (opening)⁴⁵ for Le Fort I surgery and from -0.3° (closing)⁴⁶ to 0°⁶ for bimaxillary surgery; no data were found for BSSO surgery.

Table 3 (Cont'd). OVERVIEW OF THE DESIGN OF INCLUDED STUDIES

Malocclusion	Definition of OB	Orthodontics	Surgery	Surgeons	Segmental Surgery of Maxilla	Genioplasty	Fixation	Follow-Up	Judged Quality Standard
Class I or II	Overlap of maxillary and mandibular incisal edges	Yes	LFI	NR	NR	NR	WF	≥1 yr (1-11.9 yr)	B
NR	Long-face patients (skeletal OB)	NR	LFI	1 (n = 41), >1 (n = 8)	16 patients (33%)	Some cases	WF	5 yr	C
NR	Long-face patients (skeletal OB)	NR	LFI + BSSO	1	13 patients	7 patients	WF	6.66 yr (5.5-13.1 yr)	C
Class I or I/II	Anterior skeletal OB	Yes (n = 203)	LFI (n = 144), LFI + BSSO (n = 123)	>1	LFI (n = 67), LFI + BSSO (n = 25)	LFI (n = 68), LFI + BSSO (n = 68)	WF (n = 153), RF (n = 114)	69 mo (20-210 mo)	B
NR	Anterior skeletal OB	Yes	LFI (n = 17), LFI + BSSO (n = 20)	1 (n = 17), NA (n = 20)	LFI (n = 9), LFI + BSSO (n = 10)	LFI (n = 8), LFI + BSSO (n = 12)	RF	22.9 mo (12-90 mo)	C
Retrognathic mandible	Dental and/or skeletal OB	Yes	LFI + BSSO	2	19 patients	26 patients	WF/RF	2 yr	C
10 Class I, 13 Class II, 17 Class III	Anterior OB	Yes	LFI	5	No	No	RF	1-yr short term, 3-yr long term	C
NR	OB (<0 mm)	Yes	LFI + BSSO	NR	NR	NR	RF	≥2 yr, 4.5 yr (2-9 yr)	C
NR	Anterior OB (0 or negative vertical overlap of anterior teeth) immediately preoperatively	Yes	BSSO	1	No	7 patients	RF	12 mo	C

Solano-Hernández et al. Vertical Stability of Open-bite Treatment. J Oral Maxillofac Surg 2013.

Intermaxillary Angle

The short-term changes in the intermaxillary angle for Le Fort I surgery were reported in only 1 study, with a resulting mean opening of 0.7°. Similarly, for bimaxillary surgery, only 1 study reported short-term

changes in the intermaxillary angle, with a mean opening of 1.9°, whereas no data were available for BSSO surgery.

In the long-term follow-up, the intermaxillary angle was found to open by a mean of 0.7° for Le Fort I

Table 4. PERCENTAGE OF TOTAL PATIENTS WITH AN INCREASE OR DECREASE OF THE STUDIED VARIABLES

Variable Changes	OB (mm)		MP (°)		PP (°)		PP/MP (°)		Na-Me (mm)	
	↓	↑	↓	↑	↓	↑	↓	↑	↓	↑
Le Fort I										
ST	55%	45%	57%	43%	57%	43%	35%	65%	58%	42%
LT	61%	39%	24%	76%	52%	48%	38%	62%	19%	81%
BSSO										
ST	67%	33%	52%	48%	43%	57%	—	—	—	—
Bimaxillary										
ST	48%	52%	16%	84%	53%	47%	14%	86%	64%	36%
LT	57%	43%	24%	76%	51%	49%	30%	70%	30%	70%

Abbreviations: ↑, increase; ↓, decrease; BSSO, bilateral sagittal split osteotomy; LT, long term; MP, mandibular plane; Na-Me, anterior facial height; OB, overbite; PP, palatal plane; PP/MP, intermaxillary angle; ST, short term.

Solano-Hernández et al. Vertical Stability of Open-bite Treatment. J Oral Maxillofac Surg 2013.

Table 5. PERCENTAGE OF TOTAL PATIENTS WITH LARGER THAN A 2-MM OR 2° CHANGE

Variable Changes	OB (mm)			MP (°)			PP (°)			PP/MP (°)			Na-Me (mm)		
	↓ >2	↑ >2	≤2	↓ >2	↑ >2	≤2	↓ >2	↑ >2	≤2	↓ >2	↑ >2	≤2	↓ >2	↑ >2	≤2
Le Fort I															
ST	8%	8%	84%	21%	12%	67%	2%	9%	89%	7%	23%	70%	11%	20%	69%
LT	16%	6%	78%	5%	37%	58%	7%	6%	87%	5%	20%	75%	15%	21%	64%
BSSO															
ST	13%	2%	85%	8%	6%	86%	0%	0%	100%	—	—	—	—	—	—
Bimaxillary															
ST	5%	3%	92%	7%	60%	33%	2%	2%	96%	2%	53%	45%	33%	11%	56%
LT	12%	8%	80%	5%	56%	39%	12%	10%	78%	6%	36%	58%	8%	33%	59%

Abbreviations: ↑, increase; ↓, decrease; BSSO, bilateral sagittal split osteotomy; LT, long term; MP, mandibular plane; Na-Me, anterior facial height; OB, overbite; PP, palatal plane; PP/MP, intermaxillary angle; ST, short term.

Solano-Hernández et al. Vertical Stability of Open-bite Treatment. *J Oral Maxillofac Surg* 2013.

surgery and from 1°⁶ to 2.9°⁴⁵ for bimaxillary surgery. No data were found for BSSO surgery.

Gonial Angle

Limited data were available for changes in the gonial angle after open-bite surgery in the short or long term. Namely, a mean long-term closing of the angle of -1° for Le Fort I osteotomy and -0.3° for bimaxillary surgery was observed.⁴⁵

Anterior Facial Height

The short-term changes in anterior facial height ranged from a mean decrease of 1.5 mm⁴⁴ to an increase of 2.1 mm⁴⁸ for Le Fort I surgery. No data were available for BSSO surgery, and a mean decrease of 0.9 mm⁴⁹ was noted for bimaxillary surgery.

In the long-term follow-up, changes in anterior facial height ranged from a mean increase of 1.2 mm⁴⁵ to 1.4 mm⁴⁴ for Le Fort I surgery, a mean increase of 0.7 mm⁴⁵ to 1.5 mm⁴⁹ for bimaxillary surgery, and no data were found for BSSO surgery.

FIXATION

Comparing post-treatment outcomes and stability resulting from the different approaches with fixation was impossible because only 1 of the included studies compared types of fixation.

Discussion

Optimal treatment planning for skeletal anterior open-bite malocclusion in adults requires an understanding of the postoperative stability of the different possible approaches. This review aimed to summarize postoperative skeletal stability after surgical treatment of this malocclusion. The long-term stability of an anterior open bite after orthodontic or combined orthodontic-surgical treatment was addressed in a previous review,⁵¹ where the reviewer stated that the

level of evidence provided by the scientific literature was not conclusive because of the small samples studied, the potential for selection bias, and the considerable variation in the methodology of the studies.

The present review includes some, but not all, the studies mentioned in the review by Huang.⁵¹ Studies were not included because the studied variables were not the same as those that the authors were interested in,^{29,52} insufficient patient and/or surgical data were presented,^{31-33,35} the patients had undergone other types of surgery or the exact surgical procedure was not described,²³ there was a previous study^{44,49} in which the same material was used, and only the most recent publication based on the longest follow-up period was included.³ Conversely, the present study also included those articles published since 2002 that fulfilled the inclusion criteria.^{7,47,50}

From the results of the present study, it is evident that there is wide variation in post-treatment changes and relapse after a combined orthodontic and orthognathic surgical treatment approach to a skeletal anterior open bite. Overbite changes after treatment showed a wide variation, with a relapse (opening of bite, >2 mm) in 16% of patients followed long term after Le Fort I osteotomy, no important long-term changes after bimaxillary surgery, and relapses in 13% of patients followed short term after BSSO. One problem with the interpretation of the present results is that most studies used postsurgical lateral cephalometric radiographs as the baseline and not after orthodontic treatment, meaning that postsurgical orthodontics also could have influenced overbite changes in the initial postsurgical period, when the orthodontic forces were still in effect.

In regard to skeletal changes after treatment, the mandibular plane angle showed a trend toward an opening of the angle (>2°) and more so after bimaxillary surgery. This opening was evident in the short-term follow-up after bimaxillary surgery (in 60% of

patients) but only after long-term follow-up after Le Fort I osteotomy (in 37% of patients). In contrast, the palatal plane seemed to remain rather stable, with most patients showing a change smaller than 2°. The intermaxillary plane angle opened after treatment and more so after bimaxillary surgery than after Le Fort I osteotomy. This opening was evident after short-term follow-up in 53% of bimaxillary surgical patients compared with 23% of Le Fort I osteotomy patients. The anterior facial height seemed to show variable post-treatment results, with more patients showing an increase (>2 mm) after long-term follow-up in the bimaxillary group (33%).

When analyzing stability, the follow-up period needs to be carefully considered, because a too short follow-up would not be of much value. From the work by Moldez et al,³⁵ 12 months would seem to be an appropriate period after appliance removal to evaluate surgical stability. In consequence, the present review selected only studies with a minimum 1-year postoperative follow-up. Moreover, the evaluation of stability is made more complex by the fact that postoperative results, rather than results after treatment, are often reported. The included studies were subsequently divided into 2 categories: short-term and long-term follow-up, setting the cutoff value at 2 years. Unfortunately, this cutoff value could not be strictly applied to all studies, and thus the available data are not always clear-cut when dividing the patients in terms of follow-up period. For example, Denison et al⁴⁸ reported that 21.4% of patients treated with Le Fort I osteotomy exhibited reopening of the anterior open bite during the post-treatment period, when the patients presented no pretreatment overlap and no contact of the mandibular and maxillary incisal edges. However, the sample included patients followed from 1 to 11.9 years, which makes analyzing data in terms of the postoperative follow-up period rather difficult.

The age of the patients is another important factor to consider. Most studies included in the present review included patients who underwent surgical treatment before the end of the growth, with a large age range in the patients (12⁴⁸ to 54 yrs⁵⁰). In consequence, residual growth may affect the stability of the treatment outcomes. It also must be remembered that long-term growth in adults reflects a pattern of growth that is expressed in adolescence and continues to occur during adult life, although at a slower rate.⁵³ Continued vertical eruption also can play a role in post-treatment changes. Christou and Kiliaridis⁵⁴ found that eruption was a process that continued into adult life. There is no way to assure that the changes observed in a treated sample exceed what would have occurred if the subjects had received no treatment, especially without the inclusion of an untreated control group. However, the magnitude of the changes in

some postsurgical patients was greater than that observed by Behrents⁵³ over a much longer period, which may suggest that something more than unaltered growth has occurred.⁴⁴

Relapse of an anterior open bite may occur because of various factors, such as tongue size or posture, an unfavorable growth pattern, orofacial musculature, respiratory problems, careless orthodontic preparation, dental movements, and condylar resorption after orthognathic surgery.⁵⁵ However, the criteria for assessing the stability and relapse of the correction of an anterior open bite have not been defined quantitatively. This makes an evaluation of the results after treatment complicated. Moreover, when analyzing cephalometric variables, the findings are based on studies that usually have small samples or are based on a very limited number of studies, which makes drawing definitive conclusions difficult. One should note also that 50% of the values are smaller than 0.5° or 0.5 mm, and these small values are influenced by the cephalometric error of the method, which adds further limitations. Therefore, the authors chose to consider changes larger or smaller than 2° or 2 mm as the cutoff value, and differences of 10% between patients showing an increase or decrease as clinically important, as explained in Materials and Methods (Table 5).

The variability induced by having different surgeons carrying out the procedures further complicates the evaluation of stability. One previous report on mandibular surgery suggested that the identity of the surgeon is the single most important variable explaining postsurgical instability.⁵⁶

The type of fixation (RF or WF) and its influence on stability could not be easily analyzed. Only 1 of the included studies⁶ compared RF with WF. The authors of this study stated that internal plate fixation rendered better maxillary stability than intraosseous WF; however, results in the early postoperative period were masked by initial superior movement when using WF.⁶ They also found that mandibular stability in bimaxillary procedures was better in the early postoperative period when RF was performed.⁶ Fischer et al⁴⁶ stated that some of the relapse in the position of the incisors and the open bite may be attributed to incisor retroclination and the relatively short duration of fixed retention. Their study, however, did not differentiate between the outcomes of the 2 types of fixation. No conclusions could be drawn from the available studies, although clinical trends have shown an increase in the use of RF as opposed to WF.⁵⁷

A quality evaluation according to a scoring system developed by the Swedish Council on Technology Assessment in Health Care²⁰ was used as the basis to judge quality in the present systematic review. All the included studies were retrospective clinical trials. In

consequence, a meta-analysis using the existing data was impossible. To increase the power of this systematic review, it would have been necessary to include only randomized clinical trials, prospective multicenter studies, or prospective clinical trials. Unfortunately, the available scientific literature on this specific topic is scarce.

Despite a large number of studies on long-term stability after orthodontic treatment, this systematic review shows that evidence-based conclusions are few. This was caused most often by the inherent problems associated with retrospective studies and an inferior study design. There is a great need for well-designed prospective studies with untreated control groups, sufficient sample sizes, and sample selection according to factors such as type of malocclusion, age, growth pattern, and specific characteristics related to the surgical procedure and technique. Newer state-of-the-art techniques could also be used, such as cone-beam computed tomography or 3-dimensional imaging, to better assess and better quantify relapse and stability.

In conclusion, vertical relapse is a characteristic in a certain number of patients after combined orthodontic surgical treatment, regardless of the type of surgery used. This can be observed by an opening of the bite dentally and an increase in the mandibular plane and intermaxillary angles skeletally during long-term follow-up. Long-term skeletal relapse seems to be more common after bimaxillary surgery.

References

1. Sarver DM, Weissman SM: Nonsurgical treatment of open bite in nongrowing patients. *Am J Orthod Dentofacial Orthop* 108: 651, 1995
2. Cozza P, Mucedero M, Baccetti T, et al: Early orthodontic treatment of skeletal open-bite malocclusion: A systematic review. *Angle Orthod* 75:707, 2005
3. Proffit WR, Bailey LJ, Phillips C, et al: Long-term stability of surgical open-bite correction by Le Fort I osteotomy. *Angle Orthod* 70:112, 2000
4. Proffit WR, Fields HW, Moray LJ: Prevalence of malocclusion and orthodontic treatment need in the United States: Estimates from the NHANES III survey. *Int J Adult Orthodon Orthognath Surg* 13:97, 1998
5. Bailey LJ, Haltiwanger LH, Blakey GH, et al: Who seeks surgical-orthodontic treatment: A current review. *Int J Adult Orthodon Orthognath Surg* 16:280, 2001
6. Hoppenreijts TJ, Freihofer HP, Stoelinga PJ, et al: Skeletal and dento-alveolar stability of Le Fort I intrusion osteotomies and bimaxillary osteotomies in anterior open bite deformities. A retrospective three-centre study. *Int J Oral Maxillofac Surg* 26:161, 1997
7. Wriedt S, Buhl V, Al-Nawas B, et al: Combined treatment of open bite—Long-term evaluation and relapse factors. *J Orofac Orthop* 70:318, 2009
8. Ellis E III, McNamara JA Jr: Components of adult Class III open-bite malocclusion. *Am J Orthod* 86:277, 1984
9. Greebe RB, Tuinzing DB: Superior repositioning of the maxilla by a Le Fort I osteotomy: A review of 26 patients. *Oral Surg Oral Med Oral Pathol* 63:158, 1987
10. Krekmanov L, Lilja J, Ringqvist M: Simultaneous correction of maxillary and mandibular dentofacial deformities without the use of postoperative intermaxillary fixation. A clinical and cephalometric study. *Int J Oral Maxillofac Surg* 17:363, 1988
11. Lello GE: Skeletal open bite correction by combined Le Fort I osteotomy and bilateral sagittal split of the mandibular ramus. *J Craniomaxillofac Surg* 15:132, 1987
12. Rondahl US, Bystedt H, Enqvist B, et al: Changes after correction of maxillary retrusion by Le Fort I osteotomy. A comparison of 2 methods of skeletal fixation. *Int J Oral Maxillofac Surg* 17:165, 1988
13. Singer RS, Bays RA: A comparison between superior and inferior border wiring techniques in sagittal split ramus osteotomy. *J Oral Maxillofac Surg* 43:444, 1985
14. Hennes JA, Wallen TR, Bloomquist DS, et al: Stability of simultaneous mobilization of the maxilla and mandible utilizing internal rigid fixation. *Int J Adult Orthodon Orthognath Surg* 3:127, 1988
15. Larsen AJ, Van Sickels JE, Thrash WJ: Postsurgical maxillary movement: A comparison study of bone plate and screw versus wire osseous fixation. *Am J Orthod Dentofacial Orthop* 95:334, 1989
16. Rittersma J, van der Veld RG, van Gool AV, et al: Stable fragment fixation in orthognathic surgery: Review of 30 cases. *J Oral Surg* 39:671, 1981
17. Rosen HM: Miniplate fixation of Le Fort I osteotomies. *Plast Reconstr Surg* 78:748, 1986
18. Van Sickels JE, Nishioka GJ: Rigid fixation of maxillary osteotomies: A review of treatment results. *Oral Surg Oral Med Oral Pathol Oral Radiol Endod* 66:2, 1988
19. National Health Service (NHS) Centre for Reviews and Dissemination: Undertaking Systematic Reviews of Research on Effectiveness. York, UK, University of York, York Publishing Services, 2001
20. Bondemark L, Holm AK, Hansen K, et al: Long-term stability of orthodontic treatment and patient satisfaction. A systematic review. *Angle Orthod* 77:181, 2007
21. Deeks J, Glanville J, Sheldon T: Undertaking Systematic Reviews of Research on Effectiveness: CRD Guidance for Those Carrying out or Commissioning Reviews. CRD Report No 4. York, UK, NHS Centre for Reviews and Dissemination, 2001
22. Dattilo DJ, Braun TW, Sotereanos GC: The inverted L osteotomy for treatment of skeletal open-bite deformities. *J Oral Maxillofac Surg* 43:440, 1985
23. Ermel T, Hoffmann J, Alfter G, et al: Long-term stability of treatment results after upper jaw segmented osteotomy according to Schuchardt for correction of anterior open bite. *J Orofac Orthop* 60:236, 1999
24. Lawry DM, Heggie AA, Crawford EC, et al: A review of the management of anterior open bite malocclusion. *Aust Orthod J* 11:147, 1990
25. Lo FM, Shapiro PA: Effect of presurgical incisor extrusion on stability of anterior open bite malocclusion treated with orthognathic surgery. *Int J Adult Orthodon Orthognath Surg* 13:23, 1998
26. Kahnberg KE, Zouloumis L, Widmark G: Correction of open bite by maxillary osteotomy. A comparison between bone plate and wire fixation. *J Craniomaxillofac Surg* 22:250, 1994
27. Kuroda S, Sakai Y, Tamamura N, et al: Treatment of severe anterior open bite with skeletal anchorage in adults: Comparison with orthognathic surgery outcomes. *Am J Orthod Dentofacial Orthop* 132:599, 2007
28. Bishara SE, Chu GW, Jakobsen JR: Stability of the LeFort I one-piece maxillary osteotomy. *Am J Orthod Dentofacial Orthop* 94:184, 1988
29. Swinnen K, Politis C, Willems G, et al: Skeletal and dento-alveolar stability after surgical-orthodontic treatment of anterior open bite: A retrospective study. *Eur J Orthod* 23:547, 2001
30. Hoppenreijts TJ, van der Linden FP, Freihofer HP, et al: Occlusal and functional conditions after surgical correction of anterior open bite deformities. *Int J Adult Orthodon Orthognath Surg* 11:29, 1996
31. Haymond CS, Stoelinga PJ, Blijdorp PA, et al: Surgical orthodontic treatment of anterior skeletal open bite using small plate

- internal fixation. One to five year follow-up. *Int J Oral Maxillofac Surg* 20:223, 1991
32. McCance AM, Moss JP, James DR: Stability of surgical correction of patients with skeletal III and skeletal II anterior open bite, with increased maxillary mandibular planes angle. *Eur J Orthod* 14:198, 1992
 33. Oliveira JA, Bloomquist DS: The stability of the use of bilateral sagittal split osteotomy in the closure of anterior open bite. *Int J Adult Orthodon Orthognath Surg* 12:101, 1997
 34. Hoppenreijts TJ, van der Linden FP, Freihofer HP, et al: Stability of transverse maxillary dental arch dimensions following orthodontic-surgical correction of anterior open bites. *Int J Adult Orthodon Orthognath Surg* 13:7, 1998
 35. Moldez MA, Sugawara J, Umemori M, et al: Long-term dentofacial stability after bimaxillary surgery in skeletal Class III open bite patients. *Int J Adult Orthodon Orthognath Surg* 15:309, 2000
 36. Claudio R, Claudio U, Alessandro A, et al: Variations of the gonial angle in vertical surgical reduction of the maxillary-mandibular complex. *J Craniofac Surg* 16:716, 2005
 37. Ding Y, Xu TM, Lohrmann B, et al: Stability following combined orthodontic-surgical treatment for skeletal anterior open bite—A cephalometric 15-year follow-up study. *J Orofac Orthop* 68:245, 2007
 38. Iannetti G, Fadda MT, Marianetti TM, et al: Long-term skeletal stability after surgical correction in Class III open-bite patients: A retrospective study on 40 patients treated with mono- or bimaxillary surgery. *J Craniofac Surg* 18:350, 2007
 39. Bianchi A, Amadori S, Pironi M, et al: Maxillary expansion and stability in the orthodontic-surgical treatment of skeletal anterior open bites. *Prog Orthod* 10:26, 2009
 40. Hoppenreijts TJ, Voorsmit RA, Freihofer HP: Open bite deformity in amelogenesis imperfecta. Part 1: An analysis of contributory factors and implications for treatment. *J Craniomaxillofac Surg* 26:260, 1998
 41. Hoppenreijts TJ, Voorsmit RA, Freihofer HP, et al: Open bite deformity in amelogenesis imperfecta. Part 2: Le Fort I osteotomies and treatment results. *J Craniomaxillofac Surg* 26:286, 1998
 42. Lansley CV, Stirrups DR, Moos KF: Relapse following surgical treatment of anterior open bite. *Br J Oral Maxillofac Surg* 24:391, 1986
 43. Reyneke JP, Ferretti C: Anterior open bite correction by Le Fort I or bilateral sagittal split osteotomy. *Oral Maxillofac Surg Clin North Am* 19:321, 2007
 44. Bailey LJ, Phillips C, Proffit WR, et al: Stability following superior repositioning of the maxilla by Le Fort I osteotomy: Five-year follow-up. *Int J Adult Orthodon Orthognath Surg* 9:163, 1994
 45. Arpornmaeklong P, Heggie AA: Anterior open-bite malocclusion: Stability of maxillary repositioning using rigid internal fixation. *Aust Orthod J* 16:69, 2000
 46. Fischer K, von Konow L, Brattström V: Open bite: Stability after bimaxillary surgery—2-Year treatment outcomes in 58 patients. *Eur J Orthod* 22:711, 2000
 47. Espeland L, Høgevold HE, Stenvik A: A 3-year patient-centred follow-up of 516 consecutively treated orthognathic surgery patients. *Eur J Orthod* 30:24, 2008
 48. Denison TF, Kokich VG, Shapiro PA: Stability of maxillary surgery in openbite versus nonopen-bite malocclusions. *Angle Orthod* 59:5, 1989
 49. Miguel JA, Turvey TA, Phillips C, et al: Long-term stability of two-jaw surgery for treatment of mandibular deficiency and vertical maxillary excess. *Int J Adult Orthodon Orthognath Surg* 10:235, 1995
 50. Stansbury CD, Evans CA, Miloro M, et al: Stability of open bite correction with sagittal split osteotomy and closing rotation of the mandible. *J Oral Maxillofac Surg* 68:149, 2010
 51. Huang GJ: Long-term stability of anterior open-bite therapy: A review. *Semin Orthod* 8:162, 2002
 52. Reitzik M, Barer PG, Wainwright WM, et al: The surgical treatment of skeletal anterior open-bite deformities with rigid internal fixation in the mandible. *Am J Orthod Dentofacial Orthop* 97:52, 1990
 53. Behrents RG: The biological basis for understanding craniofacial growth during adulthood. *Prog Clin Biol Res* 187:307, 1985
 54. Christou P, Kiliaridis S: Three-dimensional changes in the position of unopposed molars in adults. *Eur J Orthod* 29:543, 2007
 55. Hoppenreijts TJ, Freihofer HP, Stoelinga PJ, et al: Condylar remodelling and resorption after Le Fort I and bimaxillary osteotomies in patients with anterior open bite. A clinical and radiological study. *Int J Oral Maxillofac Surg* 27:81, 1998
 56. Schendel SA, Epker BN: Results after mandibular advancement surgery: An analysis of 87 cases. *J Oral Surg* 38:265, 1980
 57. Joss CU, Joss-Vassalli IM, Kiliaridis S, et al: Soft tissue profile changes after bilateral sagittal split osteotomy for mandibular advancement: A systematic review. *J Oral Maxillofac Surg* 68, 1260:201