



Article scientifique

Article

2013

Published version

Open Access

This is the published version of the publication, made available in accordance with the publisher's policy.

Clinical Course and Management of Iatrogenic Cushing's Syndrome after Co-Administration of Injected-Triamcinolone and Ritonavir: a Systematic Review

John, Gregor Raphaël; Olo, Diana; Meyer, Patrick; Herold, Markus; Samer, Caroline Flora; Calmy, Alexandra

How to cite

JOHN, Gregor Raphaël et al. Clinical Course and Management of Iatrogenic Cushing's Syndrome after Co-Administration of Injected-Triamcinolone and Ritonavir: a Systematic Review. In: Journal of Antivirals and Antiretrovirals, 2013, vol. 05, n° 07. doi: 10.4172/jaa.1000086

This publication URL: <https://archive-ouverte.unige.ch/unige:99750>

Publication DOI: [10.4172/jaa.1000086](https://doi.org/10.4172/jaa.1000086)

Research Article

Open Access

Clinical Course and Management of Iatrogenic Cushing's Syndrome after Co-Administration of Injected-Triamcinolone and Ritonavir: a Systematic Review

Gregor John^{1*}, Diana Olló¹, Patrick Meyer¹, Markus Herold², Caroline Flora Samer³ and Alexandra Calmy⁴¹Department of Internal Medicine Specialties, Geneva University Hospitals (HUG), Switzerland²Private medical practice for infectious diseases, Maihofstrasse 1, Switzerland³Department of Clinical Pharmacology and Toxicology, Geneva University Hospitals (HUG), Switzerland⁴Department of Internal Medicine Specialties, Infectious Diseases Division, Geneva University Hospitals (HUG), Switzerland

Abstract

Background: Iatrogenic Cushing Syndrome (ICS) has been reported after co-administration of injected-triamcinolone and ritonavir. Clinical evolution is however poorly described and recommendations on how to manage this drug-drug interaction are lacking.

Methods: We performed a systematic review of all reported cases of ICS exploring Pubmed, Embase, Cochrane library, and articles references. Time to Hypothalamic-Pituitary-Adrenal (HPA) axis recovery for patients with or without ritonavir interruption, was compared in a Cox model adjusted for confounding factors.

Results: Twenty-four cases of injected triamcinolone induced ICS have been reported. 11/24 cases were related to an epidural injection, 7/24 to an intra-articular, 3/24 to an intramuscular and 3/24 to other injection sites. Symptoms started within 2 weeks (IQR: 0.8-2.3) after steroids injection and needed 11 weeks (IQR: 8-21) to resolve. HPA axis suppression lasted beyond clinical recovery, for a median of 23 (IQR: 12-28) weeks after triamcinolone injection. In a multivariate Cox model, time to HPA axis recovery was shortened when ritonavir was withheld (HR of 18.6 (CI 95% 2.4-145.1), $p < 0.01$) and was prolonged for higher dose of injected-triamcinolone (HR 0.9 (CI 95% 0.9-1), $p = 0.03$) and dose of ritonavir superior to 100mg (HR 0.2 (CI 95% 0.04-0.9, $p = 0.04$). Nineteen out of 24 cases (79%) encountered a medical complication related to steroids excess or HPA axis suppression. Although 42% of cases were offered steroids replacement, only 4/24 experienced symptomatic adrenal insufficiency.

Conclusion: ICS is associated with frequent complications. HPA axis recovery depends on steroids and ritonavir doses, and is accelerated when ritonavir is discontinued. HPA axis replacement therapy is rarely necessary.

Keywords: MeSh; Cushing Syndrome; Ritonavir; Triamcinolone; Injections; HIV infections

Background

HIV-infected patients have long been known to have musculoskeletal pain; arthralgia and back pain being the most frequent sources [1]. With an increased life expectancy, many HIV-positive patients are now living long enough to suffer from degenerative musculoskeletal conditions, which might conduct to corticosteroids infiltrations.

Ritonavir is an irreversible inhibitor of the cytochrome P450 3A enzyme (CYP3A) and is mostly used as a booster for other antiretroviral drugs, raising their plasma concentrations, improving intervals and drug dosage. As most corticosteroids are metabolized by CYP3A, a pharmacokinetic interaction is expected between ritonavir and corticosteroids. A recent retrospective cohort study showed that following corticosteroids injection, hypothalamic-pituitary-adrenal (HPA) axis dysfunction occurred in 11% of HIV-infected patients on protease inhibitors (82% boosted with ritonavir) [2].

Knowledge on Iatrogenic Cushing's Syndrome (ICS) associated with the pharmacokinetic interaction between ritonavir and injected-triamcinolone is based on individual case reports. Clinical picture and management differs somewhat between cases. We aimed to summarize clinical presentation, complication and provide management considerations on this interaction.

Method

We conducted a systematic review on case reports/series of ICS associated drug-drug interaction between ritonavir and injected-triamcinolone, irrespective of language, exploring Pubmed, Embase, Cochrane library and articles references up to 30 Jun 2013. The first two authors (GJ and DO) performed the articles search and data extraction using different combination of keywords (triamcinolone, steroids, Cushing, adrenal insufficiency, iatrogenic, ritonavir, joints, articular, muscular). A third author (MH or CS) resolved disagreements. We excluded articles with no individual patient description. We extracted clinical relevant information at presentation, complications due to steroids excess or adrenal insufficiency, time from injection of triamcinolone to first symptom and clinical or hypothalamic-pituitary-

***Corresponding author:** Gregor John, Department of Internal Medicine Specialties, Infectious Diseases Division, Geneva University Hospitals (HUG), Gabrielle-Perret-Gentil 4, CH-1205 Geneva, Switzerland, Tel: 0041 79 553 43 08; E-mail: gregor.john@hcuge.ch

Received November 05, 2013; **Accepted** December 13, 2013; **Published** December 15, 2013

Citation: John G, Olló D, Meyer P, Herold M, Samer CF, et al. (2013) Clinical Course and Management of Iatrogenic Cushing's Syndrome after Co-Administration of Injected-Triamcinolone and Ritonavir: a Systematic Review. J Antivir Antiretrovir 5: 180-184. doi:[10.4172/jaa.1000086](https://doi.org/10.4172/jaa.1000086)

Copyright: © 2013 John G, et al. This is an open-access article distributed under the terms of the Creative Commons Attribution License, which permits unrestricted use, distribution, and reproduction in any medium, provided the original author and source are credited.

adrenal (HPA) axis recovery (when measured). Symptoms duration was estimated from the first symptom onset to clinical recovery. We resumed distribution of variables with median and interquartile range 25-75% (IQR). We compared groups through Kruskal-Wallis rank test for continuous variable and Fisher exact test for proportion. Time-to-event curves were calculated with the Kaplan-Meier method and group compared through log-rank test. Time to HPA axis recovery for those who discontinued ritonavir or not were compared in a multivariate Cox model adjusted for daily ritonavir (100 mg or more) and triamcinolone doses (continuous). Ritonavir withdrawal was considered as a time dependant variable to take into account inter-cases variation on time of discontinuation considered from the day of last steroid injection. Information on cases with missing value on time to HPA axis recovery was censored from time to clinical recovery. Proportional hazards assumption was verified using Schoenfeld test. This analysis was also performed for time to first symptom onset and symptom duration.

Results

Twenty-four individual cases had a clinical description of the disease course and a confirmed exposition of both ritonavir and injected-triamcinolone (Figure 1 and Table 1). Median age was 47 years (IQR: 40-52.5) and 14/24 (58%) were women. 11/24 cases (45%) were related to an epidural injection, 7/24 (29%) to an intra-articular, 3/24 (12.5%) to an intramuscular and 3/24 to other injection sites. Median triamcinolone dose was 80 mg (IQR: 50-130) and 7/18 received ritonavir at a dose above 100 mg. Ritonavir was stopped in 10/24 patients with a delay of 6 weeks (IQR: 4-8) after the last triamcinolone injection (Appendix Table 1).

Facial swelling (71%) and weight gain (67%) were the most commonly reported symptoms, followed by anxiety (46%), fatigue (37.5%), weakness (25%) and rash (21%). Symptoms appeared within 2 weeks (IQR: 0.8-2.3) after last injection and lasted for a median of 11 weeks (IQR: 8-21) (Appendix Table 2). HPA axis suppression lasted beyond clinical recovery, with a median of 23 weeks (IQR: 12-28) after triamcinolone injection. Injection location, age, and CD4 number had no influence on presentation and evolution of ICS. Female patients had an earlier onset of symptoms: one week (IQR: 0.5-2) compared to two weeks (IQR: 2-3, $p=0.02$) for male patients, but clinical evolution and HPA axis recovery were not statistically different. Time to axis recovery tend to be longer for patient taking 200 mg or 300 mg of ritonavir daily compared to 100 mg of ritonavir (24 weeks (IQR: 22-28) vs 12.5 weeks (IQR: 9-22); $p=0.08$) (Appendix Table 2 and Appendix Figure 1).

The 10/24 patients for whom ritonavir was withheld had received higher dose of triamcinolone and tended to have experienced a longer duration of symptoms (Appendix Table 2). The time to HPA axis recovery appeared earlier for those patients for whom ritonavir was withheld, with a median time of 22 weeks (IQR: 9-28) as compared to 24 weeks (IQR: 13-32), (Appendix Table 1 and Figure 2). In a multivariate Cox model, withdrawal of ritonavir (HR of 18.6 (CI95% 2.4-145.1), $p<0.01$), dose of injected triamcinolone (HR of 0.9 (CI95% 0.9-1), $p=0.03$), and use of more than 100mg of ritonavir (HR of 0.2 (CI95% 0.04-0.9), $p=0.04$), were all associated with time to HPA axis recovery (Table 2). Schoenfeld test showed constant proportional hazard ($p=0.47$). There were no statistical association in the multivariate Cox model for time to symptom onset and duration of symptoms.

Although 10/24 patients were offered steroids replacement, 4/24 only experienced symptomatic adrenal crisis. Seventeen cases

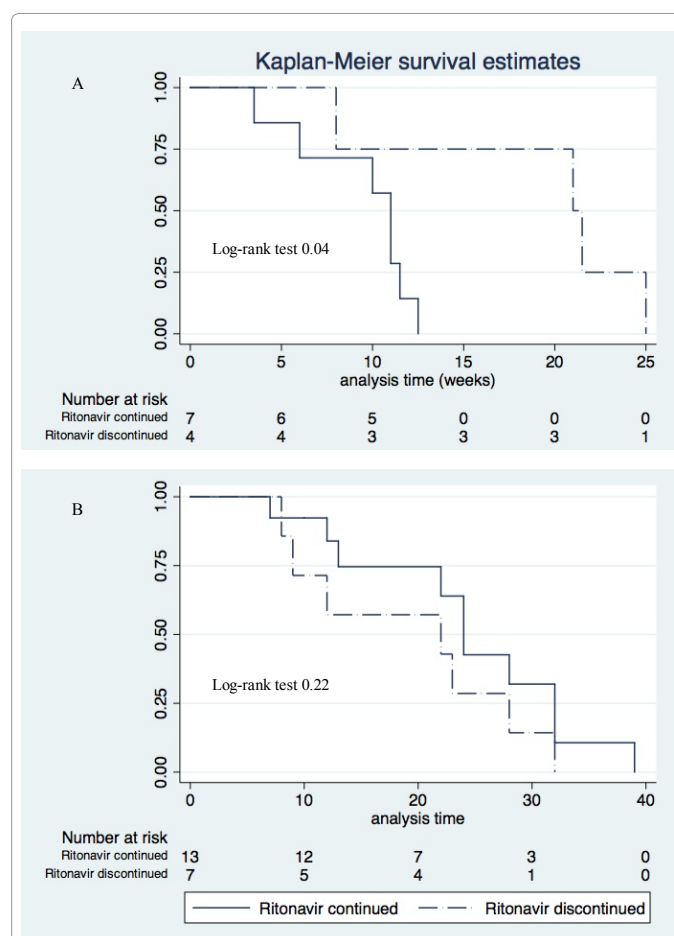
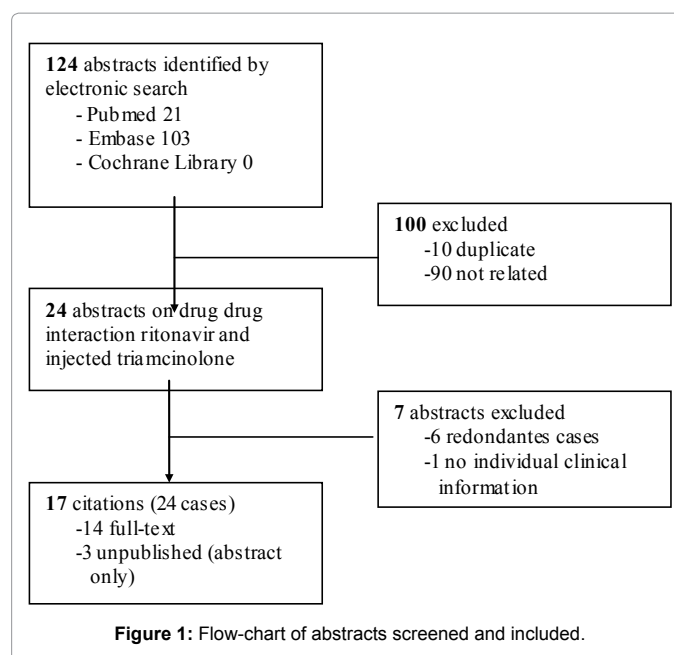


Figure 2: Symptoms (panel A) and hypothalamic-pituitary-adrenal (HAP) axis (panel B) recovery according to ritonavir withdrawal. Time is expressed in weeks and estimated from onset of symptoms for clinical evolution and from the last injection day for HPA axis recovery.

	Patient			Other		Injections characteristics	- RTV	+HPA	Time to (weeks)			ICS complications
	Age (y), sex	CD4 (/μL)	RTV (mg)	S	I				Symptom onset	Clinical recovery	HPA recovery	
Ramanathan 2008 [12]	35, m	470	200		•	Epidural (2x: 60 mg, 80 mg)	•		1	9*	12	CD4 decrease, Oral thrush, AVN
Yombi 2008 [22]												
Case 1	54, f	354	200		•	IA knee (40 mg)		•	2	-	39	Symptomatic HPA
Case 2	56, m	-	200			Epidural (40 mg)		•	2	-	22	Symptomatic HPA
Case 3	49, f	-	200			IA shoulder (40 mg)			2.5	6	28	Symptomatic HPA
Danaher 2009 [23]	44, m	-	100			IA hip joint (80 mg)	•		0.5	-	9	Diabetes (ICU)
Dort 2009 [24]												
Case 1	41, m	842	100			Epidural (2x 80 mg)			2	12	32	CD4 decrease, AVN
Case 2	42, f	693	100			Subacromial space (40 mg)	•		2	13	-	CD4 decrease
Herold 2010 [25]												
Case1	27, f	427	200			Epidural (2x 80 mg)	•		3	28	28	Oral thrush
Case2	62, m	466	100			Epidural (80 mg)			0.5	13	13	CD4 decrease, AVN
Levine 2010 [9]	41, f	-	-		•	Intramuscular (60 mg)			-	24	24	-
Paul 2011 [26]†	49, m	-	-	•		IA sacroiliac (3x40 mg)			-	-	32	-
Albert 2012 [27]	58, w	400	100		•	Epidural (-)			4	10	-	CD4 decrease
Conway 2012 [28]†												
Case 1	50, f	-	-		•	IA shoulders (2x), troch. Bursae (-)		•	2	-	-	Oral thrush, symptomatic HPA
Case 2	58, f	398	-		•	IA knee (-)			-	-	7	CD4 decrease
Fessler 2012 [6]												
Case1	41, m	871	100		•	Epidural (80 mg)			0.5	12	>12	Oral thrush
Case 2	47, f	180	100	•	•	Epidural (2x 80 mg)	•		0.5	22	22	Oral thrush
Grierson 2012 [5]	47, f	627	100		•	Epidural (3x 80 mg)	•	•	3	-	-	Diabetes, hyperlipemia
McManus 2012 [29]†	60, f	-	-	•	•	Intramuscular (-)	•	•	4	-	-	-
John 2013[21]	51, m	114	100	•		Intramuscular (2x40 mg)	•	•	2	-	-	Pulmonary embolism
Maviki 2013 [3]												
Case 1	39, f	657	-			Epidural (2x40 mg)	•	•	0.5	-	32	CD4 decrease, oral thrush
Case 2	47, m	-	200			Subacromial bursae (80 mg)		•	1	-	24	Diabetes
McConkey 2013 [30]	39, f	8	100		•	Orbital floor (2x40 mg)	•		-	5	8	-
Eeftink Schattenkerk 2013 [31]	32, m	430	100		•	IA acromioclavicular (3x10 mg)			1	12	12	-
Song 2013 [32]	34, f	307	300	•	•	Epidural (2x60 mg)	•	•	2	23	23	Thrombosis

Time is expressed in weeks and estimated from the last injection day.*20 weeks for total recovery. † Unpublished.

AVN: avascular necrosis; CD4: Absolute count of CD4 lymphocytes; f: female; +HPA: hypothalamic-pituitary-adrenal axis substitution; I: use of other CYP3A inhibitor; IA: intra articular; ICU: intensive care unit; m: male; RTV: daily dose of ritonavir; -RTV: ritonavir discontinued; S: use of other non-injected steroids; TCL: triamcinolone; y: years

Table 1: Characteristics of patients with Iatrogenic Cushing Syndrome (ICS) due to drug-drug interaction between injected-triamcinolone and ritonavir.

	Symptoms onset*	p value	Symptoms duration†	p value	HPA axis recovery*	p value
Ritonavir discontinued, HR (CI 95%)	1.3 (0.3-5.2)	0.7	0.2 (0.01-6.0)	0.4	18.6 (2.4-145.9)	<0.01
Use of more than 100mg of Ritonavir, HR (CI 95%)	0.6 (0.2-1.7)	0.3	4.2 (0.3-52.5)	0.3	0.2 (0.04-0.9)	0.04
Triamcinolone dose (continue, mg), HR (CI 95%)	1.3 (0.3-5.2)	0.2	0.9 (0.9-1)	0.1	0.9 (0.9-1)	0.03

Discontinuation of ritonavir is considered as a time dependant variable (time between triamcinolone injection and the discontinuation of ritonavir vary for all cases). *Expressed in weeks, estimated from last injection day of triamcinolone; † expressed in weeks, estimated from first symptom onset. CI 95%: 95% confidence interval; HR: hazard ratio

Table 2: Multivariate Cox models for symptom onset, symptoms duration and HPA axis recovery.

encountered at least one complication attributed to ICS: 7 had absolute CD4-count decrease, 6 infections (oral thrush), 5 hyperglycaemias/diabetes (one admitted to the ICU), 4 symptomatic adrenal insufficiency, 2 osteonecrosis and 2 thrombosis.

Discussion

This systematic review shows that HPA axis recovery may depend on steroids and ritonavir doses, and is accelerated when ritonavir is discontinued. Besides, in the 24 cases reviewed, many complications appeared due to ICS. Forty-two percents of HIV-infected patients in Switzerland are currently receiving ritonavir-containing antiretroviral regimens (personal communication, Dr Martin Rickenbach, www.

SCHS.ch). Steroids injections are often administrated by specialists who are not necessarily aware of HIV-infection, use of antiretroviral, or possible drug-drug interactions [3]. Moreover, non-oral steroids exposure is rarely reported by patients, and even rarely written in medical charts. Thus, we believe that ritonavir-induced ICS is probably under-reported. This stresses the need to improve physician's knowledge on this potentially deleterious interaction.

ICS should be differentiated from lipodystrophy, as they share some similar features of fat redistribution (most characteristically: buffalo hump and visceral fat accumulation) [4,5]. However, lipodystrophy syndrome is not associated with other characteristic features of ICS, such as cutaneous changes or neuropsychological conditions; it is a slow, chronic change of fat distribution, generally evolving for many years. Lipodystrophy is associated with normal diurnal variation in cortisol level, normal dexamethasone suppression test, and normal ACTH stimulating test compared to ICS.

Triamcinolone glucocorticoid's relative potency is 5 times higher than hydrocortisone, and similar to methylprednisolone. Triamcinolone acetonide, more frequently used than triamcinolone hexacetonide, is less water-soluble and more rapidly absorbed, and reaches higher peak plasma levels, which are directly proportional to HPA axis suppression [6]. A significant part of the molecule injected locally (intra-articular or epidural) is absorbed in peripheral blood up to 2-3 weeks after the injection, even without co-administration of ritonavir [7,8]. Absorption from intramuscular route is more difficult to predict, depending on location and fat/muscle ratio [9]. Once in the blood, triamcinolone is rapidly metabolised and has a approximate half-life of 2-3 hours [10,11], and a biological half-life of 12-36 hours. Ramanathan et al. estimated that elimination half-life of epidural triamcinolone was 170-fold prolonged when co-administrated with ritonavir [12].

Ritonavir is one of the most potent CYP inhibitor currently available and is nearly exclusively used as a booster drug. It is an irreversible inhibitor and its effect will last until new enzymes are synthesized (up to 7 days) [13]. A wide range of ritonavir doses have been used to boost protease inhibitors. A dose-dependent boosting effect has been demonstrated for some antiproteases (lopinavir or indinavir), while a ceiling effect at 100 mg of ritonavir per day is observed for other drugs, like midazolam, a prototypical CYP3A substrate [14,15]. Ritonavir is responsible for steroids accumulation through inhibition of CYP3A, the major metabolic route of elimination of most corticosteroids. However, ritonavir may also inhibit endogenous steroid synthesis. A retrospective study demonstrated that newborns treated with lopinavir-ritonavir for 30 days had 17-hydroxyprogesteron and DHEA elevations suggesting adrenal dysfunction [16]. Cobicistat is an equally potent CYP3A inhibitor in use since 2013 as a new pharmaco-enhancer of antiretroviral drugs. It will be important to provide education on drug-drug interactions also with cobicistat-containing antiretroviral regimens [17].

In the light of this review we can make the following recommendation concerning preventive measures: It is important to assess the real need for steroid infiltration, since some indications lack evidence. When corticosteroid's infiltration is decided, the smallest effective dose should be chosen. Virtually all steroids are metabolized through the CYP3A, but no study has been conducted to demonstrate that bethamethasone is a substrate of CYP3A in vivo, and there is no documented interaction between this molecule and classical CYP3A inhibitors. However, evidence is lacking to clearly recommend a

specific "safer" injected steroid. A multi disciplinary team, comprising an infectious/AIDS specialist could help to choose the best strategy before the infiltration (e.g: change for non ritonavir-based HAART at least one week before).

Management of ICS should consider avoiding new exposition of steroids, alternative for ritonavir treatment, and HPA axis management. The first measure is limited by the fact that the injected-triamcinolone will remain for weeks after the injection (under ritonavir) and some patients may have no alternative to topical steroids. The second measure - change for non ritonavir-based HAART like a non boosted PI or other anti-HIV drug class (NNRTI or integrase inhibitor) - can be challenging in patients harbouring documented drug resistances, and must be discussed with an infectious disease specialist. When ritonavir has to be maintained, an alternative could be to give another boosted-HAART with smaller dose of ritonavir. We suggest an evaluation of potential other drug-drug interactions using validated tools (e.g. www.hivdruginteraction.org) before any treatment modifications, since several other antiretroviral drugs and treatment such as antifungals azole derivatives are well-known CYP3A inhibitors [18]. The third measure to consider is HPA axis substitution. ICS is characterized by an apparent excess of steroid associated with paradoxal endogenous HPA axis suppression, which may give two sets of symptoms: steroid excess (even after a single dose of 40 mg of triamcinolone), followed by insufficiency when steroids gradually wear off. However, mineralocorticoids insufficiency, which is responsible for most symptoms of adrenal insufficiency, is rare in central adrenal suppression, since aldosterone secretion is not ACTH-dependant. Substitution should be considered on an individual case basis, with cautious clinical follow-up, since there is a significant inter-individual variability in the suppression and the recovery of the HPA axis [19]. Indeed, in most cases of triamcinolone-induced ICS reported (58%), in the absence of severe symptoms, physiological replacement with hydrocortisone was not necessary [20]. Patients must always be advised about steroid withdrawal symptoms (i.e. weakness, weight loss, fatigue, dizziness, postural hypotension and acute adrenal crisis), especially during profound stress like serious infection or operation. When considering ritonavir withdrawal, one must be aware of a rapid metabolism of steroids, and risk of symptomatic adrenal insufficiency.

Some limitations of this review must be pointed out. First, broad range of injected triamcinolone doses or locations, concomitant use of other steroids or drugs with CYP3A inhibitory effects, and a wide heterogeneity in patients monitoring precluded a precise description of clinical evolution. Although the onset of the symptoms and the biological axis suppression were mostly well described, cortisol blood fraction follow-up, and clinical recovery were not systematically mentioned. Thus many "time to recovery" (clinical or HPA axis) could only be estimated from reports. Second, complications considered were those reported, which could overlook many others unmeasured or not stated. Third, decision to stop ritonavir was not random, but based on severity of clinical presentation (e.g: persistent symptoms) and HIV resistance profile. Therefore, the comparison between patients for whom ritonavir was continued or discontinued has several confounding factors. Furthermore the small number of cases reported limits the results. Association between axis recovery and dose of ritonavir deserves to be confirmed by other studies.

Conclusion

The presence of lipodystrophy may delay the diagnosis of ICS in HIV-infected patients. Injection of triamcinolone is not trivial and should be documented in the medical file. Complications of ICS are frequent and deserve careful considerations. We recommend stopping the offending corticosteroid and/or ritonavir by using an antiretroviral drug that does not need to be boosted and with no CYP3A inhibitory effect [21]. HPA axis substitution, although unnecessary for the vast majority of patients, must be tailored in an individual fashion. All patients must be informed on adrenal crisis symptoms and treated when presenting a symptomatic adrenal insufficiency, until normalization of the HPA axis.

Competing interests

All authors have completed the Unified Competing Interest form and declare: no support from any organisation for the submitted work; no financial relationships with any organisations that might have an interest in the submitted work in the previous three years, no other relationships or activities that could appear to have influenced the submitted work.

Authors' contributions

Each author fulfils the condition for authorship and attests that they have directly participated in the preparation of this manuscript and that they have read and approved the final version submitted. GJ and DO had full access to all the data in the study and take responsibility for the integrity of the data and the accuracy of the data analysis. Study concept, design and supervision: GJ. Acquisition of data: DO, CS, MH and GJ. Statistical analysis: GJ. Drafting of the manuscript: GJ and DO. Critical revision of the manuscript for important intellectual content: CS, AC, PM and DO.

Acknowledgements

We gratefully acknowledge Niroshini Ariarajah and Dan Lebowitz for their correction of the English manuscript.

References

- Lawson E, Walker-Bone K (2012) The changing spectrum of rheumatic disease in HIV infection. *Br Med Bull* 103: 203-221.
- Hyle EP, Wood BR, Backman ES, Noubary F, Hwang J, et al. (2013) High frequency of hypothalamic-pituitary-adrenal axis dysfunction after local corticosteroid injection in HIV-infected patients on protease inhibitor therapy. *J Acquir Immune Defic Syndr* 63: 602-608.
- Maviki M, Cowley P, Marmery H (2013) Injecting epidural and intra-articular triamcinolone in HIV-positive patients on ritonavir: beware of iatrogenic Cushing's syndrome. *Skeletal Radiol* 42: 313-315.
- Valin N, De Castro N, Garrait V, Bergeron A, Bouche C, et al. (2009) Iatrogenic Cushing's syndrome in HIV-infected patients receiving ritonavir and inhaled fluticasone: description of 4 new cases and review of the literature. *J Int Assoc Physicians AIDS Care (Chic)* 8: 113-121.
- Grierson MJ, Harrast MA (2012) Iatrogenic Cushing syndrome after epidural steroid injections for lumbar radiculopathy in an HIV-infected patient treated with ritonavir: a case report highlighting drug interactions for spine interventionists. *PM R* 4: 234-237.
- Fessler D, Beach J, Keel J, Stead W (2012) Iatrogenic hypercortisolism complicating triamcinolone acetate injections in patients with HIV on ritonavir-boosted protease inhibitors. *Pain Physician* 15: 489-493.
- Derendorf H, Möllmann H, Grüner A, Haack D, Gyselby G (1986) Pharmacokinetics and pharmacodynamics of glucocorticoid suspensions after intra-articular administration. *Clin Pharmacol Ther* 39: 313-317.
- Ward A, Watson J, Wood P, Dunne C, Kerr D (2002) Glucocorticoid epidural for sciatica: metabolic and endocrine sequelae. *Rheumatology (Oxford)* 41: 68-71.
- Levine D, Ananthakrishnan S, Garg A (2011) Iatrogenic Cushing syndrome after a single intramuscular corticosteroid injection and concomitant protease inhibitor therapy. *J Am Acad Dermatol* 65: 877-878.
- Argenti D, Colligon I, Heald D, Ziemniak J (1994) Nasal mucosal inflammation has no effect on the absorption of intranasal triamcinolone acetate. *J Clin Pharmacol* 34: 854-858.
- Habib GS (2009) Systemic effects of intra-articular corticosteroids. *Clin Rheumatol* 28: 749-756.
- Ramanathan R, Pau AK, Busse KH, Zemskova M, Nieman L, et al. (2008) Iatrogenic Cushing syndrome after epidural triamcinolone injections in an HIV type 1-infected patient receiving therapy with ritonavir-lopinavir. *Clin Infect Dis* 47: e97-99.
- Katzenmaier S, Markert C, Riedel KD, Burhenne J, Haefeli WE, et al. (2011) Determining the time course of CYP3A inhibition by potent reversible and irreversible CYP3A inhibitors using a limited sampling strategy. *Clin Pharmacol Ther* 90: 666-673.
- Hill A, van der Lugt J, Sawyer W, Boffito M (2009) How much ritonavir is needed to boost protease inhibitors? Systematic review of 17 dose-ranging pharmacokinetic trials. *AIDS* 23: 2237-2245.
- Mathias AA, West S, Hui J, Kearney BP (2009) Dose-response of ritonavir on hepatic CYP3A activity and elvitegravir oral exposure. *Clin Pharmacol Ther* 85: 64-70.
- Simon A, Warszawski J, Kariyawasam D, Le Chenadec J, Benhammou V, et al. (2011) Association of prenatal and postnatal exposure to lopinavir-ritonavir and adrenal dysfunction among uninfected infants of HIV-infected mothers. *JAMA* 306: 70-78.
- Temesgen Z (2013) Cobicistat, a pharmacoenhancer for HIV treatments. *Drugs Today (Barc)* 49: 233-237.
- Samer CF, Lorenzini KI, Rollason V, Daali Y, Desmeules JA (2013) Applications of CYP450 testing in the clinical setting. *Mol Diagn Ther* 17: 165-184.
- Igaz P, Rácz K, Tóth M, Gláz E, Tulassay Z (2007) Treatment of iatrogenic Cushing syndrome: questions of glucocorticoid withdrawal. *Orv Hetil* 148: 195-202.
- Hopkins RL, Leinung MC (2005) Exogenous Cushing's syndrome and glucocorticoid withdrawal. *Endocrinol Metab Clin North Am* 34: 371-384, ix.
- John G, Ollo D, Meyer P, Samer FC, Calmy A (2013) Pulmonary embolism and iatrogenic Cushing's syndrome after co-administration of injected-triamcinolone and ritonavir. *AIDS* 27: 2827-2828.
- Yombi JC, Maiter D, Belkhir L, Nzeusseu A, Vandercam B (2008) Iatrogenic Cushing's syndrome and secondary adrenal insufficiency after a single intra-articular administration of triamcinolone acetate in HIV-infected patients treated with ritonavir. *Clin Rheumatol* 27: S79-S82.
- Danaher PJ, Salisbury TL, Delmar JA (2009) Metabolic derangement after injection of triamcinolone into the hip of an HIV-infected patient receiving ritonavir. *Orthopedics* 32: 450.
- Dort K, Padia S, Wispelwey B, Moore CC (2009) Adrenal suppression due to an interaction between ritonavir and injected triamcinolone: a case report. *AIDS Res Ther* 6: 10.
- Herold MA, Günthard HF (2010) Cushing syndrome after steroid-infiltration in two HIV-patients with antiretroviral therapy. *Praxis (Bern 1994)* 99: 863-865.
- Paul JH, Akuthota V (2011) Poster 335 Corticosteroids and retroviral protease inhibitor agents creating an exogenous steroid excess syndrome: a case report. *PM&R* 3: S289.
- Albert NE, Kazi S, Santoro J, Dougherty R (2012) Ritonavir and epidural triamcinolone as a cause of iatrogenic Cushing's syndrome. *Am J Med Sci* 344: 72-74.
- Conway KWD, Walker-Bone K, Churchill D (2012) Steroids strike again - but where is the warning? *HIV Med* 13: S55-S56.
- McManus F, White B, MacConnachie A, Perry C (2012) Risk of iatrogenic Cushing syndrome and adrenal suppression in antiretroviral regimes including CYP450 3A4 inhibitors. *Endocrine abstracts* 28: 329.
- McConkey HZ, Williams H, Kulasegaram R, Graham E (2013) Orbital floor triamcinolone causing Cushing's syndrome in a patient treated with Kaletra for HIV 1. *BMJ Case Rep* 2013.
- Eeftink Schattenkerk JK, Lager PS (2013) Cushing's syndrome during HIV treatment: pharmacological interaction during use of ritonavir. *Ned Tijdschr Geneesk* 157: A5509.
- Song Y, Schroeder JR, Bush LM (2013) Iatrogenic Cushing Syndrome and Secondary Adrenal Insufficiency Related to Concomitant Triamcinolone and Ritonavir Administration: A Case Report and Review. *J Int Assoc Provid AIDS Care*.