



Article scientifique

Article

2003

Published version

Open Access

This is the published version of the publication, made available in accordance with the publisher's policy.

Long term results after complete or incomplete surgical resection of liver hydatid disease

Chautems, Roland; Buehler, Leo Hans; Gold, Benjamin; Chilcott, Michael John; Morel, Philippe;
Mentha, Gilles

How to cite

CHAUTEMS, Roland et al. Long term results after complete or incomplete surgical resection of liver
hydatid disease. In: Schweizerische medizinische Wochenschrift, 2003, vol. 133, n° 17-18, p. 258–262.
doi: 10.4414/smw.2003.10168

This publication URL: <https://archive-ouverte.unige.ch/unige:37173>

Publication DOI: [10.4414/smw.2003.10168](https://doi.org/10.4414/smw.2003.10168)

Long term results after complete or incomplete surgical resection of liver hydatid disease

Roland Chautems, Leo Bubler, Benjamin Gold, Michael Chilkott, Philippe Morel, Gilles Mentha

Clinic of Visceral Surgery, Department of Surgery, University Hospital Geneva, Switzerland

Summary

Background: The liver is the organ most frequently infected by hydatid disease and medical therapy alone is ineffective in eliminating the parasite. Surgical options vary from complete resection (e.g. total pericystectomy or hepatectomy) to limited procedures (e.g. percutaneous aspiration or unroofing of cysts). The aim of this study was to determine the long-term outcome after complete or partial resection of liver hydatid cysts.

Patients and results: Between 1980 and 1996, 78 patients were operated upon at our institution for liver hydatid cysts. In Group 1, complete resection was achieved in 57 patients (73%), whereas in Group 2, incomplete resection was performed in 21 patients (27%), due to multiplicity, bilaterality of cysts or close contact between a cyst and por-

tal or hepatic veins. The post-operative morbidity in Groups 1 and 2, was 31% and 47% (N.S.), respectively. Mean duration of hospital stay was 17 and 26 days ($p = 0.004$), respectively. Recurrence rate of hydatid disease after a mean follow-up of 6.6 years was 0% and 12% (N.S.), respectively. There was no mortality in either group.

Conclusions: Complete surgical resection of hepatic hydatid disease should be attempted whenever possible. Our results, with a mean follow-up of 6.6 years, indicate limited post-operative debilitating complications, low recurrence rate and no mortality.

Key words: *hydatidosis; liver; Echinococcus granulosus; surgical resection*

Introduction

Hydatidosis is an endemic parasitic disease in countries where sheep are prolific. This is particularly the case in Mediterranean countries including North Africa, Spain and Portugal [1]. The parasite, *Echinococcus granulosus*, is a cestode that grows in the small intestine of its definitive host, usually a dog. Eggs are eliminated in the faeces and when ingested, liberate their larvae in the duodenum of an intermediate host (sheep or humans). The larvae cross the intestinal wall and via the portal system reach the liver where they form cysts. The liver is the organ most frequently infected by this disease (50–93%) [2–4].

Without treatment, cysts grow and eventually form fistulas into adjacent organs or rupture into the peritoneal cavity requiring emergency surgery. Older cysts have an increased risk of exogenous daughter cyst formation, which is an important factor for recurrence of disease after surgery [5–8].

Different therapies have been suggested. Medical therapy alone is insufficient to cure the disease, although stabilization has been reported with albendazole alone or in combination with praziquantel [9–12].

Surgical therapy varies from complete resection (e.g. total pericystectomy or hepatectomy) to minimal invasive procedures (e.g. percutaneous aspiration of cysts) [7, 13–17]. More recently, reports have been published on laparoscopic surgery for hepatic hydatid cysts [18–24]. The choice of therapy depends on several factors: general condition of the patient, number and localisation of the cysts, the surgeon's expertise and the type of hospital where such surgery is performed, including the possibility of intensive post-operative care.

This study presents the long term results in patients undergoing complete or incomplete surgical resection of liver hydatid cysts.

Methods

Patients

Between 1980 and 1996, 78 patients were operated upon for liver hydatid cysts at our institution. The study group consisted of 48 women (62%) and 30 men (38%). Age ranged from 15 to 73 years (mean age 40.4 years). Most patients came from countries where parasitic infection is endemic. Seven out of 8 Swiss patients were born or had travelled in these countries (table 1).

Diagnosis

For 44 patients (56%), abdominal pain was the first symptom leading to the diagnosis of hydatidosis, whereas in 20 cases (26%) the diagnosis was made incidentally during a medical check-up. Nine patients (12%) had an abrupt presentation of the disease following the rupture of a cyst. These patients presented with a hypersensitivity reaction (pruritus, urticaria, anaphylaxis), fever of sudden onset, acute abdominal pain or vomiting of pieces of cysts (table 2). One patient was diagnosed with a hydatid cyst peroperatively during an elective procedure for peptic ulcer disease. Eight patients had a recurrence of their disease between 3 and 35 years after one or more operations in

their home country. The type of initial operation performed was not known exactly, but in most cases this was essentially minimal surgery (emptying, marsupialization, or unroofing of cysts).

Pre-operative evaluation

Pre-operative evaluation included blood tests (complete blood count, liver function tests and anti-echinococcus antibody testing) and radiological imaging. Abdominal echography and computerised tomography was done routinely. If vascular compression was suspected, angiography or porto-caval venography was performed.

Surgery

Group 1: Complete resection of the cyst(s) was performed whenever possible, i.e. by total pericystectomy or hepatectomy. Group 2: When complete resection of a cyst was impossible due to multiplicity, bilaterality or close contact between cyst and portal or hepatic veins, unroofing was performed. The latter technique involved placing towels soaked with a hypertonic saline solution around the cyst, emptying it with an aspiration cannula and finally opening and removing of the roof. No scolical agent was injected under pressure into a cyst at any time.

If the pre-operative assessment suggested a possible communication between a cyst and the biliary tree (e.g. cholestasis or dilatation of the biliary tree) or this was suspected during surgery, peroperative cholangiography was performed and, if necessary, the biliary tree was explored. Cholecystectomy was not performed routinely.

Follow-up

After surgery, patients were followed up, either by our department or by a primary care physician. A complete follow-up was achieved in 48 cases (62%), whereas 23 patients (30%) had an incomplete follow-up and 7 patients (8%) returned to their native countries after the operation with no follow-up. Patients who had a radical resection underwent abdominal echography or computerised tomography one year after the operation. Those patients with less definitive surgery, however, underwent radiological imaging every six months.

Data analysis

Complication rates according to the type of surgery, mean hospital stay and recurrence rate of hydatid disease were analysed. Statistical analysis was calculated using χ^2 square and Student test.

Table 1

Native country and corresponding number of patients.

Portugal: 15	Ex-Yougoslavia: 4	Chile: 1
Italy: 13	Morocco: 3	Uruguay: 1
Spain: 12	Libya: 3	Greece: 1
Switzerland: 8	Tunisia: 2	Great-Britain: 1
Turkey: 5	Lebanon: 2	France: 1
Algeria: 5	Ethiopia: 1	

Table 2

Symptoms leading to discovery of hydatid disease.

Abdominal pain	44 (56%)
Fortuitous discovery	20 (26%)
Pruritus or urticaria	3 (4%)
Emesis	2 (3%)
Anaphylactic shock	1 (~1%)
Traumatic rupture	1 (~1%)
Abdominal mass	1 (~1%)
Fever	1 (~1%)
Pneumonia	1 (~1%)
Thoracic pain	1 (~1%)
Nausea	1 (~1%)

Results

Operations

The different types of surgical techniques are summarized in table 3. Patients were divided into 2 groups. Group 1: surgery was considered curative with complete resection of the cyst (s) in 57 patients (73%). Group 2: incomplete resection of cysts was performed in 21 patients (27%).

Thirty-five patients from both groups (45%) had complicated cysts, which communicated with or had perforated into other organs. Communication between a cyst and the biliary tree was found in 27 (35%), with the right lung through the di-

aphragm in three (4%), with the right diaphragm in two (2%), with liver parenchyma in one (1%) and with the peritoneal cavity in one case (1%).

Adjuvant medical therapy

Thirteen patients (16%) with complicated cysts received peri- and/or post-operative albendazole therapy. Duration of albendazole treatment ranged from a few days to 6 months depending on side effects of the medication and compliance of the patient. The total daily doses varied between 600 and 800 mg.

Table 3
Types of surgical techniques performed in 78 patients.

	Group 1: complete resection (57 patients)	group 2: subtotal resection (21 patients)
Total pericystectomies	60	subtotal pericystectomies 20
Right hepatectomies	10	unroofing of cysts 8
Right lobectomy	1	cysto-jejunostomy 1
Left hepatectomies	4	
Left lobectomies	8	
Segmentectomies	8	

Table 4
Post-operative morbidity.

Types of complications	group 1 (nbr. of patients)	group 2 (nbr. of patients)
I	12	1
II a	5	1
II b	1	5
III	0	3
IV	0	0

Classification by Clavien et al. [25]

Grade I:	alterations from the ideal postoperative course, non-life-threatening and with no lasting disability. Complications of this grade necessitate only bedside procedures and do not significantly extend hospital stay.
Grade II:	complications which are potentially life-threatening but without residual disability. A subdivision is made according to the requirement for invasive procedures (IIb).
Grade III:	complications resulting in residual long-term disability, including organ resection or persistence of life-threatening conditions.
Grade IV:	complications leading to patient death

Complications

In group 1, 18 out of 57 patients (32%) developed post-operative complications, compared to 10 among 21 patients (48%) in group 2 (N.S.). The complications were classified according to Clavien et al. (25) from grade I to grade IV (table 4).

Grade I, IIa, and IIb complications consisted of pleural effusions (n = 10), parietal infections (n = 5), biliary fistulae (n = 3) and a sub-diaphragmatic collection (n = 1). These problems resolved spontaneously or by simple drainage in all but one patient, who required relaparotomy to treat active haemorrhage of the phrenic artery.

Grade III complications (complications resulting in a prolonged or definitive disability) were:

- injury to the right brachial nerve plexus (with incomplete sensory-motor recovery) in 1 patient due to positioning on the operating table.
- development of hepatitis C in two patients, possibly due to transfusion of infected blood.

The mortality rate (grade IV complications) was 0.

Duration of hospital stay

Mean hospital stay of Group 1 and 2, was 17 (6–53) and 26 days (10–77), respectively (p = 0.004).

Recurrence

After a mean follow-up period of 79 months (4–207) or 6.6 years, two patients from Group 2 initially operated at our institution developed disease recurrence. Therefore, recurrence rate of Group 1 and 2, was 0 and 12% (N.S.), respectively.

- In one case, recurrence occurred 3 years after subtotal pericystectomy. Recurrence was revealed by ultrasound during a regular follow-up. Initially, a cyst could not be completely removed due its close contact with a sus-hepatic vein. The patient was reoperated on with unroofing of the cyst and has had no further recurrence in 17 years.
- In the second case, recurrence occurred 4 years after subtotal pericystectomy. The patient was lost to follow-up after the first operation and was readmitted emergently to hospital when a recurrent cyst perforated into liver parenchyma, requiring a right hepatectomy.

Discussion

Our results suggest that a radical surgical approach (i.e. hepatectomy, total pericystectomy) of liver hydatid disease offers better results in terms of morbidity, duration of hospital stay and recurrence rate, compared to incomplete removal of parasitic lesions.

Less invasive procedures (i.e. percutaneous or surgical drainage of the cysts) are still therapeutic options, but patients treated with these methods need close and long-term follow-up. Recurrence

of disease is likely even years later, as has been confirmed by other centres [5, 8, 26, 27].

Surgery and complications

Over 30% of our patients developed post-operative complications. The majority were minor problems without long-term disability. Only 3 patients (4%) suffered from long-lasting disabilities related to surgery (grade III). Complication rate was lower in Group 1 compared to Group 2 (32 vs.

47%), however this difference was not significant. Overall bile leakage rate was 4%, which is similar to results published by other centres (3–6%). With more conservative approaches, however, this rate may reach 14 to 27% [27]. In our study, no post-operative deaths were observed in either group, indicating that complete removal of parasitic lesions by radical surgery can be achieved without increased mortality.

Complicated cysts

Almost half of our patients (45%) had complicated hydatid cysts, which is similar to other reported series (36–40%) [2, 26]. Most of the fistulae were with the biliary tree and were diagnosed during surgery.

Peri-operative use of scolicedal agents

Drapes soaked with hypertonic saline solution (at least a 20% solution to have scolicedal effect) were placed around the cysts before their emptying, in order to prevent any soiling of the peritoneal cavity with contents of the cysts [33]. Caution must accompany peri-operative use of scolicedal agents. Several authors reported complications following the use of formaldehyde solution, including the development of sclerosing cholangitis [26]. Therefore, we injected no scolicedal agents into cysts during surgery in order to avoid any contact between the agent and the biliary tree in case of biliary fistula. It appears that the risk of sclerosing cholangitis is related to the presence of a communication between a cyst and the biliary tree, to the duration of exposure to the scolicedal agent or a particular sensitivity to this agent [28–32]. Furthermore, use of peri-operative scolicedal agents has not yet been clearly proven to be useful.

Duration of hospital stay

Mean hospital stay was shorter in patients undergoing radical surgery compared to patients treated by partial removal of parasitic lesions (17 vs. 26 days, $p = 0.004$). This difference can be explained by a lower complication rate, but it must also be mentioned that drainage procedures were more widely used in Group 2. Drainage was related to longer hospital stay (23 vs. 15 days, $p = 0.004$), which has also been reported by other centres [34].

Adjuvant medical therapy

Albendazole has been reported to have some scolicedal effects [35]. Pre-operative use of this

drug aims to reduce viability of cysts [36, 37] and may be of benefit in reducing risk of spillage in the event of rupture of a cyst during surgery.

After surgery, the recommended daily dose of albendazole is 800 mg [35]. Continuous therapy appears to be more effective than repeated cycles and should last at least 6 months [10]. This treatment seems to reduce the risk of recurrence [37]. For these reasons, we treated patients with complicated cysts before and after surgery for approximately 6 months.

Recurrence

Overall recurrence rate was 3% with a mean follow-up period of over 6 years. Both recurrences occurred in patients of Group 2 (subtotal pericysectomy). Therefore, risk of recurrence seems to be increased after incomplete resection compared to complete removal, although the difference was not significant (12% vs. 0%, N.S.). This result is confirmed by data from the literature [26, 38–42]. Recurrence is likely to be due to residual vesicles left in place, even if cysts were carefully emptied. Vesicles can develop from a main cyst and grow next to it, which is especially the case in older cysts. Recurrences may also develop if peritoneal soiling occurs during emptying of a cyst. Recurrence will become symptomatic 3–4 years after surgery [38, 43–46]. Several studies advocating minimally invasive approaches do not mention any follow-up or report short follow-up periods that do not properly assess success of treatment [13, 14, 45, 47].

Conclusions

We recommend complete resection of hepatic hydatid lesions, provided that localisation of the cysts is favourable and that the technical and logistic infra-structure is available. This study demonstrates that this approach can result in a shorter hospital stay, limited post-operative debilitating complications, low recurrence rate and no mortality.

We thank Dr A.Watts for the helpful review of the manuscript.

Correspondence:
Leo Bühler, MD
Department of Surgery
University Hospital Geneva
CH-1211 Geneva
E-Mail: leo.buhler@hcuge.ch

References

- 1 Schantz PM, Schwabe C. Worldwide status of hydatid disease control. *J Am Vet Assoc* 1969;155:2104–21.
- 2 Radford AJ. Hydatid disease. In: Weatherall DJ, Ledingham JGG, Warrell DA, eds. *Oxford Textbook of Medicine*. Oxford University Press 1987;5:561–565.
- 3 Gomez R, Marcello M, Moreno E, Hernandez D, Calle A, Palomo J, et al. Incidence and surgical treatment of extrahepatic abdominal hydatidosis. *Rev Esp Enferm Dig* 1992;82:100–3.
- 4 Amr SS, Amr ZS, Jitawi S, Annab H. Hydatidosis in Jordan: an epidemiological study of 306 cases. *Ann Trop Med Parasitol* 1994;88:623–7.
- 5 Slaoui A, Settaf A. *Chirurgie des kystes hydatiques du foie*. Casablanca: édition Idéale; 1992.
- 6 Guntz M. Les bases anatomo-physio-pathologiques du traitement chirurgical du kyste hydatique du foie. *Min Chir* 1973;28:708.
- 7 Kammerer WS, Schantz PM. Echinococcal Disease. *Infect Dis Clin North Am* 1993;7:605–18.
- 8 Magistrelli P, Masetti R, Coppola R, Messina A, Nuzzo G, Picciocchi A. Surgical treatment of hydatid disease of the liver: a 20-year experience. *Arch Surg* 1991;126:518–22.
- 9 Nahmias J, Goldsmith R, Soibelman M, el-On J. Three-to-7-year follow-up after albendazole treatment of 68 patients with cystic echinococcosis (hydatid disease). *Ann Trop Med Parasitol* 1994;88:295–304.
- 10 Luchi S, Vincenti A, Messina F, Parenti M, Scasso A, Campatelli A. Albendazole treatment of human hydatid tissue. *Scand J Infect Dis* 1997;29:165–7.
- 11 Mohamed AE, Yasawy MI, Al Karawi MA. Combined albendazole and praziquantel versus albendazole alone in the treatment of hydatid disease. *Hepatogastroenterology* 1998;45:1690–4.
- 12 Franchi C, Di vico B, Teggi A. Long-term evaluation of patients with hydatidosis treated with benzimidazole carbamates. *Clin Infect Dis* 1999;29:304–9.
- 13 Aeberhard P, Fuhrimann R, Strahm P, Thommen A. Surgical treatment of hydatid disease of the liver: an experience from outside the endemic area. *Hepatogastroenterology* 1996;43:627–36.
- 14 Alfieri S, Doglietto GB, Pacelli F, Costamagna G, Carriero C, Mutignani M, et al. Radical surgery for liver hydatid disease: a study of 89 consecutive patients. *Hepatogastroenterology* 1997;44:496–500.
- 15 Uravic M, Stimac D, Lenac T, Ivanis N, Petrosic N, Rubinic M, et al. Diagnosis and treatment of liver hydatid disease. *Hepatogastroenterology* 1998;45:2265–9.
- 16 Men S, Hekimoglu B, Yucesoy C, Arda IS, Baran I. Percutaneous treatment of hepatic hydatid cysts: an alternative to surgery. *Am J Roentgenol* 1999;172:83–9.
- 17 Ustunsoz B, Akhan O, Kamiloglu MA, Somuncu I, Ugurel MS, Cetiner S. Percutaneous treatment of hydatid cysts of the liver: long-term results. *Am J Roentgenol* 1999;172:91–6.
- 18 Guibert L, Gayral F. Laparoscopic pericystectomy of a liver hydatid cyst. *Surg Endosc* 1995;9:442–3.
- 19 Sever M, Skapin S. Laparoscopic pericystectomy of liver hydatid cyst. *Surg Endosc* 1995;9:1125–6.
- 20 Bickel A, Eitan A. The use of a large transparent cannula, with a bevelled tip, for safe laparoscopic management of hydatid cysts of liver. *Surg Endosc* 1995;9:1304–5.
- 21 Houry G, Jabbour-Khoury S, Bikhazi K. Results of laparoscopic treatment of hydatid cysts of the liver. *Surg Endosc* 1996;10:57–9.
- 22 Bickel A, Daud G, Urbach D, Lefler E, Barasch EF, Eitan A. Laparoscopic approach to hydatid liver cysts. Is it logical? Physical, experimental, and practical aspects. *Surg Endosc* 1998;12:1073–7.
- 23 Ertem M, Uras C, Karahasanoglu T, Erguney S, Alemdaroglu K. Laparoscopic approach to hepatic hydatid disease. *Dig Surg* 1998;15:333–6.
- 24 Verma GR, Bose SM. Laparoscopic treatment of hepatic hydatid cyst. *Surg Laparosc Endosc* 1998;8:280–2.
- 25 Clavien PA, Sanabria JR, Strasberg SM. Proposed classification of complications of surgery with examples of utility in cholecystectomy. *Surgery* 1992;111:518–26.
- 26 Behrns KE, Van Heerden JA. Surgical management of hepatic hydatid disease. *Mayo Clin Proc* 1991;66:1193–7.
- 27 Kumar A, Chattopadhyay TK. Management of hydatid disease of the liver. *Postgrad Med J* 1992;68:853–6.
- 28 Besim H, Karayalcin K, Hamamci O, Gungor C, Korkmaz A. Scolicidal agents in hydatid cyst surgery. *H P B Surg* 1998;10:347–51.
- 29 Khodadadi DJ, Kurgan A, Schmidt B. Sclerosing cholangitis following the treatment of echinococcosis of the liver. *Int Surg* 1981;66:361–2.
- 30 Terés J, Gomez-Moli J, Bruguera M, Visa J, Bordas JM, Pera C. Sclerosing cholangitis after surgical treatment of hepatic echinococcal cysts: report of three cases. *Am J Surg* 1984;148:694–7.
- 31 Belghiti J, Benhamou JP, Houry S, Grenier P, Huguier M, Fékété F. Caustic sclerosing cholangitis: a complication of the surgical treatment of hydatid disease of the liver. *Arch Surg* 1986;121:1162–5.
- 32 Castellano G, Moreno-Sanchez D, Gutierrez J, Moreno-Gonzales E, Colina F, Solis Herruzo JA. Caustic sclerosing cholangitis. Report of four cases and a cumulative review of the literature. *Hepatogastroenterol* 1994;41:458–70.
- 33 Tsimoyiannis EC, Grantzis E, Moutesidou K, Lekkas ET. Secondary sclerosing cholangitis after injection of formaldehyde into hydatid cysts of the liver. *Eur J Surg* 1995;161:299–300.
- 34 Kama NA, Sahin M, Gocmen E, Bayrak M, Kulacoglu H, Akat AZ. The results of surgical techniques in hepatic hydatidosis: treatment with drainage versus treatment without drainage – a 6-year experience. *J R Coll Surg Edinb* 1998;43:254–6.
- 35 Horton RJ. Albendazole in treatment of human cystic echinococcosis: 12 years experience. *Acta Trop* 1997;64:79–93.
- 36 Aktan AO, Yalin R. Preoperative albendazole treatment for liver hydatid disease decreases the viability of the cyst. *Eur J Gastroenterol Hepatol* 1996;8:877–9.
- 37 Turkapar AG, Ersoz S, Gungor C, Aydinuraz K, Yerdel MA, Aras N. Surgical treatment of hepatic hydatidosis combined with perioperative treatment with albendazole. *Eur J Surg* 1997;163:923–8.
- 38 Barros JL. Hydatid disease of the liver. *Am J Surg* 1978;135:597–600.
- 39 Gargouri M, Ben Amor N, Ben Chehida F, Hammou A, Gharbi HA, Ben Cheikh M, et al. Percutaneous treatment of hydatid cysts (*Echinococcus granulosus*). *Cardiovasc Intervent Radiol* 1990;13:169–73.
- 40 Elhamel A. Percystectomy for the treatment of hepatic hydatid cysts. *Surgery* 1990;107:316–20.
- 41 Vagianos CE, Androulakis JA. Capsectomy and drainage in hepatic hydatidosis. *Dig Surg* 1997;14:241–4.
- 42 Abu Zeid M, El-Eibiedy G, Abu-El-Einen A, Gad El-Hak N, Abd El-Wahab M, Azzat F. Surgical treatment of hepatic hydatid cysts. *Hepatogastroenterology* 1998;45:1802–6.
- 43 Morel Ph, Robert J, Rohner A. Surgical treatment of hydatid disease of the liver: a survey of 69 patients. *Surgery* 1988;104:859–62.
- 44 Ozmen V, Igci A, Kebudi A, Kecer M, Bozfakioglu Y, Parlak M. Surgical treatment of hepatic hydatid disease. *C J Surg* 1992;35:423–7.
- 45 Di Matteo G, Bove A, Chiarini S, Capuano LG, De Antoni E, Lanzi G, et al. Hepatic echinococcus disease: our experience over 22 years. *Hepatogastroenterol* 1996;43:1562–5.
- 46 Khuroo MS, Wani NA, Javid G, Khan BA, Yattoo GN, Shah AH, et al. Percutaneous drainage compared with surgery for hepatic hydatid cysts. *N Eng J Med* 1997;337:881–7.
- 47 Tan A, Yakut M, Kaymakcioglu N, Ozerhan IH, Cetiner S, Akdeniz A. The results of surgical treatment and percutaneous drainage of hepatic hydatid disease. *Int Surg* 1998;83:314–6.

The many reasons why you should choose SMW to publish your research

What Swiss Medical Weekly has to offer:

- SMW's impact factor has been steadily rising, to the current 1.537
- Open access to the publication via the Internet, therefore wide audience and impact
- Rapid listing in Medline
- LinkOut-button from PubMed with link to the full text website <http://www.smw.ch> (direct link from each SMW record in PubMed)
- No-nonsense submission – you submit a single copy of your manuscript by e-mail attachment
- Peer review based on a broad spectrum of international academic referees
- Assistance of our professional statistician for every article with statistical analyses
- Fast peer review, by e-mail exchange with the referees
- Prompt decisions based on weekly conferences of the Editorial Board
- Prompt notification on the status of your manuscript by e-mail
- Professional English copy editing
- No page charges and attractive colour offprints at no extra cost

Editorial Board

Prof. Jean-Michel Dayer, Geneva
 Prof. Peter Gehr, Berne
 Prof. André P. Perruchoud, Basel
 Prof. Andreas Schaffner, Zurich
 (Editor in chief)
 Prof. Werner Straub, Berne
 Prof. Ludwig von Segesser, Lausanne

International Advisory Committee

Prof. K. E. Juhani Airaksinen, Turku, Finland
 Prof. Anthony Bayes de Luna, Barcelona, Spain
 Prof. Hubert E. Blum, Freiburg, Germany
 Prof. Walter E. Haefeli, Heidelberg, Germany
 Prof. Nino Kuenzli, Los Angeles, USA
 Prof. René Lutter, Amsterdam,
 The Netherlands
 Prof. Claude Martin, Marseille, France
 Prof. Josef Patsch, Innsbruck, Austria
 Prof. Luigi Tavazzi, Pavia, Italy

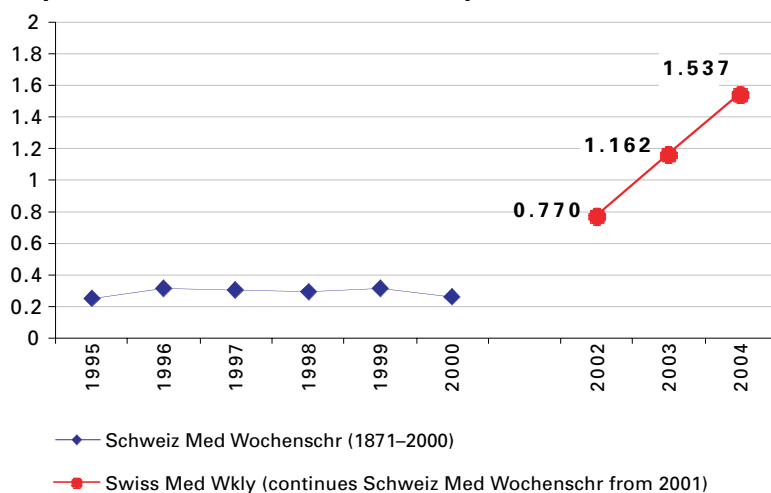
We evaluate manuscripts of broad clinical interest from all specialities, including experimental medicine and clinical investigation.

We look forward to receiving your paper!

Guidelines for authors:

http://www.smw.ch/set_authors.html

Impact factor Swiss Medical Weekly



All manuscripts should be sent in electronic form, to:

EMH Swiss Medical Publishers Ltd.
 SMW Editorial Secretariat
 Farnsburgerstrasse 8
 CH-4132 Muttenz

Manuscripts: submission@smw.ch
 Letters to the editor: letters@smw.ch
 Editorial Board: red@smw.ch
 Internet: <http://www.smw.ch>