



Article scientifique

Article

2010

Published version

Open Access

This is the published version of the publication, made available in accordance with the publisher's policy.

---

## Transpulmonary thermodilution curves for detection of shunt

---

Giraud, Raphaël; Siegenthaler, Nils; Park, Chan; Beutler, Sascha; Bendjelid, Karim

### How to cite

GIRAUD, Raphaël et al. Transpulmonary thermodilution curves for detection of shunt. In: Intensive care medicine, 2010, vol. 36, n° 6, p. 1083–1086. doi: 10.1007/s00134-010-1876-7

This publication URL: <https://archive-ouverte.unige.ch/unige:26445>

Publication DOI: [10.1007/s00134-010-1876-7](https://doi.org/10.1007/s00134-010-1876-7)

Raphael Giraud  
Nils Siegenthaler  
Chan Park  
Sascha Beutler  
Karim Bendjelid

## Transpulmonary thermodilution curves for detection of shunt

Received: 11 December 2009  
Accepted: 4 March 2010  
Published online: 16 April 2010  
© Copyright jointly held by Springer and ESICM 2010

### Electronic supplementary material

The online version of this article (doi:[10.1007/s00134-010-1876-7](https://doi.org/10.1007/s00134-010-1876-7)) contains supplementary material, which is available to authorized users.

C. Park  
Division of Cardiology,  
Department of Internal Medicine,  
Geneva University Hospitals,  
Geneva, Switzerland

S. Beutler  
Department of Anesthesia and Critical Care,  
Massachusetts General Hospital,  
Harvard Medical School,  
Boston, MA, USA

**Abstract** *Purpose:* Monitoring using transpulmonary thermodilution (TPTD) via a single thermal indicator technique allows measurement of cardiac output, extravascular lung water (EVLW) and volumetric variables. *Methods and results:* This report describes two cases of systemic-venous circulation shunt generating early recirculation of thermal indicator with overestimation of EVLW. *Conclusion:* In the case of recirculation of thermal indicator,

the observed overestimated EVLW in absence of gas exchanges abnormality could be an indicator suggesting the search for a circulatory shunt.

**Keywords** Pulmonary edema · Interventricular shunt

### Abbreviations

CO	Cardiac output
CI	Cardiac index
GEDVI	Global end diastolic volume indexed
ITBVI	Intrathoracic blood volume indexed
EVLWI	Extravascular lung water indexed
ITTV	Intrathoracic thermal volume
PTV	Pulmonary thermal volume
MTt	Mean transit time
DSt	Down slope time

R. Giraud · N. Siegenthaler · K. Bendjelid (✉)  
Médecin Adjoint Agrégé,  
Intensive Care Unit, Geneva University Hospitals, Rue Micheli-du-Crest 24,  
1205 Geneva, Switzerland  
e-mail: Karim.Bendjelid@hcuge.ch  
Tel.: +41-22-3827460  
Fax: +41-22-3827470

### Introduction

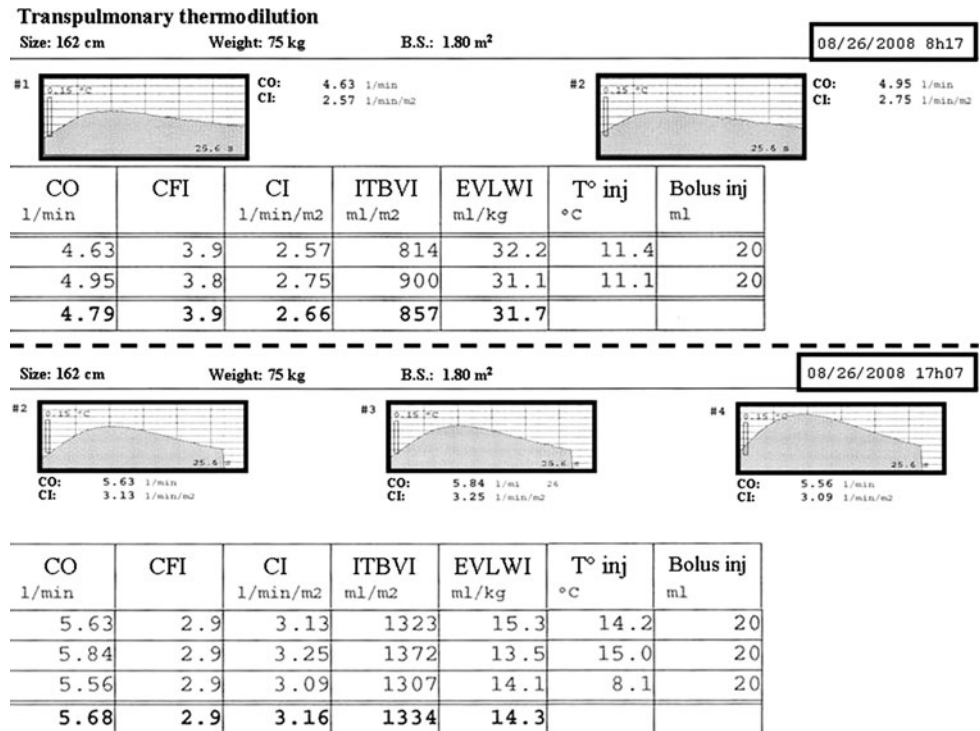
The transpulmonary thermodilution (TPTD) with integrated invasive arterial pulse contour analysis monitoring system operates via a single thermal indicator technique to determine extravascular lung water (EVLW), cardiac output (CO) and volumetric variables. The impact of intracardiac shunt on volumetric variables derived from the TPTD curve has not previously been studied. The present two case reports, describe the impact of ventricular septal defect (VSD) and aorto cava fistula (ACF) on the TPTD curve and EVLW

measurements in critically ill patients monitored with TPTD [1, 2].

### Case 1

The institutional review board (IRB) determined that permission was not required for this report. But, permission to present the case was obtained from the patient. A 66-year-old man, with a medical history of poorly controlled hypertension, dyslipidaemia and diabetes mellitus,

**Fig. 1** Transpulmonary thermodilution curves before (top) and after VSD closure (bottom). Note that the first part of the curve did not change (mean transit time) while the second part decreased in time (down slope time). Tables indicate CO and the derived volumetric values of the TPTD curves. (CO cardiac output, IFC index of cardiac function, CI cardiac index, ITBVI intrathoracic blood volume indexed, EVLWI extravascular lung water indexed,  $T_{inj}$  injection temperature,  $Vol_{inj}$  volume injected)



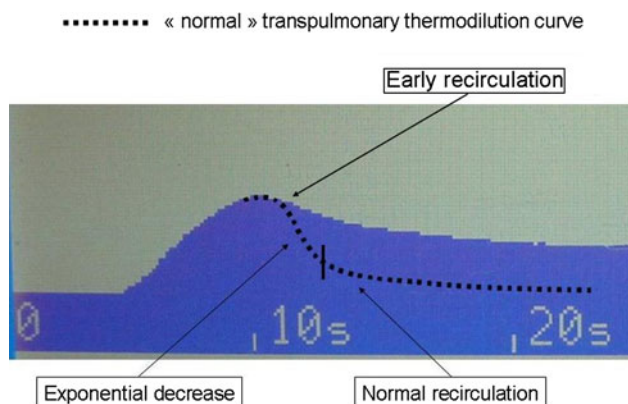
admitted after 24 h of chest pain. The admission electrocardiogram showed abnormalities consistent with anterolateral myocardial infarction. Immediate coronary angiogram performed showed left anterior descending artery occlusion, which was revascularized. Transthoracic echocardiography revealed antero-septo-apical akinesia with estimated ejection fraction of 40%. The initial evolution was favourable.

Two weeks after his admission, the patient developed haemodynamic instability necessitating oral intubation, mechanical ventilation and high dose of inotropes and vasopressors. 5-Fr femoral arterial and subclavian central venous catheters were inserted to measure CO using the TPTD curve technique (Pulsio cath; PiCCO™, Pulsion Medical Systems, Munich, Germany). Haemodynamic measurements showed a CO at 4.8 l/min with an increased extravascular lung water indexed value (EVLWI, 31.7 ml/kg), despite absence of hypoxaemia (FiO<sub>2</sub> 30%) and normal lungs on chest ray (Fig. 1). Because, of these conflicting monitoring results, a second transthoracic echocardiography was performed that displayed an apical VSD with a gradient measured at 30 mmHg. The patient was immediately transferred to the operative room and the VSD repaired by using a pericardial patch. Postoperatively, another transthoracic echocardiography showed the VSD correction. Immediately after the surgical repair, CO was 5.7 l/min and EVLWI decreased to 14.3 ml/kg (Fig. 1), FiO<sub>2</sub> staying stable at 30%. Patient condition improved thereafter and

he could be rapidly extubated. Eight days later, he left the intensive care unit.

### Case 2

A 23-year-old female patient was in her usual state of health until 8 weeks prior to admission to our hospital. At that time she presented to another hospital with a few days history of abdominal pain and shortness of breath. She transiently required mechanical ventilation and femoral arterial pressure monitoring for hypotension. The hospital course was complicated by widespread venous thrombi secondary to heparin-induced thrombocytopenia and she developed severe anasarca and proteinuria. Echocardiography showed a normal left ventricle while the right ventricle was mildly dilated. The patient's overall status improved and she was discharged to rehabilitation 2 weeks prior to admission to our hospital. During the stay at the rehabilitation centre she complained again about abdominal pain and developed fever and confusion. In the setting of haemodynamic instability, she was transferred to our hospital where she underwent an exploratory laparotomy for suspicion of abdominal sepsis. The surgical exploration did not reveal any significant findings. The central venous pressure was reported to be up to 40 mmHg during the surgical procedure. An intraoperative transoesophageal echocardiography showed normal



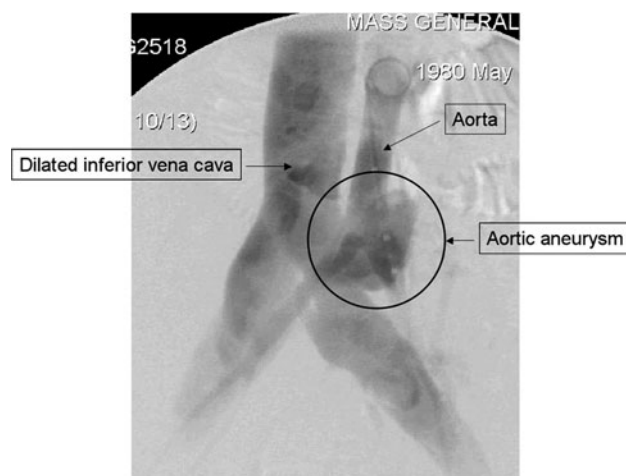
**Fig. 2** Transpulmonary thermodilution evidenced a left-to-right shunt: the dilution curve is characterized by an early recirculation of the cold indicator responsible for a premature flattening of the descending portion. The *dotted line* represents a normal dilution curve with an exponential decrease followed by a flattening of the curve due to the physiological recirculation of the cold indicator

left ventricular function, but right atrial and right ventricular dilatation with significant tricuspid regurgitation. After admission to the surgical intensive care unit the patient was instrumented with a TPTD arterial catheter (Pulsioath; PiCCO™, Pulsion Medical Systems, Munich, Germany) and a jugular central venous line. Haemodynamic measurements showed decreased global end diastolic volume (GEDV) and increased EVLWI value, despite absence of hypoxaemia. The thermodilution curve, shown in Fig. 2, evidenced a left-to-right shunt: the dilution curve was characterized by an early recirculation of the cold indicator which resulted in premature flattening of the descending portion of the curve (Fig. 2). A new echocardiography–Doppler examination was performed but did not evidence any intracardiac shunt. However, the contrast-enhanced abdominal CT scan and angiography (Fig. 3) showed an ACF related to an aortic aneurysm at the level of the bifurcation of the aorta. An endovascular stent repair of the fistula was planned but postponed because of positive blood cultures. The patient developed multiorgan failure and died.

## Discussion

A left-to-right intracardiac or vascular shunt is responsible for early recirculation of the thermal indicator, as shown in Figs. 1 and 2. As far as we know, this is the first observation of a VSD and ACF highlighted by incredible TPTD-derived volumetric parameters and detected by the mere observation of a transpulmonary dilution curve.

The TPTD with integrated invasive arterial pulse contour analysis is a haemodynamic monitoring system gaining favourable reception in intensive care units since



**Fig. 3** Intraoperative angiography demonstrated dense opacification of the inferior vena cava immediately after contrast injection into the iliac artery and the distal aortic aneurysm

it allows both intermittent and continuous CO measurements [1, 2]. It operates via a single thermal indicator technique to determine EVLW, CO and volumetric variables. In our case, CO and EVLW measurements were obtained after central venous injections of 20 ml of cooled (4°C) 0.9% saline. Cooled saline was injected into the central venous catheter while the thermistor tip on the femoral artery catheter measured the downstream temperature change within the abdominal aorta [3]. Cardiac output was then calculated by analysis of the temperature change of the TPTD curve using the Stewart–Hamilton method. Volumetric variables are derived from the TPTD curve, after measurements of the mean transit time (MTt) and the exponential down slope time (DSt) of the TPTD curve [4]. In this regard, EVLW represents all fluid that diffuses and remains outside of the pulmonary vasculature during the thermal indicator transit (i.e. summation of interstitial, intracellular and alveolar fluid).

In the two present cases, EVLWI values were abnormally high before shunt repair and normalized immediately after surgical correction of the defect in one case (Fig. 1). These findings are plausible regarding how EVLW is calculated. Indeed, according to the single thermodilution technique of the PiCCO™ system,  $CO \times \text{mean transit time (MTt)}$  equals the intrathoracic thermal volume (ITTV) and  $CO \times \text{DSt}$  equals the pulmonary thermal volume (PTV) [4]. Since VSD and ACF are responsible for a left–right communication leading to recirculation of the thermal indicator, this situation could induce more increase in the DSt value than in the MTt value measured by the PiCCO™ device as the curve decay is more prolonged (Figs. 1, 2). According to the calculation formulas of the device, this fact will induce more increase in the PTV than ITTV and rationally a decrease in global end diastolic volume decrease ( $GEDV = ITTV - PTV$ ) [5]. Because, intrathoracic blood

volume (ITBV) is related to global end diastolic volume (GEDV), it is also decreased ( $ITBV = GEDV \times 1.25$ ). Finally, EVLW remains obviously increased as it is calculated as  $ITTV - ITBV$  [4]. Measurements obtained in our patient before and after correction of VSD clearly display changes in volume values and curve shapes (Fig. 1) that support our explanations (please see the mathematical formulation in the “Appendix”).

A right-to-left intracardiac shunt related to an atrial septal defect (ASD, patent foramen ovale) can also be diagnosed by using the transpulmonary thermodilution curve [6]. In this setting, one part of the cold indicator passes through the ASD and rapidly reaches the arterial thermistor, with a curve appearing biphasic due to the premature hump related to the early thermal indicator shunt [6]. Concerning the left-to-right shunt, the early circulation could be also perceptible as a second premature hump in the decay phase in the case of significant blood volume shunted and good resolution of the TPTD curve [6].

With single the TPTD technique, ITBV is not obtained directly but derived from CO, and PTV measurements [4]. In the case of recirculation of thermal indicator an overestimation of the EVLW could be observed. This finding

could be an indicator suggesting the search for circulatory shunt in absence of gas exchanges abnormalities.

**Conflict of interest statement** None.

## Appendix

The mathematical formulation derived from haemodynamic parameters of case one (Fig. 1) that supports our explanations is based on the following equation:  $GEDV = ITTV - PTV = CO (MTt - DSt)$ ;  $MTt - DSt = GEDV/CO$ . GEDVI before surgery was  $685 \text{ ml/m}^2$  ( $ITBVI/1.25 = 857/1.25$ ) and after surgery it was  $1,067 \text{ ml/m}^2$  ( $1,334/1.25$ ). Thereafter, the GEDVI (and ITBVI) increased by **56%** [ $(1,067 - 685)/685$ ] after septal closure while CI increased by only **19%** [ $(3.16 - 2.66)/2.66$ ]. Accordingly the  $(MTt - DSt)$  value was 16 s (GEDVI/CI) before surgery and 20 s (GEDVI/CI) after septal closure. Thus  $(MTt - DSt)$  increased after septal closure (while the absolute total time curve decreased, as observed in Fig. 1). These results demonstrate that DSt decreased more than MTt after shunt correction.

## References

- Oshima K, Kunimoto F, Hinohara H, Hayashi Y, Takeyoshi I, Kuwano H (2008) The evaluation of hemodynamics in post thoracic esophagectomy patients. *Hepatogastroenterology* 55:1338–1341
- Huber W, Umgelter A, Reindl W, Franzen M, Schmidt C, von Delius S, Geisler F, Eckel F, Fritsch R, Siveke J, Henschel B, Schmid RM (2008) Volume assessment in patients with necrotizing pancreatitis: a comparison of intrathoracic blood volume index, central venous pressure, and hematocrit, and their correlation to cardiac index and extravascular lung water index. *Crit Care Med* 36:2348–2354
- Sakka SG, Reinhart K, Meier-Hellmann A (1999) Comparison of pulmonary artery and arterial thermodilution cardiac output in critically ill patients. *Intensive Care Med* 25:843–846
- Neumann P (1999) Extravascular lung water and intrathoracic blood volume: double versus single indicator dilution technique. *Intensive Care Med* 25:216–219
- Nirmalan M, Willard TM, Edwards DJ, Little RA, Dark PM (2005) Estimation of errors in determining intrathoracic blood volume using the single transpulmonary thermal dilution technique in hypovolemic shock. *Anesthesiology* 103:805–812
- Michard F, Alaya S, Medkour F (2004) Monitoring right-to-left intracardiac shunt in acute respiratory distress syndrome. *Crit Care Med* 32:308–309