



Article
scientifique

Revue de la
littérature

2003

Published
version

Open
Access

This is the published version of the publication, made available in accordance with the publisher's policy.

Squamous cell carcinoma of the anus: another sexually transmitted disease

Gervaz, Pascal; Allal, Abdelkarim Said; Villiger, Peter; Buehler, Leo Hans; Morel, Philippe

How to cite

GERVAZ, Pascal et al. Squamous cell carcinoma of the anus: another sexually transmitted disease. In: Schweizerische medizinische Wochenschrift, 2003, vol. 133, n° 25-26, p. 353–359. doi: 10.2003/25/smw-10225

This publication URL: <https://archive-ouverte.unige.ch/unige:45071>

Publication DOI: [10.2003/25/smw-10225](https://doi.org/10.2003/25/smw-10225)

Squamous cell carcinoma of the anus: another sexually transmitted disease

Pascal Gervaz, Abdelkarim S. Allal*, Peter Villiger, Léo Bübler, Philippe Morel

Clinique de Chirurgie Viscérale, *Division of Rediation Oncology, Hôpital Cantonal Universitaire de Genève

Summary

During the past 30 years, there has been remarkable progress in our understanding of the pathogenesis of squamous cell carcinoma of the anus. It is now accepted that anal cancer is a sexually transmitted disease, which can be cured using a combination of chemo- and radiotherapy. The biology of anal cancer remains to be elucidated, as do the molecular mechanisms involved in resistance to chemoradiation. The contribution of HIV infection to tumour progression currently repre-

sents an area of intensive investigation. Finally, the growing numbers of AIDS patients who experience prolonged survival represent a population at risk. In the future, cytological screening of male homosexuals with an anal Papanicolaou test may help in identifying high-grade dysplasia and preventing anal cancer.

Key words: anal cancer; chemoradiation; molecular biology; human papilloma virus; AIDS

Introduction

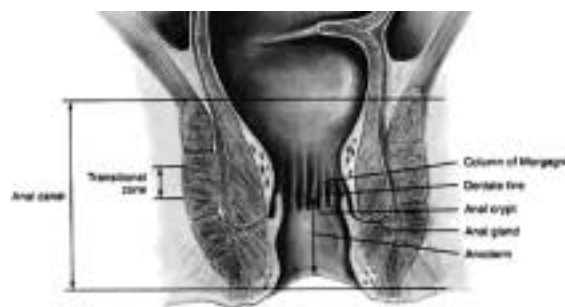Anal cancer has served during the past two decades as a paradigm for the successful application of chemoradiation to solid tumours. To date, it remains one of the few carcinomas of the gastrointestinal tract that are curable without the need for definitive surgery. Epidemiological studies have demonstrated that sexually transmitted infection with human papillomavirus is responsible for

the majority of cases. This type of neoplasm also provides a good model to study the contribution of immunodeficiency to the development of cancers. In this paper, the anatomy of the anal area is reviewed, the aetiological role of viruses is discussed and the clinical management of patients with anal cancer is presented.

Definition

Figure 1

Anatomy of the anal margin and anal canal. Reproduced with authorisation from: Gordon PH, Nivatvongs S. Principles and Practice of Surgery of the Colon, Rectum and Anus. Saint Louis: Quality Medical Publishing; 1999.



Various definitions of the anal area coexist in the medical literature. In the past this has been the source of considerable confusion. Anal cancer may arise from the *anal canal* or from the *anal margin*. Eighty-five percent of the anal cancers occur in the

anal canal and 15% in the anal margin. The anal canal is about 3.5 cm long and extends from the upper to the lower border of the anal sphincter (figure 1). The anal margin corresponds to a 5-cm area of peri-anal skin, measured from the anal verge. The anal verge is a visible landmark, corresponding to the external margin of the anus, which delineates the junction between the skin epithelium and the hairless and non-pigmented epithelium of the anal canal.

Tumours arising within the anal canal are either keratinising or non-keratinising squamous cell carcinomas, depending on their location below or above the dentate line, respectively. Various terms, such as junctional, basaloid or cloacogenic previously used to describe these tumours have

been abandoned due to the confusion surrounding them. Anal canal carcinomas are characterised by aggressive local growth, including extension to the underlying sphincter muscles. By contrast, cancers originating from the peri-anal skin have a more favourable prognosis and tend to behave more like

other skin cancers. Thus, the anal verge is an important anatomical landmark, separating two histologically distinct epithelial structures that give rise to two types of cancers with different natural histories, prognoses and treatment.

Epidemiology

Because of its relatively low incidence, little attention has been paid to squamous cell carcinoma of the anus (SCCA) in the past. Carcinomas of the anal canal constitute 1.5% of all digestive system cancers in the United States, with an estimated 3,400 new cases and 500 deaths in 1999 [1, 2]. However, the incidence of SCCA has markedly increased in younger males during the last three decades. In the San Francisco bay area, the incidence of anal cancer in male homosexuals was 9.9 (95% CI = 4.5–18.7) times higher than expected in 1973–1979 and 10.1 (95% CI = 5.0–18.0) times higher in 1988–1990 [3, 4]. Importantly, this trend was observed even before the AIDS epidemic and some authors consider that the increased risk for SCCA among AIDS patients results from human papillomaviruses (HPV) infection and not from HIV-related immune deficiency [5]. However, the increased incidence of SCCA in renal transplant patients clearly suggests that immunosuppression may play a role in tumour development [6].

Sexual transmission / HPV infection

Population studies from California and Europe have well documented the relation between anal cancer and receptive anal intercourse in individuals of both sexes, irrespective of immunosuppression. A case-control study was conducted in Denmark to compare the contribution of lifestyle to the development of anal vs. rectal cancer [7]. The risk factors associated with anal cancer *in*

women were more than ten sexual partners (RR = 2.5), a history of anal warts (RR = 11.7) and anal intercourse before the age of 30 (RR = 3.4). In the same population, HPV DNA was detected by PCR in 88% of the tumours from 394 patients with anal cancer. A cohort study within two large serum banks in Norway and Finland demonstrated an increased risk of developing SCCA among subjects seropositive for either HPV 16 (OR = 3.0) or HPV 18 (OR = 4.4) [8]. In addition, there have been numerous reports linking anal cancer and cervical cancer [9]. It appears that the association between cervical cancer and anal cancer is as strong as that between cervical and vulva cancer [10]. *Thus, anal cancer is now considered a sexually transmitted disease, which is clinically related to the development of anal warts and infection with HPV oncogenic subtypes 16 and 18.*

Immune suppression / HIV infection

Since 1994, numerous epidemiological studies from the United States have demonstrated a high incidence of anal cancer among AIDS individuals [3, 11]. HIV-positive male homosexuals are at increased risk of developing anal HPV infection and anal intraepithelial neoplasia (AIN) [12, 13]. AIN being a precursor of invasive SCCA (similar to cervical intraepithelial neoplasia [CIN] and cervical cancer), screening programs using anal Papanicolaou smears in HIV-positive homosexual have been developed and might be cost-effective [14].

Pathogenesis

At the molecular level, the best characterised factor in the development of anal cancer is the integration of HPV DNA into anal canal cell chromosomes [15]. Of note, experimental studies have demonstrated that *the presence of high-risk HPV by itself is not sufficient to induce transformation and tumour progression* [16]. In immunocompetent individuals, most cases of anogenital HPV infection undergo spontaneous regression. In the case of male homosexuals, it has been possible to investigate the effects of HIV-mediated immune suppression on HPV infection, as dual infection with both viruses is relatively common in this population [17, 18].

HIV positive patients are more likely to have persistent HPV infection, a higher viral load and anal intra-epithelial neoplasia (AIN) than HIV negative patients [19]. Thus, the current consensus is that *HIV-related immunosuppression is responsible for an enhanced expression of HPV infection in the anal canal, which may lead to HPV-induced epithelial abnormality* [20]. In the emerging model of SCCA progression, two additional factors are implicated in the malignant conversion of HPV-infected epithelial cells of the anal canal, a) the ability to escape cell-mediated immune response and b) the induction of chromosomal instability, reflected by loss of heterozygosity (LOH).

Molecular biology

Studies on squamous cell carcinomas of the cervix have demonstrated that in addition to HPV integration, the neoplastic process requires the loss of tumour suppressor gene (TSG) function, and specific chromosomal aberrations have been detected in cervical and anal squamous carcinomas [21]. Unfortunately, only a few reports on the cytogenetics of SCAA are currently available, and a common underlying theory of pathogenesis has not been established. Most reports include small numbers of patients, and none of them focused on two clinically relevant issues; response to treatment and the role of HIV infection in tumour genesis.

Muleris and colleagues have identified recurrent losses of chromosomes 3p and 11q in a series of 8 tumours [22]. Using comparative genomic hybridisation (CGH), Heselmeyer et al. identified consistent losses mapped to chromosomes arms

4p, 11q, 13q and 17q [23]. It still remains unknown whether these alterations contribute to resistance to current chemoradiation protocols. In addition, the overexpression of P53 protein detected by immunohistochemistry seems to correlate with an inferior outcome in patients who received CRT for SCCA [24, 25]. However, the authors did not correlate the molecular alterations with the HIV status. In another small study, LOH on chromosomes 5p and 18q was detected, demonstrating for the first time mutations of the APC and SMAD4/DCC tumour suppressor genes in SCCA [26]. In summary, the molecular biology of SCCA is far from being elucidated, and thus warrants further investigation. This type of malignancy indeed represents an excellent model in which to study 1) the impact of HIV infection on tumour progression and 2) the role of LOH on response to chemoradiation.

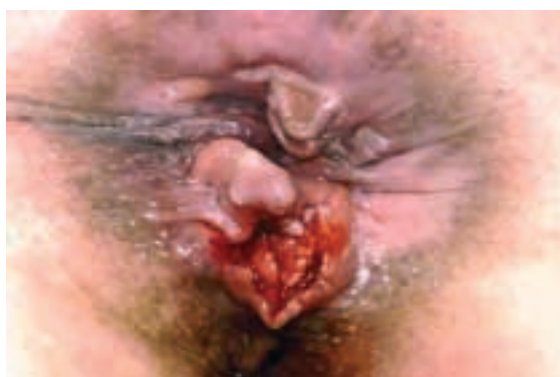Clinical features

Tumours from the anal area typically present as a mass associated with bleeding and pain (Figure 2). Even small lesions can produce significant local symptomatology, a “blessing in disguise” if it facilitates early detection [27]. Unfortunately, these symptoms are often erroneously attributed to “haemorrhoids”, with subsequent delay in the diagnosis and treatment. It is important for the clinician to remember that haemorrhoids rarely cause pain (unless thrombosed), thus patients pre-

senting with anal pain should be carefully evaluated, if possible under anaesthesia, and biopsies should be obtained. Untreated anal cancer spreads by local extension to adjacent tissues and organs of the pelvic floor, including sphincter muscles, vagina or prostate. When present, tenesmus, a painful urgency to defecate, suggests that the tumour has spread through the sphincter muscles [28]. A history of anorectal warts is present in 50% of homosexual men with anal cancer, but is found in only 20% of heterosexual individuals with SCCA [29].

Anal margin and anal canal tumours have different patterns of lymphatic drainage. Cancers arising from the more proximal anal canal (above the dentate line) drain predominantly into the peri-rectal and iliac lymph nodes, while tumours within the distal canal and the anal margin drain exclusively into inguinal lymph nodes. At presentation, approximately 50–60% of patients will have a superficial (T1 or T2) lesion, and 25% of patients will have involvement of regional lymph nodes. 10% of patients have distant metastases at the time of diagnosis [30].

Figure 2
Squamous cell carcinoma of the anus.



Staging

Once the diagnosis of anal cancer has been established by biopsy, it is important to assess the regional extension of the tumour, and to further characterise its stage. Prognosis for anal cancer is related to tumour size, but it is unclear whether the independent variable is the actual tumour size or the depth of invasion. Neither the histology type,

nor the degree of differentiation have major prognostic significance, and therefore have not been included in the American Joint Committee on Cancer (AJCC)/International Union Against Cancer (UICC) staging system (table 1) [31]. Tumours larger than 5 cm in greatest diameter (T3) and lesions with metastases in regional lymph nodes

(N1–3) have an increased risk for tumour recurrence after chemoradiation (CRT) [32].

It should be noted that staging for most solid tumours is established according to the pathological examination of the surgical specimen. Staging systems for SCCA were validated at the time when abdomino-perineal resection (APR) was the first line therapy. Since most cases of anal cancer are now treated without surgery, a revised staging method for these cancers has yet to be developed. Endoanal ultrasound currently represents the most promising modality to accurately determine

the depth of penetration of anal cancer into the sphincter complex [33, 34]. A modification of the TNM classification for transanal ultrasound has been proposed by Bartram & Burnett in order to stage SCCA prior to chemoradiation (table 2) [35]. However, ultrasound-based staging systems are notoriously operator-dependent, and have so far failed to be validated in large series. Thus, surprisingly, there is currently no staging in routine use for SCCA either before chemoradiation or after APR [36].

Table 1
AJCC/UICC staging
of anal cancer.

Primary tumour	T1	<2 cm		
	T2	>2 cm and <5 cm		
	T3	>5 cm		
	T4	Invasion of adjacent organs (vagina, urethra, bladder)		
Lymph nodes	N0	No regional lymph node metastases		
	N1	Perirectal lymph nodes metastases		
	N2	Unilateral iliac and/or inguinal lymph nodes metastases		
	N3	Bilateral iliac and/or inguinal lymph nodes metastases		
Distant metastases	M0	No distant metastases		
	M1	Distant metastases		
Staging	I	T1	N0	M0
	II	T2, T3	N0	M0
	IIIa	T4	N0	M0
		T1, T2, T3	N1	M0
	IIIb	T4	N1	M0
		Any T	N2, N3	M0
IV	Any T	Any N	M1	

Table 2
Ultrasound staging
of anal cancer

T1	Tumour limited to internal anal sphincter
T2	Tumour involving external anal sphincter
T3	Tumour extending outside external sphincter (or >5 cm in greatest dimension)
T4	Tumour involving adjacent organ

Treatment

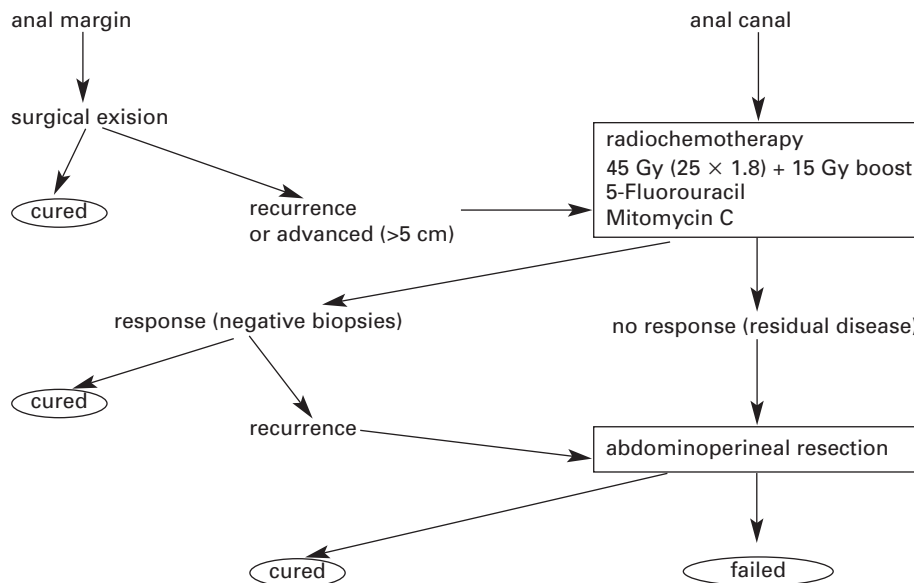
In 1974, Nigro et al published their initial experience with preoperative radiation and chemotherapy followed by abdomino-perineal resection in three patients with SCCA. Unexpectedly, no residual tumour was found in the resected specimen. The same authors eventually confirmed these findings in a larger series [37]. Since then, it is commonly admitted that 1) SCCA is a radiosensitive carcinoma, 2) most anal cancers can be cured with chemoradiotherapy (CRT), and 3) APR is unnecessary in the majority of cases. However, despite good results with CRT as the primary means of management, approximately 30% of patients will develop a local recurrence [38]. Most patients with residual disease are ultimately candidates for

an APR with definitive colostomy. Relatively good results can be achieved with salvage APR for recurrent SCCA with 5-year survival rates reported up to 50% in patients who had evidence of residual disease after CRT [39, 40]. The management algorithm for SCCA is summarized in figure 3.

Anal margin cancer

Wide local excision is usually recommended for anal margin cancer, with excellent results. Epidermoid carcinomas of the anal margin rarely metastasise to visceral organs. Recurrences may occur and are managed by re-excision in most cases. Combined chemoradiotherapy with 5-fluorouracil and mitomycin C remains an option in

Figure 3
Management algorithm of anal cancer.



patients with locally advanced tumours (>5 cm). As for most skin cancers, the prognosis is good with 5-year survival rates reportedly up to 90% [41].

Anal canal cancer

While small tumours (<2 cm) arising in the anal canal may be amenable to local excision, most patients present with lesions of greater dimensions. Thanks to the pioneering work of Nigro, it is now widely accepted that the majority of cases can be cured by a combination of external-beam radiation therapy and chemotherapy with fluorouracil and mitomycin. Currently, the standard of care consists in the combination of radiation and chemotherapy, which has proven superior to radiotherapy alone in two randomised trials conducted in Europe [42, 43]. In the EORTC trial, 110 patients with Stage II or III SCCA were randomised to receive either external-beam radiation (45 Gy over 5 weeks, with a 15 Gy boost) with concurrent chemotherapy (5-fluorouracil and mitomycin-C) or radiotherapy alone. The dose of 5-FU was 750 mg/m² on days 1–5 and 29–33; the dose of mitomycin was 15 mg/m² on day 1. The chemoradiation protocol resulted in a higher remission rate (80% vs. 54%) and a 32% higher colostomy-free rate.

Following chemoradiation, patients should be

examined at 3-months intervals, if possible under anaesthesia, and biopsy specimen taken of any induration or zone suspicious for recurrence. The functional results are usually good, and most patients retain a functional anal sphincter, with no alteration in their lifestyle. However, it is known that radiation negatively affects the internal sphincter function, with resulting faecal incontinence in a small percentage of cases [44]. It is important to differentiate *residual disease* (positive biopsies less than 6 months after completion of chemoradiation) from *tumour recurrence* (complete response initially, with positive biopsies more than 6 months after cessation of treatment) [45]. In most cases, recurrence occurs within 2 years of CRT. Patients with locally recurrent anal canal cancer should undergo an APR. It is estimated that, only 50% of patients who have locally recurrent SCCA following CRT will be cured with salvage APR.

CRT may be given safely at conventional doses in HIV-positive patients [46]. However, it has been demonstrated that this subset of SCAA patients have a poor outcome, with response rate and 2-year colostomy-free survival rate of less than 50% [47, 48]. These data support the routine screening for anal intraepithelial lesions in HIV-positive patients [49].

Anal intraepithelial neoplasia (AIN) in the antiretroviral therapy era

Anal intraepithelial neoplasia (AIN) as a precursor for invasive SCCA has emerged from the recent literature as one of the most important contributions to the field of anal cancer. HIV positive women are more likely to demonstrate abnormal Papanicolaou smears, as well as persistence of cervical infection with HPV over time [50]. Thus, invasive cervical cancer was added to the list of AIDS-defining conditions in 1993. Not surpris-

ingly, AIN is common among HIV-positive homosexuals, in this population, more than 50% of individuals with a CD4⁺ count <500, and 33% of those who had a CD4⁺ count >500 developed AIN within 4 years of follow-up [51]. Anal colposcopy is a specialised procedure, which should be performed by a trained coloproctologist, using 5% acetic acid epithelial staining in accordance with the techniques used for cervical colposcopy. The

rationale for screening this high-risk population with anal Papanicolaou smears is currently under investigation. It appears, however, that AIN does not always progress to SCCA, and that a significant percentage of these lesions undergo spontaneous regression.

In theory, highly active antiretroviral therapy (HAART), which results in improved immune function, may subsequently reduce the risk of HIV-positive homosexuals developing persistent HPV infection in the anal canal. *Alternatively, the incidence of AIN may increase over time, since AIDS patients now live longer in the setting of imperfect immune reconstitution.* Indeed, recent data regarding AIN and SCCA in the era of HAART give cause for concern. Despite prolonged response to antiretroviral therapy, HIV-positive homosexuals have persistent HPV infection, and HAART had no ef-

fect on the incidence and progression of AIN [52]. The current consensus is that HAART will probably not be associated with a reversal of high-grade dysplasia, since these lesions have already acquired irreversible chromosomal alterations. Furthermore, epidemiological data from the San Francisco area indicate that the incidence of anal cancer continues to increase substantially despite the widespread use of HAART in this population.

Correspondence:

Pascal Gervaz, MD

Clinique de Chirurgie Viscérale

Hôpital Cantonal Universitaire de Genève

Rue Micheli-du-Crest 24

CH-1211 Genève

E-Mail: pascal.gervaz@hcuge.ch

References

- Greenlee RT, Murray T, Bolden S, Wingo PA. Cancer statistics 2000. *CA Cancer J Clin* 2000; 50:7-33.
- Ryan DP, Compton C, Mayer RJ. Carcinoma of the anal canal. *N Engl J Med* 2000; 342:792-800.
- Palefsky JM. Anal human papillomavirus infection and anal cancer in HIV-positive individuals: an emerging problem. *AIDS* 1994; 8:283-95.
- Rabkin CS, Yellin F. Cancer incidence in a population with a high prevalence of infection with human immunodeficiency virus type 1. *J Natl Cancer Inst* 1994; 86:1711-6.
- Goedert JJ. The epidemiology of acquired immunodeficiency syndrome malignancies. *Semin Oncol* 2000; 27:390-401.
- Penn I. Cancers of the anogenital region in renal transplant recipients. *Cancer* 1986;58:611-6.
- Frisch M, Glimelius B, van den Brule AJC, Wohlfart J, Meijer CJ, et al. Sexually transmitted infection as a cause of anal cancer. *N Engl J Med* 1997; 337:1350-8.
- Bjorge T, Engeland A, Luostarinen T, Mork J, Gislefoss RE, et al. Human papillomavirus infection as a risk factor for anal and perianal skin cancer in a prospective study. *Br J Cancer* 2002; 87:61-4.
- Northfelt DW. Cervical and anal neoplasia and HPV infection in persons with HIV infection. *Oncology* 1994; 8:32-7.
- Melbye M, Spregel P. Aetiological parallel between anal cancer and cervical cancer. *Lancet* 1991; 338:657-9.
- Melbye M, Cote TR, Kessler L, Gail M, Biggar RJ, et al. High incidence of anal cancer among AIDS patients. *Lancet* 1994; 343:636-9.
- Causy D, Goedert JJ, Palefsky J, et al. Interaction of human immunodeficiency and papilloma viruses: association with anal epithelial abnormalities in homosexual men. *Int J Cancer* 1990; 46:214-9.
- Palefsky JM, Gonzales J, Greenblatt RM, Ahn DK, Hollander H. Anal intraepithelial neoplasia and anal papillomavirus infection among homosexual males with group IV HIV disease. *JAMA* 1990; 263:2911-6.
- Goldie SJ, Kuntz KM, Weinstein MC, Freedberg KA, Welton ML, Palefsky JM. The clinical effectiveness and cost-effectiveness of screening for anal squamous intraepithelial lesions in homosexual and bisexual HIV-positive men. *JAMA* 1999; 281:1822-9.
- Xi LF, Critchlow CW, Wheeler CM, Koutsky LA, Galloway DA, et al. Risk of anal carcinoma in situ in relation to human papillomavirus type 16 variants. *Cancer Res* 1998; 58:3839-44.
- Chen T, Pecaro G, Defendi V. Genetic analysis of in vitro progression of human papillomavirus transfected human cervical cells. *Cancer Res* 1993; 53:1167-71.
- Critchlow CW, Hawes SE, Kuypers J, Goldbaum G, Holmes K, et al. Effect of HIV infection on the natural history of anal human papillomavirus infection. *AIDS* 1998; 12:1177-84.
- Tilston P. Anal human papillomavirus and anal cancer. *J Clin Pathol* 1997; 50:625-34.
- Palefsky JM, Holly EA, Ralston ML, Jay N. Prevalence and risk factors for human papillomavirus infection of the anal canal in human immunodeficiency virus (HIV)-positive and HIV-negative homosexual men. *J Infect Dis* 1998; 177:361-7.
- Palefsky JM, Holly EA, Ralston ML, Arthur SP, Jay N, et al. Anal squamous intraepithelial lesions in HIV-positive and HIV-negative homosexual and bisexual men: prevalence and risk factors. *J Acquir Immune Def Syndr Hum Retrovirol* 1998; 17:320-6.
- Rader JS, Kamarasova T, Huettner PC, Li L, et al. Allelotyping of all chromosomal arms in invasive cervical cancer. *Oncogene* 1996;13:2737-41.
- Muleris M, Salmon RJ, Girodet J, Zafrani B, Dutrillaux B. Recurrent deletions of chromosomes 11q and 3p in anal canal carcinoma. *Int J Cancer* 1987; 39:595-8.
- Heselmeyer K, du Manoir S, Blegen H, Friberg B, Svensson C, et al. A recurrent pattern of chromosomal aberrations and immunophenotypic appearance defines anal squamous cell carcinomas. *Br J Cancer* 1997; 76:1271-8.
- Wong CS, Tsao MS, Sharma V, Chapman WB, Pintilie M, Cummings BJ. Prognostic role of p53 protein expression in epidermoid carcinoma of the anal canal. *Int J Radiat Oncol Biol Phys* 1999; 45:309-14.
- Bonin SR, Pajak TF, Russell AH, Coia LR, Paris KJ, et al. Overexpression of p53 protein and outcome of patients treated with chemoradiation for carcinoma of the anal canal: a report of randomized trial RTOG 87-04. *Radiation Therapy Oncology Group. Cancer* 1999; 85:1226-33.
- Gervaz P, Efron J, Alonso Poza A, Chun SW, Pham TT, et al. Loss of heterozygosity and HIV infection in patients with anal squamous-cell carcinoma. *Dis Colon Rectum* 2001; 44:1503-8.
- Fuchshuber PR, Rodriguez-Bigas M, Weber T, Petrelli NJ. Anal canal and perianal epidermoid cancers. *J Am Coll Surg* 1997; 185:494-505.
- Corman ML. Malignant tumors of the anal canal. In: *Colon & Rectal Surgery*, 4th edition Lippincott-Raven Pub. 1998: pp. 863-883.
- Ryan DP, Mayer RJ. Anal carcinoma: histology, staging, epidemiology, treatment. *Curr Opin Oncol* 2000; 12:345-52.
- Savoca PE, Wong WD. Anal carcinoma: anatomy, staging and prognostic variables. In: Cohen AM, Winaver SJ, eds. *Cancer of the Colon, Rectum and Anus*. McGraw-Hill Publ. (1st Ed) 1995: pp 1013-20.
- Harmer MH, ed. *TNM classification of malignant tumors*, 3rd Ed. Geneva, Switzerland, 1978: pp. 77-81.
- Cummings BJ. Anal cancer: radiation, with and without chemotherapy. In: Cohen AM, Winaver SJ, eds. *Cancer of the Colon, Rectum and Anus*. McGraw-Hill Publ. (1st Ed) 1995: pp 1025-42.
- Tarantino D, Bernstein MA. Endoanal ultrasound in the staging and management of squamous-cell carcinoma of the anal canal. *Dis Colon Rectum* 2002; 45:16-22.

- 34 Magdeburg B, Fried M, Meyenberger C. Endoscopic ultrasonography in the diagnosis, staging and follow-up of anal carcinomas. *Endoscopy* 1999;31:359-564.
- 35 Bartram CI, Burnett SJD. In *Atlas of anal endosonography* (1st Ed). Butterworth-Heinemann, Oxford (1991).
- 36 Hill J, Meadows H, Haboubi N, Talbot IC, Northover JMA. Pathological staging of epidermoid anal carcinoma for the new era. *Colorectal Disease* 2003; 5:206-13.
- 37 Nigro ND, Vaitkevicius VK, Buroker T, Bradley GT, Considine B. Combined therapy for cancer of the anal canal. *Dis Colon Rectum* 1981; 24:73-5.
- 38 Longo WE, Vernava AM III, Wade TP, Coplin MA, et al. Recurrent squamous cell carcinoma of the anal canal. Predictors of initial treatment failure and results of salvage therapy. *Ann Surg* 1994; 220:40-9.
- 39 Nilsson PJ, Svensson C, Goldman S, Glimelius B. Salvage abdominoperineal resection in anal epidermoid cancer. *Br J Surg* 2002; 89:1425-9.
- 40 Allal AS, Laurencet FM, Reymond MA, Kurtz JM, Marti MC. Effectiveness of surgical salvage therapy for patients with locally uncontrolled anal carcinoma after sphincter-conserving treatment. *Cancer* 1999; 86:405-9.
- 41 Greenall MJ, Quan SHQ, Stearns MW, et al. Epidermoid cancer of the anal margin. *Am J Surg* 1985;149:95-101.
- 42 Northover JMA, UKCCCR anal cancer trial working party. Epidermoid anal cancer: results from the UKCCCR randomised trial of radiotherapy alone versus radiotherapy, 5-fluorouracil, and mitomycin. *Lancet* 1996; 348:1049-54.
- 43 Bartelink H, Roelofsen F, Eschewege F, et al. Concomitant radiotherapy and chemotherapy is superior to radiotherapy alone in the treatment of locally advanced anal cancer: results of a phase III randomised trial of the European Organization for Research and Treatment of Cancer Radiotherapy and Gastrointestinal Cooperative Groups. *J Clin Oncol* 1997;15:2040-9.
- 44 Vordermark D, Sailer M, Flentje M, Thiede A, Kolbl O. Impaired sphincter function and good quality of life in anal carcinoma patients after radiotherapy: a paradox? *Front Radiat Ther Oncol* 2002; 37:132-9.
- 45 Pocard M, Tiret E, Nugent K, Dehni N, Parc R. Results of salvage abdominoperineal resection for anal cancer after radiotherapy. *Dis Colon Rectum* 1998; 41:488-93.
- 46 Cleator S, Fife K, Nelson M, Gazzard B, Phillips R, Bower M. Treatment of HIV-associated invasive anal cancer with combined chemoradiation. *Eur J Cancer* 2000; 36:754-8.
- 47 Vatra B, Sobhani I, Aparicio T, Girard PM, Puy Montbrun TD, et al. Anal canal squamous-cell carcinomas in HIV positive patients: clinical features, treatments and prognosis. *Gastroenterol Clin Biol* 2002; 26:147-9.
- 48 Place RJ, Gregorcyk SG, Huber PJ, Simmang CL. Outcome analysis of HIV-positive patients with anal squamous cell carcinoma. *Dis Colon Rectum* 2001; 44:506-12.
- 49 Goldie SJ, Kuntz KM, Weinstein MC, Freedberg KA, Welton ML, Palefsky JM. The clinical effectiveness and cost-effectiveness of screening for anal squamous intraepithelial lesions in homosexual and bisexual HIV-positive men. *JAMA* 1999; 281:1822-9.
- 50 Massad LS, Riester KA, Anastos KM, Fruchter RG, Palefsky JM, et al. Prevalence and predictors of squamous cell abnormalities in Papanicolaou smears from women infected with HIV-1. *J Acquir Immune Defic Syndr* 1999; 21:33-41.
- 51 Palefsky JM, Holly EA, Ralston ML, et al. High incidence of anal high grade squamous intraepithelial lesions among HIV positive and HIV negative homosexual and bisexual men. *AIDS* 1998; 12:495-503.
- 52 Palefsky JM, Holly EA, Ralston ML, et al. The effect of highly active antiretroviral therapy on the natural history of anal squamous intraepithelial lesions and anal HPV infection. *J Acquir Immune Defic Syndr* 2001; 28:422-8.

The many reasons why you should choose SMW to publish your research

What Swiss Medical Weekly has to offer:

- SMW's impact factor has been steadily rising, to the current 1.537
- Open access to the publication via the Internet, therefore wide audience and impact
- Rapid listing in Medline
- LinkOut-button from PubMed with link to the full text website <http://www.smw.ch> (direct link from each SMW record in PubMed)
- No-nonsense submission – you submit a single copy of your manuscript by e-mail attachment
- Peer review based on a broad spectrum of international academic referees
- Assistance of our professional statistician for every article with statistical analyses
- Fast peer review, by e-mail exchange with the referees
- Prompt decisions based on weekly conferences of the Editorial Board
- Prompt notification on the status of your manuscript by e-mail
- Professional English copy editing
- No page charges and attractive colour offprints at no extra cost

Editorial Board

Prof. Jean-Michel Dayer, Geneva
 Prof. Peter Gehr, Berne
 Prof. André P. Perruchoud, Basel
 Prof. Andreas Schaffner, Zurich
 (Editor in chief)
 Prof. Werner Straub, Berne
 Prof. Ludwig von Segesser, Lausanne

International Advisory Committee

Prof. K. E. Juhani Airaksinen, Turku, Finland
 Prof. Anthony Bayes de Luna, Barcelona, Spain
 Prof. Hubert E. Blum, Freiburg, Germany
 Prof. Walter E. Haefeli, Heidelberg, Germany
 Prof. Nino Kuenzli, Los Angeles, USA
 Prof. René Lutter, Amsterdam, The Netherlands
 Prof. Claude Martin, Marseille, France
 Prof. Josef Patsch, Innsbruck, Austria
 Prof. Luigi Tavazzi, Pavia, Italy

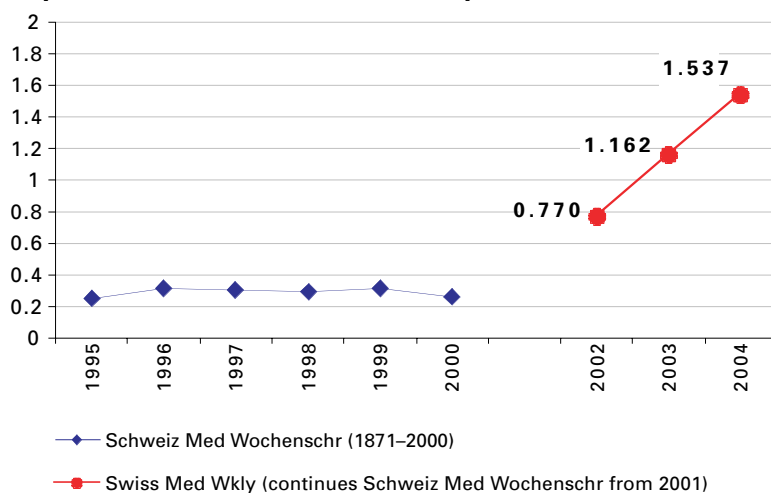
We evaluate manuscripts of broad clinical interest from all specialities, including experimental medicine and clinical investigation.

We look forward to receiving your paper!

Guidelines for authors:

http://www.smw.ch/set_authors.html

Impact factor Swiss Medical Weekly




EMH **FMH**
SCHWABE
 Editores Medicorum Helveticorum

All manuscripts should be sent in electronic form, to:

EMH Swiss Medical Publishers Ltd.
 SMW Editorial Secretariat
 Farnsburgerstrasse 8
 CH-4132 Muttenz

Manuscripts: submission@smw.ch
 Letters to the editor: letters@smw.ch
 Editorial Board: red@smw.ch
 Internet: <http://www.smw.ch>