



Article
scientifique

Revue de la
littérature

2024

Published
version

Open
Access

This is the published version of the publication, made available in accordance with the publisher's policy.

PET Imaging in Dementia : Mini-Review and Canadian Perspective for Clinical Use

Juengling, Freimut; Wuest, Frank; Schirmacher, Ralf; Abele, Jonathan; Thiel, Alexander; Soucy, Jean-Paul;
Camicioli, Richard; Garibotto, Valentina

How to cite


JUENGLING, Freimut et al. PET Imaging in Dementia : Mini-Review and Canadian Perspective for
Clinical Use. In: Canadian journal of neurological sciences, 2024, p. 1–13. doi: 10.1017/cjn.2024.31

This publication URL: <https://archive-ouverte.unige.ch//unige:177247>

Publication DOI: [10.1017/cjn.2024.31](https://doi.org/10.1017/cjn.2024.31)

Review Article

PET Imaging in Dementia: Mini-Review and Canadian Perspective for Clinical Use

Freimut Juengling^{1,2,3} , Frank Wuest², Ralf Schirmacher^{2,4}, Jonathan Abele⁵, Alexander Thiel⁶, Jean-Paul Soucy⁷, Richard Camicioli^{1,8} and Valentina Garibotto⁹

¹Neuroscience and Mental Health Institute, University of Alberta, Edmonton, AB, Canada, ²Division of Oncologic Imaging and Radionuclide Therapy, Cross Cancer Institute, Edmonton, AB, Canada, ³Medical Faculty, University of Bern, Bern, Switzerland, ⁴Medical Isotope and Cyclotron Facility, University of Alberta, Edmonton, AB, Canada, ⁵Department of Radiology and Diagnostic Imaging, University of Alberta, Edmonton, AB, Canada, ⁶Department of Neurology and Neurosurgery, Lady Davis Institute for Medical Research, McGill University, Montréal, QC, Canada, ⁷Montréal Neurological Institute, McGill University, Montréal, QC, Canada, ⁸Department of Medicine, Division of Neurology, University of Alberta, Edmonton, AB, Canada and ⁹Diagnostic Department, Nuclear Medicine and Molecular Imaging Division, University Hospitals of Geneva, Geneva, Switzerland

ABSTRACT: PET imaging is increasingly recognized as an important diagnostic tool to investigate patients with cognitive disturbances of possible neurodegenerative origin. PET with 2-^[18F]fluoro-2-deoxy-D-glucose (^[18F]FDG), assessing glucose metabolism, provides a measure of neurodegeneration and allows a precise differential diagnosis among the most common neurodegenerative diseases, such as Alzheimer's disease, frontotemporal dementia or dementia with Lewy bodies. PET tracers specific for the pathological deposits characteristic of different neurodegenerative processes, namely amyloid and tau deposits typical of Alzheimer's Disease, allow the visualization of these aggregates *in vivo*. ^[18F]FDG and amyloid PET imaging have reached a high level of clinical validity and are since 2022 investigations that can be offered to patients in standard clinical care in most of Canada.

This article will briefly review and summarize the current knowledge on these diagnostic tools, their integration into diagnostic algorithms as well as perspectives for future developments.

RÉSUMÉ : La tomographie par émission de positons dans la prise en charge de la démence : une mini-revue et une perspective canadienne en vue d'une utilisation clinique

La tomographie par émission de positons (TEP) est un examen d'imagerie de plus en plus reconnu comme outil de diagnostic important pour étudier les patients présentant des troubles cognitifs dont l'origine est possiblement neurodégénérative. La TEP au moyen d'une molécule de fluor 18 (18-FDG), qui évalue le métabolisme du glucose, fournit une mesure de la neurodégénérescence et permet un diagnostic différentiel précis entre les maladies neurodégénératives les plus courantes, par exemple la maladie d'Alzheimer, la démence fronto-temporale ou la démence à corps de Lewy. Dans le cas de la TEP, les traceurs spécifiques des dépôts pathologiques caractéristiques des différents processus neurodégénératifs, à savoir les dépôts amyloïdes et tau typiques de la maladie d'Alzheimer, permettent de les visualiser *in vivo*. Ajoutons aussi que la TEP au moyen d'une molécule 18-FDG et de l'amyloïde a atteint un niveau élevé de validité clinique et fait partie depuis 2022 des procédures qui peuvent être proposées aux patients dans le cadre des soins cliniques standards offerts dans la plupart des provinces du Canada. Cet article entend donc passer brièvement en revue et résumer les connaissances actuelles au sujet de ces outils de diagnostic, leur intégration dans les algorithmes au service d'un diagnostic médical ainsi que les perspectives de développement futur.

Keywords: Alzheimer's disease; amyloid; dopamine transporters; DOPA; Frontotemporal lobar degeneration; glucose metabolism; Parkinsonism; PET; SPECT; tau

(Received 11 September 2023; final revisions submitted 17 February 2024; date of acceptance 23 February 2024)

Introduction

Cognitive disorders are a priority public health issue, considering their steadily increasing prevalence associated with an aging population throughout the world. There are over 50 million people worldwide living with dementia in 2020 and this number is

expected to double every 20 years, reaching 139 million in 2050, with the fastest increase occurring in developing countries.¹ Their economic impact is very relevant, with nearly 820 billion dollars in 2015, requiring proportionate research investment in prevention, treatment, care and cure.²

Corresponding author: F. Juengling; Email: fjuengli@ualberta.ca

Cite this article: Juengling F, Wuest F, Schirmacher R, Abele J, Thiel A, Soucy J-P, Camicioli R, and Garibotto V. PET Imaging in Dementia: Mini-Review and Canadian Perspective for Clinical Use. *The Canadian Journal of Neurological Sciences*, <https://doi.org/10.1017/cjn.2024.31>

© The Author(s), 2024. Published by Cambridge University Press on behalf of Canadian Neurological Sciences Federation. This is an Open Access article, distributed under the terms of the Creative Commons Attribution licence (<http://creativecommons.org/licenses/by/4.0/>), which permits unrestricted re-use, distribution and reproduction, provided the original article is properly cited.

A better understanding of the diseases underlying cognitive impairment is one of the key elements to tackle this issue, namely establishing an early and correct diagnosis to implement medical and social care adapted to each individual patient. This may include personalized support, but also the introduction of treatments to slow the progression of the decline and reduce its symptoms. An improvement in diagnosis is also a prerequisite to properly test disease-modifying therapeutic strategies, some of which have recently shown promising results.³⁻⁵

The clinical picture of cognitive disturbances alone does not allow identification of its underlying cause with adequate precision, and to differentiate, for example, a cognitive decline due to depression, from a neurodegenerative process. Among the main causes of dementia or cognitive impairment, the most common are Alzheimer's disease (AD) – which alone accounts for two thirds of cases – vascular dementia, Lewy body dementia and frontotemporal dementia.

The role of imaging as biomarker in cognitive disorders

The initial diagnosis of a cognitive disorder is based on clinical and neuropsychological assessment, following which etiological hypotheses can be established, which are then confirmed or refuted through the use of different disease biomarkers. Among biomarkers, brain imaging plays a central role and includes morphological imaging with Magnetic Resonance Imaging (MRI) as well as functional and molecular imaging with Positron Emission Tomography (PET) and single photon emission computed tomography (SPECT). Thanks to recent technological advances, it is now possible to establish a precise etiological diagnosis in the majority of the cases.⁶

The initial goal of anatomical imaging is to verify whether a treatable cause can explain the cognitive disorders (e.g.: ischemia/infarct, extra-/subdural hematoma, hydrocephalus, tumor). It can then be used to guide the diagnosis, in particular by evaluating the presence of regional brain atrophy that could suggest a primary degenerative dementia, as well as the load of vascular lesions or white matter lesions in general.⁷ The recommended first-line morphological imaging modality is MRI, which is more sensitive than CT.⁸

Molecular imaging by PET

Namely in the case of a clinically atypical or rapidly progressing form of cognitive impairment, in young patients (<65 years) and in all cases in which the combination of clinical, neuropsychological and morphological imaging assessment does not allow the physician to establish an etiological diagnosis with an adequate level of confidence, functional and molecular imaging examinations can be a valuable complementary tool.⁹ Several imaging modalities using different radiotracers have been tested.¹⁰ We will discuss here the most commonly used PET tracers, which are already established or have recently been introduced into clinical practice. These could be roughly divided in two main categories: tracers measuring the presence of neurodegeneration or tracers specific for pathological deposits.

PET markers of neurodegeneration

PET markers of neurodegeneration measure a functional parameter for a brain region or pathway which is typically affected by a neurodegenerative process and more or less tightly linked with clinical symptoms. Neurodegeneration markers per definition are nonspecific endpoints, as they do not distinguish between different

etiologies affecting the same functional process; however, they can contribute to the process of differential diagnostic as the various etiologies usually have some pattern specificity.

Fluorodeoxyglucose (¹⁸F]FDG) PET

The most commonly used neurodegeneration PET marker is 2-[¹⁸F]fluoro-2-deoxy-D-glucose (¹⁸F]FDG). Brain PET imaging with [¹⁸F]FDG allows to measure regional brain glucose metabolism, using a radiotracer consisting of a glucose molecule on which a hydroxyl group has been replaced by 18-fluorine. This radiotracer is delivered to the brain from blood vessels primarily via glucose transporter Glut-1, and then subject to intracellular phosphorylation. 18-Fluoro-2-deoxy-D-6-phosphate, however, is a poor substrate for subsequent metabolism in the glycolytic chain, thus remaining trapped and accumulating in the cells, allowing the study of regional cellular metabolism. The examination is usually performed with hybrid devices that combine PET acquisition with computed tomography imaging (PET/CT) and most recently with MRI (PET/MRI).

As the physiological brain metabolism is glucose-dependent, the mapping of brain glucose metabolism generally is a reflection of neuronal and synaptic activity and thus allows topographical detection of hypo- or hyperfunctional areas, corresponding to a loss or a synaptic dysfunction at these levels. Since hypometabolism has a different regional topography for different neurodegenerative disorders, [¹⁸F]FDG PET has been established as a clinically validated tool useful to differentiate between them.¹¹⁻¹³

In AD, a typical topographic pattern of metabolic changes involving mainly the posterior cortex is seen, with hypometabolism of the temporo-parietal neocortex and posterior cingulate gyrus, whereas the primary visual cortex, the cerebellum and the central gray nuclei are relatively spared. This pattern has been a stable and consistent finding through longitudinal as well as cross-sectional studies during the past 20 years, and [¹⁸F]FDG PET is likely the most thoroughly validated diagnostic tool in dementia, with a summarized evidence of a sensitivity of 80% and a specificity of 90% for AD in the dementia stage.¹² While there is no effective Lewy body PET ligand, [¹⁸F]FDG PET also is helpful in distinguishing Lewy Body Dementia from other dementia, with Lewy Body Dementia showing occipital hypometabolism with sparing of the posterior cingulate (cingulate island sign) and basal ganglia hypermetabolism.¹⁴ Dopamine imaging using SPECT (¹²³I]FP-CIT) or PET (¹⁸F]F-Dopa) may be more specific indicating dopamine system denervation.¹⁵⁻¹⁷ The development of cerebrospinal fluid (CSF) markers for synuclein holds the promise of introducing less invasive biomarkers, which are anticipated to significantly impact clinical practices once they become widely available.¹⁸⁻²⁰ A caution will be the recognition that many cases of age-related neurodegeneration can show mixed pathology. Moreover, in early stages (i.e., MCI) PET in differential diagnosis may be more challenging.

Despite its limitations, [¹⁸F]FDG PET remains a mainstay of diagnostic criteria for various degenerative conditions, namely:

- Alzheimer's Dementia (AD)²¹
- Mild Cognitive Impairment (MCI)²²
- frontotemporal dementia (FTD)²³
- corticobasal degeneration²⁴
- progressive supranuclear palsy²⁵
- multiple system atrophy (MSA)²⁶ and
- Lewy Body dementia (LBD)¹⁴

The identification of regional patterns of hypometabolism is based on visual interpretation of radiotracer distribution images, supported by a statistical voxelwise comparison with the normal distribution, as observed in healthy individuals. Multiple studies have consistently shown that the support of the semi-quantitative analysis improves the sensitivity and the specificity of [¹⁸F]FDG PET, even if this might differ across software.^{27,28}

The analysis of glucose metabolism is not only a valid diagnostic marker in various conditions, but also allows studying a number of pathophysiological processes, e.g. the specific networks associated with specific symptoms,^{29–31} or the reserve phenomenon, i.e. the ability of the brain to cope with neurodegeneration by using alternative functional pathways.³²

Synaptic vesicle protein 2a (SV2A) PET

As a still experimental PET neurodegeneration marker, a number of tracers targeting the synaptic vesicle protein 2a receptor (SV2A) have been developed.^{33–36} These have shown to represent synaptic density.³⁷ The advantages of SV2A imaging in Alzheimer's disease over [¹⁸F]FDG PET include a higher sensitivity for early detection of neurodegeneration in the hippocampus, potentially improving the differential diagnosis and prediction of disease progression even in the prodromal (MCI) stage of the disease, where [¹⁸F]FDG PET often fails to find significant reduction in regional cerebral glucose metabolism (rCGM), unless complex corrections for partial volume correction and spatial mapping are performed.^{38–40} In previous trials, SV2A PET has shown reductions in synaptic density *in vivo* in the entorhinal cortex and hippocampus of individuals with amnesic MCI and mild AD dementia,⁴¹ reflecting the pathological Braak stages I–III.⁴² This marks the first demonstration of *in vivo* imaging correlates within a single imaging modality for a pathological staging system in AD.

SV2A-PET also has shown a distinct differential pattern of neurodegeneration for LBD,^{43,44} offering an additional tool for the differential diagnostic between LBD and AD. While availability is currently the main limitation for a more widespread use, it has the potential to possibly replace the role of [¹⁸F]FDG PET in the future, provided it becomes more widely available. In Canada, SV2A-PET is currently available or in use for clinical trials at the Universities of Alberta and Toronto.⁴⁵

PET markers of pathology

Over the last two decades, a novel category of PET radiotracers has revolutionized the study of AD and other neurodegenerative disorders, i.e. PET tracers specific for amyloid and tau pathological deposits. As the gold standard for AD diagnosis is based on the postmortem immunohistological detection of amyloid and tau pathology, the availability of PET markers specific for these targets has opened the opportunity for an *in vivo* visualization of their presence and distribution, and ultimately for *in vivo* diagnosis. This has been reflected in the National Institute on Aging – Alzheimer's Association (NIA-AA) Research Framework recommendation towards a biological definition of AD by presence of biological markers using the A/T/N classification, where A stands for Amyloid, T for Tau and N for Neurodegeneration.⁴⁶

Other conditions characterized by specific pathological deposits, namely by the alpha-synuclein deposits, are Parkinson's Disease (PD) and LBD; while FTD is characterized by TDP-43 and tau deposits. The development of PET markers for these conditions, however, is still in the earliest phases of development (see 6.1).

Amyloid PET

Over the last two decades, a number of tracers have been developed targeting extracellular beta-amyloid plaques with high sensitivity and specificity. Since the first report of successfully targeting beta-amyloid in 2004 using the PET tracer named Pittsburgh compound B (PiB), labeled with carbon-11,⁴⁷ various fluorinated tracers have been developed, allowing tracer commercialization and distribution. These tracers, namely [¹⁸F]-Florbetapir, [¹⁸F]-Flutemetamol and [¹⁸F]-Florbetaben, have been validated for their accuracy in predicting the presence of neuropathological changes and are or have been authorized and marketed in the US and in Europe. [¹⁸F]-Florbetaben has been approved for marketing in Canada in 2017,⁴⁸ Table 1.

Image analysis shows a physiological fixation of the tracer within white matter in a negative case, and conversely, an increased uptake in cortical areas will be considered positive for cortical deposition of amyloid plaques. Specific reading guidelines have been developed for each tracer.

Negative imaging can exclude a diagnosis of AD, whereas positive imaging, especially in association with an imaging marker of neurodegeneration, such as temporomesial atrophy or posterior hypometabolism, allows the identification of prodromal AD among subjects with mild cognitive impairment (MCI) (cf. Figure 1).

Visual interpretation of images is usefully supported by semi-quantitative indices, usually based on a ratio between cortical uptake and uptake in a reference region (often the cerebellum or white matter structures, such as supratentorial white matter or the pons). Importantly, a common scale, called "Centiloid," has been proposed and is increasingly adopted in order to standardize the semi-quantitative measures obtained with different tracers.

The Centiloid scale is a method used to standardize and compare quantitative measurements of amyloid burden obtained from positron emission tomography (PET) scans. It converts the raw PET data into a common scale, making it easier to interpret and compare results from different studies and imaging centers. The Centiloid value (CL) is calculated using a three-level process, which involves scaling the data to a common reference and then applying a non-negative matrix factorization model to improve its robustness in longitudinal studies. For initial scaling, 0- and 100-anchor points of the Centiloid scale have been defined, with the 0-anchor point to represent a definitively amyloid-negative brain scan, and the 100-anchor to represent the amount of global amyloid deposition found in a typical mild-moderate AD subject. The Centiloid scale, being a mean value, may result in slightly negative values for some amyloid-negative scans. Similarly, there will be a range of "typical AD values" around 100 CL, and approximately half of all AD subjects will have values above 100 CL, sometimes significantly so. The benefits of the Centiloid scale include the ability to draw intuitive conclusions, reduce variability in measurements, improve sensitivity and make results more easily comparable across different analysis techniques and large datasets, and has been adapted to all of the currently available amyloid PET tracers.^{49–51}

The largest body of the literature so far is, however, based on a binary classification of amyloid PET scans, as positive or negative, but recent data suggest that visual interpretation can also be sensitive for the earliest phases of amyloid accumulation, possibly providing relevant staging and prognostic information, even if this still needs to be confirmed in prospective studies.⁵²

As a most recent advancement, "early frame" acquisitions of amyloid PET tracers, i.e. acquisitions performed immediately after injection of the radiotracer, usually during the first 5 to 10 minutes, can provide an estimate of relative regional brain perfusion. Given

Table 1: Reimbursement of PET for dementia in Canada (modified and updated from ⁷⁸)

Jurisdiction	Non-cancer indications : Dementia listed?	How is it delivered?	How is it paid for
British Columbia	PET imaging is not regularly provided for non-cancer indications.	PET imaging is not provided for non-cancer indications. Case-by-case exceptions may apply.	PET imaging is not regularly provided for non-cancer indications. PET imaging for dementia is reimbursed on a case-by-case basis
Alberta	Dementia is listed as indication, and FDG as well as amyloid imaging are explicitly noted	The PET program is run by Alberta Health Services, and patients are referred to services through the provincial directory	PET imaging for non-cancer indications including dementia are covered by the Alberta Health Care Insurance Plan
Saskatchewan	Dementia is listed as indication	Saskatchewan's single PET/CT unit is located in a hospital and requires advance booking from a physician	PET imaging for the specified clinical indications including dementia are covered with a valid Saskatchewan Health Service Card through the Saskatchewan Health Authority
Manitoba	Dementia is listed as indication	Manitoba's single PET/CT unit is located in a hospital	The province of Manitoba funds 2,000 scans per year for patients who meet the clinical indications.
Ontario	Dementia is not listed as indication on the 2023 PET Scans Ontario Indications List	<ul style="list-style-type: none"> • PET-CTs can be accessed through: • Ontario Health Insurance Plan, when there is evidence that the scan will benefit the patient; <hr/> or the Ontario PET Registry, which makes scans available when there is some evidence for success but not enough to receive insurance; <hr/> or provincial clinical trials, which have been approved by the PET Steering Committee and are being conducted by the Ontario Clinical Oncology Group; <hr/> or the Ontario PET Access Program, in which a panel of experts considers physician requests when patients do not meet eligibility criteria for the scan	<p>The PET Steering Committee evaluates all other routes of PET-CI access (Ontario PET Registry, clinical trials, Ontario PET Access Program)</p> <hr/> <p>The committee is made up of experts who review clinical situations where PET scans may be indicated, considering scientific evidence and prioritizing based on impact on patient care</p>
Quebec	Indicated in certain cases in neurocognitive disorders (when identifying the disease process could change treatment plan)	Tests must be requested by a healthcare professional	Financing of PET is included in global budgets of hospitals and is not limited to any types of diagnostics or indications
Nova Scotia	Dementia is not listed as indication, but non-listed indications may be approved by Medical Services Insurance on an individual case basis	<p>Nova Scotia's single PET unit is located in a hospital</p> <hr/> Tests must be requested by a specialist	PET-CT imaging is funded through the Cancer Care Nova Scotia program
New Brunswick	PET imaging is not provided for non-cancer indications	PET imaging is not provided for non-cancer indications	PET imaging is not provided for non-cancer indications
Prince Edward Island	The province does not have a PET unit	The province does not have a PET unit	While the province does not have a PET unit, they do fund exams out-of-province
Newfoundland and Labrador	A PET was recently added in the province, however specific indications were not identified through publicly available sources on websites reviewed	PET imaging must be requested by a specialist	Unable to determine how PETs are funded for non-cancer indications based on the available information

that metabolic coupling of perfusion and glucose metabolism has been reported to be grossly undisturbed in neurodegenerative conditions, “early frame” acquisitions are closely correlated to [¹⁸F] FDG PET images, thus simultaneously allowing for obtaining information on neurodegeneration, combined with the information on amyloid status, using a multiphase acquisition.^{53,54} An example of “early frame” 18F-flutemetamol imaging obtained from 1 to 11 minutes post injection, in comparison with the result of [¹⁸F]FDG PET imaging, is provided in Figure 2. If a patient is scheduled for an amyloid PET scan as part of a clinical workup and has not undergone a previous [¹⁸F]FDG PET scan, obtaining an

early frame of the amyloid PET scan may thus eliminate the need for an additional [¹⁸F]FDG PET scan for clinical purposes.

Although there is a significant amount of literature in the field, the reimbursement of amyloid PET has been met with reluctance in most countries.⁹ This is mainly linked to the lack of studies showing, beyond its analytical and clinical validity, its impact on patients' management and care. With the first disease-modifying therapies using amyloid-antibodies having been FDA-approved^{55,56}, reimbursement status is gradually changing, as the proof of target expression may be required prior to initiation of an expensive – and not risk-free – antibody therapy. Currently,

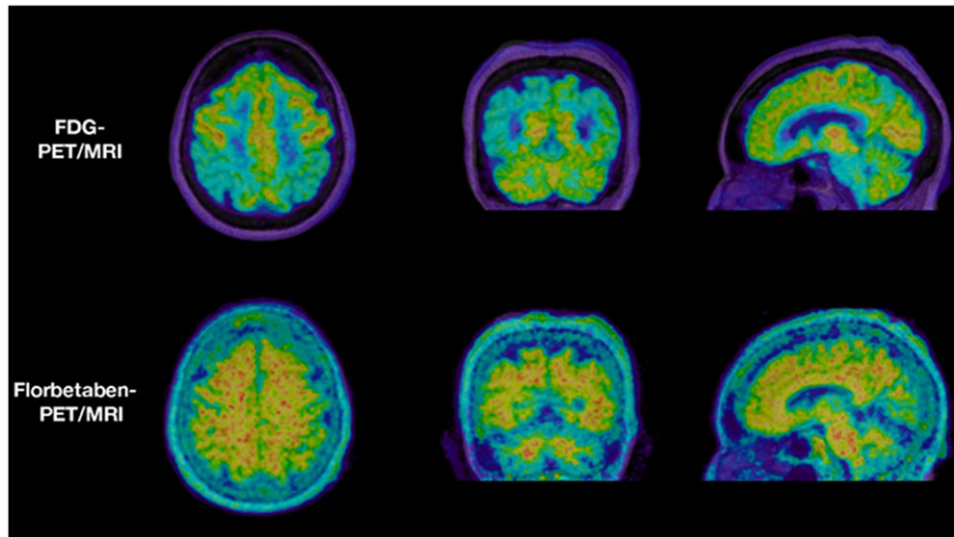


Figure 1: 71 year old male patient with mild cognitive impairment, Mini Mental State Exam (MMSE) score 27. ^{18}F FDG-PET in representative, axial, coronal and sagittal orientation demonstrates temporoparietal and cingulate hypometabolism in a pattern typically seen in early AD (upper panel), while ^{18}F -florbetaben-PET demonstrates significant cortical amyloid load, predominantly in the hypometabolic areas. PET images are fused with the individual patient's morphological T1-weighted MR images (PET/MRI, isotropic MPRAGE images for coregistration and image display).

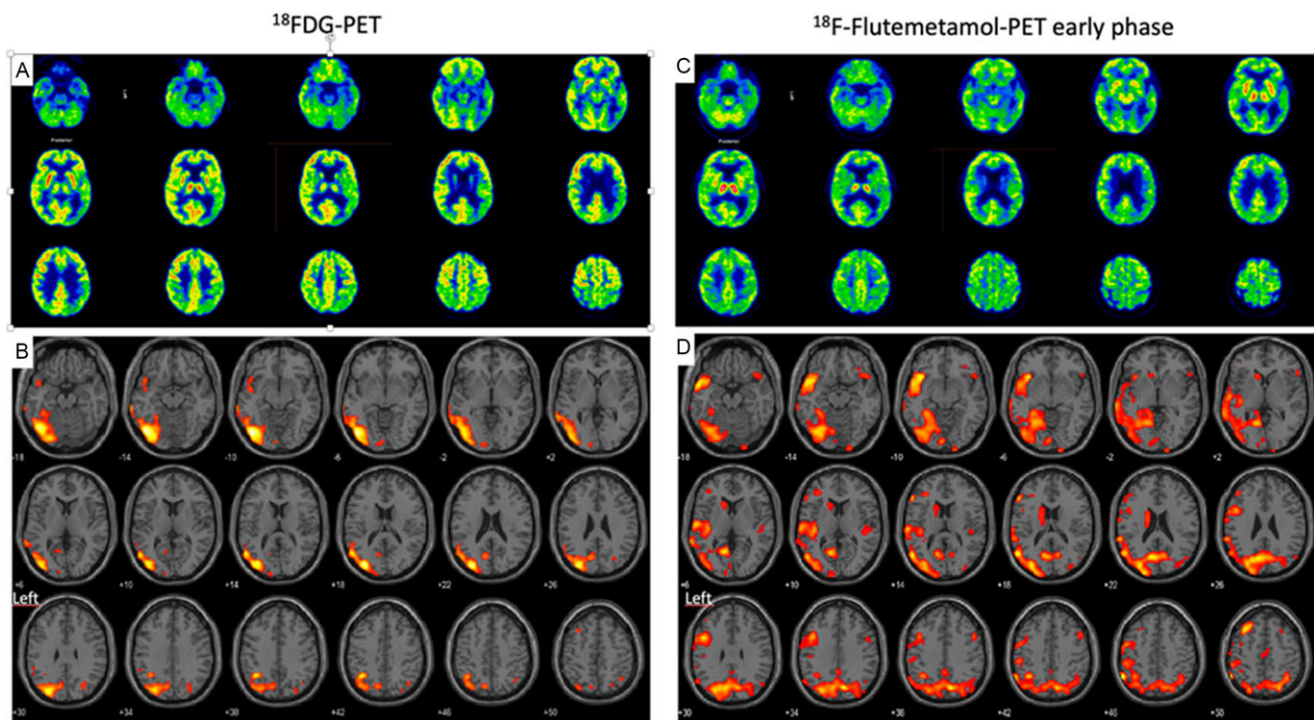


Figure 2: Patient with probable AD and cognitive deficits including aphasia. ^{18}F FDG-PET demonstrates a significant, predominantly left temporoparietal hypometabolism (a). Voxel-based comparison to a reference database (b) depicts brain regions with metabolism exceeding two standard deviations below norm (red color scale overlaid on a standard MR anatomical template, statistical parametric mapping, in neurological convention, left on the left side of the image). The early phase of ^{18}F -flutemetamol-PET demonstrates hyperperfusion concordant to ^{18}F FDG-PET (c) and its deviation from norm (d). Results of amyloid-PET and tau-PET of the same patient are shown in Figure 3 and Figure 4.

amyloid PET is reimbursed in Switzerland since August 2020,⁸⁴ in France since August 2022,⁵⁸ in the U.S since October 2023⁵⁹ and in Japan since November 2023.⁶⁰ In Germany, amyloid PET is currently available to patients under an evidence development study protocol.⁶¹

Large prospective studies focusing on the impact of amyloid PET images on patient management,^{62,63} were able to demonstrate that amyloid PET changes the care plan and medication prescription in over 60% of cases, both in MCI and in patients with dementia.⁶²

Tau PET

Finally, among the latest pathophysiological radiotracers developed for the diagnosis of AD are the tau radiotracers. Hyperphosphorylation and abnormal intracellular aggregation of tau proteins constitutes the second molecular marker of AD, in association with extracellular amyloid plaques. Tau targeting PET tracers have been developed mainly to selectively bind tau isoforms typical of AD pathology, i.e. neurofibrillary tangles. Tau PET images allow the visualization of the progressive accumulation of the radiotracer in different brain regions, in agreement with

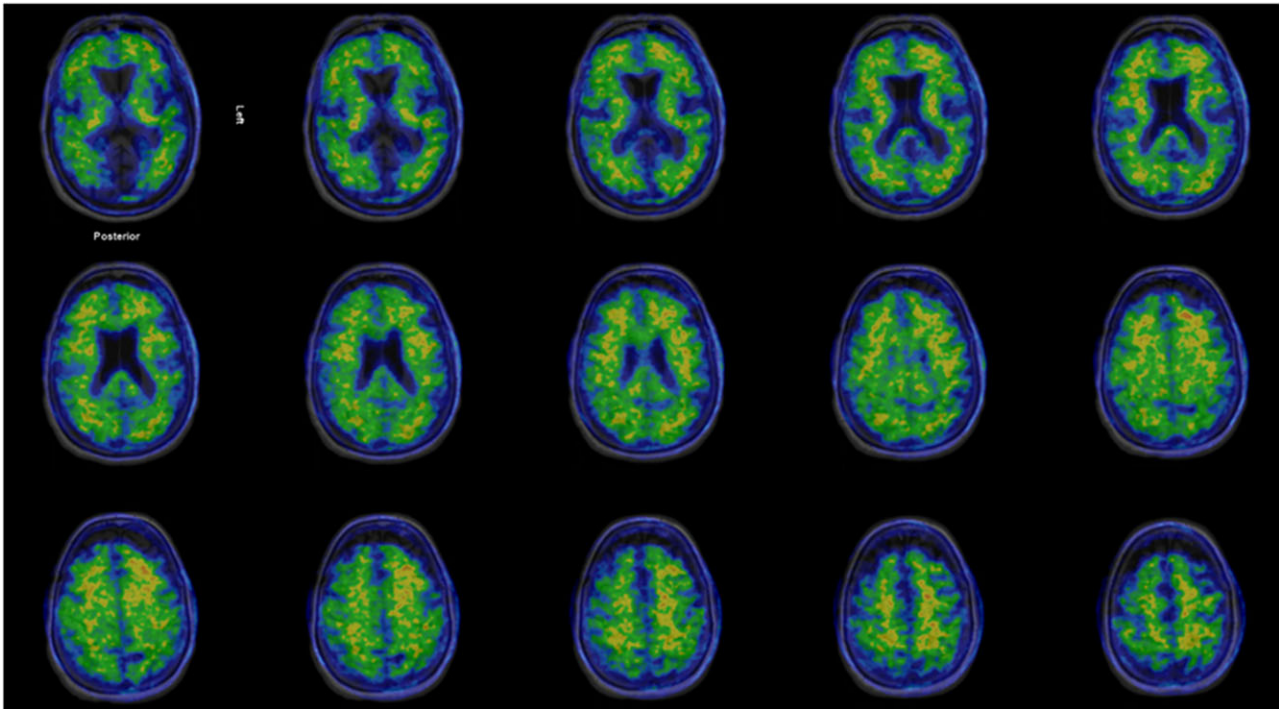


Figure 3: ^{18}F -flutemetamol-PET in patient with probable AD and cognitive deficits (same patient as in Fig. 2, images acquired at recommended time interval). The study demonstrates a typical case of increased cortical amyloid in frontal cortex, posterior cingulate and temporolateral cortex, with the occipital cortex being spared. PET images are fused to the patient's T2-FLAIR-MR images.

topographic patterns of Braak stages, as described from neuropathological studies.

This is a rapidly evolving field and one of the first-generation tracers tested, [^{18}F]-Flortaucipir, has obtained approval for clinical use from the Food and Drug Administration in 2020.⁶⁴ These tracers have a great potential for staging and monitoring AD, but also for distinguishing AD versus non-AD pathologies, since they allow accurate measurement of the advanced neuropathological stages of AD that are almost invariably associated with the presence of amyloid plaques⁶⁵ – an example of results of amyloid-PET and tau PET of the same patient are shown in Figure 3 and Figure 4. A strong clinical added value is expected based on the observation that tau PET combines the specificity for the disease process with the ability to stage it and thus provide relevant prognostic information, with the potential to usefully complement or even replace amyloid PET and [^{18}F]FDG PET in specific indications.⁶⁶

Many other first-generation and second-generation tracers have been or are being tested, all with a different degree of affinity for AD and non-AD tau pathology as well as different off-target binding profiles.^{10,67} While first-generation tracers demonstrated off-target binding in up to 10% of cognitively normal elderly, the second generation and third generation tracers have further improved on their specificity to diverse Tau fibril strains.

Several tau tracers are currently being used in clinical research studies at various Canadian universities, including the Universities of British Columbia, London, Montréal and Toronto.⁶⁸ However, none of these tracers has been authorized by Health Canada for routine clinical use as of yet.

In summary, while tau PET imaging holds promise for the diagnostic assessment of patients with cognitive impairment, its limitations in differentiating various neurodegenerative disorders and its utility in early disease stages should be taken into

consideration. Potential off-target binding should always be kept in mind for clinical interpretation, which also will include assessment of further biomarkers, as negative results do not exclude other coexistent neurodegenerative disorders. Data to define their utility in differentiating non-AD tauopathies at an individual-patient level also is still limited.

PET imaging in diagnostic algorithms

As discussed above, multiple PET tracers can be proposed to refine the diagnosis of patients with cognitive impairment of a neurodegenerative etiology, and they all contribute with different and possibly complementary information. However, it is important to emphasize that diagnostic tools in clinical practice should be limited to those that are *required* to reach a diagnosis and favorably *impact* patient management.

Evidence-based recommendations in this sense are still lacking. Recently completed or ongoing prospective large scale studies, mainly in the field of amyloid imaging, will provide pivotal data to answer these questions.⁶³ The majority of the studies conducted so far focused on the diagnostic performance of individual tests, and only a few studies have focused on the incremental diagnostic value of additional tests, when the result of other investigations already is available.^{69–71}

The diagnostic algorithms currently available are mainly based on expert consensus, and overall converge in proposing a stepwise approach, in which morphological imaging, MRI when possible, represents the first-line investigation, and the test to propose as second line investigation depends on the clinical and neuropsychological profile and thus the prevalent etiological hypothesis.^{6,72,73} The level of diagnostic confidence reached on the basis of the results of the first test will help in deciding if the

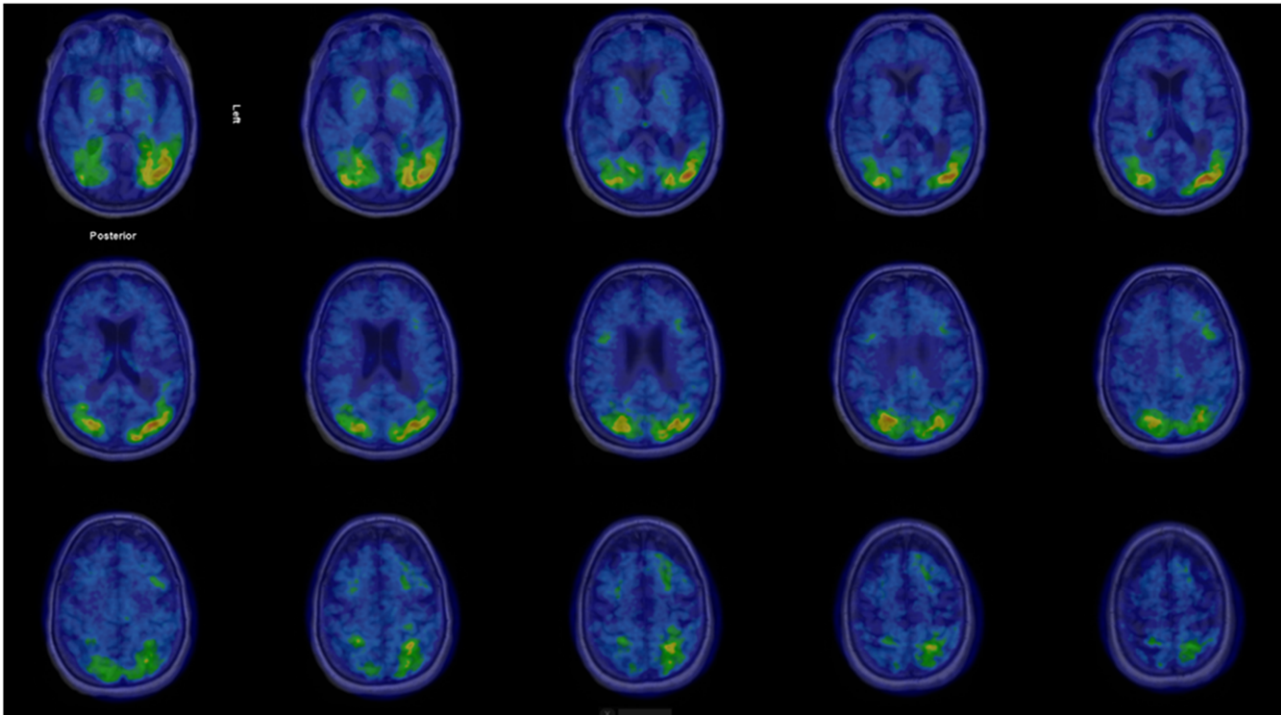


Figure 4: ^{18}F -flortaucipir-PET in patient with probable AD and cognitive deficits (same patient as in Fig. 2 and Fig. 3). PET demonstrates increased, predominantly left-sided cortical tau deposits in temporooccipital, parietal and frontal cortex, fused to coregistered T1-3D-MRI. Regions with increased tau deposits correlate well with hypometabolic areas seen in ^{18}F FDG-PET (Fig. 2) but are significantly more extensive than the metabolic changes.

investigations should stop or continue. In Canada, four Canadian Consensus Conferences on the Diagnosis and Treatment of Dementia have provided guidelines in general since 2012,^{74,75} with a separate consensus guidelines on the use of amyloid imaging in Canada issued 2016.⁷⁶ These guidelines also include dopaminergic imaging, an important tool to evaluate the integrity of the nigrostriatal system, typically involved in LBD. A detailed review on the respective dopaminergic imaging methods is given in the joint practice guideline by the European Association of Nuclear Medicine and the Society of Nuclear Medicine and Molecular Imaging issued in 2020.⁷⁷

PET imaging for dementia: availability and reimbursement conditions in Canada

Public provision and funding of PET imaging for non-cancer indications varies widely within provinces of Canada. A survey conducted by the McMaster Health Forum in 2018⁷⁸ has shown that comprehensive information about reimbursement conditions were difficult to access, not all data for all provinces were publicly available, or the publicly available information were out-of-date. In this survey, PET imaging for dementia was only listed in 5 out of 10 Canadian provinces among the procedures reimbursed by the health insurances in Canada (Table 1, modified from⁷⁸)

^{18}F FDG as a radiopharmaceutical for PET imaging is widely available throughout the Canadian provinces, has received Health Canada approval, and is generally reimbursed for oncologic imaging, but not paid for neurological indications in a minority of provinces. The amyloid-tracer Flortbetaben (NeuraCeq[®]) has received marketing authorization from Health Canada for the commercial production and market supply in March 2017, but is currently produced only in a single production site in Hamilton (ON), which reduces its availability due to the short physical half-life of its

radioligand ^{18}F of less than 2 hours, even when directly shipped by air courier. Availability could be improved if production were out-licensed to one or more adequately equipped radiopharmacies, as established in many PET-Centers countrywide.

In many countries with comparable Health Systems, including the United States, France, Germany, Switzerland and Japan, ^{18}F FDG PET as well as amyloid PET are available to be used for diagnostic algorithms in dementia as proposed^{57,79–81}. The current practice in Canada regarding availability and reimbursement allows for the use of ^{18}F FDG PET for the differential diagnosis of dementia in the majority of provinces. However, due to cost and availability, amyloid-PET is yet rarely used for this purpose.

Once better availability is provided, similar to the practice in the U.S., Europe and Japan, the use of amyloid-PET is expected to significantly increase in Canada, given its role in determining patient candidates for therapy modifying treatment. Currently, albeit being invasive in nature, cerebrospinal fluid markers including amyloid-beta, tau and p-tau are more used in tertiary care settings to rule in Alzheimer pathology. Novel blood markers, particularly those related to amyloid and tau are not currently in clinical practice in Canada.

Trends and future perspectives for PET molecular imaging in dementia

Three main current trends will impact the role of PET molecular imaging for cognitive disturbances in the near future:

- the development of novel tracers,
- the advent of blood plasma markers of pathology and
- the advent of disease-modifying drugs for neurodegenerative diseases.

Development of novel PET tracers

The evolution of molecular imaging is fundamentally linked to the availability and validation of novel markers, allowing to extend the spectrum of imageable targets and to improve the sensitivity and specificity of the measure.

In the field of neurodegenerative disorders, the validation of novel tracers is of the utmost importance to image: (i) pathological deposits, such as alpha-synuclein, TDP-43 or tau isoforms typical for non-AD tauopathies; (ii) pathophysiological processes linked to the brain response to pathology, such as neuroinflammation, or synapses loss.

Alpha-synuclein PET imaging

There have been a number of efforts to develop a PET tracer specific for α -synuclein,⁸² with first-in-human scans just recently presented.⁸³ None of these are currently available in Canada. The relevance of α -synuclein PET imaging lies in its potential to serve as a key biomarker for the evaluation of Parkinson's disease (PD) and related disorders, including dementia with Lewy bodies (DLB) and MSA. Alpha-synuclein is a critical protein associated with the pathogenesis of PD, and its aggregation is a hallmark of these neurodegenerative conditions. Additionally, α -synuclein PET imaging may offer insights into the progression of α -synuclein pathology in the brain, which is essential for monitoring disease advancement and assessing treatment efficacy.

The current evidence suggests that α -synuclein PET imaging is not specific for the diagnosis of LBD. However, it shows potential in distinguishing MSA from other neurodegenerative diseases.⁸⁴

TDP-43 PET imaging

Concerted efforts have been made to develop a TDP-43 specific tracer, all of which being still in the preclinical phase, and are not yet available in Canada. TDP-43, short for Transactive response DNA binding protein 43 kDa, is a protein primarily localized in the cell nucleus that binds to nucleic acids. It plays a crucial role in alternative splicing and is encoded by the TDP-43 gene on Chromosome 1. TDP-43 is ubiquitously expressed and consists of 414 amino acids. Mutations in the TDP-43 gene can lead to amyotrophic lateral sclerosis (ALS), frontotemporal lobar degeneration (FTLD) or LATE dementia. In many ALS cases, post mortem brain tissue samples show TDP-43 positive cytoplasmic inclusions. TDP-43 is considered a molecular signature of ALS and FTLD. In the context of Alzheimer's disease (AD), TDP-43 pathology can impact the pattern of hypometabolism detected by [¹⁸F]FDG PET imaging and is a relevant driver of volume-uptake mismatch in old AD patients. The development of TDP-43 PET tracers and the understanding of TDP-43 pathology's impact on neuroimaging markers hold promise for enhancing the diagnostic evaluation and characterization of neurodegenerative dementias, including AD and related conditions.^{85,86}

Further physiopathological processes linked to neuroinflammation and neurodegeneration

A number of PET-Tracers have been developed to depict and quantify *neuroinflammation*, the majority of which targeting the translocator protein 18kDa (TSPO), shown to be overexpressed in activated microglia and astrocytes.⁸⁷ Main limitation of this family of PET-Tracers, despite some improvement on 3rd generation TSPO tracers, is the genetic variability of the TSPO gene, particularly the rs6971 polymorphism, which leads to different

binding affinities for TSPO ligands. This results in individuals being classified as high-affinity binders (HABs), low-affinity binders (LABs) or mixed-affinity binders (MABs). This heterogeneity can significantly impact the interpretation of PET imaging results, with findings in LABs being of disputable relevance, significantly impairing clinical study design, which might have to exclude individuals based on their genetic profile, makes quantitation less reliable without a prior genetic testing. [¹¹C] PK11195, the prototypical first-generation PET radioligand, is the best characterized TSPO ligand, but has severe limitations, including low sensitivity and poor amenability to quantification. The short half-life of 20.4 min of ¹¹C severely limits its accessibility outside of specialized centers equipped with a cyclotron and an experienced radiopharmacy. The substitution of ¹¹C with the more common, longer-lived ¹⁸F (half-life 109.7 min), significantly affects lipophilicity, stability, specific binding and metabolic degradation, affecting brain penetration, specific binding and reliability of quantitation.⁸⁸ A low radiochemical yield also limits the number of exams per production run of the radiotracer. The "ideal" TSPO-tracer has yet to be developed, and currently available tracers each have their specific limitations, which only partly can be overcome by prior genetic testing to improve interpretation of individual findings. This has, so far, limited their widespread use, but nevertheless TSPO-PET has proven to be of significant value in clinical trials designed around the tracer specifics. In Canada, TSPO-PET is currently available or in use for clinical trials at the Universities of Alberta, British Columbia, Montréal and Toronto.⁸⁹

Alternatives to TSPO tracers for imaging of neuroinflammation are PET tracers targeting:

- the purinergic P2X7 ionotropic receptor (P2X7R), which is expressed in astrocytes, microglia and oligodendrocytes, where they mediate inflammasome signaling⁹⁰
- the cyclooxygenase-enzyme-2 (COX-2),⁹¹⁻⁹³ which has been implicated in neuroinflammation preceding neurodegeneration,⁹⁴ and could provide a rationale for stage-dependent antioxidative treatment
- the C-X-C motif chemokine receptors (CXCR)-4 and (CXCR)-3, which critically contribute to the disease process in systemic inflammation,⁹⁵⁻⁹⁷ opening another door to possible future therapeutic principles targeting the respective C-X-C motif chemokine receptor⁹⁵
- the Glucose Transporter 5 (GLUT-5), which is exclusively expressed in microglial cells,⁹⁸ with 18-Fluoro-D-Fructose being the most extensively preclinically characterized compound.⁹⁹⁻¹⁰¹ Further to providing information on neuroinflammation, the involvement of dietary fructose and cerebral fructose metabolism GLUT-5 in patients with concurrent diabetes has attracted interest.¹⁰²

As a novel measure for neurodegeneration and neurorestoration, tyrosine kinase receptors as the binding targets of neurotrophins have attracted considerable interest regarding their diagnostic and therapeutic potential. Within this class of receptors, synthetic antibodies have recently been linked to PET-radioligands targeting the TrkB receptor, activated by brain derived neurotrophic factor (BDNF), which have passed the preclinical and clinical assessments.¹⁰³⁻¹⁰⁵ While this research still is in the experimental phase, the recent development of TrkB agonistic antibodies and BDNF-targeted gene therapies^{106,107} could prove useful as an alternative line of therapy to amyloid modifying treatments, and changes in

TrkB alterations as measured by PET/MRI during targeted therapy could potentially qualify as an imaging endpoint in clinical trials in AD. In Canada, TrkB PET using the novel tracer [¹⁸F]-TRACK is currently available or in use for clinical trials at the Universities of Alberta and Montréal.¹⁰⁸

Markers of pathology in plasma

A major development of the last years has been the advent of highly sensitive assays able to accurately measure pathological markers in plasma.¹⁰⁹ The availability of these assays, representing a simple blood test versus the more invasive CSF test requiring a spinal tap, opens new perspectives for large scale population-level screening with a noninvasive and affordable test. Preliminary data suggests feasibility of diagnostic algorithms based on the results of plasmatic markers as first-line test, followed by further diagnostic modalities including molecular imaging, following an “integral diagnostic,” or precision medicine approach.¹¹⁰ However, until more data is available, careful interpretation of these biomarkers is still required, as a recent study found that plasma-Tau abnormalities were rather associated with cerebral amyloid-beta deposition than with cerebral tau deposition measured by PET.¹¹¹

Disease-modifying drugs for neurodegenerative diseases

The research to develop pharmacological and non-pharmacological approaches to treat neurodegenerative conditions is actively testing a large panel of compounds and strategies to deal with these devastating conditions, namely targeting the most common condition, AD.¹¹²

Encouraging although strongly debated results have been obtained by two antibodies targeting amyloid which have shown biological changes, namely using amyloid PET as treatment biomarker.^{4,113,114} Given the high costs for these treatments, and potential severe side-effects,^{115,116} it seems straightforward to require a positive amyloid PET scan as proof of target engagement prior to therapy.

Molecular imaging markers are surrogate markers now consistently integrated in clinical trials, and clearly the advent of current and future disease-modifying drugs will profoundly change the role and the implications of diagnostic processes in AD and related disorders. PET imaging biomarkers have proven to provide a framework for PET-based Braak staging of AD to monitor AD severity in living humans,¹¹⁷ which will provide further rationale for a patient-adapted approach on therapeutic interventions, as a further example of precision medicine.

Conclusions

In conclusion, there is a clinical need for an accurate diagnosis of cognitive disorders using biologic criteria,¹¹⁸ both for the adaptation of the management of these patients and for the implementation and development of new treatments. PET represents already a mainstay of the etiological diagnostic process, as a key element to approach an anatomic-pathological diagnosis *in vivo*, and is susceptible to play an increasingly important role. [¹⁸F] FDG PET still is the worldwide most frequently used PET imaging agent in dementia, and is broadly available and in clinical use in Canada. Amyloid PET has been extensively investigated in clinical trials in Europe, Switzerland, Japan and the U.S., and is increasingly reimbursed for the use in dementia as amyloid-targeted treatment continues to expand. A lack of reimbursement

and limited availability limit the clinical use of amyloid PET in Canada, which consequently is rarely used clinically.

From the author's perspective, in the light of extraordinarily high costs of beta-amyloid altering therapy, and its potentially life-threatening side-effects, beta-amyloid altering therapy should not be administered without prior proof of target engagement, which ideally would include PET imaging and/or other biomarkers relevant to the case, including CSF examination or blood biomarkers. Should Canada secure reimbursement for amyloid PET, aligning with the practice in the U.S., both the industry and local radiopharmacies in PET-centers with cyclotron availability, stand ready to scale up production and distribution. Read-out of amyloid PET has been highly standardized, and diagnostic scales, such as the Centiloid Scale can be adapted with little local effort or industry support, similar to prior practice in various fields of PET imaging.

Regarding current and future developments including novel tracers for dementia and neurodegenerative disease, Canada has been engaging for more than a decade in research initiatives at the highest, international level, with a number of unique tracers being created and evaluated in Canadian university labs and clinics. However, the country's vast geography and uneven population distribution create significant challenges in making these advancements accessible to all Canadians in need. Overcoming this accessibility gap will require a collaborative effort that combines academic ingenuity, renowned logistical expertise and industry support. This approach has already demonstrated success with the introduction of [¹⁸F]FDG PET in oncologic imaging in Canada during the past decade.

Author contribution. Conception and manuscript writing: FJ, VG. Specific contributions: FW, RS, JA, JS, AT, RC. Correction, revising, final approval: FJ, FW, RS, JA, AT, JS, RC, VG. Revisions and proofreading: FJ.

Funding statement. None.

Competing interests. JA declares to have received a research grant from the Canadian Neuroendocrine Tumor Society. JS declares to have received payments for PET studies interpretation from Optina Diagnostics, as well as payment or honoraria from the Royal College of Physicians and Surgeons of Canada. RC is team lead of the CIHR – Canadian Consortium on Neurodegeneration of Aging, is site-PI/site investigator of the NIH SPARX3 clinical trial, CIHR Compass-ND, the Weston Foundation Synergic2 clinical trial and has received funding through a subcontract with the University of Calgary from CIHR/Brain Canada for functional assessment of vascular reactivity. RC also is unpaid scientific advisor for the Weston Foundation, Western University on Ambroxol for Parkinson's Disease Dementia, is unpaid member of the scientific board of the Parkinson Society of Canada, as well as an unpaid member of the Michael J Fox Gait Advisory Board. VC has received research funding to her institution from Siemens Healthineers and GE Healthcare, and has received speaker fees from GE Healthcare, Siemens Healthineers, Novo Nordisk and Janssen. All other authors declare that the review was conducted in the absence of any commercial or financial relationships that could be construed as a potential conflict of interest.

References

1. <https://www.alzint.org/about/dementia-facts-figures/dementia-statistics/>. Accessed February 02, 2024.
2. Prince M, Wimo A, Guerchet M, et al. World Alzheimer Report 2015 - The global impact of dementia: An analysis of prevalence, incidence, cost and trends. London, UK: Alzheimer's Disease International, 2015: 1–84.
3. Mintun MA, Lo AC, Duggan Evans C, et al. Donanemab in early Alzheimer's disease. *N Engl J Med*. 2021;6:1691–704. DOI: [10.1056/NEJMoa2100708](https://doi.org/10.1056/NEJMoa2100708).

4. Kuller LH, Lopez OL. ENGAGE and EMERGE: truth and consequences? *Alzheimer's Dement.* 2021;17:692–5. DOI: [10.1002/alz.12286](https://doi.org/10.1002/alz.12286).
5. van Dyck CH, Swanson CJ, Aisen P, et al. Lecanemab in early Alzheimer's disease. *New Engl J Med.* 2023;388:9–21. DOI: [10.1056/NEJMoa2212948](https://doi.org/10.1056/NEJMoa2212948).
6. Chetelat G, Arbizu J, Barthel H, et al. Amyloid-PET and (18)F-FDG-PET in the diagnostic investigation of Alzheimer's disease and other dementias. *Lancet Neurol.* 2020;19:951–62. DOI: [10.1016/S1474-4422\(20\)30314-8](https://doi.org/10.1016/S1474-4422(20)30314-8).
7. Dadar M, Mahmoud S, Zhernovaia M, et al. White matter hyperintensity distribution differences in aging and neurodegenerative disease cohorts. *Neuroimage Clin.* 2022;36:103204. DOI: [10.1016/j.nicl.2022.103204](https://doi.org/10.1016/j.nicl.2022.103204).
8. Hanstock C, Sun K, Choi C, et al. Spectroscopic markers of neurodegeneration in the mesial prefrontal cortex predict survival in ALS. *Amyotroph Lateral Scler Frontotemporal Degener.* 2020;21:246–51. DOI: [10.1080/21678421.2020.1727926](https://doi.org/10.1080/21678421.2020.1727926).
9. Frisoni GB, Boccardi M, Barkhof F, et al. Strategic roadmap for an early diagnosis of Alzheimer's disease based on biomarkers. *Lancet Neurol.* 2017;16:661–76. DOI: [10.1016/S1474-4422\(17\)30159-X](https://doi.org/10.1016/S1474-4422(17)30159-X).
10. Villemagne VL, Barkhof F, Garibotto V, Landau SM, Nordberg A, van Berckel BNM. Molecular imaging approaches in dementia. *Radiology.* 2021;298:517–30. DOI: [10.1148/radiol.2020200028](https://doi.org/10.1148/radiol.2020200028).
11. Nobili F, Arbizu J, Bouwman F, et al. European association of nuclear medicine and European academy of neurology recommendations for the use of brain (18) F-fluorodeoxyglucose positron emission tomography in neurodegenerative cognitive impairment and dementia: Delphi consensus. *Eur J Neurol.* 2018;25:1201–17. DOI: [10.1111/ene.13728](https://doi.org/10.1111/ene.13728).
12. Garibotto V, Herholz K, Boccardi M, et al. Clinical validity of brain fluorodeoxyglucose positron emission tomography as a biomarker for Alzheimer's disease in the context of a structured 5-phase development framework. *Neurobiol Aging.* 2017;52:183–95. DOI: [10.1016/j.neurobiolaging.2016.03.033](https://doi.org/10.1016/j.neurobiolaging.2016.03.033).
13. Zahn R, Buechert M, Overmans J, et al. Mapping of temporal and parietal cortex in progressive nonfluent aphasia and Alzheimer's disease using chemical shift imaging, voxel-based morphometry and positron emission tomography. *Psychiatr Res Neuroimaging.* 2005;30:115–31. DOI: [10.1016/j.psychres.2005.08.001](https://doi.org/10.1016/j.psychres.2005.08.001).
14. Lim SM, Katsifis A, Villemagne VL, et al. The ¹⁸F-FDG PET cingulate island sign and comparison to ¹²³I-beta-CIT SPECT for diagnosis of dementia with Lewy bodies. *J Nuclear Med.* 2009;50:1638–45. DOI: [10.2967/jnumed.109.065870](https://doi.org/10.2967/jnumed.109.065870).
15. Miyagawa T, Przybelski SA, Maltais D, et al. The value of multimodal imaging with (123)I-FP-CIT SPECT in differential diagnosis of dementia with Lewy bodies and Alzheimer's disease dementia. *Neurobiol Aging.* 2021;99:11–8. DOI: [10.1016/j.neurobiolaging.2020.12.009](https://doi.org/10.1016/j.neurobiolaging.2020.12.009).
16. O'Brien JT, McKeith IG, Walker Z, et al. Diagnostic accuracy of ¹²³I-FP-CIT SPECT in possible dementia with Lewy bodies. *Br J Psychiatry.* 2009;194:34–9. DOI: [10.1192/bjp.bp.108.052050](https://doi.org/10.1192/bjp.bp.108.052050).
17. Hu XS, Okamura N, Arai H, et al. ¹⁸F-fluorodopa PET study of striatal dopamine uptake in the diagnosis of dementia with Lewy bodies. *Neurology.* 2000;55:1575–7. DOI: [10.1212/WNL.55.10.1575](https://doi.org/10.1212/WNL.55.10.1575).
18. Magalhaes P, Lashuel HA. Opportunities and challenges of alpha-synuclein as a potential biomarker for Parkinson's disease and other synucleinopathies. *NPJ Parkinsons Dis.* 2022;8:93. DOI: [10.1038/s41531-022-00357-0](https://doi.org/10.1038/s41531-022-00357-0).
19. Ganguly U, Singh S, Pal S, et al. Alpha-synuclein as a biomarker of parkinson's disease: good, but not good enough. *Front Aging Neurosci.* 2021;13:702639. DOI: [10.3389/fnagi.2021.702639](https://doi.org/10.3389/fnagi.2021.702639).
20. Shi M, Tang L, Toledo JB, et al. Cerebrospinal fluid alpha-synuclein contributes to the differential diagnosis of Alzheimer's disease. *Alzheimers Dement.* 2018;14:1052–62. DOI: [10.1016/j.jalz.2018.02.015](https://doi.org/10.1016/j.jalz.2018.02.015).
21. McKhann GM, Knopman DS, Chertkow H, et al. The diagnosis of dementia due to Alzheimer's disease: recommendations from the national institute on aging-Alzheimer's association workgroups on diagnostic guidelines for Alzheimer's disease. *Alzheimers Dement.* 2011;7:263–9. DOI: [10.1016/j.jalz.2011.03.005](https://doi.org/10.1016/j.jalz.2011.03.005).
22. Albert MS, DeKosky ST, Dickson D, et al. The diagnosis of mild cognitive impairment due to Alzheimer's disease: recommendations from the national institute on aging-Alzheimer's association workgroups on diagnostic guidelines for Alzheimer's disease. *Alzheimers Dement.* 2011;7:270–9. DOI: [10.1016/j.jalz.2011.03.008](https://doi.org/10.1016/j.jalz.2011.03.008).
23. Rascovsky K, Hodges JR, Knopman D, et al. Sensitivity of revised diagnostic criteria for the behavioural variant of frontotemporal dementia. *Brain.* 2011;134:2456–77. DOI: [10.1093/brain/awr179](https://doi.org/10.1093/brain/awr179).
24. Armstrong MJ, Litvan I, Lang AE, et al. Criteria for the diagnosis of corticobasal degeneration. *Neurology.* 2013;80:496–503. DOI: [10.1212/WNL.0b013e31827f0fd1](https://doi.org/10.1212/WNL.0b013e31827f0fd1).
25. Hoglinger GU, Respondek G, Stamelou M, et al. Clinical diagnosis of progressive supranuclear palsy: the movement disorder society criteria. *Mov Disord.* 2017;32:853–64. DOI: [10.1002/mds.26987](https://doi.org/10.1002/mds.26987).
26. Gilman S, Wenning GK, Low PA, et al. Second consensus statement on the diagnosis of multiple system atrophy. *Neurology.* 2008;71:670–6. DOI: [10.1212/01.wnl.0000324625.00404.15](https://doi.org/10.1212/01.wnl.0000324625.00404.15).
27. Morbelli S, Garibotto V, Van De Giessen E, et al. A cochrane review on brain [(1)(8)F]FDG PET in dementia: limitations and future perspectives. *Eur J Nucl Med Mol Imag.* 2015;42:1487–91. DOI: [10.1007/s00259-015-3098-2](https://doi.org/10.1007/s00259-015-3098-2).
28. Garibotto V, Trombetta S, Antelmi L, et al. A comparison of two statistical mapping tools for automated brain FDG-PET analysis in predicting conversion to Alzheimer's disease in subjects with mild cognitive impairment. *Curr Alzheimer Res.* 2020;17:1186–94. DOI: [10.2174/1567205018666210212162443](https://doi.org/10.2174/1567205018666210212162443).
29. Morbelli S, Chincarini A, Brendel M, et al. Metabolic patterns across core features in dementia with lewy bodies. *Ann Neurol.* 2019;85:715–25. DOI: [10.1002/ana.25453](https://doi.org/10.1002/ana.25453).
30. Zahn R, Garrard P, Talazko J, et al. Patterns of regional brain hypometabolism associated with knowledge of semantic features and categories in Alzheimer's disease. *J Cognit Neurosci.* 2006;18:2138–51. DOI: [10.1162/jocn.2006.18.12.2138](https://doi.org/10.1162/jocn.2006.18.12.2138).
31. Zahn R, Juengling F, Bubrowski P, et al. Hemispheric asymmetries of hypometabolism associated with semantic memory impairment in Alzheimer's disease: a study using positron emission tomography with fluorodeoxyglucose-F18. *Psychiatr Res Neuroimaging.* 2004;15:159–72. DOI: [10.1016/j.psychres.2004.07.006](https://doi.org/10.1016/j.psychres.2004.07.006).
32. Bauckneht M, Chincarini A, Brendel M, et al. Associations among education, age, and the dementia with Lewy bodies (DLB) metabolic pattern: a European-DLB consortium project. *Alzheimers Dement.* 2021;17:1277–86. DOI: [10.1002/alz.12294](https://doi.org/10.1002/alz.12294).
33. Bahri MA, Plenevaux A, Aerts J, et al. Measuring brain synaptic vesicle protein 2A with positron emission tomography and [¹⁸F]UCB-H. *Alzheimers Dement (N Y).* 2017;3:481–6. DOI: [10.1016/j.trci.2017.08.004](https://doi.org/10.1016/j.trci.2017.08.004).
34. Bretin F, Bahri MA, Bernard C, et al. Biodistribution and radiation dosimetry for the novel SV2A radiotracer [(18)F]UCB-H: first-in-human study. *Mol Imaging Biol.* 2015;17:557–64. DOI: [10.1007/s11307-014-0820-6](https://doi.org/10.1007/s11307-014-0820-6).
35. Li S, Cai Z, Wu X, et al. Synthesis and in vivo evaluation of a novel PET radiotracer for imaging of synaptic vesicle glycoprotein 2A (SV2A) in nonhuman primates. *ACS Chem Neurosci.* 2019;10:1544–54. DOI: [10.1021/acschemneuro.8b00526](https://doi.org/10.1021/acschemneuro.8b00526).
36. Cai Z, Li S, Zhang W, et al. Synthesis and preclinical evaluation of an ¹⁸F-labeled synaptic vesicle glycoprotein 2A PET imaging probe: [¹⁸F]SynVesT-2. *ACS Chem Neurosci.* 2020;11:592–603. DOI: [10.1021/acschemneuro.9b00618](https://doi.org/10.1021/acschemneuro.9b00618).
37. Finnema SJ, Nabulsi NB, Eid T, et al. Imaging synaptic density in the living human brain. *Sci Transl Med.* 2016;8:348ra96–348ra96. DOI: [10.1126/scitranslmed.aaf6667](https://doi.org/10.1126/scitranslmed.aaf6667).
38. Bastin C, Bahri MA, Meyer F, et al. In vivo imaging of synaptic loss in Alzheimer's disease with [¹⁸F]UCB-H positron emission tomography. *Eur J Nuclear Med Molec Imag.* 2020;47:390–402. DOI: [10.1007/s00259-019-04461-x](https://doi.org/10.1007/s00259-019-04461-x).
39. Silva-Rudberg JA, Salardini E, O'Dell RS, et al. Assessment of gray matter microstructure and synaptic density in Alzheimer's disease: a multimodal imaging study with DTI and SV2A PET. *Am J Geriatr Psychiatry.* 2024;32:17–28. DOI: [10.1016/j.jagp.2023.08.002](https://doi.org/10.1016/j.jagp.2023.08.002).
40. Maldjian JA, Whitlow CT. Alzheimer's disease neuroimaging I. Whither the hippocampus? FDG-PET hippocampal hypometabolism in Alzheimer

- disease revisited. *AJNR Am J Neuroradiol.* 2012;33:1975–82. DOI: [10.3174/ajnr.A3113](https://doi.org/10.3174/ajnr.A3113).
41. Chen MK, Mecca AP, Naganawa M, et al. Assessing synaptic density in Alzheimer disease with synaptic vesicle glycoprotein 2A positron emission tomographic imaging. *JAMA Neurol.* 2018;75:1215–24. DOI: [10.1001/jamaneurol.2018.1836](https://doi.org/10.1001/jamaneurol.2018.1836).
 42. Braak H, Alafuzoff I, Arzberger T, Kretzschmar H, Del Tredici K. Staging of Alzheimer disease-associated neurofibrillary pathology using paraffin sections and immunocytochemistry. *Acta Neuropathol.* 2006;112:389–404. DOI: [10.1007/s00401-006-0127-z](https://doi.org/10.1007/s00401-006-0127-z).
 43. Andersen KB, Hansen AK, Damholdt MF, et al. Reduced synaptic density in patients with Lewy body dementia: an [(11)C]UCB-J PET imaging study. *Mov Disord.* 2021;36:2057–65. DOI: [10.1002/mds.28617](https://doi.org/10.1002/mds.28617).
 44. Nicastro N, Holland N, Savulich G, et al. 11C-UCB-J synaptic PET and multimodal imaging in dementia with Lewy bodies. *Eur J Hybrid Imaging.* 2020;4:25. DOI: [10.1186/s41824-020-00093-9](https://doi.org/10.1186/s41824-020-00093-9).
 45. Search: Clinical Trials using SV2A-PET in Canada. <https://clinicaltrials.gov/search?locStr=Canada&country=Canada&term=SV2A>. Accessed February 2, 2024.
 46. Jack CR Jr., Bennett DA, Blennow K, et al. NIA-AA research framework: toward a biological definition of Alzheimer's disease. *Alzheimers Dement.* 2018;14:535–62. DOI: [10.1016/j.jalz.2018.02.018](https://doi.org/10.1016/j.jalz.2018.02.018).
 47. Klunk WE, Engler H, Nordberg A, et al. Imaging brain amyloid in Alzheimer's disease with Pittsburgh compound-B. *Ann Neurol.* 2004;55:306–19. DOI: [10.1002/ana.20009](https://doi.org/10.1002/ana.20009).
 48. Chiotis K, Saint-Aubert L, Boccardi M, et al. Clinical validity of increased cortical uptake of amyloid ligands on PET as a biomarker for Alzheimer's disease in the context of a structured 5-phase development framework. *Neurobiol Aging.* 2017;52:214–227.
 49. Klunk WE, Koeppe RA, Price JC, et al. The centiloid project: standardizing quantitative amyloid plaque estimation by PET. *Alzheimers Dement.* 2015;11:1–15. DOI: [10.1016/j.jalz.2014.07.003](https://doi.org/10.1016/j.jalz.2014.07.003).
 50. Cho SH, Choe YS, Kim HJ, et al. A new centiloid method for (18)F-florbetaben and (18)F-flutemetamol PET without conversion to PiB. *Eur J Nucl Med Mol Imaging.* 2020;47:1938–48. DOI: [10.1007/s00259-019-04596-x](https://doi.org/10.1007/s00259-019-04596-x).
 51. Doré V, Bullich S, Rowe CC, et al. Comparison of ¹⁸F-florbetaben quantification results using the standard centiloid, MR-based, and MR-less CapAIBL® approaches: validation against histopathology. *Alzheimer's Dement.* 2019;15:807–16. DOI: [10.1016/j.jalz.2019.02.005](https://doi.org/10.1016/j.jalz.2019.02.005).
 52. Rowe CC, Jones G, Doré V, et al. Standardized expression of ¹⁸F-NAV4694 and ¹¹C-PiB β-amyloid PET results with the centiloid scale. *J Nuclear Med.* 2016;1:1233–7. DOI: [10.2967/jnumed.115.171595](https://doi.org/10.2967/jnumed.115.171595).
 53. Collij LE, Salvado G, Shekari M, et al. Visual assessment of [¹⁸F]flutemetamol PET images can detect early amyloid pathology and grade its extent. *Eur J Nucl Med Mol Imaging.* 2021;48:2169–82. DOI: [10.1007/s00259-020-05174-2](https://doi.org/10.1007/s00259-020-05174-2).
 54. Daerr S, Brendel M, Zach C, et al. Evaluation of early-phase [¹⁸F]-florbetaben PET acquisition in clinical routine cases. *Neuroimage Clin.* 2017;14:77–86. DOI: [10.1016/j.nicl.2016.10.005.S2213-1582\(16\)30186-3](https://doi.org/10.1016/j.nicl.2016.10.005.S2213-1582(16)30186-3).
 55. Boccalini C, Peretti DE, Ribaldi F, et al. Early-phase ¹⁸F-florbetapir and ¹⁸F-flutemetamol images as proxies of brain metabolism in a memory clinic setting. *J Nucl Med.* 2022;64:266–73. DOI: [10.2967/jnumed.122.264256](https://doi.org/10.2967/jnumed.122.264256).
 56. FDA. Drugs@FDA: FDA-Approved Drugs: Leqembi - Lecanemab-IRMB. January 6, 2023. <https://www.accessdata.fda.gov/scripts/cder/daf/index.cfm?event=overview.process&AppNo=761269>. Accessed June 4, 2023.
 57. FDA. Drugs@FDA: FDA-Approved Drugs, Aduhelm - Aducanumab-AVWA. June 07, 2021. <https://www.accessdata.fda.gov/scripts/cder/daf/index.cfm?event=overview.process&varAppNo=761178>. Accessed June 04, 2023.
 58. Juengling FD, Allenbach G, Bruehlmeier M, et al. Appropriate use criteria for dementia amyloid imaging in Switzerland - mini-review and statement on behalf of the Swiss Society of Nuclear Medicine and the Swiss Memory Clinics. *Nuklearmedizin.* 2021;60:7–9. DOI: [10.1055/a-1277-6014](https://doi.org/10.1055/a-1277-6014).
 59. Garnier-Crussard A, Flaus A. Positive opinion of the French national authority for health on the reimbursement of amyloid tracer (flutemetamol). *Eur J Nucl Med Mol Imag.* 2023;50:253–4. DOI: [10.1007/s00259-022-06025-y](https://doi.org/10.1007/s00259-022-06025-y).
 60. CAG-00431R Decision Memo. <https://www.cms.gov/medicare-coverage-database/view/ncacal-decision-memo.aspx?proposed=N&NCAId=308>. Accessed October 13, 2023.
 61. First Reimbursed Amyloid PET Diagnostic Tool in Japan. <https://life-mi.com/cmi-inc-and-life-molecular-imaging-announce-the-reimbursement-of-the-amyloid-pet-diagnostic-neuraqeq-florbetaben-18f-in-japan/>. Accessed November 22, 2023.
 62. Teipel SJ, Spottke A, Boecker H, et al. Patient-related benefits of amyloid PET imaging in dementia: rationale and design of the German randomized coverage with evidence development study ENABLE. *Alzheimers Dement (N Y).* 2023;9:e12383. DOI: [10.1002/trc2.12383](https://doi.org/10.1002/trc2.12383).
 63. Rabinovici GD, Gatzonis C, Apgar C, et al. Association of amyloid positron emission tomography with subsequent change in clinical management among Medicare beneficiaries with mild cognitive impairment or dementia. *JAMA.* 2019;321:286–94. DOI: [10.1001/jama.2019.2000](https://doi.org/10.1001/jama.2019.2000).
 64. Frisoni GB, Barkhof F, Altomare D, et al. AMYPAD diagnostic and patient management study: rationale and design. *Alzheimers Dement.* 2019;15:388–99. DOI: [10.1016/j.jalz.2018.09.003](https://doi.org/10.1016/j.jalz.2018.09.003).
 65. Pascoal TA, Benedet AL, Tudorasu DL, et al. Longitudinal 18F-MK-6240 tau tangles accumulation follows Braak stages. *Brain.* 2021;144:3517–28. DOI: [10.1093/brain/awab248](https://doi.org/10.1093/brain/awab248).
 66. Wolters EE, Dodich A, Boccardi M, et al. Clinical validity of increased cortical uptake of [(18)F]flortaucipir on PET as a biomarker for Alzheimer's disease in the context of a structured 5-phase biomarker development framework. *Eur J Nucl Med Mol Imaging.* 2021;48:2097–109. DOI: [10.1007/s00259-020-05118-w](https://doi.org/10.1007/s00259-020-05118-w).
 67. Fleisher AS, Pontecorvo MJ, Devous MD Sr., et al. Positron emission tomography imaging with [¹⁸F]flortaucipir and postmortem assessment of Alzheimer disease neuropathologic changes. *JAMA Neurol.* 2020;77:829–39. DOI: [10.1001/jamaneurol.2020.0528](https://doi.org/10.1001/jamaneurol.2020.0528).
 68. Boccalini C, Ribaldi F, Hristovska I, et al. The impact of tau deposition and hypometabolism on cognitive impairment and longitudinal cognitive decline. *Alzheimers Dement.* 2024;20:221–33. DOI: [10.1002/alz.13355](https://doi.org/10.1002/alz.13355).
 69. Lemoine L, Leuzy A, Chiotis K, Rodriguez-Vieitez E, Nordberg A. Tau positron emission tomography imaging in tauopathies: the added hurdle of off-target binding. *Alzheimers Dement (Amst).* 2018;10:232–6. DOI: [10.1016/j.dadm.2018.01.007](https://doi.org/10.1016/j.dadm.2018.01.007).
 70. Ricci M, Cimini A, Camedda R, Chiaravallotti A, Schillaci O. Tau biomarkers in dementia: positron emission tomography radiopharmaceuticals in tauopathy assessment and future perspective. *Int J Mol Sci.* 2021;22:10.3390/ijms222313002.
 71. <https://clinicaltrials.gov/search?locStr=Canada&country=Canada&term=Tau%20PET>. Accessed February 2, 2024.
 72. Altomare D, Caprioglio C, Assal F, et al. Diagnostic value of amyloid-PET and tau-PET: a head-to-head comparison. *Eur J Nucl Med Mol Imaging.* 2021;48:2200–11. DOI: [10.1007/s00259-021-05246-x](https://doi.org/10.1007/s00259-021-05246-x).
 73. Ramusino MC, Garibotto V, Bacchin R, et al. Incremental value of amyloid-PET versus CSF in the diagnosis of Alzheimer's disease. *Eur J Nucl Med Mol Imag.* 2020;47:270–80. DOI: [10.1007/s00259-019-04466-6](https://doi.org/10.1007/s00259-019-04466-6).
 74. Massa F, Farotti L, Eusebi P, et al. Reciprocal incremental value of 18F-FDG-PET and cerebrospinal fluid biomarkers in mild cognitive impairment patients suspected for Alzheimer's disease and inconclusive first biomarker. *J Alzheimers Dis.* 2019;72:1193–207. DOI: [10.3233/JAD-190539](https://doi.org/10.3233/JAD-190539).
 75. Perini G, Rodriguez-Vieitez E, Kadir A, Sala A, Savitcheva I, Nordberg A. Clinical impact of ¹⁸F-FDG-PET among memory clinic patients with uncertain diagnosis. *Eur J Nucl Med Mol Imaging.* 2021;48:612–22. DOI: [10.1007/s00259-020-04969-7](https://doi.org/10.1007/s00259-020-04969-7).
 76. Boccardi M, Nicolosi V, Festari C, et al. Italian consensus recommendations for a biomarker-based aetiological diagnosis in mild cognitive impairment patients. *Eur J Neurol.* 2020;27:475–83. DOI: [10.1111/ene.14117](https://doi.org/10.1111/ene.14117).
 77. Montero-Odasso M, Pieruccini-Faria F, Ismail Z, et al. CCCDTD5 recommendations on early non cognitive markers of dementia: a

- Canadian consensus. *Alzheimers Dement* (N Y). 2020;6:e12068. DOI: [10.1002/trc2.12068](https://doi.org/10.1002/trc2.12068).
78. Ismail Z, Black SE, Camicioli R, et al. Recommendations of the 5th Canadian consensus conference on the diagnosis and treatment of dementia. *Alzheimers Dement*. 2020;16:1182–95. DOI: [10.1002/alz.12105](https://doi.org/10.1002/alz.12105).
 79. Brisson M, Brodeur C, Letourneau-Guillon L, et al. CCCDTD5: clinical role of neuroimaging and liquid biomarkers in patients with cognitive impairment. *Alzheimers Dement* (N Y). 2020;6:e12098. DOI: [10.1002/trc2.12098](https://doi.org/10.1002/trc2.12098).
 80. Laforce R, Rosa-Neto P, Soucy JP, Rabinovici GD, Dubois B, Gauthier S. Canadian consensus guidelines on use of amyloid imaging in Canada: update and future directions from the specialized task force on amyloid imaging in Canada. *Can J Neurol Sci*. 2016;43:503–12. DOI: [10.1017/cjn.2015.401](https://doi.org/10.1017/cjn.2015.401).
 81. Morbelli S, Esposito G, Arbizu J, et al. EANM practice guideline/SNMMI procedure standard for dopaminergic imaging in Parkinsonian syndromes 1.0. *Eur J Nucl Med Mol Imag*. 2020;47:1885–912. DOI: [10.1007/s00259-020-04817-8](https://doi.org/10.1007/s00259-020-04817-8).
 82. Mattison C, Gauvin F, Wilson M. Rapid synthesis: Examining the public provision and funding of PET-CT imaging for non-cancer indications. McMaster Health Forum, Hamilton, Canada. 2018: 1–20. <https://www.mcmasterforum.org/docs/default-source/product-documents/rapid-responses/examining-the-public-provision-and-funding-of-pet-ct-imaging-for-non-cancer-indications.pdf?sfvrsn=2>. Accessed February 2, 2024.
 83. Boccardi M, Nicolosi V, Festari C, et al. Italian consensus recommendations for a biomarker-based aetiological diagnosis in mild cognitive impairment patients. *Eur J Neurol*. 2020;27:475–83. DOI: [10.1111/ene.14117](https://doi.org/10.1111/ene.14117).
 84. Burge M, Bieri G, Bruhlmeier M, et al. Recommendations of Swiss memory clinics for the diagnosis of dementia. *Praxis* (Bern 1994). 2018;107:435–451.
 85. Chételat G, Desgranges B, De La Sayette V, Viader F, Eustache F, Baron J-C. Mapping gray matter loss with voxel-based morphometry in mild cognitive impairment. *Neuroreport*. 2002;13:1939–43. DOI: [10.1097/00001756-200210280-00022](https://doi.org/10.1097/00001756-200210280-00022).
 86. Korat S, Bidesi NSR, Bonanno F, et al. Alpha-synuclein PET tracer development—an overview about current efforts. *Pharmaceuticals* (Basel). 2021;14:10.3390/ph14090847.
 87. Smith R, Capotosti F, Schain M, et al. Initial clinical scans using [18-F]-ACI-12589, a novel α -synuclein PET-tracer. *Alzheimer's Dement*. 2022;18:e065394. DOI: [10.1002/alz.065394](https://doi.org/10.1002/alz.065394).
 88. Smith R, Capotosti F, Schain M, et al. The alpha-synuclein PET tracer [¹⁸F] ACI-12589 distinguishes multiple system atrophy from other neurodegenerative diseases. *Nat Commun*. 2023;14:6750. DOI: [10.1038/s41467-023-42305-3](https://doi.org/10.1038/s41467-023-42305-3).
 89. Steinacker P, Barschke P, Otto M. Biomarkers for diseases with TDP-43 pathology. *Mol Cell Neurosci*. 2019;97:43–59. DOI: [10.1016/j.mcn.2018.10.003](https://doi.org/10.1016/j.mcn.2018.10.003).
 90. Knight AC, Morrone CD, Varlow C, Yu WH, McQuade P, Vasdev N. Head-to-head comparison of tau-PET radioligands for imaging TDP-43 in post-mortem ALS brain. *Mol Imaging Biol*. 2023;25:513–27. DOI: [10.1007/s11307-022-01779-1](https://doi.org/10.1007/s11307-022-01779-1).
 91. Corica F, De Feo MS, Gorica J, et al. PET imaging of neuro-inflammation with tracers targeting the translocator protein (TSPO), a systematic review: from bench to bedside. *Diagnostics* (Basel). 2023;13:10.3390/diagnostics13061029.
 92. Viviano M, Barresi E, Simeon FG, et al. Essential principles and recent progress in the development of TSPO PET ligands for neuro-inflammation imaging. *Curr Med Chem*. 2022;6:4862–90. DOI: [10.2174/0929867329666220329204054](https://doi.org/10.2174/0929867329666220329204054).
 93. Search term: TSPO PET in Canada. <https://clinicaltrials.gov/search?term=TSPO&locStr=Canada&country=Canada>. Accessed February 2, 2024.
 94. Franceschini A, Capece M, Chiozzi P, et al. The P2X7 receptor directly interacts with the NLRP3 inflammasome scaffold protein. *FASEB J*. 2015;29:2450–61. DOI: [10.1096/fj.14-268714](https://doi.org/10.1096/fj.14-268714).
 95. Bhardwaj A, Kaur J, Wuest M, Wuest F. In situ click chemistry generation of cyclooxygenase-2 inhibitors. *Nat Commun*. 2017;8:1–1. DOI: [10.1038/s41467-016-0009-6](https://doi.org/10.1038/s41467-016-0009-6).
 96. Litchfield M, Wuest M, Glubrecht D, Wuest F. Radiosynthesis and biological evaluation of [(18)F]Triacoxib: a new radiotracer for PET imaging of COX-2. *Mol Pharm*. 2020;17:251–61. DOI: [10.1021/acs.molpharmaceut.9b00986](https://doi.org/10.1021/acs.molpharmaceut.9b00986).
 97. Juengling FD, Wuest F, Kalra S, et al. Simultaneous PET/MRI: The future gold standard for characterizing motor neuron disease—A clinico-radiological and neuroscientific perspective. *Front Neurol*. 2022;13:890425. DOI: [10.3389/fneur.2022.890425](https://doi.org/10.3389/fneur.2022.890425).
 98. Yiangou Y, Facer P, Durrenberger P, et al. COX-2, CB2 and P2X7-immunoreactivities are increased in activated microglial cells/macrophages of multiple sclerosis and amyotrophic lateral sclerosis spinal cord. *BMC Neurol*. 2006;6:12–12. DOI: [10.1186/1471-2377-6-12](https://doi.org/10.1186/1471-2377-6-12).
 99. Kircher M, Herhaus P, Schottelius M, et al. CXCR4-directed theranostics in oncology and inflammation. *Ann Nuclear Med*. 2018;32:503–11. DOI: [10.1007/s12149-018-1290-8](https://doi.org/10.1007/s12149-018-1290-8).
 100. Mo XM, Sun HX. The anti-inflammatory effect of the CXCR4 antagonist-N15P peptide and its modulation on inflammation-associated mediators in LPS-induced PBMC. *Inflammation*. 2015;38:1374–83. DOI: [10.1007/s10753-015-0109-1](https://doi.org/10.1007/s10753-015-0109-1).
 101. Chu T, Shields LBE, Zhang YP, Feng S-Q, Shields CB, Cai J. CXCL12/CXCR4/CXCR7 chemokine axis in the central nervous system: therapeutic targets for remyelination in demyelinating diseases. *Neuroscientist*. 2017;23:627–48. DOI: [10.1177/1073858416685690](https://doi.org/10.1177/1073858416685690).
 102. Payne J, Maher F, Simpson I, Mattice L, Davies P. Glucose transporter glut 5 expression in microglial cells. *Glia*. 1997;21:327–31. DOI: [10.1002/\(sici\)1098-1136\(199711\)21:3<327::aid-glia7>3.0.co;2-1](https://doi.org/10.1002/(sici)1098-1136(199711)21:3<327::aid-glia7>3.0.co;2-1).
 103. Boyle AJ, Murrell E, Tong J, et al. PET imaging of fructose metabolism in a rodent model of neuroinflammation with 6-[(18)F]fluoro-6-deoxy-D-fructose. *Molecules*. 2022;27:10.3390/molecules27238529.
 104. Bouvet V, Jans HS, Wuest M, et al. Automated synthesis and dosimetry of 6-deoxy-6-[(18)F]fluoro-D-fructose (6-[(18)F]FDF): a radiotracer for imaging of GLUT5 in breast cancer. *Am J Nucl Med Mol Imag*. 2014;4:248–59.
 105. Wuest M, Trayner BJ, Grant TN, et al. Radiopharmacological evaluation of 6-deoxy-6-[(18)F]fluoro-D-fructose as a radiotracer for PET imaging of GLUT5 in breast cancer. *Nucl Med Biol*. 2011;38:461–75. DOI: [10.1016/j.nucmedbio.2010.11.004](https://doi.org/10.1016/j.nucmedbio.2010.11.004).
 106. Johnson RJ, Gomez-Pinilla F, Nagel M, et al. Cerebral fructose metabolism as a potential mechanism driving Alzheimer's disease. *Front Aging Neurosci*. 2020;12:560865. DOI: [10.3389/fnagi.2020.560865](https://doi.org/10.3389/fnagi.2020.560865).
 107. Bailey JJ, Kaiser L, Lindner S, et al. First-in-human brain imaging of [¹⁸F] TRACK, a PET tracer for tropomyosin receptor kinases. *ACS Chem Neurosci*. 2019;10:2697–702. DOI: [10.1021/acscchemneuro.9b00144](https://doi.org/10.1021/acscchemneuro.9b00144).
 108. Bernard-Gauthier V, Mossine AV, Mahringer A, et al. Identification of [¹⁸F]TRACK, a fluorine-18-labeled tropomyosin receptor kinase (Trk) inhibitor for PET imaging. *J Med Chem*. 2018;22:1737–43. DOI: [10.1021/acscimedchem.7b01607](https://doi.org/10.1021/acscimedchem.7b01607).
 109. Wuest M, Bailey JJ, Dufour J, et al. Toward in vivo proof of binding of [¹⁸F]-labeled inhibitor [(18)F]TRACK to peripheral tropomyosin receptor kinases. *EJNMMI Res*. 2022;12:46. DOI: [10.1186/s13550-022-00915-w](https://doi.org/10.1186/s13550-022-00915-w).
 110. Tuszynski MH, Yang JH, Barba D, et al. Nerve growth factor gene therapy: activation of neuronal responses in alzheimer disease. *JAMA Neurol*. 2015;72:1139–47. DOI: [10.1001/jama.2015.1807](https://doi.org/10.1001/jama.2015.1807).
 111. Osborne A, Wang AXZ, Tassoni A, Widdowson PS, Martin KR. Design of a novel gene therapy construct to achieve sustained brain-derived neurotrophic factor signaling in neurons. *Hum Gene Ther*. 2018;29:828–41. DOI: [10.1089/hum.2017.069](https://doi.org/10.1089/hum.2017.069).
 112. Search term: 18F-TRACK PET in Canada. <https://clinicaltrials.gov/search?term=18F-TRACK&locStr=Canada&country=Canada>. Accessed February 2, 2024.
 113. Simren J, Leuzy A, Karikari TK, et al. The diagnostic and prognostic capabilities of plasma biomarkers in Alzheimer's disease. *Alzheimers Dement*. 2021;17:1145–56. DOI: [10.1002/alz.12283](https://doi.org/10.1002/alz.12283).
 114. Garibotto V, Boccardi M, Chiti A, Frisoni GB. Molecular imaging and fluid biomarkers of Alzheimer's disease neuropathology: an opportunity for integrated diagnostics. *Eur J Nucl Med Mol Imag* 2021;48:2067–9. DOI: [10.1007/s00259-020-05116-y](https://doi.org/10.1007/s00259-020-05116-y).

115. Therriault J, Vermeiren M, Servaes S, et al. Association of phosphorylated tau biomarkers with amyloid positron emission tomography vs tau positron emission tomography. *JAMA Neurol.* 2023;1:188–99. DOI: [10.1001/jamaneurol.2022.4485](https://doi.org/10.1001/jamaneurol.2022.4485).
116. Cummings J, Lee G, Ritter A, Sabbagh M, Zhong K. Alzheimer's disease drug development pipeline: 2020. *Alzheimers Dement (N Y).* 2020;6:e12050. DOI: [10.1002/trc2.12050](https://doi.org/10.1002/trc2.12050).
117. Mintun MA, Lo AC, Duggan Evans C, et al. Donanemab in early Alzheimer's disease. *N Engl J Med.* 2021;384:1691–1704. DOI: [10.1056/NEJMoa2100708](https://doi.org/10.1056/NEJMoa2100708).
118. Knopman DS. Lecanemab reduces brain amyloid-beta and delays cognitive worsening. *Cell Rep Med.* 2023;4:100982. DOI: [10.1016/j.xcrm.2023.100982](https://doi.org/10.1016/j.xcrm.2023.100982).
119. Hampel H, Elhage A, Cho M, Apostolova LG, Nicoll JAR, Atri A. Amyloid-related imaging abnormalities (ARIA): radiological, biological and clinical characteristics. *Brain.* 2023;146:4414–24. DOI: [10.1093/brain/awad188](https://doi.org/10.1093/brain/awad188).
120. Roytman M, Mashriqi F, Al-Tawil K, et al. Amyloid-related imaging Abnormalities: an update. *AJR Am J Roentgenol.* 2023;220:562–74. DOI: [10.2214/AJR.22.28461](https://doi.org/10.2214/AJR.22.28461).
121. Therriault J, Pascoal TA, Lussier FZ, et al. Biomarker modeling of Alzheimer's disease using PET-based Braak staging. *Nat Aging.* 2022;2:526–35. DOI: [10.1038/s43587-022-00204-0](https://doi.org/10.1038/s43587-022-00204-0).
122. Gauthier S. Can we improve care of people with mild cognitive impairment or dementia in Canada? *Can J Neurol Sci.* 2023;1–3. DOI: [10.1017/cjn.2023.283](https://doi.org/10.1017/cjn.2023.283).