



Article  
scientifique

Rapport de  
cas

2020

Published  
version

Open  
Access

This is the published version of the publication, made available in accordance with the publisher's policy.

---

## Long-Term Positional Headaches Due to Cervical Cerebrospinal Fluid Leak After Acupuncture Treatment – A Case-Report

---

Constanthin, Paul; Vayssiere, Pia; Janssen, Insa; Tessitore, Enrico

### How to cite

CONSTANTHIN, Paul et al. Long-Term Positional Headaches Due to Cervical Cerebrospinal Fluid Leak After Acupuncture Treatment – A Case-Report. In: Journal of Clinical and Medical Images, 2020, vol. 4, n° 11, p. 1–3.

This publication URL: <https://archive-ouverte.unige.ch/unige:155529>

© The author(s). This work is licensed under a Creative Commons Attribution (CC BY)

<https://creativecommons.org/licenses/by/4.0>

## Long-Term Positional Headaches Due to Cervical Cerebrospinal Fluid Leak After Acupuncture Treatment – A Case-Report

Paul E Constanthin<sup>1,2\*</sup>, Pia Vayssière<sup>1,2</sup>, Insa Janssen<sup>1,2</sup> and Enrico Tessitore<sup>1,2</sup>

<sup>1</sup>Neurosurgery Department, Hôpitaux Universitaires de Genève, Geneva, Switzerland

<sup>2</sup>Neurosurgery Department, University of Geneva Medical Center, Faculty of Medicine, University of Geneva, Geneva, Switzerland

Volume 4 Issue 11- 2020

Received Date: 30 June 2020

Accepted Date: 18 July 2020

Published Date: 23 July 2020

### 2. Key words

Acupuncture; Dural leak;  
Neck pain

### 1. Abstract

Acupuncture is a frequent alternative treatment for both acute and chronic pain and its usage has spread widely during the last decades. This technique is however not free of adverse effects, mainly due to migrating material or excessive depth of needling, and some might durably impair patients' quality of life. In this article, we present a case of post-acupuncture traumatic cervical dural leak in a young female patient leading to chronic positional headaches resulting in a significant impairment of the patient's everyday life.

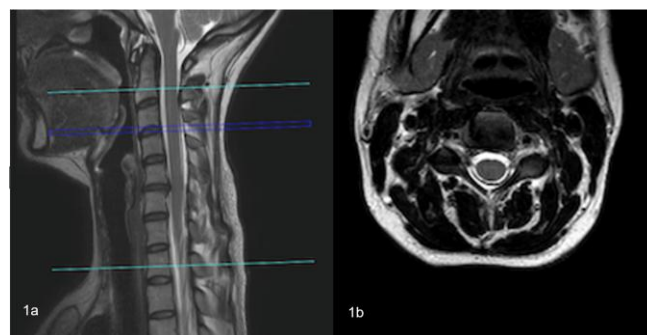
### 3. Introduction

Acupuncture is a well-known, widely used Chinese traditional treatment against chronic back pain and its efficacy (other than due to a simple placebo effect) has been suggested in several recent studies [2, 11] when treatment is provided by correctly trained practitioners. While majority of the adverse effects linked to acupuncture are minor, some cases of central nervous system involvement have now been identified, with potentially dire consequences [4, 7, 12–15]. In this article, we report the case of a patient presenting with positional headaches, nausea and fatigue (resulting in a significantly impaired quality of life) due to three traumatic dural leaks after cervical acupuncture treatment.

### 4. Case

A 37-year-old woman, with no past medical history except chronic neck pain due to a medial protrusion of the C5-C6 disc without neurological deficit and without surgical indication, consulted in our emergency department for positional headaches four days after having received acupuncture treatment for the aforementioned cervicalgia. The patient reported the sudden appearance of headaches and acute, electric pain along the entirety of the spine and in the four limbs (particularly in the left C6 dermatome) immediately after needling of her neck with four needles during the acupuncture session. While the spinal and left C6 pain disappeared at the end of the session, the headaches worsened progressively during the following days, becoming positional. The patient also reported nausea and vomiting. No other neurological symptoms were reported, and the physical examination remained normal except for the presence of 3 puncture points in the neck (no hematoma was noted). Laboratory testing did not show any abnormality (more specifically, no coagulation anomaly was found). A head and neck

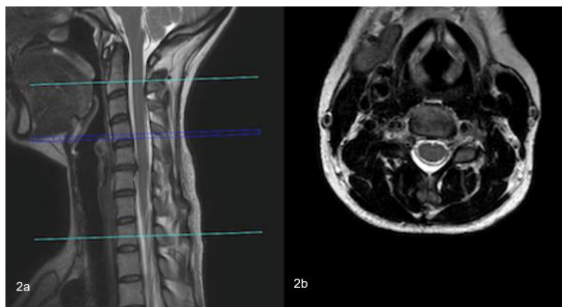
CT-scan did not find any hematoma, but a cervical MRI showed three dural leaks with visualization of the needles' trajectories in the cervical spine (Figure 1-3) confirming the cause of the leaks as being traumatic. The patient was hospitalized in our neurosurgical department where she was treated conservatively with bed rest (with her head resting at 0° compared to the rest of the bed), intravenous hydration and caffeine pills intake. A cerebral scan was performed in order to exclude a subdural hematoma induced by intracranial hypotension (Figure 4). The patient was progressively verticalized after seven days of treatment and could walk again two days later, allowing her discharge. Follow-up consults in our department at two, four and seven months showed only a very slight improvement of the patient's positional headaches, with worsening in the evening. She still reported intense fatigue with nausea and could only work part-time (compared to full-time before the acupuncture session). A control MRI, which was performed due to persisting residual symptoms, did not show any radiological signs of a remaining cervical CSF leakage after four months (Figure 5).



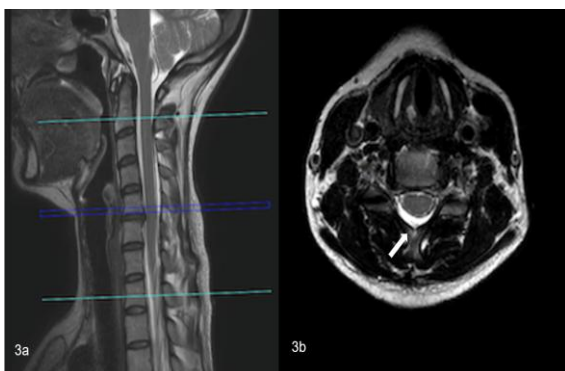
**Figure 1a:** A spinal extradural collection in the sagittal MRI (T2-sequence) expanded between C3 and C5, confirming the CSF leakage (arrows).

**Figure 1b:** The axial MRI (T2) also shows the typical double-contour as well as needles trajectory at level C3-C4 (arrow).

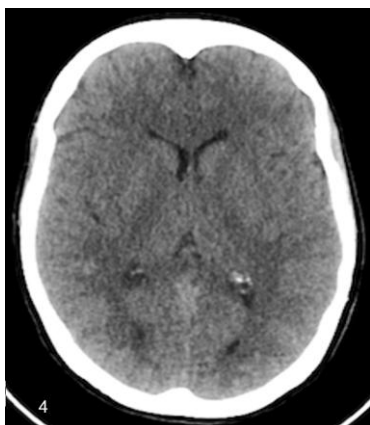\*Corresponding Author (s): Paul E Constanthin, Neurosurgery Department, Hôpitaux Universitaires de Genève, Rue Gabrielle Perret-Gentil 4, 1205 Genève, Switzerland, Tel: +41795533786, E-mail: paul.constanthin@hcuge.ch



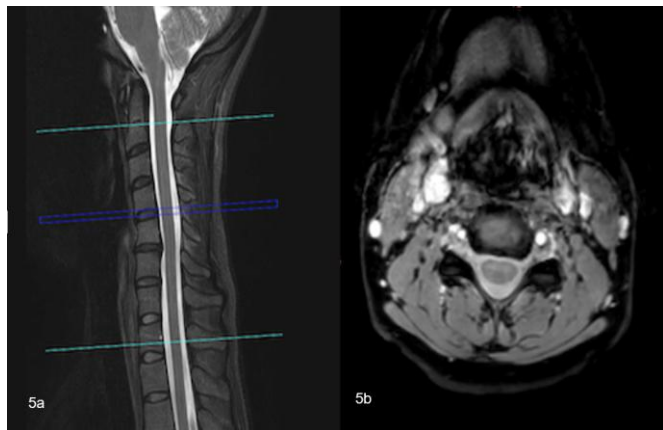**Figure 2:** Needles trajectory at level C4-C5 (arrow) in the axial MRI (T2) (Fig.2b)



**Figure 3:** Needles trajectory at level C5-C6 (arrow) in the axial MRI (T2) (Fig.3b)



**Figure 4:** A cerebral CT-scan ruled out the presence of a subdural hematoma.



**Figure 5:** An MRI realized at four months showed the disappearance of the extradural collection in both the sagittal and axial sequences.

## 5. Discussion

Chronic neck pain is a major burden for both the patient and society and is often very frustrating for specialists due to the limited response to traditional medical treatment [2]. Therefore, several alternative treatments have been proposed during the last decades, one of them being acupuncture [11, 14]. Acupuncture represents a very interesting adjuvant treatment as recent studies have suggested a positive effect of the technique on chronic neck pain and several researchers now believe that its effects are not only related to a placebo effect but might originate from other, electrophysiological components [1]. Due to its apparent successes, acupuncture is now recognized by several medical authorities (such as the Food and Drug Administration) and major efforts have been made to structure its licencing and practice. However, despite the relatively low invasiveness of the technique compared to surgical approaches, acupuncture is not free of complications, some of which can be of major concern for the patients' life. Indeed, in their review of the literature, Xu and colleagues found a total of 117 reports of adverse events of acupuncture, totalling to 308 events [13]. The most frequent adverse event after acupuncture is, by far, an infection (sometimes with dire consequences) while other, rarer cases, include lesions to internal organs. Of note, central nervous involvements (at both the cranial and spinal levels) have also been reported. Regarding spine [3, 5, 6, 10, 13], the lesion was either due to migration of the material or to an excessive depth of needling, often resulting in epidural hematoma due to penetration into the vertebral canal. Of note, to our knowledge, only two cases of cerebrospinal leakage, both through a lumbar fistula, were ever reported after acupuncture and hypotensive symptoms appeared weeks to months after treatment [8, 10]. In our case, the patient immediately experienced pain in the four limbs with positional headaches and the entirety of the material was removed. The dural leak was perfectly visible on the MRI due to the visualization of the needle trajectory. Such a case of acute dural leak has never, to our knowledge, been reported after acupuncture while this complication has already been reported in the cases of epidural anaesthesia [9]. Moreover, our case also underlines the long-term consequences that these lesions might have on the patients' life. Indeed, the patient's quality of life significantly decreased after the acupuncture session with daily positional headaches and fatigue, resulting in the impossibility to work full-time after more than half a year. The cause of the lesion being the depth of the needling, we believe it is of paramount importance, as was already underlined by the FDA, to precisely and correctly regulate the licencing and practicing of acupuncture 1) to allow this very interesting technique to reach its full potential and 2) to prevent such life-impairing adverse events to occur in the future.

## 6. Conclusion

Acupuncture is a well-known adjuvant therapy in the case of

chronic neck pain. Despite its relative low invasiveness, it still presents with risks and needs to be properly delivered to prevent major impairment to the life of patients.

## References

1. Bechara OMR, Bataglioni C, Palinkas M, Vasconcelos PB de, Sempriani M, Siessere S, et al. Changes in sternocleidomastoid and descending portion of trapezius muscles in terms of electromyography and pressure pain threshold: women with chronic neck pain after acupuncture treatment. *J Tradit Chin Med.* 2020; 40(1): 144-149.
2. Cohen SP, Hooten WM. Advances in the diagnosis and management of neck pain. *BMJ.* 2017. doi: 10.1136/bmj.j3221.
3. Domenicucci M, Marruzzo D, Pesce A, Raco A, Missori P. Acute Spinal Epidural Hematoma After Acupuncture: Personal Case and Literature Review. *World Neurosurg.* 2017; 102(695): e11-695. e14. doi: 10.1016/j.wneu.2017.03.125.
4. Lao L, Hamilton GR, Fu J, Berman BM. Is acupuncture safe? A systematic review of case reports. *Altern Ther Health Med.* 2003; 9(1): 72-83.
5. Lee JH, Lee H, Jo DJ. An acute cervical epidural hematoma as a complication of dry needling. *Spine (Phila Pa 1976).* 2011; 36(13): E891-3. doi: 10.1097/BRS.0b013e3181fc1e38.
6. Liou JT, Liu FC, Hsin ST, Sum DCW, Lui PW. Broken needle in the cervical spine: A previously unreported complication of Xiaozendao acupuncture therapy. *J Altern Complement Med.* 2007; 13(1): 129-32. doi: 10.1089/acm.2006.6007.
7. Melchart D, Weidenhammer W, Streng A, Reitmayr S, Hoppe A, Ernst E, et al. Prospective Investigation of Adverse Effects of Acupuncture in 97 733 Patients. *Arch Intern Med.* 2004; 164(1): 104-5. doi: 10.1001/archinte.164.1.104.
8. Noh SM, Lee KM, Kim BJ. Teaching NeuroImages: Cerebrospinal fluid leakage observed from skin after acupuncture. *Neurology.* 2019; 92: (10). doi: 10.1212/WNL.0000000000007045.
9. Pattichis A (Andreas), Slee M. CSF hypotension: A review of its manifestations, investigation and management. *J Clin Neurosci.* 2016. 34: 39-43. doi: 10.1016/j.jocn.2016.07.002.
10. Ulloth JE, Haines SJ. Acupuncture needles causing lumbar cerebrospinal fluid fistula. Case report. *J Neurosurg Spine.* 2007; 6(6): 567-9. doi: 10.3171/spi.2007.6.6.9.
11. Vickers AJ, Linde K. Acupuncture for chronic pain. *JAMA - J Am Med Assoc.* 2014; 311(9): 955-956. doi: 10.1001/jama.2013.285478.
12. Wu J, Hu Y, Zhu Y, Yin P, Litscher G, Xu S. Systematic Review of Adverse Effects: A Further Step towards Modernization of Acupuncture in China. *Evidence-based Complement Altern Med.* 2015; 2015: 432467. doi: 10.1155/2015/432467.
13. Xu S, Wang L, Cooper E, Zhang M, Manheimer E, Berman B, et al. Adverse events of acupuncture: A systematic review of case reports. *Evidence-based Complement Altern Med.* 2013; 2013: 581203. doi: 10.1155/2013/581203.
14. Yin C, Buchheit TE, Park JJ. Acupuncture for chronic pain: An update and critical overview. *Curr Opin Anaesthesiol.* 2017; 30(5): 583-592. doi: 10.1097/ACO.0000000000000501.
15. Zhang J, Shang H, Gao X, Ernst E. Acupuncture-related adverse events: A systematic review of the chinese literature. *Bull World Health Organ.* 2010; 88(12): 915-921C. doi: 10.2471/BLT.10.076737.