



Article scientifique

Article

2022

Published version

Open Access

This is the published version of the publication, made available in accordance with the publisher's policy.

---

## Insular Stimulation Produces Mental Clarity and Bliss

---

Nencha, Umberto; Spinelli, Laurent; Vulliemoz, Serge; Seeck, Margitta; Picard, Fabienne

### How to cite

NENCHA, Umberto et al. Insular Stimulation Produces Mental Clarity and Bliss. In: Annals of neurology, 2022, vol. 91, n° 2, p. 289–292. doi: 10.1002/ana.26282

This publication URL: <https://archive-ouverte.unige.ch/unige:158800>

Publication DOI: [10.1002/ana.26282](https://doi.org/10.1002/ana.26282)

# Insular Stimulation Produces Mental Clarity and Bliss

Umberto Nencha, MD,  
Laurent Spinelli, PhD,  
Serge Vulliemoz, MD, PhD,  
Margitta Seeck, MD, and  
Fabienne Picard, MD 

For the first time, an ecstatic aura has been evoked through the electrical stimulation of the dorsal anterior insula during presurgical invasive intracerebral monitoring in a patient who did not suffer from an ecstatic form of epilepsy. This case provides more evidence that the anterior insula is the major generator of such a mystical-type experience even in individuals with no underlying brain network changes related to a preexisting ecstatic epilepsy.

ANN NEUROL 2022;91:289–292

The anterior insular cortex (AIC) is dedicated to the processing of internal bodily stimuli (ie, interoception), contextualized by the external stimuli. There is a posterior to mid to anterior progression of integration of these stimuli within the insula, up to the ultimate representation into feelings in the AIC, which is considered a major structure for the sentient self.

The brain functions as a predictive coding machine to rapidly process and resolve the uncertainty arising from the ambiguous information provided by our environment.<sup>1</sup> Our perception of the world is the result of top-down predictions originating from deep generative models formed with time through our own life experiences, continuously compared with the real incoming signals, at many different hierarchical levels and time scales in the brain. When predictions and real incoming signals do not match, prediction errors are generated, and the next predictions are updated. Large prediction errors indicate the degree to which an outcome is unexpected and the predictive model was inaccurate. For interoception, the processing of prediction and prediction errors relevant to conscious experience has been suggested to involve primarily the AIC.<sup>2</sup> The interoceptive prediction errors reflect the uncertainty/ambiguity of the physiological state of the body associated with the environment. This is

consistent with the function of AIC in tracking risk, and uncertainty more generally.<sup>3,4</sup>

Ecstatic epilepsy is a rare type of focal epilepsy in which the patient experiences a modified state of consciousness, with a feeling of mental clarity (increased self-awareness, more vivid perception of the world), a distortion of time perception (“eternal now”), and a sense of union with the universe.<sup>5</sup> This state is similar to the mystical experience, which includes a state of knowledge or “insight into depths of truth” (revelation) and ineffability, as described by William James,<sup>6</sup> or to states of “pure perception” described by some expert meditators.

The localization of ecstatic seizures has long been considered to be the temporal lobe in the literature, due to the presence of temporal lobe lesions and/or of scalp electroencephalographic (EEG) interictal epileptiform discharges visible in the anterior temporal regions in some patients (see Picard and Craig<sup>7</sup>). The AIC has only more recently been recognized to be the symptomatogenic zone at the origin of the ecstatic phenomenon,<sup>5,8</sup> whether the epileptogenic zone is within the AIC, or within the temporal lobe with an ictal spread to the dorsal AIC.

In the past, we could reproduce an ecstatic state by electrical stimulation of the dorsal AIC in 3 patients suffering from a drug-resistant ecstatic epilepsy, during presurgical stereo-EEG (SEEG) monitoring.<sup>9,10</sup> Here, an ecstatic phenomenon was induced in a patient who had never experienced such a state, confirming the primary role of the AIC in access to this state.

## Subject and Methods

The patient was a 51-year-old male suffering from a refractory epilepsy since his first year of life, with a left hippocampal sclerosis on cerebral magnetic resonance imaging (MRI). His seizures did not comprise ecstatic symptoms, but a thoracic oppression, an impairment of awareness with oroalimentary automatisms, and bilateral hypermotor signs. Cerebral positron emission tomography

From the Department of Neurology, University Hospital and Medical School of Geneva, Geneva, Switzerland

Address correspondence to Dr Picard, Department of Neurology, University Hospital and Medical School of Geneva, Geneva, Switzerland. E-mail: fabienne.picard@hcuge.ch

Received Jun 8, 2021, and in revised form Nov 23, 2021. Accepted for publication Dec 5, 2021.

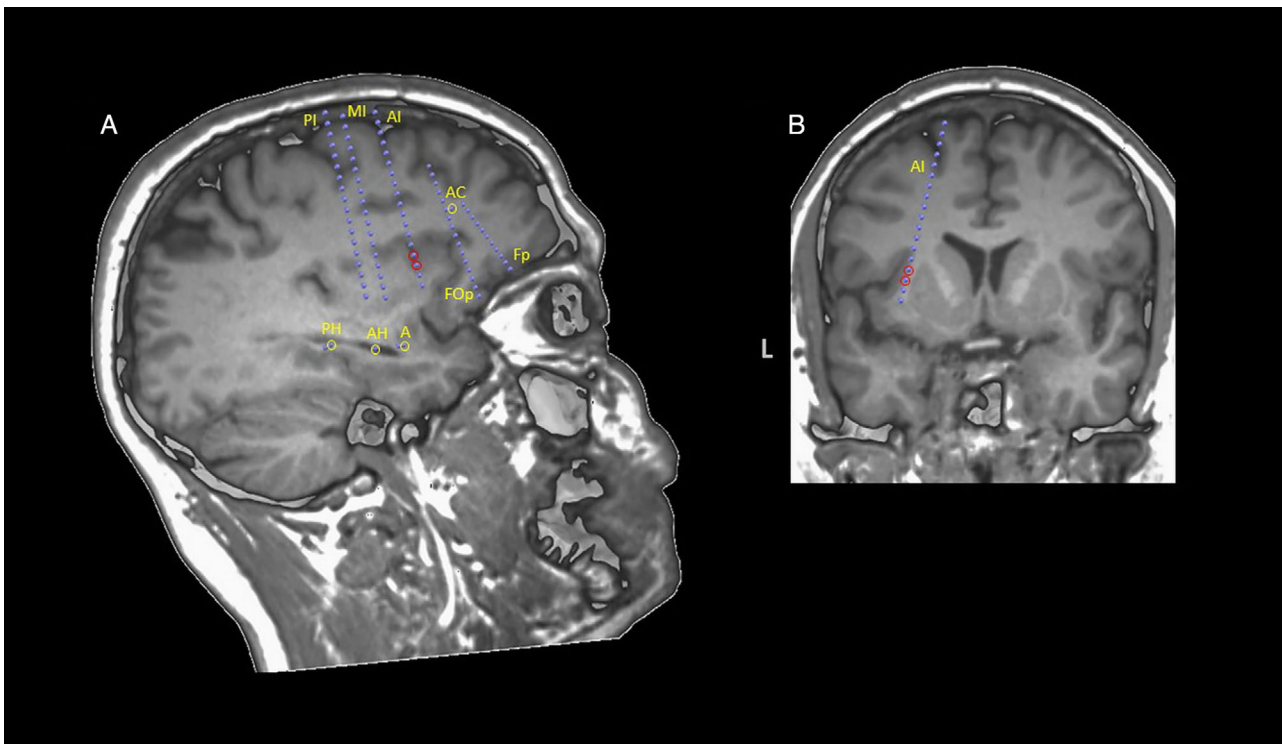
View this article online at [wileyonlinelibrary.com](http://wileyonlinelibrary.com). DOI: 10.1002/ana.26282.

(PET) using  $^{18}\text{F}$ -fluorodeoxyglucose (FDG) showed a left temporomesial and temporopolar hypometabolism, without any insular hypometabolism. Noninvasive presurgical evaluation suggested a probable left mesiotemporal lobe epilepsy, but invasive recording was indicated to rule out an extratemporal origin, given the prominent hypermotor semiology. SEEG recording included 9 intracerebral multilead electrodes (Microdeep; DIXI Medical, Besançon, France) stereotactically placed in the left amygdala, anterior and posterior hippocampus, anterior cingulate gyrus, frontopolar cortex, frontal operculum, and anterior insula (AI), middle insula (MI), and posterior insula (PI). Each electrode had multiple contacts, labeled according to their distance from the cortical surface (1 = deepest).

An electrical stimulation device integrated into the EEG equipment was used (SystemPlus; Micromed, Walferdange, Luxembourg). Electrical stimulation of contacts potentially involved in the epileptogenic zone was performed as a clinical procedure to test the

epileptogenicity of the contacts and map cortical functions. For each electrode, we successively stimulated the different pairs of adjacent contacts inside the gray matter (bipolar stimulation, frequency = 50Hz, overall pulse width = 1 millisecond, duration = 3 seconds) with current intensities from 0.5mA up to 6mA. The interval between one stimulation and the next was of at least 10 seconds. The patient was blinded to the timing of individual stimulation trains and their parameters. All the stimulations were performed the same day, while the patient was partially weaned from preimplantation anti-epileptic medication. He was at rest or talking with the physician during the stimulation session and was asked to report in detail any mental or emotional change in addition to physical sensations.

The ecstatic experience induced by the electrical stimulations was scored poststimulation with the revised 30-item Mystical Experience Questionnaire (MEQ-30), which has been validated in mystical-type experiences induced by consumption of psilocybin.<sup>11</sup> This questionnaire comprises



**FIGURE:** Localization of cortical stimulation contacts in the left dorsal anterior insular cortex (AIC), which is associated with mental clarity and bliss. Coregistration is shown of preimplantation T1-weighted magnetic resonance imaging and stereoelectroencephalography (SEEG) electrodes (localized from postimplantation computed tomography scan, not shown). (A) Sagittal plane showing the SEEG contacts of interest (red circles on contacts 3 and 4 of the left anterior insula [AI] electrode) as well as neighboring insular and extrainsular electrodes. As the electrodes are all oblique and not coplanar, some contacts remote from the insula are projected onto this plane to display the trajectory of the electrodes. Contact 4 of AI is at the junction between the white and gray matter and contacts the insular cortex. (B) Coronal plane showing the same contacts of interest (red circles) and highlighting their position at the cortical-subcortical junction in the left dorsal AIC. Electrical stimulation of these contacts at 2.7 to 3mA repeatedly produced a sensation of mental clarity, without any epileptiform afterdischarge on the SEEG, that is, without any visible propagation of the stimulation effect. A = amygdala; AC = anterior cingulate gyrus; AH = anterior hippocampus; FOp = frontal operculum; Fp = frontopolar cortex; L = left; MI = middle insula; PH = posterior hippocampus; PI = posterior insula.

4 subscales: mystical, positive mood, transcendence of time and space, and ineffability. The mystical subscale includes items for internal unity, external unity, noetic quality (the sense that objectively true aspects of reality have been revealed), and sacredness.

Written informed consent was obtained from the patient, and this single-case study was approved by the institutional review board (Commission Cantonale d'Éthique de la Recherche, University Hospitals of Geneva).

## Results

Spontaneous seizures occurred during sleep and started with low-amplitude fast rhythms in the amygdala and anterior hippocampus, with a propagation about 7 seconds later to the PI, MI, and AI, concomitant with an awakening, and involving several seconds later the anterior dorso-lateral frontal cortex simultaneously with the clinical onset (impairment of awareness and hypermotor semiology). There were no interictal EEG markers of epileptogenicity in the AI.

Electrical stimulation at 2.7 to 3mA for 3 seconds of contacts 3–4 of the electrode located in the dorsal AIC (AI3-4; Fig ) repeatedly produced a blissful sensation of mental clarity, without any epileptiform afterdischarge on the SEEG, that is, without any visible propagation of the stimulation effect (3 stimulations in total). The patient reported that “everything seems simplified”; he felt “he could take care of multiple problems at the same time.” He felt “liberated” and reported a very strong feeling of fullness. His consciousness “has suddenly enlarged”; “it is like looking at infinity, I no longer have any limits, as if everything was connected, and I was connected with any part around me.” He started to describe these symptoms 1 to 2 seconds after the end of the 3-second stimulations. Electrical stimulations of lower intensities of the same AI3-4 contacts induced either no symptoms (0.5–1.5mA), subtle trunk paresthesias (2mA), or a slight feeling of falling into the void (2.5mA). The ecstatic symptoms were not reproduced during the stimulation of other bipolar pairs of the AI electrode neighboring the AI3-4 contacts, nor of the other electrodes (MI, PI, amygdala, anterior hippocampus, and posterior hippocampus, with intensities up to 1–6mA, according to the contacts). Stimulation of the amygdalar electrode reproduced his typical auras of thoracic oppression.

On the MEQ-30 questionnaire, completed to describe the ecstatic symptoms experienced during the AI3-4 stimulations, the patient had a total score of 130 of 150 points, with a score  $\geq 60\%$  of the maximum possible score on each of the 4 subscales (mystical, 67/75; positive

mood, 19/30; transcendence of time and space, 30/30; and ineffability, 14/15), which is considered a “complete” mystical experience.

The patient benefited from a left anterior temporal lobectomy, with an excellent outcome on the 18-month follow-up (seizure-free, International League Against Epilepsy epilepsy surgery outcome = 1).

## Discussion

For the first time, ecstatic symptoms have been evoked by means of electrical stimulation of the dorsal AIC in a patient who had never presented such feelings before. It should be noted that the ecstatic phenomenon is not consistently obtained by stimulating the dorsal AIC, as such an effect has not been reproduced in 5 of our other pharmacoresistant patients who were tested in similar conditions. In the past, this phenomenon was induced in a few patients already suffering from ecstatic seizures,<sup>9,10</sup> who were thus possibly predisposed to ecstatic symptoms due to altered neural networks by repeated epileptic discharges.

The arguments supporting that the insula was not part of the epileptogenic zone in our patient are the following: (1) in all seizures, the onset of the ictal discharges involved only the anterior hippocampus and the amygdala; (2) there were no independent interictal epileptiform discharges in the insula; (3) the FDG-PET hypometabolism spared the insula; and (4) an anterior temporal lobectomy (not involving the insula) led to seizure freedom.

In our patient, the questionnaire's items concerning mental clarity in the mystical subscale (certainty of encounter with ultimate reality, gain of insightful knowledge experienced at an intuitive level) received a maximum value. As we already reported, the ecstatic state appears to be primarily related to a mental clarity, sometimes described as a feeling of hyper-reality<sup>10</sup> or a sense of certainty.<sup>8</sup> The ecstatic experience has often been called “mystical experience” in the literature.<sup>12</sup>

How could the AIC account for the generation of such a state of mental clarity, whether physiological or epilepsy-related? We already hypothesized that the epileptic activity occurring within the insula<sup>7</sup> could prevent the generation of interoceptive prediction errors.<sup>8,10</sup> We postulate that the AIC electrical stimulation causes an increased functional connectivity with several brain regions, and a supraoptimal level of AIC activity preventing its normal functioning.<sup>10</sup> Previous stimulation studies using corticocortical evoked potentials demonstrated that the dorsal AIC is a major network hub largely connected to various cortical regions, including the amygdala, hippocampus, and frontal cortical regions.<sup>13</sup> In the case of absence of interoceptive prediction errors, any conflict/surprise at the bodily level would disappear. Except in

certain deep states of meditation with a suspected suppression of the gain of prediction errors,<sup>14</sup> a state of absence of bodily conflict/surprise is totally unusual and could change the way the external world is interpreted, with a feeling of clarity and understanding.

This interpretation of the ecstatic state implies that the ultimate aim of the brain (allowing the attainment of bliss) is not value optimization, but is only to minimize surprise by satisfying its predictions, that is, to control uncertainty.<sup>15</sup> If confirmed, these findings have major implications for the decision sciences, which currently view human behavior as the result of value optimization. Theories may need to be reassessed, and based on control of uncertainty instead.

Our findings provide evidence that the AIC is a modulator for higher cognitive functions, able to underpin the state of mental clarity. An AIC dysfunction with disturbances of the interoceptive inference process (“amplified” interoceptive predictions) has also been suggested in neuropsychiatric disorders such as anxiety disorders and depression.<sup>16,17</sup> In this perspective, we suggest that the dorsal AIC could become a possible target for novel therapeutic approaches, potentially through noninvasive intermittent brain stimulation techniques. This could constitute an alternative to the current novel therapeutic field of psychedelic drugs in severe depression, on the assumption that a transitory mystical-type altered state of consciousness may induce long-lasting positive therapeutic effects.<sup>18,19</sup>

To sum up, it is the first time a causal link has been reported between disruption of a key brain region controlling awareness of uncertainty, and bliss, or “ecstatic experience,” in a patient who had never presented such experiences before and hence was not predisposed to such symptoms. Further research is needed (1) to understand why this ecstatic phenomenon occurs in only a subset of patients during the stimulation of the dorsal AIC and (2) to evaluate the potential beneficial role of dorsal AIC stimulation in some disabling neuropsychiatric disorders.

## Acknowledgments

This study was supported by SNF CRS115-180365 and 163398 (M.S.) and SNF CRS115-170873 and 192749 (S.V.). We thank Drs S. Momjian and M. Corniola, who performed the implantation of the intracerebral electrodes, and the patient who allowed that we report his case. Open access funding provided by Universite de Geneve.

## Author Contributions

F.P. contributed to the conception and design of the study; all authors contributed to the acquisition and

analysis of data; F.P., U.N., L.S., and S.V. contributed to drafting the text or preparing the figure.

## Potential Conflicts of Interest

Nothing to report.

## References

- Clark A. Whatever next? Predictive brains, situated agents, and the future of cognitive science. *Behav Brain Sci* 2013;36:181–204.
- Seth AK, Friston KJ. Active interoceptive inference and the emotional brain. *Philos Trans R Soc B* 2016;371:20160007.
- Singer T, Critchley HD, Preuschoff K. A common role of insula in feelings, empathy and uncertainty. *Trends Cogn Sci* 2009;13:334–340.
- Loued-Khenissi L, Pfeuffer A, Einhäuser W, Preuschoff K. Anterior insula reflects surprise in value-based decision-making and perception. *Neuroimage* 2020;210:116549.
- Gschwind M, Picard F. Ecstatic epileptic seizures: a glimpse into the multiple roles of the insula. *Front Behav Neurosci* 2016;10:21.
- James W. *The varieties of religious experience*. Cambridge, MA: Harvard University Press, 1985.
- Picard F, Craig A. Ecstatic epileptic seizures: a potential window on the neural basis for human self-awareness. *Epilepsy Behav* 2009;16:539–546.
- Picard F. State of belief, subjective certainty and bliss as a product of cortical dysfunction. *Cortex* 2013;49:2494–2500.
- Picard F, Scavarda D, Bartolomei F. Induction of a sense of bliss by electrical stimulation of the anterior insula. *Cortex* 2013;49:2935–2937.
- Bartolomei F, Lagarde S, Scavarda D, et al. The role of the dorsal anterior insula in ecstatic sensation revealed by direct electrical brain stimulation. *Brain Stimul* 2019;12:1121–1126.
- Barrett FS, Johnson MW, Griffiths RR. Validation of the revised mystical experience questionnaire in experimental sessions with psilocybin. *J Psychopharmacol* 2015;29:1182–1190.
- Taves A. Mystical and other alterations in sense of self: an expanded framework for studying nonordinary experiences. *Perspect Psychol Sci* 2020;15:669–690.
- Dionisio S, Mayoglou L, Cho SM, et al. Connectivity of the human insula: a cortico-cortical evoked potential (CCEP) study. *Cortex* 2019;120:419–442.
- Jamieson GA. A unified theory of hypnosis and meditation states: the interoceptive predictive coding approach. In: Lifshitz M, Raz A, eds. *Hypnosis and meditation: Towards an integrative science of conscious planes*. Oxford: Oxford University Press, 2015.
- Bossaerts P. Formalizing the function of anterior insula in rapid adaptation. *Front Integr Neurosci* 2018;12:61.
- Paulus MP, Stein MB. Interoception in anxiety and depression. *Brain Struct Funct* 2010;214:451–463.
- Paulus MP, Stein MB. An insular view of anxiety. *Biol Psychiatry* 2006;60:383–387.
- Davis AK, Barrett FS, May DG, et al. Effects of psilocybin-assisted therapy on major depressive disorder: a randomized clinical trial. *JAMA Psychiatry* 2021;78:481–489.
- Carhart-Harris RL, Bolstridge M, Rucker J, et al. Psilocybin with psychological support for treatment-resistant depression: an open-label feasibility study. *Lancet Psychiatry* 2016;3:619–627.