



Article scientifique

Article

2009

Published version

Open Access

This is the published version of the publication, made available in accordance with the publisher's policy.

Collagen crosslinking with ultraviolet-A and hypoosmolar riboflavin solution in thin corneas

Hafezi, Farhad; Mrochen, Michael; Iseli, Hans Peter; Seiler, Theo

How to cite

HAFEZI, Farhad et al. Collagen crosslinking with ultraviolet-A and hypoosmolar riboflavin solution in thin corneas. In: Journal of cataract and refractive surgery, 2009, vol. 35, n° 4, p. 621–624. doi: 10.1016/j.jcrs.2008.10.060

This publication URL: <https://archive-ouverte.unige.ch/unige:22472>

Publication DOI: [10.1016/j.jcrs.2008.10.060](https://doi.org/10.1016/j.jcrs.2008.10.060)

Collagen crosslinking with ultraviolet-A and hypoosmolar riboflavin solution in thin corneas

Farhad Hafezi, MD, PhD, Michael Mrochen, PhD, Hans Peter Iseli, MD, Theo Seiler, MD, PhD

Corneal collagen crosslinking (CXL) with riboflavin and ultraviolet-A light is a method for treating progressive keratectasia. The currently accepted treatment parameters induce collagen crosslinking in the anterior 250 to 350 μm of corneal stroma. To protect the endothelium, CXL inclusion criteria require a minimum corneal thickness of 400 μm after removal of the epithelium. In advanced keratoconus, however, progressive corneal thinning often leads to a remaining stromal thickness of less than 400 μm . We have therefore modified the current treatment protocol by preoperatively swelling thin corneas to a stromal thickness of at least 400 μm using hypoosmolar riboflavin solution. This treatment protocol was performed in a case series of 20 patients, and no complications were observed. Preoperative swelling of the cornea safely broadens the spectrum of CXL indications to thin corneas that would otherwise not be eligible for treatment.

J Cataract Refract Surg 2009; 35:621–624 © 2009 ASCRS and ESCRS

Riboflavin and ultraviolet-A (UVA)-induced crosslinking of corneal collagen (CXL) is a method to increase the biomechanical^{1–4} and biochemical^{5,6} stability of the cornea by inducing additional crosslinks within or between collagen fibers using UVA light and the photomediator riboflavin. The therapeutic potential of CXL to treat progressive keratoconus was demonstrated in a clinical pilot study,³ as well as in controlled prospective studies and in case reports and case series of patients with iatrogenic keratectasia after refractive laser surgery.^{7–10} Before the first application in humans in 1999,³ the parameters of the method (riboflavin concentration, intensity and wavelength of UVA light, and duration of treatment) were established in a series of time- and dose-response assays in animal models

over several years.^{2–4,11–14} To protect the corneal endothelium and deeper ocular structures, the currently used treatment parameters are set so the anterior 250 to 350 μm of corneal stroma are treated.¹⁵ Accordingly, the current inclusion criteria require a minimum stromal thickness (without the corneal epithelium) of 400 μm , including a safety margin.

In many cases of advanced progressive keratectasia, patients achieve a satisfactory visual acuity with contact lenses, and a low minimum stromal thickness is the only parameter prohibiting safe CXL. We present a modified technique of CXL using hypoosmolar riboflavin solution to induce stromal swelling and increase the stromal thickness before CXL in cases with preoperatively thin corneas.

TECHNIQUE

Isoosmolar riboflavin 0.1% solution is generated by diluting vitamin B₂-riboflavin-5-phosphate 0.5% (G. Streuli & Co. AG) with dextran T500 20% (Roth AG) (402.7 mOsmol/L). The solution is protected from light and used within 2 hours. Hypoosmolar riboflavin 0.1% solution is generated by diluting vitamin B₂-riboflavin-5-phosphate 0.5% with physiological salt solution (sodium chloride 0.9% solution, B. Braun Medical AG) (310 mOsmol/L). Hypoosmolar riboflavin solution does not contain dextran T500. It is protected from light and used within 2 hours.

After 9.0 mm of the corneal epithelium is abraded, isoosmolar riboflavin 0.1% solution with dextran T500 is applied to the cornea every 3 minutes for

Submitted: February 3, 2008.

Final revision submitted: October 22, 2008.

Accepted: October 26, 2008.

From the Institute for Refractive and Ophthalmic Surgery, Zurich, Switzerland.

Dr. Mrochen has a financial interest as the producer of the UV device used in this study. No other author has a financial or proprietary interest in any material or method mentioned.

Presented at the Third International Cross-Linking Congress, Zurich, Switzerland, December 2007.

Corresponding author: Farhad Hafezi, MD, PhD, Institute for Refractive and Ophthalmic Surgery, Stockerstrasse 37, 8002 Zurich, Switzerland. E-mail: farhad.hafezi@iroc.ch.

30 minutes. After 30 minutes, ultrasound pachymetry (5 repetitive measurements) is performed on the deepithelialized cornea at approximately the thinnest point. Hypoosmolar riboflavin is applied every 20 seconds for 5 more minutes, and the corneal thickness is checked by ultrasound pachymetry again. Hypoosmolar riboflavin solution is again administered until the minimal corneal thickness reaches 400 μm . Successful penetration of riboflavin through the cornea is ensured by visualization of riboflavin in the anterior chamber by slitlamp biomicroscopy (using blue light).

The eye is then irradiated for 30 minutes with UVA at a working distance of 5 cm with an irradiance of 3 mW/cm^2 , corresponding to a surface dose of 5.4 J/cm^2 (UV-X, Peschke Meditrade). During treatment, isotonic riboflavin 0.1% solution and a topical anesthetic agent (oxybuprocaine 0.4%) are administered every 5 minutes to saturate the cornea with riboflavin.

After the treatment, antibiotic ointment (ofloxacin 0.3%) and a bandage contact lens soaked in a preservative-free antibiotic agent (ofloxacin 0.3%) are applied until the corneal epithelium has healed completely. Fluorometholone eyedrops are then applied twice daily for 2 weeks.

Clinical Study and Results

Since 2006, the technique has been used in 20 patients with progressive keratoconus and iatrogenic keratectasia after refractive laser surgery. The mean patient age of the 13 men and 7 women was 29.5 years (range 19 to 42 years). In all patients, the central stromal thickness after abrasion of the epithelium was at least 320 μm measured by ultrasound pachymetry. Progression of the keratectasia was verified by corneal topographies over a minimum of 6 months. Only eyes with distinct keratoconus (maximum K-reading > 58 diopters [D]) and a minimum stromal thickness of 320 μm to 400 μm after removal of the epithelium were included in the treatment group. Before the study, patients were informed that if stromal thickness were less than 320 μm after the epithelium was removed, CXL would not be performed. In this circumstance, the epithelium would be allowed to heal as described below. However, in all patients in the study, the remaining stromal thickness after removal of the epithelium and before swelling with hypoosmolar riboflavin solution measured at least 320 μm .

The patients were examined preoperatively, early postoperatively (1 to 3 days until healing of the epithelium), and 1, 3, and 6 months after the treatment. Preoperatively and at every follow-up except early postoperatively, the examination included corneal topography (Keratograph C, Oculus), Scheimpflug imaging (Pentacam 70700, Oculus), and slitlamp

Table 1. Preoperative findings.

Case	Sex	Age (Y)	Reason	US Pachymetry (μm)			
				Pre Abrasion	Post Abrasion	Post Swelling	Increase (μm)
1	M	19	Prog KC	424	385	432	+47
2	M	23	Prog KC	367	330	435	+105
3	M	40	Prog KC	443	395	428	+33
4	M	24	Prog KC	404	366	448	+82
5	F	31	Prog KC	379	337	414	+77
6	F	29	Prog KC	385	352	421	+69
7	M	32	Prog KC	393	353	407	+54
8	M	24	Prog KC	389	339	404	+65
9	M	20	Prog KC	398	323	410	+87
10	M	35	Prog KC	364	327	402	+75
11	M	27	Prog KC	416	386	462	+76
12	F	19	Prog KC	432	391	465	+74
13	F	24	Prog KC	409	371	423	+52
14	M	19	Prog KC	421	376	450	+74
15	F	42	Iatr kerat	410	363	421	+58
16	M	38	Iatr kerat	448	396	446	+50
17	F	38	Iatr kerat	435	393	471	+78
18	M	41	Iatr kerat	362	328	403	+75
19	F	26	Iatr kerat	437	393	446	+53
20	M	38	Iatr kerat	415	389	431	+42

Iatr kerat = iatrogenic keratectasia; Prog KC = progressive keratoconus; US = ultrasound

examination of the anterior and posterior segments of the eyes.

Patients using rigid contact lenses were asked to remove them at least 3 weeks before the preoperative examination and before each follow-up examination.

Table 1 summarizes the preoperative corneal swelling behavior in the 20 patients. At 6 months, no signs of postoperative endothelial damage or changes in corneal clarity or any other side effects were seen. Scheimpflug analysis of the maximum K-readings showed no progression of the keratectasia ($\Delta K_{\text{max}} \geq +1.0$ D); stabilization of the keratectasia ($+1.0 \text{ D} \geq \Delta K_{\text{max}} + B_6 \leq -1.0 \text{ D}$) was observed in 12 patients and regression, in 8 patients ($\Delta K_{\text{max}} \geq -1.0 \text{ D}$). The absolute increase in corneal thickness ranged from 36 μm to 110 μm ; the thinnest cornea was 323 μm after the epithelium was removed and before the hypoosmolar riboflavin solution was instilled.

Figure 1 shows a thickness map generated by optical pachymetry (Pentacam image) to demonstrate the effect of hypoosmolar riboflavin solution on a moderately thinned keratoconus cornea. Figure 2 shows the intraoperative changes in corneal thickness in one case. Before corneal abrasion, the minimum corneal thickness measured by ultrasound pachymetry was 398 μm . After corneal abrasion, the minimum

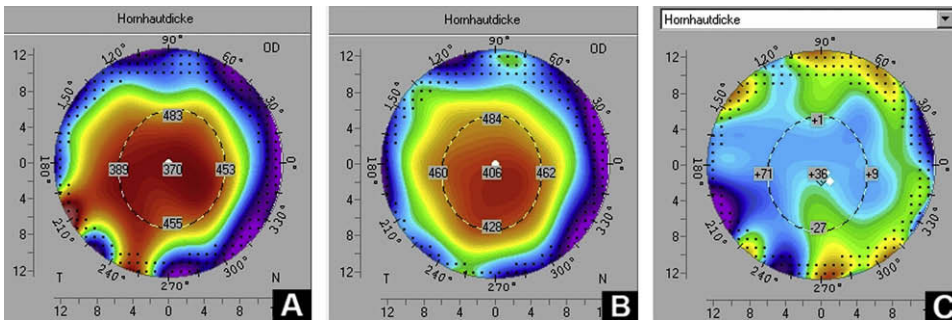


Figure 1. A: Corneal thickness after removal of the epithelium and instillation of isotonic 0.1% riboflavin solution for 30 minutes. B: Corneal swelling after 5 minutes of instillation of hypoosmolar riboflavin 0.1% solution. C: The increase in corneal thickness (difference map).

thickness was 323 μm , which increased slightly to 330 μm after the isotonic riboflavin solution was applied for 30 minutes. Following an additional application of hypoosmolar riboflavin solution for 10 minutes, the stromal thickness increased to 410 μm .

DISCUSSION

Control of corneal hydration is based on several factors such as active transendothelial transport and the epithelial and endothelial barrier. If one of these mechanisms is impaired, corneal swelling and edema occur.^{16–19} Under physiologic circumstances, the corneal stroma shows a swelling pressure of 50 to 60 mm Hg.¹⁶ Swelling of the corneal stroma can be achieved using a solution with a low colloid osmotic pressure. Such a hypoosmolar solution was used in this case series. The deepithelialized cornea can swell to double its normal thickness when irrigated with a hypoosmolar solution.¹⁹ This phenomenon is not due to an increase in the diameter of the collagen fibrils but rather to the hydrophilic capacities of the stromal proteoglycans, creating collagen-free “lakes.”¹⁷ This characteristic behavior is used to increase corneal thickness before the CXL procedure.

In Figure 1, a thickness map generated by optical pachymetry shows the effect of hypoosmolar riboflavin solution on a moderately thinned keratoconus cornea. However, in clinical practice, optical pachymetry does not provide reliable data in swollen corneas because of the increased light scattering and absorption.²⁰ Therefore, in our cases, all measurements were carried out

with an ultrasound pachymeter (SP 2000, Tomey GmbH) (Figure 2).

Clinically, the promptness of the stromal swelling response and the amount of swelling showed distinct interindividual variation (3 minutes to 20 minutes; 36 to 105 μm). In several cases, repeat application of the hypoosmolar solution followed by ultrasound pachymetry was needed to obtain a minimum stromal thickness of 400 μm . In this case series, we could not determine whether age, sex, or the underlying condition influenced the variation in promptness and/or the amount of stromal swelling.

Parameters other than the osmolarity of the riboflavin solution could be modified to obtain a more shallow depth of treatment; ie, the intensity of the UVA light, the duration of treatment, or the intensity of riboflavin concentration. However, changing these parameters would substantially modify the amount and distribution of induced radicals and, for safety reasons, would require new dose-response assays in the animal model or at least a computational model that fits experimental data.¹⁵ In contrast, the exclusive change in the osmolarity of the riboflavin solution, while maintaining the concentration at 0.1%, probably does not alter the final riboflavin concentration in the cornea.

Human keratoconus corneas show an altered ratio of dermatan sulfate/keratan sulfate proteoglycans,²¹ and little is known about the swelling properties of the keratoconus cornea. Although the results in our series are promising, it is not yet clear whether swollen corneas demonstrate the same behavior after CXL as nonswollen keratoconus corneas. Furthermore, clinical follow-up of more than 6 months is necessary to determine

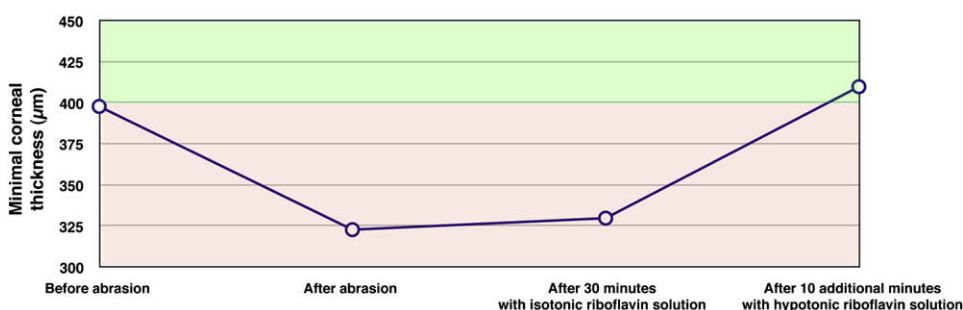


Figure 2. Stromal swelling prior to CXL in the case of a 20-year-old man who showed progressive keratoconus in the right cornea with a maximum K-value of 56.7 and a minimum corneal thickness of 398 μm (including the epithelium) in ultrasound pachymetry (Tomey GmbH) and 392 μm in optical pachymetry (Oculus Instruments).

whether the high success rate in stabilization achieved in keratoconus patients with thicker corneas can be achieved in patients with swollen corneas. Finally, we cannot rule out subclinical effects on the corneal endothelium.

We perform corneal swelling before CXL in cases of progressive keratoconus and iatrogenic keratectasia when the minimum stromal thickness is less than 400 μm . Some might consider implantation of intrastromal rings as a therapeutic alternative to CXL in such cases. However, it has been demonstrated repeatedly that in advanced keratoconus, keratectasia progresses after intrastromal ring implantation.

In conclusion, preoperative swelling of the cornea safely broadens the spectrum of CXL indications to corneas that would otherwise not be eligible for treatment due to low minimum stromal thickness.

REFERENCES

1. Spoerl E, Huhle M, Seiler T. Induction of cross-links in corneal tissue. *Exp Eye Res* 1998; 66:97–103
2. Wollensak G, Spoerl E, Seiler T. Stress-strain measurements of human and porcine corneas after riboflavin-ultraviolet-A-induced cross-linking. *J Cataract Refract Surg* 2003; 29:1780–1785
3. Wollensak G, Spoerl E, Seiler T. Riboflavin/ultraviolet-a-induced collagen crosslinking for the treatment of keratoconus. *Am J Ophthalmol* 2003; 135:620–627
4. Wollensak G, Spörl E, Seiler T. Behandlung von Keratoconus durch Kollagenvernetzung [Treatment of keratoconus by collagen cross linking]. *Ophthalmologe* 2003; 100:44–49
5. Seli HP, Thiel MA, Hafezi F, Kampmeier J, Seiler T. Ultraviolet A/riboflavin corneal cross-linking for infectious keratitis associated with corneal melts. *Cornea* 2008; 27:590–594
6. Spoerl E, Wollensak G, Seiler T. Increased resistance of cross-linked cornea against enzymatic digestion. *Curr Eye Res* 2004; 29:35–40
7. Caporossi A, Baiocchi S, Mazzotta C, Traversi C, Caporossi T. Parasurgical therapy for keratoconus by riboflavin-ultraviolet type A rays induced cross-linking of corneal collagen; preliminary refractive results in an Italian study. *J Cataract Refract Surg* 2006; 32:837–845
8. Hafezi F, Kanellopoulos J, Wiltfang R, Seiler T. Corneal collagen crosslinking with riboflavin and ultraviolet A to treat induced keratectasia after laser in situ keratomileusis. *J Cataract Refract Surg* 2007; 33:2035–2040
9. Kohlhaas M, Spoerl E, Speck A, Schilde T, Sandner D, Pillunat LE. Eine neue Behandlung der Keratektasie nach LASIK durch Kollagenvernetzung mit Riboflavin/UVA-Licht. [A new treatment of keratectasia after LASIK by using collagen with riboflavin/UVA light cross-linking]. *Klin Monatsbl Augenheilkd* 2005; 222:430–436
10. Raiskup-Wolf F, Hoyer A, Spoerl E, Pillunat LE. Collagen cross-linking with riboflavin and ultraviolet-A light in keratoconus: long-term results. *J Cataract Refract Surg* 2008; 34:796–801
11. Wollensak G, Aurich H, Pham D-T, Wirbelauer C. Hydration behavior of porcine cornea crosslinked with riboflavin and ultraviolet A. *J Cataract Refract Surg* 2007; 33:516–521
12. Wollensak G, Spoerl E, Reber F, Seiler T. Keratocyte cytotoxicity of riboflavin/UVA-treatment in vitro. *Eye* 2004; 18:718–722
13. Wollensak G, Spoerl E, Wilsch M, Seiler T. Keratocyte apoptosis after corneal collagen cross-linking using riboflavin/UVA treatment. *Cornea* 2004; 23:43–49
14. Wollensak G, Spörl E, Reber F, Pillunat L, Funk R. Corneal endothelial cytotoxicity of riboflavin/UVA treatment in vitro. *Ophthalmic Res* 2003; 35:324–328
15. Spoerl E, Mrochen M, Sliney D, Trokel S, Seiler T. Safety of UVA-riboflavin cross-linking of the cornea. *Cornea* 2007; 26:385–389
16. Dohlman CH, Hedbys BO, Mishima S. The swelling pressure of the corneal stroma. *Invest Ophthalmol* 1962; 1:158–162. Available at: <http://www.iovs.org/cgi/reprint/1/2/158>. Accessed December 21, 2008
17. Dohlman CH. Physiology of the cornea: corneal edema. In: Smolin G, Thoft RA, eds, *The Cornea: Scientific Foundations and Clinical Practice*, 2nd ed. Boston, MA, Little, Brown and Company, 1987; 3–16
18. Hara T, Maurice DM. Changes in the swelling pressure of the corneal stroma with time, hydration and temperature, determined by a new method. *Exp Eye Res* 1972; 14:40–48
19. Maurice DM, Giardini AA. Swelling of the cornea in vivo after the destruction of its limiting layers. *Br J Ophthalmol* 1951; 35:791–797. Available at: <http://www.pubmedcentral.nih.gov/picrender.fcgi?artid=1323849&blobtype=pdf>. Accessed December 21, 2008
20. Swartz T, Marten L, Wang M. Measuring the cornea: the latest developments in corneal topography. *Curr Opin Ophthalmol* 2007; 18:325–333
21. Wollensak J, Buddecke E. Biochemical studies on human corneal proteoglycans—a comparison of normal and keratoconic eyes. *Graefes Arch Clin Exp Ophthalmol* 1990; 228:517–523



First author:

Farhad Hafezi, MD, PhD

Institute for Refractive and Ophthalmic Surgery, Stockerstrasse, Zurich, Switzerland