



Article
scientifique

Revue de la
littérature

2001

Published
version

Open
Access

This is the published version of the publication, made available in accordance with the publisher's policy.

Esthesioneuroblastoma: a meta-analysis and review

Dulguerov, Pavel; Allal, Abdelkarim Said; Calcaterra, Thomas C

How to cite

DULGUEROV, Pavel, ALLAL, Abdelkarim Said, CALCATERRA, Thomas C. Esthesioneuroblastoma: a meta-analysis and review. In: Lancet oncology, 2001, vol. 2, n° 11, p. 683–690. doi: 10.1016/S1470-2045(01)00558-7

This publication URL: <https://archive-ouverte.unige.ch/unige:26084>

Publication DOI: [10.1016/S1470-2045\(01\)00558-7](https://doi.org/10.1016/S1470-2045(01)00558-7)

Esthesioneuroblastoma: a meta-analysis and review

Pavel Dulguerov, Abdelkarim S Allal, and Thomas C Calcaterra

Our objective was to review recent developments in diagnosis, staging, and treatment of esthesioneuroblastoma (ENB). A meta-analysis of publications between 1990 and 2000 was carried out, and studies were classified according to their main subject: origin/aetiology of ENB, histopathological diagnosis, and treatment. Data so far point to the basal progenitor cells of the olfactory epithelium as the origin of ENB. Histopathological diagnosis remains difficult and is based on results of antigen expression detected through a panel of antibodies by immunohistochemistry. RT-PCR of HASH expression could be a specific marker of ENB. Overall and disease-free survival at 5 years averaged 45% (SD 22) and 41% (SD 21) in the studies included in the meta-analysis. Survival in Hyams' grades I–II was 56% (SD 20) compared with 25% (SD 20) in grades III–IV (odds ratio 6.2). In patients with metastases in cervical lymph nodes (on average 5% of the total) survival was 29%, compared with 64% for patients with N0 disease (odds ratio 5.1). Survival according to treatment modalities was 65% for surgery plus radiotherapy, 51% for radiotherapy and chemotherapy, 48% for surgery, 47% for surgery plus radiotherapy and chemotherapy, and 37% for radiotherapy alone. The histopathological grading according to Hyams and the presence of cervical lymph-node metastases emerged as prognostic factors. A combination of surgery and radiotherapy seems to be the optimum approach to treatment. The exact role of chemotherapy in treatment protocols is still unclear. The role of elective neck dissection is unclear.

Lancet Oncol 2001; **2**: 683–90

Esthesioneuroblastoma (ENB) is an uncommon malignant neoplasm of the nasal vault, believed to arise from the olfactory epithelium. The tumour was first described in 1924 by Berger and colleagues, and given the name *esthésioneuroépithéliome olfactif*.¹ Uncertainty about the precise histological origin has led to the use of various names for this tumour, but the only two terms used in recent publications are esthesioneuroblastoma and olfactory neuroblastoma.

Just as there are differing views about the most appropriate name for this unusual tumour, there are many opinions about its origin, diagnosis, and management. The controversy arises primarily from the fact that almost no individual clinician or even institution will treat more than a few patients a year with this diagnosis. Three other factors contribute to the controversy.² First, the tumour shows

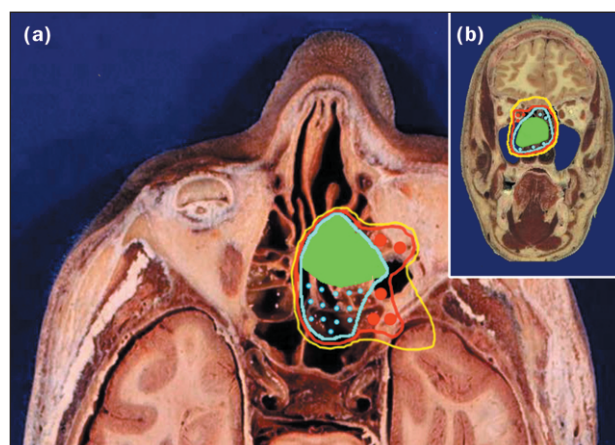


Figure 1. Graphic representation of the UCLA T staging system in the horizontal (a) and coronal (b) planes. Stage T1 is depicted in green, T2 in blue, T3 in red, and T4 in yellow. Original coronal section of the head from the Visible Human Project.

varying biological activity, ranging from indolent growth, with patients surviving with known tumour for more than 20 years, to a highly aggressive neoplasm, capable of rapid widespread metastasis with survival limited to a few months. Second, ENB is easily confused with other undifferentiated neoplasms of the nasal cavity. Third, no universally accepted staging system is available.

Kadish and coworkers were the first to propose a staging classification, of three categories, for ENB.³ Group A is limited to tumours of the nasal fossa; in group B extension is to the paranasal sinuses; group C is defined as extension beyond the paranasal sinuses. Recognising the many shortcomings of this staging system, we proposed a classification based on the more familiar TNM system (Figure 1; Table 1).² The staging can be accomplished before treatment and is largely based on computed tomography (CT) and magnetic resonance imaging (MRI), which are quite reliable in assessing the anatomical extent of disease. Therefore, patients given primary or preoperative radiotherapy can be staged as reliably as those who are candidates for surgery. Although this classification system

PD is at the Division of Head and Neck Surgery and ASA at the Division of Radiation Oncology, Geneva University Hospital, Geneva, Switzerland. TCC is at the Division of Head and Neck Surgery, UCLA Medical Center, Los Angeles, CA, USA.

Correspondence: Pavel Dulguerov, MD PD, Department of Otolaryngology – Head and Neck Surgery, Geneva University Hospital, 24 rue Micheli-du-Crest, Geneva, CH-1205 Switzerland. Tel: +41 22 372 8285. Fax: +41 22 372 8240. E-mail: pavel.dulguerov@hcuge.ch

Table 1. Esthesioneuroblastoma staging system²

Stage	Characteristics
T1	Tumour involving the nasal cavity and/or paranasal sinuses (excluding sphenoid), sparing the most superior ethmoidal cells
T2	Tumour involving the nasal cavity and/or paranasal sinuses (including the sphenoid) with extension to or erosion of the cribriform plate
T3	Tumour extending into the orbit or protruding into the anterior cranial fossa, without dural invasion
T4	Tumour involving the brain
N0	No cervical lymph-node metastasis
N1	Any form of cervical lymph-node metastasis
M0	No metastases
M1	Distant metastasis

has gained popularity,⁴⁻⁶ various attempts have been made to modify the Kadish system for ENB.^{7,8}

Within the past decade, there has been progress in identifying the origin of ENB, which should lead to more precise diagnosis. In addition, although surgery and radiotherapy have remained the main treatments, chemotherapy has been increasingly used. Because of the rarity of this disease, a meta-analysis approach to comparison of treatment modalities could be helpful. The purpose of this paper is to provide such a statistical analysis and to assess recent developments through a systematic review.

Methods

Because of the small number of patients, Hyams' histopathological grades (Table 2; Figure 2) are commonly analysed in two groups (grades I and II versus grades III and IV). Since in most cases data were reported in this way only, we also used this grouping. Outcome according to the clinical staging of the Kadish, as well as the Dulguerov-Calcaterra classifications, were tabulated, but not statistically analysed because present meta-analysis statistical methods are geared to comparison of two groups.

The treatment modalities used were surgery alone; surgery and radiotherapy; radiotherapy alone; a combination of surgery, radiotherapy, and chemotherapy; radiotherapy and chemotherapy; surgery and chemotherapy; and chemotherapy alone. Only the original treatment modality was considered, independently of any salvage therapy for recurrence. Because of the small number of patients, the sequence of treatments was not taken into account. Statistical analysis compared the different treatment modalities against the approach with the highest average survival (surgery and radiotherapy). Because few patients had chemotherapy alone or with surgery, statistical analysis was not done for these two groups.

The type of recurrence (local, regional, or distant) was tabulated overall, since the exact site of first recurrence was not available in all publications.

Data were tabulated in a spreadsheet for basic calculations, averages, and standard deviations. They were arranged to correspond to a contingency table: for example, in comparing the survival of patients treated with surgery

versus those treated with surgery and radiotherapy, the numbers of surviving and deceased patients for each treatment modality were calculated for each study. This approach was used for all pairs of variables that were statistically compared. Statistical evaluation of the data was done with the MetaWin software (version 2; Sinauer, Sunderland, MA, USA).⁹¹ The two-by-two contingency data algorithm was used for all variables to calculate the effect size and variance of the odds ratio for each study. The cumulative size effect of the odds ratio across all studies was used to assess the significance of differences between pairs of variables. Fixed and random effects calculations were done, but only the more conservative random effects calculation was used for the statistical evaluation. Data are presented as odds ratios.

The total heterogeneity among studies was assessed by calculation of the sum of the weighted difference between

Search strategy and selection criteria

The MEDLINE database was searched with the combination 'esthesioneuroblastoma' and 'olfactory neuroblastoma', from 1990 to 2000, without language tags. The search was supplemented by cross-checking of the references in each publication. Among the 242 articles retrieved, we excluded 53 that did not report directly on ENB cases, 12 that dealt with radiology issues, ten reviews on ENB, and 13 reviews of treatments for base-of-skull neoplasms of mixed histology. We arbitrarily decided to include only articles reporting on five or more cases, further excluding 88 references. Finally, nine publications were excluded because the language of the article was not English, French, German, Italian, or Spanish.

The remaining 57 publications constitute the basis of this review. These were supplemented by another 19 relevant publications found in references cited.^{4,9-26} The studies were divided into three types, according to their principal objectives: origin and aetiology of ENB,^{9,11,15,17-19,21,24,27-40} histopathological diagnosis,^{10,12-14,23,37,41-53} and treatment.^{2,4-8,16,20,22,25,26,43,54-78} The remaining 14 cited publications are of historical interest^{1,3,79-84} or concern ENB indirectly,⁸⁵⁻⁹⁰ and they were not directly used in the data analysis.

Studies on the origin, aetiology, and histopathological diagnosis were reviewed subjectively and summarised in the discussion.

Among the 37 treatment studies, analysis was restricted to 26 because seven articles were repeated reports probably on the same patients,^{16,59,61,67,74-76} and four^{20,22,25,26} only covered specific aspects of the treatment of ENB. Data extracted from the studies were the total number of patients, the staging system used, the patients' distribution by stage and by histological grade, and the type of treatment. Outcome data consisted of recurrence-free survival at 3 years and 5 years, overall survival at 5 years and 10 years, and the results by stage, grade, and treatment modality. For data on grading, staging, and treatment, at least 2-year disease-free survival was used. The studies were selected and data extracted independently by two authors. Differences were reconciled through discussion.

Table 2. Histopathological grading, according to Hyams¹⁴

Grade	Lobular architecture preservation	Mitotic index	Nuclear polymorphism	Fibrillary matrix	Rosettes	Necrosis
I	+	none	none	prominent	HW rosettes	none
II	+	low	moderate	present	HW rosettes	none
III	+/-	moderate	prominent	low	FW rosettes	rare
IV	+/-	high	marked	absent	none	frequent

HW, Homer Wright; FW, Flexner-Wintersteiner rosettes

individual and total size effects⁹² and compared with the χ^2 distribution. Publication bias was assessed graphically by examining funnel plots, weighted histograms, and normal quantile plots, as well as by rank correlation tests (Kendall's tau and Spearman's rho) between the effect size and the study size.

Results

The 26 studies^{2,4-6,8,43,54-58,60-66,68-73,77,78} reported on 390 patients with ENB. Overall survival at 5 years could be extracted from 25 studies; the mean was 45% (SD 22), with extremes of 86%⁵⁸ and zero.⁵⁷ Disease-free survival at 2 years was found in 17 studies,^{2,43,54-58,60,62,65,66,68-71,73,78} that at 3 years in 20

reports^{4,6,8,43,54-58,60,62,65,66,68-73,78} and that at 5 years in 24 publications.^{2,4,6,8,43,54-58,60-66,68-73,78} The mean values were 52% (SD 21), 45% (SD 23), and 41% (SD 21), respectively. A few studies^{2,58,62,64,65} reported 10-year survival data, with an average of 52% (SD 27).

In five studies,^{61,62,70,77,78} ENB were histopathologically graded according to Hyams *et al.*¹⁴ The average distribution was 14% grade I, 48% grade II, 21% grade III, and 17% grade IV. Mean survival was 56% (SD 20) in patients with ENB of Hyams' grades I or II and 25% (SD 20) in those with tumours of grades III or IV. This difference was significant (odds ratio 6.18 [95% CI 1.30-29.3]).

Even if Kadish and colleagues' classification was not used as the principal staging system, data according to this system were available from 21 studies.^{2,6,54-58,61-66,68-73,77,78} The distribution was 12% stage A, 27% stage B, and 61% stage C. Mean survival for these three groups was 72% (SD 41), 59% (SD 44), and 47% (SD 16), respectively. Four studies^{2,4-6} used the Dulguerov and Calcaterra staging with the following distribution: 25% T1, 25% T2, 33% T3, and 17% T4. Mean survival was 81% (SD 17) for T1, 93% (SD 14) for T2, 59% (SD 33) for T3, and 48% (SD 41) for T4 patients.

On average 5% (SD 7) of patients presented with cervical lymph-node metastases. In the studies with survival data according to the N stage,^{2,8,60,61,64,69,78} only 29% of node-positive patients were treated successfully, compared with 64% of N0 patients, a significant difference (odds ratio 5.1 [95% CI 1.6-17.0]).

Information on the treatment modalities used were available in all the studies. For each treatment modality, the number of patients, the distribution in terms of frequency, and survival are shown in Table 3. The combination of surgery and radiotherapy was the most frequently used treatment (44%); it was associated with the best average survival results (65%) and therefore statistical analysis assessed differences between this combination and other treatment modalities. The only significant difference was for radiotherapy as sole treatment (odds ratio for death 2.5 [95% CI 1.0-6.0]).

Local recurrence was found in 29% (SD 16) of patients on average, with successful salvage in a third of cases. Regional recurrence occurred in 16% (SD 15) of patients with successful salvage in 27%. Distant metastases were found in 17% (SD 14) of patients. None of the statistical comparisons evaluated was associated with significant heterogeneity or publication bias.

Discussion and review

ENB remains a rare disease. Skolnik and colleagues were able to find only about 100 reported cases in the world

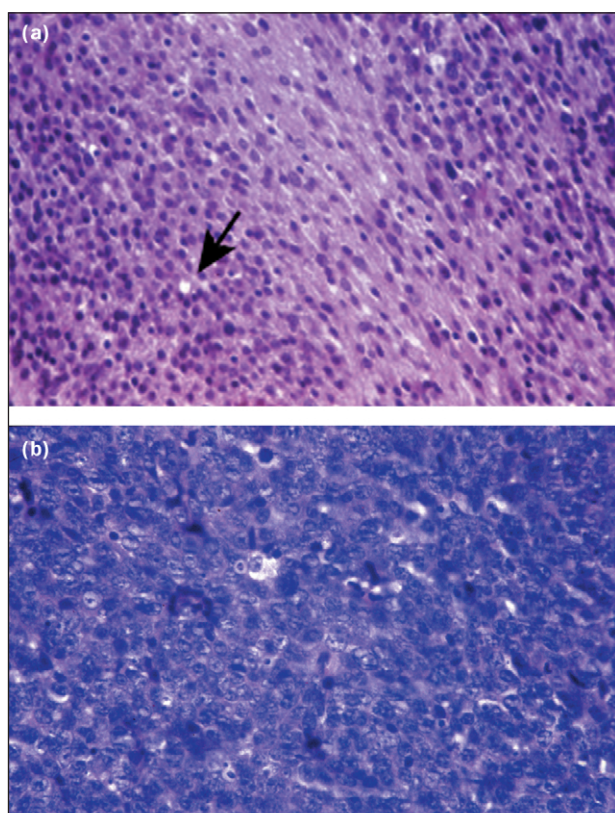


Figure 2. Histology of a low-grade (a) and high-grade (b) ENB. (a) low-grade Hyams stage II; preserved lobular architecture can be seen at lower magnification. The neoplastic cells have prominent nuclei, and the cell borders are difficult to see. Some nuclear pleiomorphism is present. Few mitotic figures can be seen. Arrow indicates a pseudorosette (Homer Wright rosette). (b) high-grade Hyams IV; the lobular architecture is absent. The neoplastic cells appear to consist essentially of prominent nuclei, which are hyperchromatic and anaplastic. Many mitotic figures can be seen. Both slides are stained with haematoxylin and eosin; magnification x400.

Courtesy of I Quinodoz-Szalay, Department of Pathology, Geneva Medical School

Table 3. Distribution of patients and survival by treatment modality

Modality	No. of patients	Frequency (%)	Survival (%)	OR	CI
Surgery alone	87	20 ± 22	48 ± 40	1.9	0.7 to 4.9
Surgery + radiation	169	44 ± 20	65 ± 25	1	
Radiation only	49	13 ± 19	37 ± 33	2.5	1.02 to 6.0
Surgery + radiation + chemotherapy	48	13 ± 16	47 ± 37	2.1	0.91 to 4.8
Radiation + chemotherapy	26	7 ± 16	51 ± 45	3.4	0.68 to 16.5
Surgery + chemotherapy	1	0 ± 1	0		
Chemotherapy	6	2 ± 4	40 ± 55		

OR, odds ratio; CI, confidence interval

literature up to 1966.⁷⁹ More recently, in an extensive review of published studies,³⁶ Broich and colleagues found about 1000 new cases reported. The majority of these (80%) have been reported during the past 20 years, almost certainly owing to better recognition of this disease entity by pathologists, although the possibility of a rising incidence cannot be entirely ruled out.

Origin

The exact cell of origin of ENB is controversial. Proposed sources include Jacobson's vomeronasal organ, the sphenopalatine ganglion, the ectodermal olfactory placode, Loci's ganglion, autonomic ganglia in the nasal mucosa, and the olfactory epithelium.³⁶ Although a neuronal or neural crest origin is supported by the presence of neurofilaments in ENB,¹¹ until recently,³³ little evidence linked ENB directly to the olfactory epithelium.

The olfactory neuroepithelium is a unique neurosensory organ, because olfactory neurons are continuously replaced throughout adult life.^{81,82} Three types of cells are classically recognised in the olfactory epithelium: the basal cells, located against the basement membrane; the olfactory neurosensory cells; and the sustentacular supporting cells, the processes of which extend onto the luminal surface. The spherical basal cells constitute a stem-cell compartment, which confers to this tissue its peculiar ability to regenerate not only physiologically but also when damaged by trauma or environmental insults.^{17,19} The basal cells express¹⁵ neural cell adhesion molecule (NCAM)⁸⁷ and the mammalian homologue of *Drosophila* achaete-scute (*MASH*) gene.⁸⁸ These progenitor cells differentiate into olfactory neurosensory cells, which show progressive maturation from the basal membrane to the epithelial surface.^{19,24} Each layer can be characterised by olfactory-specific and neuron-specific markers. Immature olfactory cells express^{17,19} GAP43, a 24 kDa membrane-associated protein kinase C involved in turnover of polyphosphoinositide.⁸⁶ As these cells mature, they grow axons to the olfactory bulb and migrate towards the surface; they express olfactory marker protein⁸⁰ and NCAM, but not GAP43.^{17,19,24}

In the mid 1990s,³³ ENB tumours were found to express HASH, the human homologue of the *MASH* gene, but stained negative for olfactory marker protein. So far, HASH has only been shown in medullary thyroid carcinoma and certain small-cell lung carcinomas.²¹ Further indirect evidence that ENB originates from olfactory stem cells comes from transgenic mice, in which the SV40T oncogene was inserted under control of the olfactory marker protein

gene promoter region;³² these mice did not develop ENB but adrenal and sympathetic ganglia neuroblastoma. Therefore, the currently available evidence links ENB with the basal progenitor cells of the olfactory epithelium.

Inclusion of ENB within the Ewing's sarcoma family of tumours³⁵ or the primitive neuroectodermal tumours (PNET)³⁴ has been proposed,³⁰ because of the identification in some cases of translocation t(11:22), which is regarded as specific for Ewing's sarcoma.⁸⁹ Studies with fluorescence *in situ* hybridisation^{39,40} and RT-PCR^{31,40} have not confirmed this translocation in ENB. ENB should therefore be seen as a distinct entity from PNET and the Ewing's sarcoma family of tumours.

No clear aetiological agent or exposure has been documented in human beings. However, ENB can be consistently induced by nitrosamine compounds in rodents.^{9,18,38} In cats with spontaneous ENB or transgenic mice developing ENB,²⁷ type C retroviral particles have been demonstrated and classified as, respectively, feline and murine leukaemia viruses. The role of retroviral sequences in human ENB remains unclear.

Histopathological diagnosis

The diagnosis of ENB by light microscopy is not difficult when the tumour is well differentiated and consists of

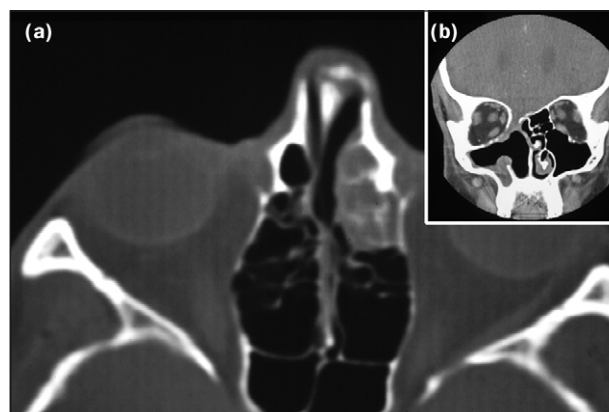


Figure 3. Preoperative and postoperative CT scan of a patient with ENB. (a) preoperative CT scan shows a non-specific opacification of the anterior ethmoid cells. In this horizontal imaging, the lesion appears of limited extension and does not invade the orbit. Note that the lesion is unilateral, a sign that suggests a malignant process. (b) Coronal CT scan after craniofacial resection. The entire ethmoid labyrinth on the involved side has been resected, including the ethmoid roof. The upper part of the adjacent septum has also been removed. In this case, the contralateral cribriform plate was preserved, allowing for residual olfactory function.

homogeneous small cells with uniform round to oval nuclei, with rosette or pseudorosette formation, and eosinophilic fibrillary intercellular background material. True rosettes (Flexner-Wintersteiner rosettes) consist of a ring of columnar cells circumscribing a central oval or round space, which appears clear on traditional pathological sections. Pseudorosettes (Homer Wright rosettes) are characterised by a looser arrangement and the presence of fibrillary material within the lumen. Fibrils have been shown by electron microscopy to represent cellular cytoplasmic processes.

When the tumour is undifferentiated, with anaplastic hyperchromatic small cells that show many mitotic figures and scant cytoplasm, differentiation from other small-cell nasal neoplasms by light microscopy becomes difficult.⁴⁹ The differential diagnosis includes malignant melanoma, embryonal rhabdomyosarcoma, malignant lymphoma, extramedullary plasmocytoma, and, in particular, sinonasal undifferentiated carcinoma and sinonasal neuroendocrine carcinoma. In these instances, immunohistochemical staining and electron microscopy become important in establishing the diagnosis. There is no specific immunocytological stain for ENB, but a typical staining profile can be very helpful. The tumour is positive for S-100 protein neurofilaments,⁴¹ but most cases are negative for cytokeratin, desmin, vimentin, actin, glial fibrillary acidic protein, UMB45, and common leucocytic antigen.^{13,34,41,43} ENB are also positive for chromogranin and synaptophysin. If special stains are not helpful, electron microscopy can be reliable in visualising uniform round nuclei, dense core neurosecretory granules with diameters of 125–350 nm, neuronal processes containing microtubules and neurofilaments, and rare synapses.^{12,48}

Distinction of ENB from melanoma is based on the lack of expression of UMB45 antigen and the pattern of S-100 staining. In melanoma, S-100 protein stains most cells strongly, resulting in a diffuse and strong immunopositivity, whereas in ENB the stain is scattered and peripheral. ENB can be distinguished from rhabdomyosarcoma by the lack of cross-striated cells (rhabdomyoblasts) and absence of desmin, vimentin, and actin expression. Differentiation of ENB from lymphoma is based on the lack of common leucocyte antigen immunostaining. Most sinonasal lymphomas are non-Hodgkin diffuse large-cell tumours, and many have a B-cell phenotype.

Sinonasal undifferentiated carcinoma was initially described by Frierson and colleagues in 1986.⁸⁵ Numerous mitotic figures, areas of necrosis, vascular invasion, and lack of glandular differentiation should aid the differential histopathological diagnosis. The immunohistochemical differentiation from ENB is based on a positive stain with cytokeratin antibodies. Recently, these tumours were found to be positive by *in situ* hybridisation for Epstein-Barr virus RNA.⁵³ This highly malignant lesion should be distinguished from ENB and needs aggressive treatment, which should probably include chemotherapy.²³

Another aggressive neoplasm that must be distinguished from ENB is neuroendocrine sinonasal carcinoma, as originally suggested by Silva and colleagues.¹⁰ Cytokeratin immunopositivity, especially in a punctate paranuclear

distribution is the main diagnostic marker for differentiation from ENB.⁵¹ Electron microscopy may be useful in demonstrating junctional complexes and tonofilaments.

Ewing's sarcoma seems difficult to distinguish from poorly differentiated ENB, and cases of Ewing's sarcoma within the paranasal sinuses, although rare, do occur.³⁹ With the use of monoclonal antibodies to myc-2 protein, a specific and sensitive marker of Ewing's sarcoma,⁹⁰ ENB can be differentiated from Ewing's sarcoma, because ENB tumours do not stain. This marker should therefore be included in the diagnostic tests for ENB.

In summary, the pathological distinction of poorly differentiated small neoplasms of the nasal cavity is difficult and is based on the results of antigen expression of a panel of antibodies by immunohistochemistry and, if necessary, electron microscopy. The reactions used should include S-100 protein, chromogranin, synaptophysin, or both, cytokeratin, desmin, actin, UMB45, common leucocyte antigen, and myc-2 protein. The demonstration by RT-PCR of *HASH* expression,³³ although still investigational, could become the diagnostic procedure of choice.

There is a lack of consensus on prognostic histological features. Support for the prognostic value of Hyams and co-workers' grading¹⁴ has been published.⁶¹ Hirose and colleagues⁴⁷ found that a high degree of S-100 immunopositivity and a low (<10%) Ki-67 labelling index (a marker for proliferation) were associated with better survival. There are conflicting data on the prognostic role of the *P53* tumour suppressor gene mutations.^{47,50}

Clinical data

There have been no precise epidemiological studies, but our unpublished data suggest that ENB represents about 5% of all nasal malignant tumours. ENB affects male and female patients with similar frequency and can be found in all age-groups.^{2,36}

There is no specific symptom for ENB, as for most nasal and paranasal malignant diseases.² The average delay between the appearance of the first symptom and the diagnosis is 6 months.² The commonest symptoms are a unilateral nasal obstruction (70%), followed by epistaxis (46%).^{2,8} However, these symptoms occur in common nasal diseases such as chronic rhinosinusitis or allergic polypoid sinus disease. The key to early diagnosis of ENB is early referral for an intranasal biopsy. We think that a unilateral nasal obstruction or recurrent epistaxis lasting more than 1–2 months should be thoroughly investigated by an otolaryngologist, although the cost-effectiveness of this approach has not been assessed.

Fine-cut CT scan (3 mm slice thickness) with direct coronal imaging is the initial radiological study of choice (Figure 3). ENB, which does not have a specific radiological appearance, is seen as a homogeneous soft-tissue mass in the nasal vault, with uniform and moderate contrast enhancement. CT images are essential for correct staging and should be carefully examined for erosion of lamina papyracea, cribriform plate, and fovea ethmoidalis.

Since nasal secretions, which tend to accumulate behind an obstruction, are difficult to differentiate from tumour

tissue by CT scan, MRI is often also necessary. ENB appears as hypointense to grey matter on T1-weighted images and isointense or hyperintense on T2-weighted images. MRI also demonstrates better an intraorbital or an intracerebral extension. When an intracerebral extension is found, marginal cysts have been seen radiologically in a few cases.²² Because details of bony erosion are better shown on CT images, both studies are required in the majority of patients.

Treatment

A combination of surgery and radiotherapy is the most frequently used approach, and the one achieving the highest cure rates. Despite the lack of support for single-modality treatment regimens,⁵⁴ a substantial number of patients are treated by surgery or radiotherapy alone. The difference in survival between the combined treatments and radiotherapy alone is significant (Table 3). Although surgery alone, a combination of radiotherapy and chemotherapy, and triple-modality treatment (surgery, radiotherapy, and chemotherapy) were associated with lower survival, with differences of 15–20%, the differences from the best combination were not significant, probably because of the limited number of patients.

Therefore the only conceivable indication for single-modality treatment would be a patient with a small tumour located well below the cribriform plate (T1 stage). Unlike most surgical specimens in the head and neck, specimens of the nasal cavity and paranasal sinuses, even *en bloc*, are difficult to orient and surgical margins difficult to analyse. Because one can rarely be completely confident of the adequacy of surgical margins, postoperative radiotherapy seems justified in almost all patients to keep the risk of local recurrence to a minimum.

Most institutions favour surgery as the first treatment modality, followed by radiotherapy.^{2,4,61,63} The theoretical advantage that preoperative radiotherapy will reduce an unresectable tumour to a resectable size has never been clearly demonstrated.⁶⁴

Standard radiotherapeutic techniques include external megavoltage beam and a three-field technique; an anterior port is combined with wedged lateral fields to provide a homogeneous dose distribution. The dose ranges from 5500 cGy to 6500 cGy and in most cases is above 6000 cGy. Possible roles of proton beam radiotherapy and stereotactic radiotherapy have been suggested,²⁵ but remain to be convincingly demonstrated.

Endocranial extension and close relation to the ethmoid roof and cribriform plate requires a combined transfacial and neurosurgical approach. A craniotomy is probably not justified for T1 tumours where there is clear radiological evidence of a normal cribriform plate and upper ethmoid cells. All other patients should be managed by a transfacial approach combined with a bifrontal craniotomy. In our experience, craniofacial resection results in much better local control than other surgical resections (100% versus 40%).² At the University of Virginia, the recurrence rate was 60% before the adoption of craniofacial resection compared with 40% afterwards.¹⁶

Craniofacial resection permits *en bloc* resection of the tumour with better assessment of any intracranial extension

and protection of the brain and optic nerves. The resection should include the entire ipsilateral cribriform plate and cristagalli. The olfactory bulb and overlying dura should be removed with the specimen. Preservation of the contralateral olfactory system, when possible, has resulted in preserved sense of smell in a few cases. Tumour that does not penetrate the orbit can be encompassed by resecting the lamina papyracea or even small segments of orbital periosteum.

Early reports on chemotherapy in ENB focused on patients with recurrent or metastatic disease.^{83,84} Neoadjuvant chemotherapy has been advocated^{5,64} for patients with advanced disease. At the University of Virginia, patients with Kadish stage C disease are first treated with two cycles of cyclophosphamide (300–650 mg/m²) and vincristine (1–2 mg) with or without doxorubicin, followed by 50 Gy of radiotherapy, which is then followed by craniofacial resection.⁶⁴ With this regimen the 5-year actuarial survival is 72% and that at 10 years 60%. Similar results have been obtained without chemotherapy,² and the extent to which chemotherapy contributed to the cure rates is unclear. Cisplatin-based regimens are preferred at the Mayo Clinic and at the Gustave-Roussy Institute.^{8,74} Although ENB responds to cisplatin, “chemotherapy for high-grade tumours in the advanced setting is not curative”.⁷⁴ At Harvard, the preferred regimen is cisplatin (33 mg/m² daily) and etoposide (100 mg/m² daily) for 3 days.⁵ This has been followed by proton radiation in nine patients, with excellent results. That study is probably the only one that shows convincingly the possibility of a non-surgical treatment of ENB, although the number of patients is small and the follow-up short.

Neck metastases are found at presentation in 5% of patients. Such patients should be treated by neck dissection or radiotherapy. Some see the frequency of delayed neck metastasis (16%) as an indication for elective neck dissection in all cases of ENB. Probably patients with advanced local disease should undergo radiological examination of the neck and may become candidates for regional treatment.²⁰

Prognosis

Treatment results before the availability and use of modern diagnostic techniques were probably flawed by the inclusion of cases of sinonasal undifferentiated carcinoma and sinonasal neuroendocrine carcinoma. Although the meta-analysis found a 5-year survival of 45%, most large studies quoted survival around 70%.^{2,6,7,64} The most frequent recurrence is local, with rates around 30%.^{7,8,64} Craniofacial resection followed by radiotherapy seems to result in fewer recurrences – around 10%.^{2,61} Salvage after local recurrence is possible in 33–50% of cases. Regional recurrence, when the primary site is under control, occurs in 15–20% of cases^{2,4,7,36,64} and is salvageable by further treatment in a third of cases. Distant metastases with locoregional control are not very common (8%⁶⁴) and carry a very poor prognosis.

The meta-analysis data confirm those of Koka and colleagues⁸ on the presence of palpable lymph nodes as one of the most important prognostic factors for survival (29% with nodes, 64% without). Hyams’ histopathological

grading should also be regarded as an important prognostic factor, as previously suggested. In addition, tumour shrinkage after chemotherapy has been correlated with survival.^{74,75}

We emphasise that recurrence can occur years after the completion of treatment, even more than 10 years later.^{2,7,64} Therefore, long-term follow-up is needed, although the exact frequency of visits and the necessity for radiological studies have not been precisely studied.

References

- Berger L, Luc R, Richard D. L'esthesioneuroepitheliome olfactif. *Bull Assoc Fr Etude Cancer* 1924; 13: 410–21.
- Dulguerov P, Calcaterra T. Esthesioneuroblastoma: the UCLA experience 1970–1990. *Laryngoscope* 1992; 102: 843–49.
- Kadish S, Goodman M, Wang CC. Olfactory neuroblastoma: a clinical analysis of 17 cases. *Cancer* 1976; 37: 1571–76.
- Austin JR, Cebrun H, Kershnik MM, et al. Olfactory neuroblastoma and neuroendocrine carcinoma of the anterior skull base: treatment results at the MD Anderson Cancer Center. *Skull Base Surg* 1996; 6: 1–8.
- Bhattacharyya N, Thornton AF, Joseph MP, et al. Successful treatment of esthesioneuroblastoma and neuroendocrine carcinoma with combined chemotherapy and proton radiation: results in 9 cases. *Arch Otolaryngol Head Neck Surg* 1997; 123: 34–40.
- Irish J, Dasgupta R, Freeman J, et al. Outcome and analysis of the surgical management of esthesioneuroblastoma. *J Otolaryngol* 1997; 26: 1–7.
- Morita A, Ebersold MJ, Olsen KD, et al. Esthesioneuroblastoma: prognosis and management. *Neurosurgery* 1993; 32: 706–14.
- Koka VN, Julieron M, Bourhis J, et al. Aesthesioneuroblastoma. *J Laryngol Otol* 1998; 112: 628–33.
- Herrold KM. Induction of olfactory neuroepithelial tumors in Syrian hamsters by diethylnitrosamine. *Cancer* 1964; 30: 1014–24.
- Silva EG, Butler JJ, Mackay B, Goepfert H. Neuroblastomas and neuroendocrine carcinomas of the nasal cavity: a proposed new classification. *Cancer* 1982; 50: 2388–405.
- Trojanowski JQ, Lee V, Pillsbury N, Lee S. Neuronal origin of human esthesioneuroblastoma demonstrated with anti-neurofilament monoclonal antibodies. *N Engl J Med* 1982; 307: 159–61.
- Taxy JB, Bharani NK, Mills SE, Frierson HF Jr, Gould VE. The spectrum of olfactory neural tumors: a light-microscopic, immunohistochemical and ultrastructural analysis. *Am J Surg Pathol* 1986; 10: 687–95.
- Axe S, Kuhajda FP. Esthesioneuroblastoma: intermediate filaments, neuroendocrine, and tissue-specific antigens. *Am J Clin Pathol* 1987; 88: 139–45.
- Hyams VJ. Olfactory neuroblastoma. In: Hyams VJ, Baksakis JG, Michaels L (Eds). *Tumors of the upper respiratory tract and ear*. Washington DC: Armed Forces Institute of Pathology, 1988: 240–48.
- Miragall F, Kadmon G, Husmann M, Schachner M. Expression of cell adhesion molecules in the olfactory system of the adult mouse: presence of the embryonic form of N-CAM. *Dev Biol* 1988; 129: 516–31.
- Spaulding CA, Kranyak MS, Constable WC, Stewart FM. Esthesioneuroblastoma: a comparison of two treatment eras. *Int J Radiat Oncol Biol Phys* 1988; 15: 581–90.
- Verhaagen J, Oestreicher AB, Gispén WH, Margolis FL. The expression of the growth associated protein B50/GAP43 in the olfactory system of neonatal and adult rats. *J Neurosci* 1989; 9: 683–91.
- Vollrath M, Altmannsberger M. Chemically induced esthesioneuroepithelioma: ultrastructural findings. *Ann Otol Rhinol Laryngol* 1989; 98: 256–66.
- Margolis FL, Verhaagen J, Biffo S, et al. Regulation of gene expression in the olfactory neuroepithelium: a neurogenetic matrix. *Prog Brain Res* 1991; 89: 97–122.
- Davis RE, Weissler MC. Esthesioneuroblastoma and neck metastasis. *Head Neck* 1992; 14: 477–82.
- Ball DW, Azzoli CG, Baylin SB, et al. Identification of a human achaete-scute homolog highly expressed in neuroendocrine tumors. *Proc Natl Acad Sci USA* 1993; 90: 5648–52.
- Som PM, Lidov M, Brandwein M, et al. Sinonasal esthesioneuroblastoma with intracranial extension: marginal tumor cysts as a diagnostic MR finding. *AJNR Am J Neuroradiol* 1994; 15: 1259–62.
- Righi PD, Francis F, Aron BS, et al. Sinonasal undifferentiated carcinoma: a 10-year experience. *Am J Otolaryngol* 1996; 17: 167–71.
- Nibu K, Li G, Zhang X, et al. Olfactory neuron-specific expression of NeuroD in mouse and human nasal mucosa. *Cell Tissue Res* 1999; 298: 405–14.
- Walch C, Stammberger H, Anderhuber W, et al. The minimally invasive approach to olfactory neuroblastoma: combined endoscopic and stereotactic treatment. *Laryngoscope* 2000; 110: 635–40.
- Yuen AP, Fung CF, Hung KN. Endoscopic cranionasal resection of anterior skull base tumor. *Am J Otolaryngol* 1997; 18: 431–33.
- Koike K, Jay G, Hartley JW, et al. Activation of retrovirus in transgenic mice: association with development of olfactory neuroblastoma. *J Virol* 1990; 64: 3988–91.
- Schrenzel MD, Higgins RJ, Hinrichs SH, et al. Type C retroviral expression in spontaneous feline olfactory neuroblastomas. *Acta Neuropathol* 1990; 80: 547–53.
- VanDevanter DR, George D, McNutt MA, Vogel A, Luthardt F. Trisomy 8 in primary esthesioneuroblastoma. *Cancer Genet Cytogenet* 1991; 57: 133–36.
- Stephenson CF, Bridge JA, Sandberg AA. Cytogenetic and pathologic aspects of Ewing's sarcoma and neuroectodermal tumors. *Hum Pathol* 1992; 23: 1270–77.
- Pellin A, Boix J, Blesa JR, Noguera R, Carda C, Llombart-Bosch A. EWS/FLI-1 rearrangement in small round cell sarcomas of bone and soft tissue detected by reverse transcriptase polymerase chain reaction amplification. *Eur J Cancer* 1994; 30A: 827–31.
- Servenius B, Vernachio J, Price J, et al. Metastasizing neuroblastomas in mice transgenic for simian virus 40 large T (SV40T) under the olfactory marker protein gene promoter. *Cancer Res* 1994; 54: 5198–205.
- Carney ME, O'Reilly RC, Sholevar B, et al. Expression of the human Achaetescute 1 gene in olfactory neuroblastoma (esthesioneuroblastoma). *J Neurooncol* 1995; 26: 35–43.
- Nelson RS, Perlman EJ, Askin FB. Is esthesioneuroblastoma a peripheral neuroectodermal tumor? *Hum Pathol* 1995; 26: 639–41.
- Sorensen PH, Wu JK, Berean KW, et al. Olfactory neuroblastoma is a peripheral primitive neuroectodermal tumor related to Ewing sarcoma. *Proc Natl Acad Sci USA* 1996; 93: 1038–43.
- Broich G, Pagliari A, Ottaviani F. Esthesioneuroblastoma: a general review of the cases published since the discovery of the tumour in 1924. *Anticancer Res* 1997; 17: 2683–706.
- Argani P, Perez-Ordóñez B, Xiao H, et al. Olfactory neuroblastoma is not related to the Ewing family of tumors: absence of EWS/FLI1 gene fusion and MIC2 expression. *Am J Surg Pathol* 1998; 22: 391–98.
- Ivankovic S, Seibel J, Komitowski D, et al. Caffeine-derived N-nitroso compounds: V, carcinogenicity of mononitrosocaffeidine and dinitrosocaffeidine in bd-ix rats. *Carcinogenesis* 1998; 19: 933–37.
- Kumar S, Perlman E, Pack S, et al. Absence of EWS/FLI1 fusion in olfactory neuroblastomas indicates these tumors do not belong to the Ewing's sarcoma family. *Hum Pathol* 1999; 30: 1356–60.
- Mezzelani A, Tornielli S, Minoletti F, et al. Esthesioneuroblastoma is not a member of the primitive peripheral neuroectodermal tumour-Ewing's group. *Br J Cancer* 1999; 81: 586–91.
- Frierson HF Jr, Ross GW, Mills SE, Frankfurter A. Olfactory neuroblastoma: additional immunohistochemical characterization. *Am J Clin Pathol* 1990; 94: 547–53.
- Kleinclaus I, Floquet J, Champigneulle J, et al. Les esthésioneuromes (esthésioneuromes) olfactifs: étude anatomo-pathologique 6 propos de 7 observations. *Ann Pathol* 1993; 13: 241–46.
- Lund VJ, Milroy C. Olfactory neuroblastoma: clinical and pathological aspects. *Rhinology* 1993; 31: 1–6.
- Barnes L, Kapadia SB. The biology and pathology of selected skull base tumors. *J Neurooncol* 1994; 20: 213–40.
- Paes de Lima A, Bellotti MS, Elsner B, et al. Esthesioneuroblastomas: estudio clínico-patológico, inmunohistoquímico y ploidia nuclear. *Medicina (B Aires)* 1994; 54: 415–22.
- Gaudin PB, Rosai J. Florid vascular proliferation associated with neural and neuroendocrine neoplasms: a diagnostic clue and potential pitfall. *Am J Surg Pathol* 1995; 19: 642–52.
- Hirose T, Scheithauer BW, Lopes MB, et al. Olfactory neuroblastoma: an immunohistochemical, ultrastructural, and flow cytometric study. *Cancer* 1995; 76: 4–19.
- Min KW. Usefulness of electron microscopy in the diagnosis of

- "small" round cell tumors of the sinonasal region. *Ultrastruct Pathol* 1995; 19: 347–63.
- 49 Devaney K, Wenig BM, Abbondanzo SL. Olfactory neuroblastoma and other round cell lesions of the sinonasal region. *Mod Pathol* 1996; 9: 658–63.
 - 50 Papadaki H, Kounelis S, Kapadia SB, *et al.* Relationship of p53 gene alterations with tumor progression and recurrence in olfactory neuroblastoma. *Am J Surg Pathol* 1996; 20: 715–21.
 - 51 Perez-Ordóñez B, Caruana SM, Huvo AG, Shah JP. Small cell neuroendocrine carcinoma of the nasal cavity and paranasal sinuses. *Hum Pathol* 1998; 29: 826–32.
 - 52 Houston GD, Gillies E. Sinonasal undifferentiated carcinoma: a distinctive clinicopathologic entity. *Adv Anat Pathol* 1999; 6: 317–23.
 - 53 Shinokuma A, Hirakawa N, Tamiya S, *et al.* Evaluation of Epstein-Barr virus infection in sinonasal small round cell tumors. *J Cancer Res Clin Oncol* 2000; 126: 12–18.
 - 54 Biller HF, Lawson W, Sachdev VP, Som P. Esthesioneuroblastoma: surgical treatment without radiation. *Laryngoscope* 1990; 100: 1199–201.
 - 55 Delank KW. Die Olfaktoriusneuroblastom – Tumorentität oder klinischer Formenkreis? *Laryngorhinootologie* 1990; 69: 426–32.
 - 56 Meneses MS, Thurel C, Mikol J, *et al.* Esthesioneuroblastoma with intracranial extension. *Neurosurgery* 1990; 27: 813–19.
 - 57 Ahern VA, Poulsen MG. Olfactory neuroblastoma—management of a rare tumour at the Queensland Radium Institute and literature review. *Australas Radiol* 1991; 35: 366–69.
 - 58 Beitler JJ, Fass DE, Brenner HA, *et al.* Esthesioneuroblastoma: is there a role for elective neck treatment? *Head Neck* 1991; 13: 321–26.
 - 59 Roux FX, Brasnu D, Villavicencio R, *et al.* Les esthesioneuroblastomes: une chimiothérapie préopératoire peut-elle en améliorer le pronostic? *Neurochirurgie* 1991; 37: 248–52.
 - 60 Lemoine C, Serrano E, Calvet H, Delisle MB, Pessey JJ. Esthesioneuroblastomes olfactifs: a propos de 12 observations. *Rev Laryngol Otol Rhinol* 1992; 113: 18–59.
 - 61 Foote RL, Morita A, Ebersold MJ, *et al.* Esthesioneuroblastoma: the role of adjuvant radiation therapy. *Int J Radiat Oncol Biol Phys* 1993; 27: 835–42.
 - 62 Sakata K, Aoki Y, Karasawa K, *et al.* Esthesioneuroblastoma: a report of seven cases. *Acta Oncol* 1993; 32: 399–402.
 - 63 Zappia JJ, Carroll WR, Wolf GT, *et al.* Olfactory neuroblastoma: the results of modern treatment approaches at the University of Michigan. *Head Neck* 1993; 15: 190–96.
 - 64 Eden BV, Debo RF, Larner JM, *et al.* Esthesioneuroblastoma: long-term outcome and patterns of failure—the University of Virginia experience. *Cancer* 1994; 73: 2556–62.
 - 65 Guedea F, Van Limbergen E, Van den Bogaert W. High dose level radiation therapy for local tumour control in esthesioneuroblastoma. *Eur J Cancer* 1994; 12: 1757–60.
 - 66 Kempf HG, Becker G, Weber BP, Ruck P. Diagnostik und Therapie des Olfaktoriusneuroblastoms. *HNO* 1994; 42: 422–28.
 - 67 Levine PA, Debo RF, Meredith SD, *et al.* Craniofacial resection at the University of Virginia (1976–1992): survival analysis. *Head Neck* 1994; 16: 574–77.
 - 68 Stmad V, Grabenbauer GG, Dunst J, Sauer R. Radiotherapy of esthesioneuroblastoma. *Strahlenther Onkol* 1994; 170: 79–84.
 - 69 Tandon DA, Bahadur S, Mohanti BK, Rath GK. Olfactory neuroblastoma: results of combined therapy. *Indian J Cancer* 1994; 31: 124–29.
 - 70 Tatagiba M, Samil M, Dankoweit-Timpe E, *et al.* Esthesioneuroblastomas with intracranial extension: proliferative potential and management. *Arquivos De Neuro-Psiquiatria* 1995; 53: 577–86.
 - 71 Jekunen AP, Kairemo KJ, Lehtonen HP, Kajanti MJ. Treatment of olfactory neuroblastoma: a report of 11 cases. *Am J Clin Oncol* 1996; 19: 375–78.
 - 72 Slevin NJ, Irwin CJ, Banerjee SS, Gupta NK, Farrington WT. Olfactory neural tumours—the role of external beam radiotherapy. *J Laryngol Otol* 1996; 110: 1012–16.
 - 73 Martinez Subias J, Dominguez Ugidos LJ, Urpugui Garcia A, *et al.* Olfactory esthesioneuroblastoma: review of seven cases. *Acta Otorrinolaringol Esp* 1998; 49: 293–96.
 - 74 McElroy EA Jr, Buckner JC, Lewis JE. Chemotherapy for advanced esthesioneuroblastoma: the Mayo Clinic experience. *Neurosurgery* 1998; 42: 1023–27.
 - 75 Polin RS, Sheehan JP, Chenelle AG, *et al.* The role of preoperative adjuvant treatment in the management of esthesioneuroblastoma: the University of Virginia experience. *Neurosurgery* 1998; 42: 1029–37.
 - 76 Levine PA, Gallagher R, Cantrell RW. Esthesioneuroblastoma: reflections of a 21-year experience. *Laryngoscope* 1999; 109: 1539–43.
 - 77 Eriksen JG, Bastholt L, Kroghdal AS, *et al.* Esthesioneuroblastoma—what is the optimal treatment? *Acta Oncol* 2000; 39: 231–35.
 - 78 Miyamoto RC, Gleich LL, Biddinger PW, Gluckman JL. Esthesioneuroblastoma and sinonasal undifferentiated carcinoma: impact of histological grading and clinical staging on survival and prognosis. *Laryngoscope* 2000; 110: 1262–65.
 - 79 Skolnik EM, Massari FS, Tenta LT. Olfactory neuroepithelioma: review of the world literature and presentation of two cases. *Arch Otolaryngol* 1966; 84: 644–53.
 - 80 Margolis FL. A brain protein unique to the olfactory bulb. *Proc Natl Acad Sci USA* 1972; 69: 1221–24.
 - 81 Graziadej PP. Cell dynamics in the olfactory mucosa. *Tissue Cell* 1973; 5: 113–31.
 - 82 Graziadei PP, Levine RR, Monti Graziadei GA. Plasticity of connections of the olfactory sensory neuron: regeneration into the forebrain following bulbectomy in the neonatal mouse. *Neuroscience* 1979; 4: 713–27.
 - 83 Wade PM, Smith RE, Johns ME. Response of esthesioneuroblastoma to chemotherapy: report of five cases and review of the literature. *Cancer* 1984; 53: 1036–41.
 - 84 Goldsweig HG, Sundaresan N. Chemotherapy of recurrent esthesioneuroblastoma: case report and review of the literature. *Am J Clin Oncol* 1990; 13: 139–43.
 - 85 Frierson HF, Mills SE, Fechner RE, *et al.* Sinonasal undifferentiated carcinoma: an aggressive neoplasm derived from schneiderian epithelium and distinct from olfactory neuroblastoma. *Am J Surg Pathol* 1986; 10: 771–79.
 - 86 Benowitz LI, Routtenberg A. A membrane phosphoprotein associated with neural development, axonal regeneration, phospholipid metabolism and synaptic plasticity. *Trends Neurosci* 1987; 10: 527–32.
 - 87 Cunningham BA, Hemperly JJ, Murray BA, *et al.* Neural cell adhesion molecule: structure, immunoglobulin-like domains, cell surface modulation, and alternative RNA splicing. *Science* 1987; 236: 799–806.
 - 88 Guillemot F, Lo LC, Johnson JE, *et al.* Mammalian achaete-scute homolog 1 is required for the early development of olfactory and autonomic neurons. *Cell* 1993; 75: 463–76.
 - 89 Delattre O, Zucman J, Melot T, *et al.* The Ewing family of tumors: a subgroup of small-round-cell tumors defined by specific chimeric transcripts. *N Engl J Med* 1994; 331: 294–99.
 - 90 Perlman EJ, Dickman PS, Askin FB, *et al.* Ewing's sarcoma—routine diagnostic utilization of MIC2 analysis: a Pediatric Oncology Group/Children's Cancer Group Intergroup Study. *Hum Pathol* 1994; 25: 304–07.
 - 91 Rosenberg MS, Adams DC, Gurevitch J. MetaWln: Statistical software for meta-analysis. Sunderland, Massachusetts: Version 2.0. Sinauer Associates, 2000.
 - 92 Hedges LV, Olkin I. *Statistical methods for meta-analysis*. New York: Academic Press, 1985.