



Article scientifique

Article

2020

Published version

Open Access

This is the published version of the publication, made available in accordance with the publisher's policy.

---

## Diagnosis of epilepsy after first seizure. Introducing the SWISS FIRST study

---

Jin, Baudouin Zongxin; De Stefano, Pia; Petroulia, Valentina; Rummel, Christian; Kiefer, Claus; Reyes, Mauricio; Schindler, Kaspar; van Mierlo, Pieter; Seeck, Margitta; Wiest, Roland

### How to cite

JIN, Baudouin Zongxin et al. Diagnosis of epilepsy after first seizure. Introducing the SWISS FIRST study. In: Clinical and Translational Neuroscience, 2020. doi: 10.1177/2514183X20939448

This publication URL: <https://archive-ouverte.unige.ch/unige:144693>

Publication DOI: [10.1177/2514183X20939448](https://doi.org/10.1177/2514183X20939448)

# Diagnosis of epilepsy after first seizure. Introducing the SWISS FIRST study

*Clinical & Translational Neuroscience*  
July-December 2020: 1–7  
© The Author(s) 2020  
Article reuse guidelines:  
sagepub.com/journals-permissions  
DOI: 10.1177/2514183X20939448  
journals.sagepub.com/home/ctn



Baudouin Zongxin Jin<sup>1,2</sup> , Pia De Stefano<sup>3</sup>, Valentina Petroulia<sup>1</sup>,  
Christian Rummel<sup>1</sup>, Claus Kiefer<sup>1</sup>, Mauricio Reyes<sup>4</sup>,  
Kaspar Schindler<sup>2</sup>, Pieter van Mierlo<sup>5</sup>, Margitta Seeck<sup>3</sup>,  
and Roland Wiest<sup>1</sup>

## Abstract

Diagnosis of epilepsy after a first unprovoked seizure is possible according to the guidelines by the International League Against Epilepsy, if the risk recurrence of a second unprovoked seizure is exceeding 60%. However, this cutoff constitutes only a proxy depending on the patients' history, magnetic resonance imaging (MRI), and electroencephalography (EEG) findings but nevertheless also from the treating neurologists' individual experience. In a Switzerland-wide observational study, we aim to recruit patients that were admitted to the emergency department with the referral diagnosis of a first and unprovoked seizure. We make use of optimized MRI protocols to identify potential structural epileptogenic lesions, introduce new imaging-based markers of epileptogenicity, and use most recent postprocessing methods as automatic morphometry, spike map analysis, and functional connectivity. With these diagnostic tools, we aim to segregate patients that present with epileptic seizures versus mimics and non-epileptic seizures and stratify for every finding in MRI and EEG its predictive value for a second unprovoked seizure. These findings shall support neurologists to calculate and not only estimate the seizure recurrence rate in future.

## Keywords

Epilepsy, neuroimaging, automatic morphometry, functional connectivity, spike maps

## Introduction

Epilepsy affects around 0.7% of the population, that is, 60,000 patients in Switzerland (8 Mio. citizens) and each year 4000 patients add to this number.<sup>1</sup> Isolated acute symptomatic seizures (e.g. due to alcohol withdrawal) or syncope are much more frequent, that is, around 10% of the population. In any case, over 90% of the patients are referred to an emergency department (ED), where the assessment of a first seizure constitutes a challenging task. The first seizure can be the first of many others or remain the only one in the patient's lifespan. Differential diagnosis encompasses psychogenic events, transient ischemic attacks, migraine, metabolic, vegetative, and cardiac events.<sup>2,3</sup> Moreover, segregating acute symptomatic and unprovoked seizures remains difficult, since patient's history can suggest provoked seizures even if there is no causal relationship and vice versa.

Currently, there are no reliable biomarkers allowing a correct classification of a first event as onset of epilepsy or

<sup>1</sup>Support Center for Advanced Neuroimaging, Inselspital, University of Bern, Bern, Switzerland

<sup>2</sup>Sleep-Wake-Epilepsy Center and Center for Experimental Neurology, Department of Neurology, Inselspital, University Hospital, University of Bern, Bern, Switzerland

<sup>3</sup>Electroencephalography and Epilepsy Unit, Department of Neurology, University Hospitals of Geneva, Geneva, Switzerland

<sup>4</sup>ARTORG Center for Biomedical Engineering, University of Bern/Inselspital, Bern, Switzerland

<sup>5</sup>Department of Electronics and Information Systems, Ghent University, Ghent, Belgium

## Corresponding author:

Baudouin Zongxin Jin, Support Center for Advanced Neuroimaging, Inselspital, Bern, Switzerland; Sleep-Wake-Epilepsy Center and Center for Experimental Neurology, Department of Neurology, Inselspital, University Hospital, University of Bern, Bern, Switzerland.  
Email: baudouinzongxin.jin@insel.ch



as a non-epileptic event. In fact, while clinical history, electroencephalography (EEG), and neuroimaging are fundamental to achieve a correct diagnosis, not more than 50% are diagnosed appropriately.<sup>4</sup>

EEG is routinely interpreted by visual expert reading for the presence of epileptic discharges (describes transients distinguishable from background activity with a characteristic morphology typically, but neither exclusively nor invariably, found in interictal EEGs of people with epilepsy.<sup>5</sup>) If present, an underlying epileptic disorder is very likely, which indicates a high positive predictive value. However, the specificity is very low, that is, absence of spikes does not indicate absence of epilepsy. Thus, alternative tools to determine or monitor epilepsy are warranted. The EEG can be described by physiological or pathological microstates (so-called spike maps), even in absence of visible spikes,<sup>6</sup> as well as by functional brain connectivity derived from resting-state EEG without visible spikes, altered in patients with focal epilepsy.<sup>7</sup>

Routine magnetic resonance imaging (MRI) has a high sensitivity to identify structural epileptogenic lesions but not epileptogenicity.<sup>8</sup> Besides, MRI eventually detects lesions whose entity remains unclear or who are erroneously interpreted as possibly epileptogenic.<sup>9</sup> Modified and tailored epilepsy imaging protocols enable neuroradiologists to detect epileptogenic lesions more reliably.<sup>10</sup> Imaging postprocessing is capable to identify visually obscured morphometric abnormalities in patients with known disease (mostly temporal lobe epilepsy (TLE)).<sup>11,12</sup> Experimental methods targeted to measure direct effects of electric currents on the magnetic field in the resting brain have been reported to underline the known diagnosis of epilepsy and correlated with the outcome after epilepsy surgery.<sup>13</sup> However, none of these studies investigated, whether there is a diagnostic yield after a first seizure, if diagnosis of epilepsy is not established. In a previous review focusing on peri-ictal changes in MRI, 96 publications were compared and summarized.

Perfusion and diffusion alterations were detected and reproduced in various anatomical regions, but the patient cohort was rather small for every finding, with none of them exceeding 69 patients.<sup>8</sup>

Since all of the methods mentioned above showed diagnostic significance in patients with chronic epilepsy, it is only reasonable to examine whether these methods can be an aid at the ED after a first seizure to diagnose and classify epilepsy. The guidelines<sup>14</sup> propose to diagnose epilepsy even after only one seizure if risk recurrence exceeds 60%.<sup>15</sup> Risk stratification still relies on clinical experience, but there is no biomarker available for risk calculation.<sup>16</sup> With our multicenter Swiss study, we aim at identifying biomarkers in the routine EEG and MRI with newly developed algorithms, thus facilitating the clinical decision for or against a particular treatment or further examinations.

For optimal treatment, safety, and life quality of patients, diagnostic certainty is required, as well as

diagnostic tools that reliably identify epilepsy and potential underlying lesions.

In the SWISS FIRST trial, we will examine patients with MRI and EEG in the context of clinical data after a first probably unprovoked probable seizure, which could be the first sign of an epileptic disorder. Diagnosis of epilepsy after a first seizure remains challenging, because there are no biomarkers available that reliably support diagnosis of epilepsy versus any other non-epileptic event or acute symptomatic seizure.

We will implement new strategies of EEG and MRI acquisition and analysis at the first event. A follow-up of 2 years will determine if the forecast was correct. We will further stratify whether categorization of the underlying syndrome (epileptic, cardiac, psychogenic, and other) is possible after the first event. To our knowledge, this will be the first large prospective and observational study regarding first seizures and early-onset epilepsy taking into account high-quality standard EEG and MRI but also advanced algorithms.

## Study concept

Patients will be recruited starting November 2019 to November 2021 at the Inselspital Bern, Hôpitaux Universitaires de Genève, Universitätsspital Zürich, Universitäts-spital Basel, Kantonsspital St.Gallen, Kantonsspital Aarau, and Ospedale Civico Lugano. Healthy controls will be recruited at the Inselspital Bern and in the Hôpitaux Universitaires de Genève. Patients and healthy controls sign-informed consent that allows usage of clinical information, images, and follow-up consultations. All sites received approval by their respective cantonal ethics committee in accordance with the declaration of Helsinki. Clinical decision-making in diagnostics and therapy will be done independently from the study. Central quantitative data evaluation will be performed on pseudonymized data only.

## Population

Adult patients, who present themselves for the first time at the ED because of a possible epileptic seizure where an unprovoked epileptic seizure (idiopathic/unclear etiology, hereditary, remote symptomatic) has to be ruled out or ensured, who sign-informed consent, will be included in this study. In our study, population, therefore, also patients with unclear events will be included, where in further visits, a cardiac or psychogenic trigger for the event can possibly be found. EEG and MRI will be executed if possible the same day but no later than 7 days after the possible seizure. Exclusion criteria are as follows:

- history of unprovoked seizure/epilepsy,
- history of provoked seizure within the previous 4 weeks,
- preexisting anticonvulsive medication,

- inability to perform MRI or EEG, and
- present alcohol dependency (ICD F10.1) and drug abuse.

If EEG suggests the presence of generalized epilepsy, which does not require MRI, it will be offered through the grant, to determine if our tools are capable to differentiate between focal and generalized epilepsy conditions.

Based on previous epidemiologic data, we expect to enroll 500–600 patients in total within 24 months.

Matched controls will be selected by the same criteria, adding only that they shall not have an underlying neurologic or psychiatric disease.

All data will be pseudoanonymized before postprocessing.

### *Follow-ups*

There will be no additional visits outside the clinical routine. It is the neurologist's decision, with which frequency patients have to be followed up, whether relapses occurred and whether antiepileptic treatment should be initiated or not. We will gather clinical information from the reports of every visit and register if recurrences occurred and if changes regarding treatment were made. When clinical information is not available after 2 years, we will contact the patient by telephone to enquire that information.

### *Spike maps and microstates*

EEGs, obtained as soon as possible after the first event, that is, within 24–72 h, will be evaluated in a first step conventionally and then quantitatively. We then will focus on the detailed analysis of microstates during resting EEG, analyze the resting states, and compare the results with the control group. Microstates are considered stable topographies on a subsecond temporal scale and have been used to describe the EEG in a number of pathologies.<sup>17,18</sup> These basic EEG microstates represent quasi-stable topographies, which can be described by their frequency of occurrence, duration, or also their syntax. Interestingly, the basic microstates are quite resistant to anesthesia or sleep, which makes them a particular interesting marker of abnormal brain activity.<sup>19</sup>

We will construct a “spike map” using publicly available software like Cartool (brainmapping.unige.ch/cartool). Next to visual identification of the interictal epileptiform discharges (IEDs), we will use software to detect them in the EEG and construct the spike topography.<sup>20</sup> For EEGs without IEDs, in a second step, we aim to develop a library of possible foci (corresponding to 28 or more cortex areas), for which possible pathological microstates are simulated. This requires the use of advanced head models to estimate the spike morphology at the scalp level from sources within cortical areas. The EEGs are then screened if one or more of these pathological microstates

are present and point to an epileptogenic underlying process.

### *Functional connectivity*

From the resting EEG, we will extract the whole-brain-directed functional connectome, first constructing a patient-specific head model, then parcelling the grey matter into 82 regions of interests (Figure 1). We will identify which anatomic structures show altered functional connectivity compared to healthy controls.

Directed functional connectivity (DFC) reveals the causal influence of one signal (coming from a distinct region) onto another signal/region within a dedicated network and among different networks. It determines directional relationships between activities of different brain regions and reflects short- and long-range interactions of complex dynamic subsystems that enable information flow through the human brain. DFC applied to brain sources, namely source space DFC, revealed, even in the absence of interictal spikes and seizures, significant connectivity differences in TLE compared to healthy controls based on source space DFC during resting state recorded with high-density EEG,<sup>7</sup> suggesting that DFC measures could serve as a qualitative parameter to determine if the person suffers from underlying epilepsy or not and, therefore, if the first seizure needs to be treated or not.

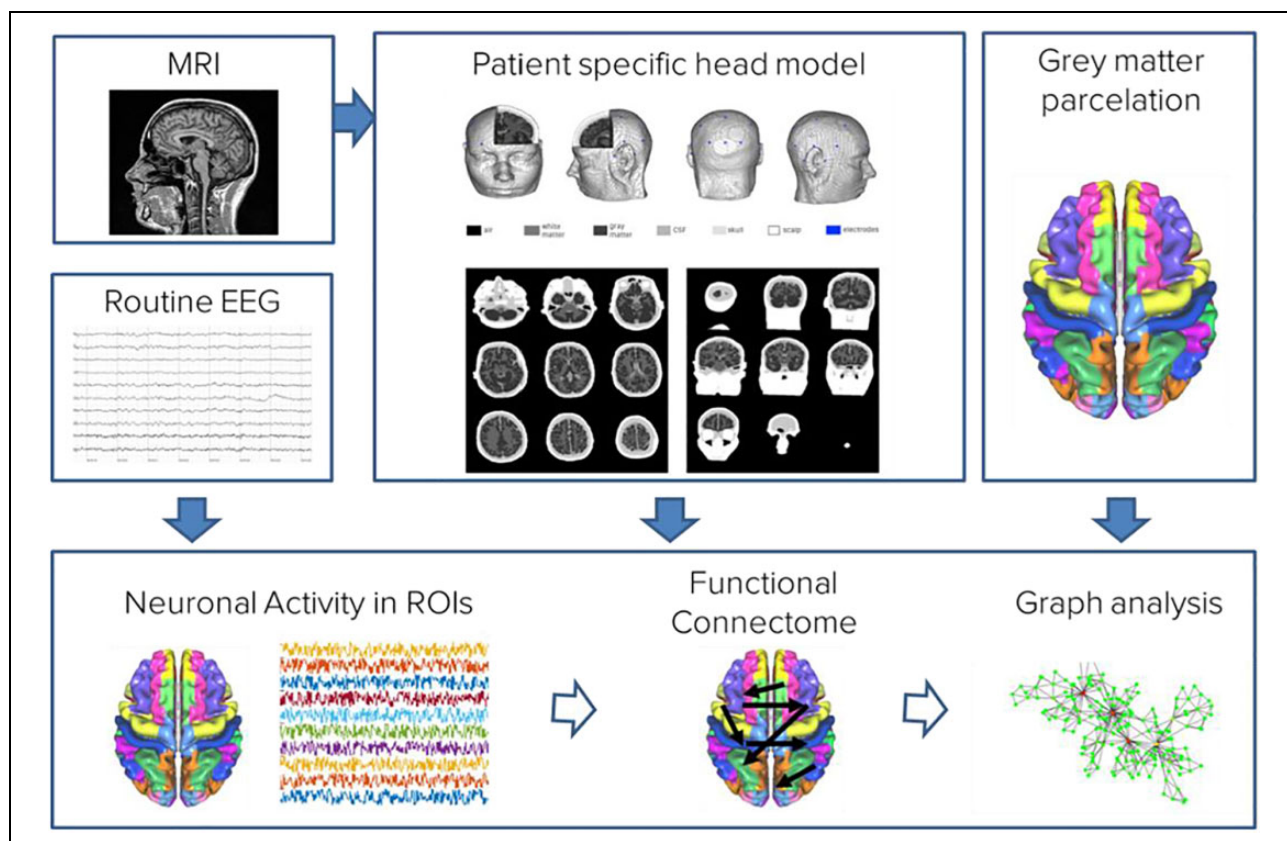
### *Advanced neuroimaging*

All images will be screened for structural epileptogenic lesion and incidental findings using a dedicated epilepsy protocol following the guidelines of the International League Against Epilepsy. Diffusion and perfusion MRI is performed to identify potentially transient peri-ictal abnormalities and their lateralizing value. With the adaptations in MRI first seizure protocols, we intend to detect possibly all epileptogenic lesions.

Centralized reading of all data will be performed at the Support Center of Advanced Neuroimaging, Institute of Diagnostic and Interventional Neuroradiology at the University of Bern. The raters will be preinformed by patient history, clinical, and EEG findings and will adhere to a predefined definition of epileptogenic versus non-epileptogenic lesions by entity.<sup>21</sup>

### *Automatic morphometry: Large-scale structural alterations and networks*

Cortical and subcortical brain areas will be automatically parcellated using the T1 image and the freely available software FreeSurfer. It distinguishes grey matter, white matter, blood vessels, ventricles, and skull and measures volumes and other morphometric parameters such as cortical thickness, surface area, or curvature. These will be compared to their respective regional normative values,



**Figure 1.** Pipeline to obtain EEG source connectivity. The EEG signals in sensor space are source imaged using a head model constructed based on a template- or patient-specific MRI. In the brain ROIs (82 ROIs), the neuronal activity is estimated over time and fed in the connectivity analysis to obtain the connectivity pattern in source space. EEG: electroencephalography; MRI: magnetic resonance imaging; ROIs: regions of interest.

correcting for age, sex, magnetic resonance (MR) scanner and MR sequence. A similar procedure was already performed in the ENIGMA study for epilepsy, which showed patterns of atrophy for every subtype of epilepsy.<sup>11</sup> Now we will investigate, whether these patterns of atrophy are already detectable earlier in the progress of disease, namely after the first seizure and if this pattern already allows a classification shortly after manifestation.

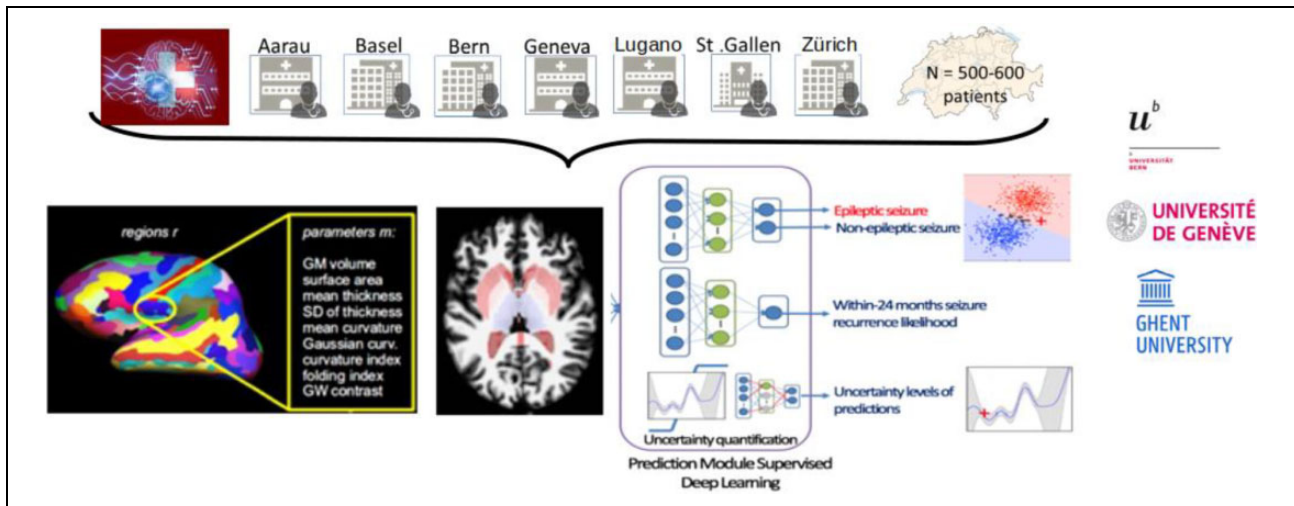
### **Neuronal current imaging/phase-cycled stimulus-induced rotary saturation (NCI/pc-SIRS) in a population-wide cohort**

A newly developed MR sequence (spin locking effects) will be applied to investigate non-hemodynamic field effects related to epileptic activity.<sup>22</sup> A first technical report of effects on magnetic field perturbations in a small series of patients that underwent presurgical phase II workup reported a hemispheric concordance in seven of eight patients.<sup>13</sup> We will investigate, whether this new sequence generates reproducible effects in patients after a first seizure and if these findings can support the diagnosis of epilepsy after the first seizure.

### **Endpoints of the study: Seizure recurrence prediction and risk stratification**

Two years after the first seizure, patients will be followed up and relapse(s) of the event will be ascertained. Clinical evaluation will serve as the ground truth. Information from advanced neuroimaging, spike maps, functional connectivity, automatic morphometry, and spin-locking effects will flow into an artificial intelligence algorithm that shall dichotomize the possible seizures into epileptic or not. Further, it shall determine the probability of seizure recurrence (Figure 2). Retrospectively, we expect to evaluate whether there were hints already available after the first seizure that would have suggested higher seizure recurrence probability and rank their diagnostic significance.

While it is known that the amount of training data in supervised learning influences the performance of the models, determining the exact amount of samples required to train a classifier is very difficult.<sup>23,24</sup> In addition, the effect size for morphometric differences in patients after a first seizure is yet unknown. However, the ENIGMA study<sup>11</sup> has found the largest morphometric difference between patients with unselected chronic epilepsy and matched healthy controls in the thalami. Using Cohen's



**Figure 2.** Data collection of all seven sites after 2 years. Information and findings from advanced neuroimaging, functional connectivity, automatic morphometry, and NCI will flow into an artificial intelligence algorithm, developed at the ARTORG/Insel Data Science Center, the recurrence risk for every information and finding.

$d = -0.37$  of the right thalamus, a significance level of 0.05, and a statistical power of 0.80, we estimate to require at least  $N = 102$  patients and healthy controls to detect a difference in an unpaired two-sample  $t$ -test. To assess the primary endpoint, models learnt by deep learning networks need to be tested using a holdout data set of only  $\sim 20\%$  of the full data set. Considering this, the project requires to include at least 510 patients after a first seizure to detect a significant difference of  $\alpha < 0.05$  and a statistical power of  $>0.8$ .

## Discussion

Only with the correct diagnosis and risk stratification, optimal therapy and prevention can be initiated. Preventing further seizures is the aim of epilepsy therapy, which is essential for patient safety and which will minimize further admissions to the ED, lower morbidity, and mortality and reduce the costs for society. For optimal detection of epileptogenic lesions, it is necessary to acquire dedicated epilepsy protocols.<sup>10</sup> With advanced MRI, we expect further improvement. In the peri- and postictal period especially, perfusion asymmetries and diffusion restrictions if present can contribute to the diagnosis of epileptic seizures.<sup>8,25</sup>

Automatic morphometry can contribute to classification of epilepsy syndromes.<sup>11</sup> Yet, it remains unclear when the process of atrophy starts and how it differs from normal aging.<sup>26</sup> Our aim is to investigate to which extent atrophy has already progressed at the time point of the first seizure and whether categorization of epilepsy syndromes is possible by identification of distinct atrophy patterns.

In previous studies, spike maps supported diagnosis of epilepsy even in the absence of interictal discharges.<sup>6,27</sup> In patients with a confirmed history of epilepsy, it is known that their functional cerebral network differs from healthy

controls.<sup>7</sup> This has never been evaluated for patients, where etiology of seizures remained unclear. To our knowledge, our study is the first trial to assess, whether network alterations already allow diagnosis of epilepsy after the first seizure. Furthermore, we will investigate whether antiepileptic drugs affect functional connectivity and whether it is possible to evaluate if antiepileptic medication is effective.<sup>28</sup>

Currently, we have only little experience with detection of magnetic field oscillations by spin-locking MR techniques. There is evidence from a single study that assessed postsurgical outcome mainly in patients with TLE.<sup>13</sup> The method identified magnetic field perturbations that were present ahead of epilepsy surgery and absent after surgery in patients with favorable clinical outcome. Patients who suffered from ongoing epileptic seizures presented with detectable MR abnormalities after surgery.

SWISS FIRST aims to investigate if MR- and EEG-based image postprocessing may support the diagnosis of epilepsy already after the first seizure and adds additional information for classification, risk recurrence, and drug responsiveness.

There are numerous EEG and MRI trials that describe alterations in epileptic brains. But there is a lack of knowledge about detectable and early changes in an epileptic brain after first seizure.<sup>8,9</sup> Moreover, longitudinal observational studies for progress of epilepsy and its damage to the central nervous system are lacking.<sup>8</sup> The study aims to fill this gap in knowledge to classify epilepsy after a first seizure.

## Authors' note

BZJ and PDS, and MS and RW are co-shared first and last authors, respectively.





## Declaration of conflicting interests

The author(s) declared no potential conflicts of interest with respect to the research, authorship, and/or publication of this article.

## Funding

The author(s) disclosed receipt of the following financial support for the research, authorship, and/or publication of this article: This study is funded by the Sinergia program of the Swiss National Science Foundation in the period January 2019 to December 2022. Cooperation contracts will be prepared by Unictetra (Bern) and signed by all other participating centers.

## ORCID iDs

Baudouin Zongxin Jin  <https://orcid.org/0000-0002-1497-2615>  
Roland Wiest  <https://orcid.org/0000-0001-7030-2045>

## References

- Sander J. The epidemiology of epilepsy revisited. *Curr Opin Neurol*, <https://www.ncbi.nlm.nih.gov/pubmed/12644744> (2003, accessed 27 November 2019)
- Vilela P. Acute stroke differential diagnosis: stroke mimics. *Eur J Radiol* 2017; 96: 133–144.
- Bergfeldt L. Differential diagnosis of cardiogenic syncope and seizure disorders. *Heart* 2003; 89(3): 353–358.
- Krumholz A, Wiebe S, Barkley G, et al. Practice parameter: evaluating an apparent unprovoked first seizure in adults (an evidence-based review). *Neurology*, <https://n.neurology.org/content/69/21/1996.long> (1996, accessed 27 November 2019)
- Kane N, Acharya J, Beniczky S, et al. A revised glossary of terms most commonly used by clinical electroencephalographers and updated proposal for the report format of the EEG findings. Revision 2017. *Clin Neurophysiol Pract* 2017; 2: 170–185.
- Grouiller F, Thornton RC, Groening K, et al. With or without spikes: localization of focal epileptic activity by simultaneous electroencephalography and functional magnetic resonance imaging. *Brain J Neurol* 2011; 134(Pt 10): 2867–2886.
- Coito A, Genetti M, Pittau F, et al. Altered directed functional connectivity in temporal lobe epilepsy in the absence of interictal spikes: a high density EEG study. *Epilepsia* 2016; 57(3): 402–411.
- Williams JA, Bede P and Doherty CP. An exploration of the spectrum of peri-ictal MRI change; a comprehensive literature review. *Seizure* 2017; 50: 19–32.
- Crocker CE, Pohlmann-Eden B and Schmidt MH. Role of neuroimaging in first seizure diagnosis. *Seizure* 2017; 49: 74–78.
- Wellmer J, Quesada C, Rothe L, et al. Proposal for a magnetic resonance imaging protocol for the detection of epileptogenic lesions at early outpatient stages. *Wiley Online Libr.*, <https://onlinelibrary.wiley.com/doi/full/10.1111/epi.12375> (2013, accessed 21 November 2019).
- Whelan CD, Altmann A, Botia JA, et al. Structural brain abnormalities in the common epilepsies assessed in a world-wide ENIGMA study. *Brain J Neurol* 2018; 141(2): 391–408.
- Rummel C, Slavova N and Seiler A. Personalized structural image analysis in patients with temporal lobe epilepsy. *Sci Rep* 2017; 7(1): 10883.
- Kiefer C, Abela E, Schindler KA, et al. Focal epilepsy: MR imaging of nonhemodynamic field effects by using a phase-cycled stimulus-induced rotary saturation approach with spin-lock preparation. *Radiology* 2016; 280: 237–243.
- Fisher RS, Boas W van E, Blume W, et al. Epileptic seizures and epilepsy: definitions proposed by the international league against epilepsy (ILAE) and the international bureau for epilepsy (IBE). *Epilepsia* 2005; 46(4): 470–472.
- Fisher RS, Acevedo C and Bogacz A. ILAE official report: a practical clinical definition of epilepsy. *Sci Direct*, <https://www.ncbi.nlm.nih.gov/pubmed/24730690> (2014, accessed 26 November 2019)
- Rizvi S, Lady Ladino D, Hernandez-Ronquillo L, et al. Epidemiology of early stages of epilepsy: risk of seizure recurrence after a first seizure. *Sci Direct*, <https://www.ncbi.nlm.nih.gov/pubmed/28242175> (2017, accessed 26 November 2019).
- Rieger K, Diaz Hernandez L, Baenninger A, et al. 15 Years of microstate research in schizophrenia—where are we? A meta-analysis. *Front Psychiatry*, <https://www.frontiersin.org/articles/10.3389/fpsy.2016.00022/full> (2016, accessed 27 January 2020).
- Nishida K, Morishima Y, Yoshimura M, et al. EEG microstates associated with salience and frontoparietal networks in frontotemporal dementia, schizophrenia and Alzheimer's disease. *Clin Neurophysiol* 2013; 124(6): 1106–1114.
- Brodbeck V, Kuhn A, von Wegner F, et al. EEG microstates of wakefulness and NREM sleep. *NeuroImage* 2012; 62(3): 2129–2139.
- van Mierlo P, Vulliémot S, Seeck M, et al. Automated EEG analysis of long-term EEG to localize the epileptogenic zone in extra-temporal lobe epilepsy. *Sci Direct*, <https://www.sciencedirect.com/science/article/pii/S1388245718302955> (2017, accessed 27 November 2019).
- Hakami T, McIntosh A, Todaro M, et al. MRI-identified pathology in adults with new-onset seizures. *Neurology* 2013; 81(10): 920–927.
- Wiest R and Beisteiner R. Recent developments in imaging of epilepsy. *Curr Opin Neurol* 2019; 32(4): 530–538.
- Figuerola RL, Zeng-Treitler Q, Kandula S, et al. Predicting sample size required for classification performance. *BMC Med Inform Decis Mak* 2012; 12: 8.
- Hajian-Tilaki K. Sample size estimation in diagnostic test studies of biomedical informatics. *J Biomed Inform* 2014; 48: 193–204.

25. Kellner-Weldon F, El-Koussy M, Jung S, et al. Cerebellar hypoperfusion in migraine attack: incidence and significance. *Am J Neuroradiol* 2018; 39(3): 435–440.
26. Caciagli L, Bernasconi A, Wiebe S, et al. A meta-analysis on progressive atrophy in intractable temporal lobe epilepsy. *Neurology* 2017; 89(5): 506–516.
27. Verhoeven T, Coito A and Plomp G. Automated diagnosis of temporal lobe epilepsy in the absence of interictal spikes. *NeuroImage Clin* 2018; 17: 10–15.
28. Wang Z, Larivière S, Qiang Xu, et al. Community-informed connectomics of the thalamocortical system in generalized epilepsy. *Neurology* 2019; 93(11): e1112–e1122.