



Article scientifique

Article

2014

Published version

Open Access

This is the published version of the publication, made available in accordance with the publisher's policy.

Brain circuits implicated in psychogenic paralysis in conversion disorders and hypnosis

Vuilleumier, Patrik

How to cite

VUILLEUMIER, Patrik. Brain circuits implicated in psychogenic paralysis in conversion disorders and hypnosis. In: Clinical neurophysiology, 2014, vol. 44, n° 4, p. 323–327. doi: 10.1016/j.neucli.2014.01.003

This publication URL: <https://archive-ouverte.unige.ch/unige:40632>

Publication DOI: [10.1016/j.neucli.2014.01.003](https://doi.org/10.1016/j.neucli.2014.01.003)




Disponible en ligne sur

ScienceDirect
www.sciencedirect.com

Elsevier Masson France

EM|consulte
www.em-consulte.com/en



REVIEW/MISE AU POINT

Brain circuits implicated in psychogenic paralysis in conversion disorders and hypnosis

Circuits cérébraux des paralysies psychogènes liées aux troubles de conversion et à l'hypnose

P. Vuilleumier

Laboratory for Behavioral Neurology and Imaging of Cognition (LABNIC), Department of Neuroscience (NEUFO), University Medical Center (CMU), 1, rue Micheli du Crest, 1205 Geneva, Switzerland

Received 27 December 2013; accepted 12 January 2014

KEYWORDS

Conversion;
Hysteria;
Hypnosis;
Paralysis;
Brain;
Neuroimaging;
Affect;
Self;
Precuneus;
VMPFC

Summary Conversion disorders are defined as neurological symptoms arising without organic damage to the nervous system, presumably in relation to various emotional stress factors, but the exact neural substrates of these symptoms and the mechanisms responsible for their production remain poorly understood. In the past 15 years, novel insights have been gained with the advent of functional neuroimaging studies in patients suffering from conversion disorders in both motor and non-motor (e.g. somatosensory, visual) domains. Several studies have also compared brain activation patterns in conversion to those observed during hypnosis, where similar functional losses can be evoked by suggestion. The current review summarizes these recent results and the main neurobiological hypotheses proposed to account for conversion symptoms, in particular motor deficits. An emerging model points to an important role of ventromedial prefrontal cortex (VMPFC), precuneus, and perhaps other limbic structures (including amygdala), all frequently found to be hyperactivated in conversion disorders in parallel to impaired recruitment of primary motor and/or sensory pathways at the cortical or subcortical (basal ganglia) level. These findings are only partly shared with hypnosis, where increases in precuneus predominate, together with activation of attentional control systems, but without any activation of VMPFC. Both VMPFC and precuneus are key regions for access to internal representations about the self, integrating information from memory and imagery with affective relevance (in VMPFC) and sensory or agency representations (in precuneus). It is therefore postulated that conversion deficits might result from an alteration of conscious sensorimotor functions and self-awareness under the influence of affective and sensory representations generated in these regions, which might promote certain patterns of behaviors in response to self-relevant emotional states.

© 2014 Elsevier Masson SAS. All rights reserved.

E-mail address: patrik.vuilleumier@unige.ch

0987-7053/\$ - see front matter © 2014 Elsevier Masson SAS. All rights reserved.

<http://dx.doi.org/10.1016/j.neucli.2014.01.003>

Please cite this article in press as: Vuilleumier P. Brain circuits implicated in psychogenic paralysis in conversion disorders and hypnosis. *Neurophysiologie Clinique/Clinical Neurophysiology* (2014), <http://dx.doi.org/10.1016/j.neucli.2014.01.003>

MOTS CLÉS

Conversion ;
Hystérie ;
Hypnose ;
Paralysie ;
Cerveau ;
Neuroimagerie ;
Affect ;
Soi ;
Précuneus ;
CPFVM

Résumé Les troubles de conversion sont définis comme des symptômes neurologiques apparaissant sans lésion organique du système nerveux, habituellement en relation avec des situations de stress émotionnel, mais les substrats cérébraux exacts de ces symptômes et les mécanismes responsables de leur apparition sont encore mal compris. Au cours des 15 dernières années, de nouvelles données ont été accumulées grâce au développement de la neuroimagerie fonctionnelle chez des patients souffrant de troubles de conversion moteurs ou non moteurs (par exemple somatosensoriel, visuel). Plusieurs études ont également comparé l'activation cérébrale lors de conversion à celle observée lors de l'hypnose, où des déficits fonctionnels similaires peuvent être induits par suggestion. Cette revue résume ces données et les principales hypothèses neurobiologiques proposées pour expliquer la genèse des symptômes de conversion, en particulier des déficits moteurs. Un aspect émergent important concerne le rôle potentiel du cortex préfrontal ventromédian (CPFVM), du précuneus, et peut-être d'autres structures limbiques (notamment les amygdales), tous fréquemment suractivés lors de troubles de conversion et associés à une altération de l'activation des voies motrices ou sensorielles élémentaires au niveau cortical ou sous-cortical (notamment ganglions de la base). Ces effets ne sont que partiellement partagés avec l'hypnose, où l'activation du précuneus prédomine, accompagnée d'une activation des systèmes de contrôle de l'attention, mais sans activation du CPFVM. Le CPFVM et le précuneus constituent deux régions cruciales pour l'accès à des représentations internes du soi, intégrant des représentations en mémoire avec leur valeur affective (CPFVM) et des informations sensorielles ou d'agentivité (précuneus). Ces données suggèrent que les symptômes de conversion pourraient refléter une altération des fonctions sensorimotrices et la conscience de soi sous l'influence de représentations affectives et sensorielles générées dans ces régions, favorisant l'expression de certains comportements en réponse à des états émotionnels particuliers et pertinents pour le soi.

© 2014 Elsevier Masson SAS. Tous droits réservés.

Introduction

Conversion disorders have been known to physicians since ancient times and consist of neurological dysfunction that occurs in the absence of organic lesions within the nervous system, but is distinct from other major psychiatric symptoms such as psychosis or depression. Thus, patients may present with a paralysis of one or more limbs, tremor or involuntary movement, anesthesia, blindness, deafness, or various other deficits, without any organic disease despite careful investigation and often signs suggestive of a non-organic/non-physiologic disruption of function [6,92]. Importantly, these symptoms are not intentionally produced in order to deceive physicians or obtain some direct material gain, but rather appear to result from a genuine belief or subjective experience of the patients that he/she is suffering from a particular disorder. While these symptoms were long labeled as "hysteria", this term has been replaced by "conversion" in modern psychiatric classifications of the 20th century. This change in terminology was partly due to increasing recognition that such problems could affect men as well as women, particularly after war episodes [7], but also reflected the major influence of Sigmund Freud [30], who proposed that these symptoms result from a transformation of a psychological conflict into symbolic physical manifestations due to repression in the unconscious (see other articles in this issue). However, although this diagnostic term is unique in psychiatry by directly referring to a specific causative mechanism, the exact causes and mechanisms underlying such conversion [2] of the psyche into the body actually still remain unclear and speculative. Furthermore, in the latest version of diagnostic criteria established

by DSM-5 in 2013 [4], the need to identify a particular psychological cause has been replaced by more general criteria implying significant distress or disability in normal activities due to the symptoms, a change that was motivated by the fact that psychological factors are often difficult to identify with certainty, or are found but with only weak or putative association with the diagnosis. In addition, it has been suggested that requiring the identification of explicit psychological factors acting on the patient's unconscious is not only difficult and unreliable in practice, but also inherently maintains a conceptual dualism between mind and body that does not fit with the current neuroscientific view, and that is generally not advocated for other mental diseases [4].

Uncertainties regarding the definition and cause(s) of conversion disorders are also reflected by the fact that they are classified in distinct diagnostic families in the DSM framework put forward by the American Psychiatry Association [2] and the ICD taxonomy established by the World Health Organization [65], being listed among somatoform disorders in the former but among dissociative disorders in the latter. Dissociation also refers to a dichotomy between conscious and unconscious processes dating back to the ideas of Janet in the late 19th century, which probably inspired Freud's conception of conversion, but this implies distinct psychodynamic mechanisms [89]. In addition, the role of dissociation in conversion disorders also remains hypothetical. Nevertheless, in the current state of psychiatric nosography, psychogenic motor or sensory losses are included in the same disease category as psychogenic amnesia according to the ICD (dissociative disorders) but in distinct categories according to the DSM. Finally, the relation of conversion disorders to other major psychiatric conditions is unresolved but a

high rate of comorbidity with depression and anxiety has long been recognized [7,8,75], suggesting a potential partial overlap of risk factors at the individual or environmental levels. For these and other reasons, it has been proposed that a purely descriptive and uncommitted term of “functional neurological disorder” should be preferred to refer to the diagnosis of conversion or psychogenic symptoms [60,95].

As a consequence of the persistent uncertainties and enduring controversies in current medical perspectives on hysteria or conversion, this condition remains very poorly understood and still rarely studied today. This is all the more surprising that historically, in the late 19th – early 20th century, hysterical disorders provided major building blocks for both the theoretical foundations and clinical semiology at the birth of modern neurology and psychiatry. Yet, over the last 100 years, this condition has remained in a grey boundary zone between these two disciplines and received much less interest for scientific inquiry from both neurologists and psychiatrists, in contrast to other diseases that were not even clearly identified in those early days. Thus, while we nowadays have a much better knowledge of brain circuits implicated in complex neurological movement deficits, such as Parkinson or Huntington disease, or those affected in complex mental disturbances such as obsessive-compulsive disorders or depression, our conceptual approach to psychogenic deficits is still very much based on ideas initially formulated by Charcot or Freud, and our mechanistic understanding of their putative neural substrates in the brain is still rudimentary. This state of affairs is even more striking when considering that conversion disorders are among the most common diagnosis in neurology, thought to represent at least 4% of all admissions on a general clinical wards and thus equal in frequency to multiple sclerosis or epilepsy [93,96].

The current article will present a selective overview of recent attempts to investigate the neural underpinning of conversion disorders, particularly thanks to the advent of functional neuroimaging techniques. This review will focus on motor deficits such as unilateral paresis or paralysis, which have most often been studied. Recent findings concerning positive symptoms such as movement disorders or dystonia can be found elsewhere (see Voon et al. in this issue). A large variety of psychogenic neurological symptoms can be seen as manifestations of conversion, which adds further difficulties to a systematic investigation of the neural bases of this condition and makes the few extant studies often difficult to compare (for detailed reviews see [13,104,105]). In spite of this, some convergence between studies is starting to emerge and, together with increasing neuroscientific knowledge about the brain mechanisms of behavior and emotion in humans, provide novel insights into possible pathways through which psyche and body may interact in conversion disorders.

Early neurobiological accounts of conversion disorders

Attempts to define clinical characteristics and putative neural mechanisms of conversion date back to Charcot and his students or co-workers, including Janet, Babinski, and Freud (for historical overview, see Crommelinck in

this issue). Charcot believed that conversion (then called hysteria) resulted from an alteration of the function of the nervous system, in the absence of macroscopically or microscopically visible damage. This dysfunction was conceived as a “dynamic cortical lesion” considered due to a sort of “invasion” of the corresponding brain pathways by a “psychological image”, leading to hyper or hypo-excitability of these pathways [15]. According to this perspective, abnormal excitability could produce virtually any symptom, and thus mimic various organic neurological disorders such as paralysis (reflecting a suppression of the normal “mental image” of movements) or seizure (reflecting an overexpression of such images). The triggering factors could be generated internally by ideas or externally by suggestion. In particular, Charcot underscored the similarities of hysteria with hypnotic phenomena, which he used to reproduce or abolish various symptoms in his clinical lessons. At the same time, Janet emphasized the notion that “fixed ideas” could act in an unconscious part of the mind and that conscious and unconscious parts could become dissociated in special circumstances such as hypnosis or strong emotional states [42]. These ideas were further elaborated by Freud and Breuer [30] who theorized on the role of unconscious motives that were often related to sexual conflicts and expressed through symbolic somatic symptoms due to repression mechanisms. This psychodynamic view led to the terminology of “conversion” disorder, which is still in use in current medical nosology. During the same period, Babinski [7] put much effort and rigor into identifying clinical signs that could distinguish conversion from organic neurological disorders, insisting on the existence of “typical manifestations” allowing a positive diagnosis (unlike a diagnosis by exclusion as often advocated in modern psychiatry and neurology textbooks). Among the latter, Babinski emphasized the role of suggestion (leading him to propose a new term of “pithiatism”, derived from the Greek “*peithein*” meaning “persuasion”) but also individual predispositions and particular kinds of emotional experiences, which he qualified as “organized affective states” (as opposed to more “transient” emotions). According to him, these affective states mainly have a permissive role that can strengthen unconscious ideas and “put them into action” but ideation is the primary causal factor (generated by unconscious processes or suggestion). Interestingly, Babinski also noted that the causal role of particular ideas and particular emotional experiences is often difficult to establish in a retrospective manner. In all the latter accounts, however, the putative neuroanatomical substrates of conversion were only loosely specified.

In subsequent decades, changes in excitability of sensory or motor pathways associated with hysterical conversions were attributed to various physiological mechanisms or anatomical loci, such as the frontal cortex [67], thalamus [50], or cingulate cortex [88] (for more detailed review see [104,105]). Yet these hypotheses were not based on experimental or objective evidence, but followed speculations or extrapolation derived from theories of the nervous system available at the time. For example, Pavlov (best known for his work on associative conditioning) proposed that emotional arousal arising in subcortical centers requires inhibitory control from cortical centers (especially in the frontal lobe), such that in some situations of strong arousal,

inhibitory control might become excessive and overflow to other neurological pathways, thus causing paralysis, anesthesia or blindness [67]. An active inhibition of motor, sensory, or even cognitive processes preventing their integration into conscious awareness was also proposed by more recent authors [10,64,78].

Other accounts have built on the notion that conversion symptoms may more often affect the left than right hemibody, on the one hand, and evidence that the right hemisphere might be dominant for emotion processing, on the other hand, to suggest a role for impaired communication or integration between the two hemispheres [29,34,90]. However, this left preponderance has been questioned by systematic reviews [94] and not all conversion symptoms are strictly lateralized.

Finally, following the earlier notion that hysteria might be triggered by strong emotions or traumatic experiences [7,30,42], several authors proposed that conversion symptoms might reflect an expression of stereotyped behavioral responses linked to more primitive forms of defense, such as motor arrest, freezing, playing dead, agitation, and so forth [47,61,62,110]. In keeping with this view, it is known that specific motor behaviors can be controlled by topographically organized circuits in basal ganglia and periaqueductal gray under the control of cortical (frontal) and subcortical limbic centers [12,104]. However, these models did not rely on empirical evidence and may not easily account for all types of conversion symptoms. Nevertheless, like other early accounts reviewed above, some of these ideas find novel echoes in recent research using functional neuroimaging methods.

Empirical investigations of motor conversion disorders

Systematic scientific investigations to elucidate the neural mechanisms by which conversion disorders may alter motor or sensory functions began to appear in the late 60s and 70s, with the emergence of EEG recordings and the discovery of specific neurophysiological markers for different stages of perceptual processing and response making. While basic neurophysiological measures used in clinical assessment (such visual, somatosensory, auditory, or motor evoked potentials) are typically normal, and may thus help to establish the diagnosis of conversion disorder, some alterations have however been reported for more sophisticated measures associated with more complex task conditions or discriminative abilities (for more detailed review see [104,105]). Most of these findings resemble modulations also known to be governed by attention, motivation, habituation, and/or expectation factors. Thus, in line with earlier neurobiological accounts of hysterical conversion, these alterations have often been interpreted as reflecting modulation (e.g. suppression) of afferent sensory or efferent motor processes under the effect of stress or emotional signals. However, great variability exists between studies and very little is known about the specificity of these findings.

Since the 90s, the emergence of functional brain-imaging techniques with higher anatomical resolution (including SPECT, PET and fMRI) has allowed more detailed investigation of the neural bases of several psychiatric illnesses.

However, to date, relatively few studies have been devoted to the conversion disorders, in contrast to the wealth of studies on other conditions such as depression, anxiety, or schizophrenia. Among the first pioneer imaging approaches, Marshall et al. [56] performed PET scans in a female patient who had had a paralysis of the left leg for 2 years, which was diagnosed as a conversion disorder. Brain activity was examined with PET during the preparation and execution (or attempted execution) of movements with either the right or left leg. Results showed that, whereas motor areas of the left hemisphere were activated during movement executed with the right leg (unaffected), movements attempts made with the left leg (affected) produced no activity in the corresponding motor regions of the right hemisphere (in keeping with the lack of movement), but also evoked an large increase in activity in more anterior and medial prefrontal regions. These increases encompassed the anterior cingulate cortex (ACC), as well as the ventromedial (VMPFC) and orbitofrontal cortex (OFC). As these areas are part of limbic prefrontal cortices, this frontal activation was interpreted as reflecting a recruitment of emotional or motivational processes that produced an active inhibition of motor cortical areas activation and hence paralysis. This interpretation thus accorded with previous accounts of conversion deficits in terms of active suppression of sensorimotor pathways under the influence of other brain (e.g. subcortical) systems as proposed by Pavlov [67] or Ludwig [50]. In addition, the same authors subsequently reported a similar experimental paradigm [37] conducted in a single healthy volunteer in whom left leg paralysis was induced under hypnosis. Again, movement attempts with the affected leg produced no increase in motor cortex, but activated OFC and ACC. However, since these regions have also been associated with self-monitoring, error processing, and conflict detection [1,83], their causal implication in active inhibition of motor activity cannot be firmly demonstrated in this paradigm. It is also possible that instructing the patient to move despite her paralysis induced conflict- or error-related activity in medial prefrontal areas [76] due to the task rather than due to conversion.

In another early study using SPECT imaging [106], we avoided these confounding factors by probing sensorimotor pathways in an indirect manner, without explicit instructions to execute movements. Brain activity was measured in 7 patients with a unilateral motor conversion deficit in three different conditions:

- at rest while they had motor symptoms;
- during a bilateral proprioceptive stimulation with vibration (expected to activate the motor pathways) while they had motor symptoms;
- during the same stimulation a few months later after recovery from symptoms.

Proprioceptive stimulation activated sensorimotor cortical areas in both hemispheres symmetrically, showing intact functions despite motor symptoms, but a selective decrease in activity was observed in the cortico-subcortical motor loops involving the basal ganglia (putamen and caudate nucleus) and thalamus in the hemisphere opposite to motor symptoms. These abnormalities in basal ganglia and thalamus disappeared when scanning was repeated after

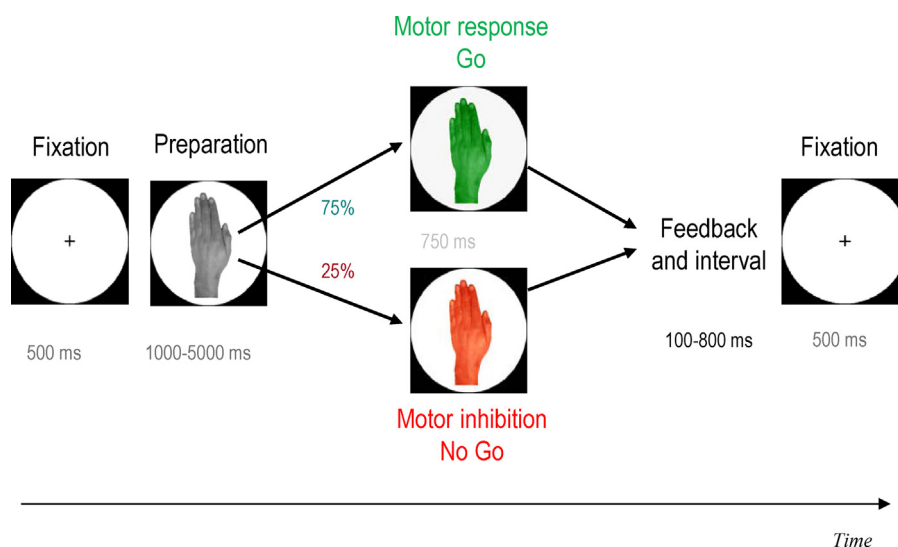


Figure 1 Illustration of the Go/NoGo paradigm used in Cojan et al. [16,18,19]. This allowed testing for brain activity during failure to move on Go trials with the paralyzed hand and comparison with inhibitory control activity during NoGo trials, in addition to motor preparation.

recovery from motor symptoms. Further, a functional network connectivity analysis based on principal components suggested that changes in basal ganglia and thalamus were coupled with the activity level in ventral and medial prefrontal areas, specifically in scans obtained during motor symptoms, not after recovery. Conversely, hyperactivation in basal ganglia was found in psychogenic dystonic movements [86], without increases in motor cortex, unlike the pattern found in organic dystonia. Volumetric changes of thalamic nuclei have also been reported in patients with chronic motor conversion disorders [5,59].

The basal ganglia-thalamic loops are crucial for motor execution and typically implicated in hypokinesia in Parkinson's disease. Decreased activity in the hemisphere contralateral to motor conversion paralysis and increased activity in conversion dystonia might reflect a dysregulation of motor execution processes, downstream to motor planning in cortical areas, perhaps under the influence of limbic prefrontal areas that were shown to be hyperactivated in Marshall et al.'s study [56] or hypercoupled with basal ganglia in our own study [106]. Indeed, the limbic ventromedial prefrontal areas also strongly project to the basal ganglia. The latter thus constitute a unique crossroads in the brain where motor signals converge with motivational signals in order to be integrated and determine behavioral motor outputs. Interestingly, modulation of motor activity in basal ganglia circuits is also known to be responsible for stereotyped motor behaviors associated with particular affective states or immobility after limb injury [23]. According to this view, conversion symptoms might result from the generation of particular motor patterns (innate or acquired) rather than from active inhibition of motor pathways.

A few other fMRI studies however have found reduced activity in motor cortex itself during conversion paralysis or weakness. Such decreases were reported during movement attempts with the affected limb [97], observation of hand movements in videos [11], or exposure to personal emotional scenarios presumed to be associated with conversion

onset [45]. In these studies, additional anomalies were also observed in other brain regions, but very variable, including decreases in supplementary motor areas and orbitofrontal cortices but increases in putamen and inferior prefrontal cortex [97], as well as increases in hippocampus and amygdala [45]. These studies however included small samples of patients ($n=1$ to 4) with heterogeneous symptoms and psychiatric comorbidities. Such reduction in motor cortex activity during motor paralysis has generally been imputed to impaired motor readiness and intentional programming, in keeping with the classic proposal of Charcot that psychogenic weakness might result from a lack of activation of the "mental image of motor movements".

In a more recent fMRI investigation, our group aimed at disentangling the role of impaired motor intention or active motor inhibition in conversion paralysis. To do so, we designed a modified Go/NoGo paradigm allowing us to probe brain activity related to various motor control stages including motor intention, execution, and inhibition. Two patients with left motor conversion were examined using slightly different versions of the same paradigm [18,49], as well as a group of healthy controls [18,19]. In this task (Fig. 1), participants were first presented with a visual cue instructing them to prepare a movement with either the right or left hand (grey hand picture), followed by a second cue instructing to either execute (green hand, 75% of trials=Go) or cancel the prepared movement (red hand, 25% of trials=NoGo). Remarkably, motor preparation with the left (paralyzed) hand or right (intact) hand produced normal contralateral and symmetric activations in contralateral primary motor cortex (area M1) for both conversion patients, just like in healthy participants (Fig. 2). This normal pattern of preparatory motor activity suggests a preserved ability to generate motor intentions and imagery, despite the psychogenic paralysis. As expected, however, a loss of motor activation was seen in the right motor cortex at the time of the instructed movement execution with the left/paralyzed hand (in accordance with the lack of movement, but in

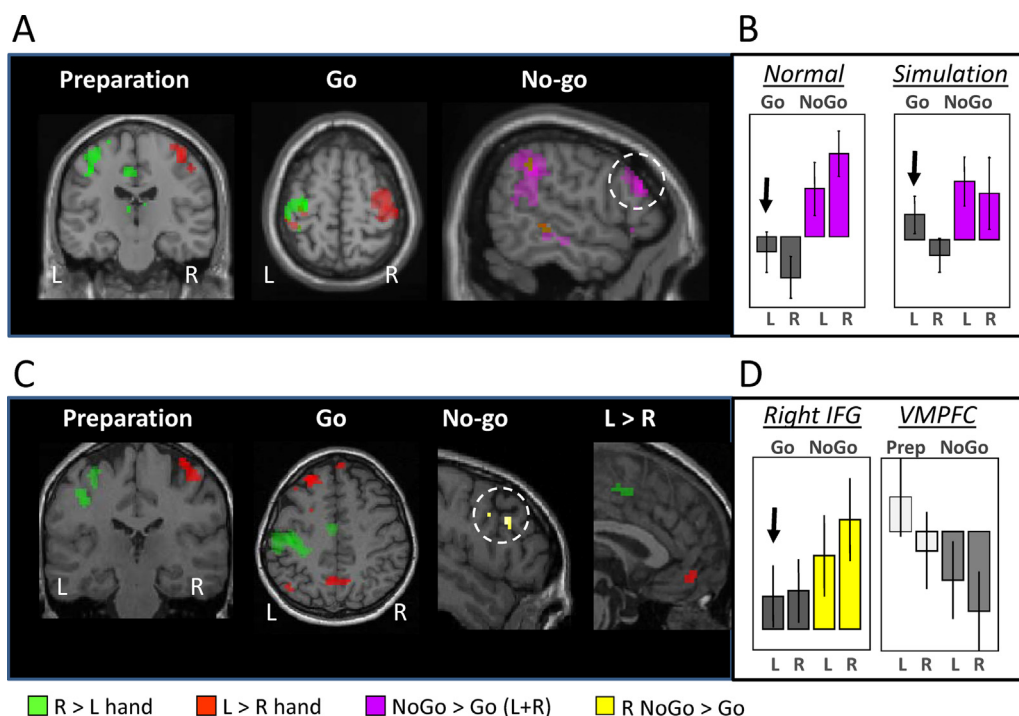


Figure 2 Brain activity in different stages of the Go/NoGo paradigm used in Cojan et al. [18,19]. A. Results in healthy controls, showing activation in contralateral primary motor cortex (M1) during preparation and execution (Go), and activation in right inferior frontal gyrus (IFG) during inhibition (NoGo) for both hands. B. Activity in right IFG during normal condition and during voluntary simulation of left paralysis, showing that simulation was associated with increases in right IFG and produced by voluntary inhibition. C. Results in a patient with left conversion paralysis, showing normal activation of contralateral M1 during preparation but lack of activation of right M1 during paralysis, together with increases in precuneus and ventromedial prefrontal cortex (VMPFC). D. In the patient, left paralysis was not associated with increased activity in right IFG as seen during voluntary inhibition of simulation; whereas activation in VMPFC was selective for preparing or attempting to move the left/paralyzed hand. Adapted from Cojan et al., [18,19].

contrast to left motor cortex activation during correctly executed right hand movement). Thus, intact motor preparation evidenced by covert cortical activity in M1 could not be transformed into actual movement in the conversion patients. Intact motor intention at the cortical level with impaired execution has also been associated with deficient “energizing” and “patterning” of the motor command due to basal ganglia dysfunction in Parkinson disease [68,81,99]. This dissociation between preparation and execution may echo the subjective experience of conversion patients who typically complain of an inability to move despite their will.

Our Go/NoGo paradigm also enabled us to directly test for a role of active inhibition and comparison of conversion disorder with voluntary simulation of paralysis. On NoGo trials, when a prepared movement had to be cancelled, healthy participants showed robust increases in a network known to be associated with motor inhibition and cognitive control, including right inferior frontal gyrus (rIFG) and right inferior parietal lobule (rIPL) [3,19,111]. Moreover, this right fronto-parietal network is similarly recruited for left or right hand motor inhibition [19]. Patients with left motor conversion paralysis showed the same pattern of increases in right inferior frontal and parietal cortices on NoGo trials but, more critically, no such activation on the left Go trials where they failed to move the left/paralyzed hand [18,49]. This suggests that despite preserved motor preparation, the

lack of motor execution with their left hand was not due to active voluntary inhibition. By contrast, when we asked a group of healthy volunteers to simulate a left hand paralysis (“as if they were patients with stroke who effortfully but unsuccessfully tried to move their paralyzed limb”), the right inferior frontal gyrus showed significant activation on the left go trials when they mimicked paralysis (Fig. 2B). Nevertheless, motor cortex was symmetrically activated during covert motor preparation with either hand. These findings indicate not only that simulators followed our task instructions correctly, but also that they actively inhibited the prepared motor command on left Go trials and treated the latter condition like NoGo trials. This differs from conversion patients, in whom no active inhibition activity was seen in prefrontal or parietal cortices, supporting the idea that their paralysis is not simulated voluntarily but rather results from a distinct kind of disturbance in the conscious control of voluntary movements.

Remarkably, however, a unique pattern of activation was observed in our two conversion patients in anterior and posterior brain midline cortical areas, the VMPFC and precuneus [18,49]. These two areas did not activate in healthy controls [19] nor in simulators [18] during the same Go/NoGo task, but were specifically recruited during left hand conditions in conversion patients, particularly during the motor preparation or execution phases for the VMPFC, and

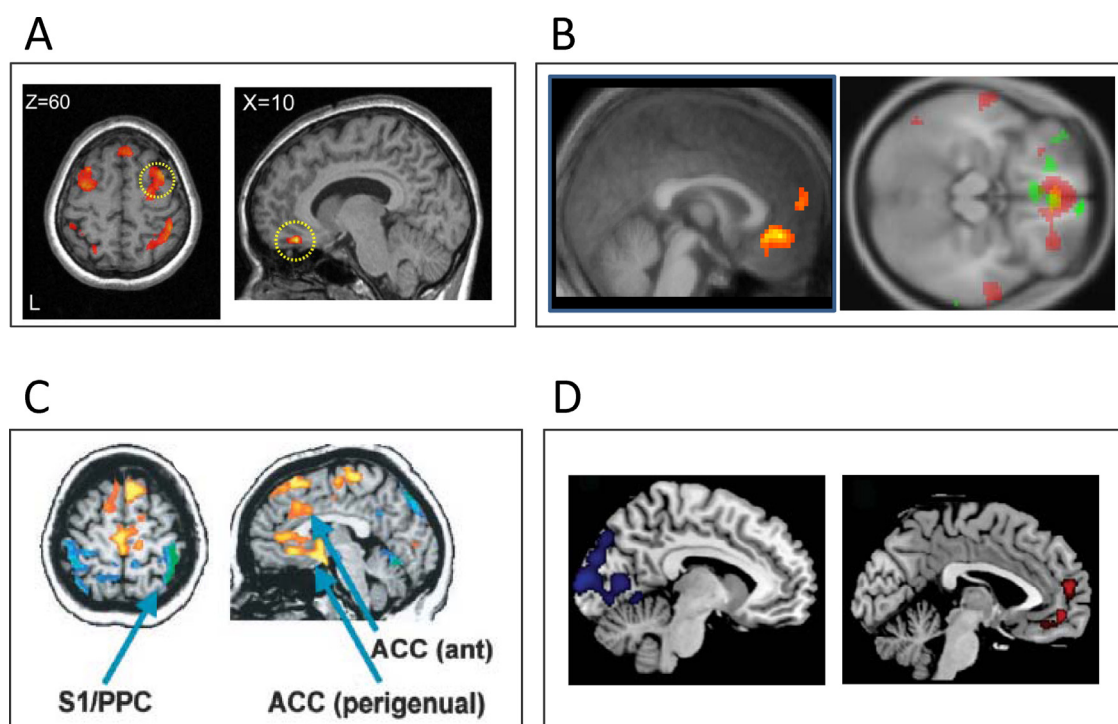


Figure 3 Brain activity patterns in different conversion disorders. A. In patients with motor loss ($n=7$), primary motor cortex activated normally during mental imagery of hand rotation for both the intact and impaired side but was accompanied by increased activity in ventromedial prefrontal cortex (VMPFC) during implicit imagery for the left hand only. From de Lange et al., [25]. B. In another group of patients with motor loss ($n=3$), VMPFC was activated during movement initiation during a visuomotor monitoring task (the right-sided panel shows the overlap for each of patient depicted in a different color: red, green, yellow). From Sinanaj et al., unpublished. C. In patients with conversion anesthesia ($n=4$), painful sensory stimulation produced both reduced activation (blue-green colors) in somatosensory cortex and increased activation (red-yellow colors) in VMPFC and anterior cingulate cortex, relative to healthy subjects. D. In a single patient with transient conversion blindness, visual stimuli evoked weaker activation in occipital areas associated with greater activation and functional coupling of VMPFC. From Becker et al., [9].

during the motor execution (Go) or inhibition (NoGo) phases for the precuneus (Fig. 2C, D). Additional increase in a more lateral portion of the right ventral prefrontal cortex was also observed during attempted movements on left Go trials in one patient [18], but not in the second [49]. Both VMPFC and precuneus are implicated in representations of the self-including [63] autobiographical memory [82] and self-reflexive imagery [14]. VMPFC is particularly recruited in tasks requiring access to affectively relevant information about the self, including personal traits judgments [21,43,84], introspection on one's own feelings [44,46,52,69] and retrieval of emotional information from either past or prospective memory [20,91]. This region is also activated in response to incidental information related to the self without explicit task demands or conscious will [58]. On the other hand, the precuneus is more particularly recruited during autobiographical memory retrieval tasks involving self-centered perspective and sensory imagery [14], as well as judgment of self-agency in actions [27] or free motor choices [87]. Finally, more lateral regions of right ventral prefrontal cortex have been linked with motor inhibition processes promoted by threat signals [79], consistent with a more general role in inhibitory control and avoidance in negative emotional contexts [32,40,41]. Taken together, our findings suggest that neural processes intimately associated

with access to self-related representations, as mediated by VMPFC and precuneus, may play an important role in disturbances of movement control in patients with motor conversion, together with other cortical limbic regions implicated in emotion regulation and motivated behavior.

These results converge with those of other recent fMRI studies that investigated motor imagery and self-monitoring in patients with unilateral motor conversion deficits. de Lange et al. [24,25] examined a group of 7 patients during an explicit motor imagery task, where they were asked to imagine actions with their right or left hand, as well as during an implicit motor task, where they were asked to make rotation judgments for right or left hand pictures. Both tasks are known to induce covert mental simulation of hand movements and activate primary motor cortical areas in healthy people [66]. In these studies, motor conversion patients showed a normal behavioral pattern in response times and normal activation in motor cortices regardless of hand side [24,25], reminiscent of normal activation during motor preparation in our Go/NoGo task [18,49]. In addition, de Lange et al. [24,25] also found a distinctive activation in VMPFC in conversion patients during imagery conditions involving the affected hand side, although this was observed only in the implicit task (Fig. 3A). This activation of VMPFC was attributed to a greater recruitment of self-monitoring processes when using motor processes associated with the

affected limb in an automatic manner, while the difference between hands disappeared when patients had to monitor their hand position in a more controlled/conscious manner during the explicit imagery condition. In accordance with these findings, in a recent (still ongoing) study, we also observed increased activation in VMPFC activation during a visuomotor task in which conversion patients ($n=3$) had to move a cursor on a computer screen using a joystick and monitor the cursor's trajectory in order to reach a pre-specified visual target on the screen (Fig. 3B). This was observed even though these patients used their non-affected hand and had no significant paresis at the time of testing. No such activation was seen in VMPFC during this task in a control group of healthy subjects. Thus, VMPFC may not only activate for the affected hand or during implicit monitoring conditions, but appears to be more generally recruited in motor tasks in patients with motor conversion deficits. More research is needed however to understand the exact role of this region in conversion disorders. Action monitoring in various motor or cognitive tasks is known to recruit more dorsal regions in ACC and pre-SMA [1,83], rather than ventral ACC and VMPFC. Hence, the role of VMPFC as well as precuneus might reflect a modulation of motor behavior driven by affect, imagery, and/or memory related representations, rather than just response monitoring.

Dissociation and hypnosis

Since the time of Charcot and Janet, conversion deficits have often been considered to resemble symptoms produced by hypnotic suggestions. Accordingly, conversion symptoms may be changed or abolished under the effect of counteracting hypnotic suggestions [48,57]. Moreover, hypnotic suggestibility tends to be higher in individuals with a history of conversion symptoms [77]. On the other hand, pathological dissociative states (e.g. post-trauma) have also been linked with changes in activity in medial prefrontal areas and precuneus [22,31], and modulations of neural activity in precuneus have often been reported under hypnosis [26,28,51,70,72]. In further support of a functional link between deficits produced by conversion and those induced by hypnosis, a few neuroimaging studies have reported that motor paralysis under hypnosis is associated with modulation of brain activity in ACC and ventral prefrontal regions [37,108]. Thus, some recent accounts have proposed that conversion symptoms might be produced by similar cognitive mechanisms as hypnotic suggestion, implicating an active inhibition of the access of sensory or motor representation to conscious awareness [10,64].

To clarify the putative links between these conditions, we also investigated the effect of a hypnotically suggested paralysis on brain activity during the same Go/NoGo motor task as described above (Fig. 1). As in healthy people and conversion patients, we found preserved activation of contralateral primary motor cortex during the motor preparation phase, for both the paralyzed and intact hands. Critically, however, we found selective increase in activation in the precuneus during covert motor preparation with the paralyzed hand, suggesting intact imagery and intention processes under hypnosis [19]. No modulation of VMPFC or VLPFC was observed, unlike conversion. Furthermore,

the right fronto-parietal networks associated with executive control and inhibitions were globally enhanced across all conditions, presumably reflecting enhanced attentional control and filtering under hypnosis. In particular the right inferior frontal gyrus (rIFG), typically recruited during tasks requiring high attentional control and during inhibition of prepotent responses [3,39,111], was strongly activated during hypnotic paralysis, but equally so for both the NoGo trials and Go trials and for both right and left hands. Similar increases in right IFG activity were found during left hypnotic paralysis using EEG recording [16] in another group of volunteers performing the same Go/NoGo paradigm in normal and hypnotic states. These findings accord with the view that hypnotic suggestions act through modulation of attentional systems that may allow selective filtering of sensory, motor, or even conceptual representations from conscious awareness [18,38,64,73].

Taken together, these results therefore only partly support a similarity between conversion and hypnosis. Whereas recruitment of internal representations mediated by the precuneus appears to be a shared feature in both cases, perhaps reflecting access to sensory imagery and memory information, more anterior brain regions in ventromedial and dorsolateral prefrontal systems appear differentially implicated in conversion and hypnosis, respectively.

Modulation of brain network connectivity during motor conversion

Early imaging studies in conversion paralysis suggested that changes in activity of cortical motor areas [56] or subcortical-basal ganglia loops [106] were causally driven by modulatory inputs from prefrontal areas partly overlapping with VMPFC and VLPFC that were found to be enhanced in our Go/NoGo paradigm [18]. In the latter, more recent fMRI study, we therefore also tested for any differences in functional connectivity of the right and left motor cortex depending on the nature of motor dysfunction. By using seeds in primary motor areas (M1) and computing temporal dynamic correlations over time during the Go/NoGo task, we found that in normal conditions (healthy controls), activity in M1 was selectively coupled with a network of regions implicated in motor control including dorsolateral premotor cortex (PMC), medial supplementary motor area (SMA), and posterior parietal lobule (SPL). In patients with motor conversion, the same connectivity pattern was found for M1 contralateral to the intact hand, whereas M1 contralateral to the affected/paralyzed hand showed reduced functional connectivity with PMC but increased connectivity with VMPFC (Fig. 4). This suggests that motor control is somehow under the influence of internal representations related to self-relevant emotional information or memory in patients with symptom conversion, rather than under the influence of premotor systems normally implicated in the generation and supervision of voluntary movements.

Remarkably, a distinct pattern of changes in functional connectivity was observed during hypnotic paralysis. M1 contralateral to the paralyzed limb was distinctively more coupled with the precuneus, in posterior and medial parietal cortices, but less coupled with premotor areas in prefrontal cortices [19]. This suggests that hypnosis might act on the

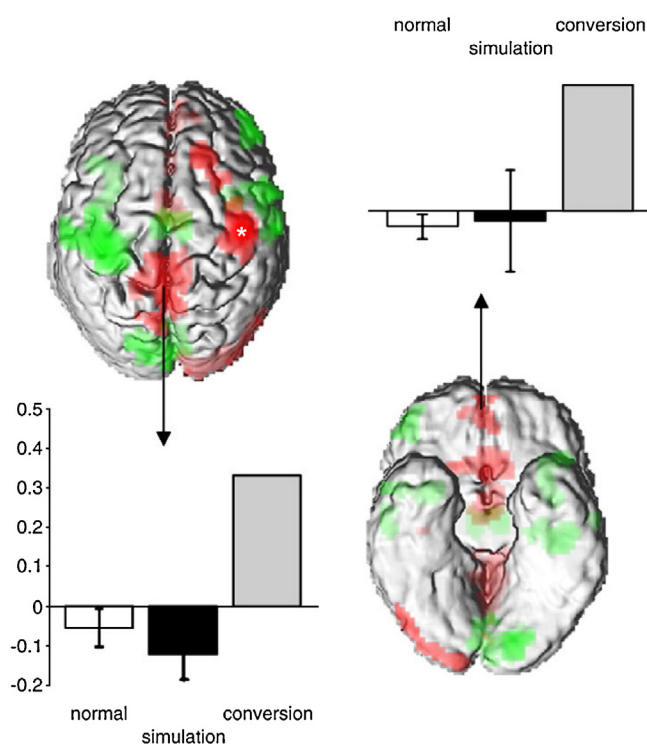


Figure 4 Functional connectivity of primary motor cortex. While both right and left primary motor cortex are generally coupled with ipsilateral premotor areas, left conversion paralysis is associated with a selective increase of connectivity with both precuneus and ventromedial prefrontal cortex. This is not seen during voluntary simulation of left paralysis.

From Cojan et al., [18,19].

motor system predominantly through an influence of internal representations that are related to mnemonic sources or sensory imagery, rather than linked to emotional memory as in conversion. Notably, functional connectivity of motor cortex during simulation of paralysis did not differ from the normal situation in healthy controls, confirming that in this case paralysis was produced by voluntary (inhibitory) control of motor commands [18].

As noted above, both the VMPFC and precuneus are crucially implicated in self-reflective processing and constitute core components of the so-called default mode network (DMN), which is typically more active at rest than during active cognitive tasks [36,71]. The DMN also shows ongoing coherent activity across different behavioral states, even during concomitant task performance [100], and can be distinguished from task-related activity using various network connectivity measures [54]. We have explored the spatial and temporal organization of such intrinsic brain networks during the Go/NoGo task described above using an independent component analysis (ICA) approach (for details see [17]). This analysis allowed us to identify several distinct networks with coherent activity during the task, including the DMN. When measuring the contribution of different brain regions to each of these networks in patients with left motor conversion, relative to healthy controls and simulators, we found a selective decrease in contribution to the DMN for the VMPFC/anterior cingulate

and precuneus/posterior cingulate cortex (Fig. 5) during conversion only. Thus, in the patients, these two areas were less engaged in default mode activity and presumably more engaged in a different network. This converges with our seed-based functional connectivity analysis (described above) suggesting that VMPFC and precuneus were dynamically coupled with motor cortex during conversion. In addition, our ICA analysis also identified a motor network including primary motor cortex (M1), supplementary motor area (SMA), and portions of the basal ganglia. Interestingly, right M1 was found to contribute less to this network during both conversion and simulation paralysis, whereas the contribution of SMA was reduced during simulation only. In addition, changes in connectivity were also found for the caudate nucleus in both hemispheres, which appeared less expressed in both the DMN and the motor networks during conversion as well as simulation, relative to its normal connectivity state (Fig. 5). The latter finding suggests a functional “disconnection” of the caudate from the rest of the DMN and the motor cortex in both types of paralysis.

These connectivity data converge with our previous results obtained with more conventional imaging analyses during either active motor performance [16–18,49] or passive proprioceptive stimulation [106], indicating that cortical and subcortical motor pathways may exhibit particular functional interactions with midline brain areas regulating self-related and affective processes during motor conversion disorders. Similar evidence has been gathered in recent studies [101–103] concerning patients with psychogenic movement disorders such as tremor or dystonia (i.e., positive rather negative motor symptoms), although pointing to the role of different circuits connecting the amygdala to SMA (see also review by Voon et al. in this issue). Future research should use more advanced connectivity measures such as dynamic causal modelling (DCM) and compare different conversion patient groups during different symptomatic conditions (pre- vs. post-recovery) to gain better insights into such interactions between motor control and emotion/motivation systems.

Neuroimaging findings in non-motor conversion disorders

A few brain-imaging studies have examined conversion deficits affecting other neurological functions such as somatosensory loss [35,53], visual loss [9,85,109], or memory loss [33,55,98]. In most cases, reduced activity was observed in brain areas involved in the impaired functions, including somatosensory cortices, occipital lobe, or temporal lobe, respectively (for review see [104,105]). Additional changes (hyper- or hypo-activation) were also generally found in various other regions such as thalamus, basal ganglia, insula, anterior cingulate or prefrontal cortex, but without a clear systematic pattern. Left spatial neglect has also been observed during conversion symptoms, with symmetric parietal activation but increased recruitment of ACC during line bisection judgments [80].

Of particular note, a recent fMRI study in a single patient with transient episode of psychogenic blindness and hallucinations reported preserved responses in occipital cortex to simple visual stimulation but markedly decreased

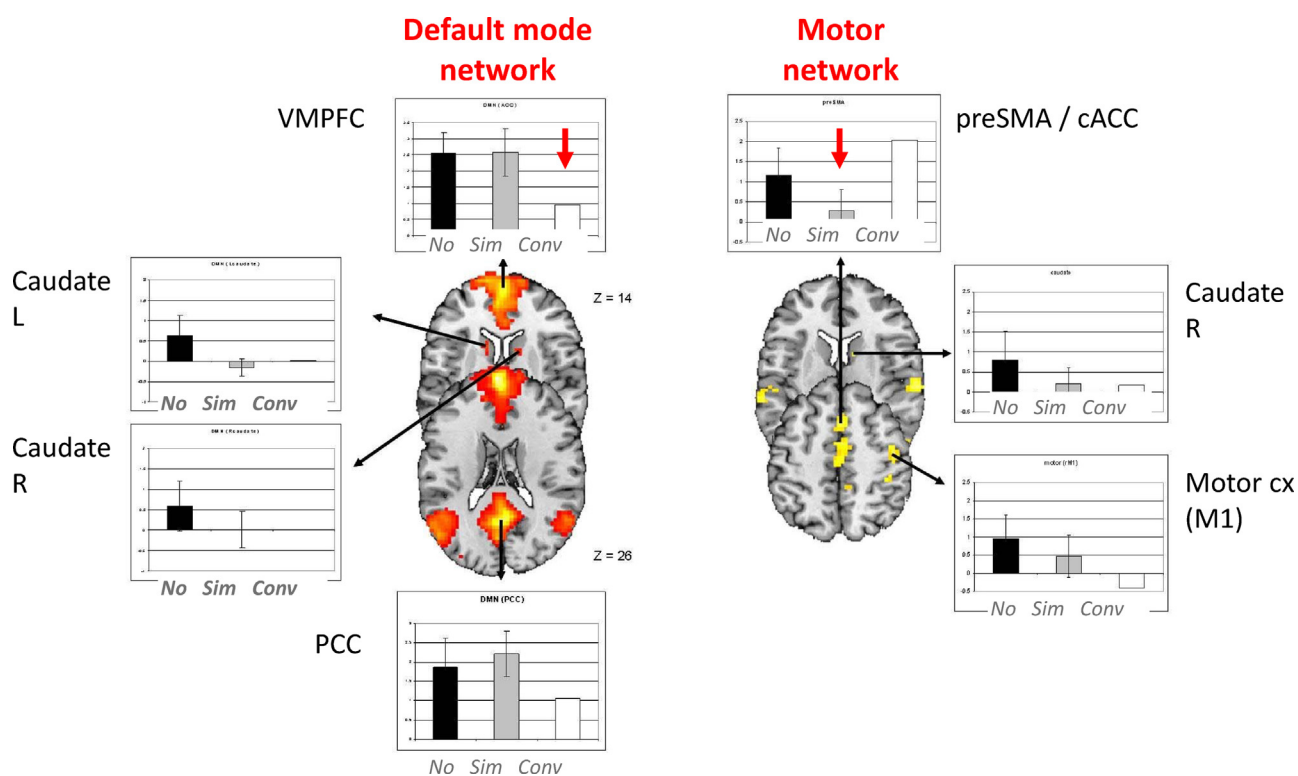


Figure 5 Functional connectivity using independent component analysis (ICA) during a Go/NoGo task. Ventromedial prefrontal cortex showed a selective reduction in its functional connectivity (i.e. temporal correlation) with a network of midline brain areas corresponding to the default mode network; the supplementary motor area showed a selective reduction of connectivity with a network of motor and premotor areas during simulation.

Data from Cojan et al., [18,19], adapted from Cojan and Vuilleumier [17].

responses to more complex pictures (faces), together with selective increases in VMPFC (Fig. 3D), which occurred only during blindness episodes and not after recovery [9]. Functional connectivity analysis also revealed increased coupling between VMPFC and occipital areas during blindness episodes. Another fMRI study [109] conducted in 7 patients with psychogenic blindness affecting various parts of the visual field (monocular or binocular) found reduced activation of bilateral occipital areas to full field visual stimulation with checkerboards, again accompanied with increased activation in right thalamus, striatum, and right VLPFC/lateral OFC. This pattern of sensory decrease and fronto-limbic increase echoes findings in 4 patients suffering from unilateral anesthesia and psychogenic pain [53], in whom somatosensory areas showed reduced response to noxious stimuli while VMPC and ACC showed increased activation in the same condition (Fig. 3C), unlike healthy participants.

Altogether, even though the existing results are still scarce and partly inconsistent across studies and conversion domains, recent neuroimaging data for non-motor deficits show some convergence with those obtained in patients with motor conversion paralysis in several studies [18,24,25,56,106]. Thus, an emerging pattern of findings across domains points to not only abnormal recruitment of brain areas involved in conscious control of movement or conscious sensory perception, but also heightened activation of both cortical (VMPFC, precuneus) and subcortical

(amygdala, thalamus, striatum) areas thought to be normally involved in emotional regulation of behavior and memory. It remains however to determine the exact mechanisms through which these systems may interact, as well as the exact factors that are responsible for these alterations.

Conclusions

Over the last 15 years, a growing number of functional brain-imaging studies have investigated the neural substrates of conversion symptoms, a clinical condition that has been recognized and much reflected upon for many centuries, and which remains puzzling today. These imaging results have begun to shed new light on the possible neurobiological underpinnings of conversion, although our current knowledge is still far from being able to provide a coherent framework. In particular, there is now clear neuroimaging evidence for changes in brain activity, affecting specific regions in accordance with the nature of the symptoms and the time-course of their recovery. Thus, more than 100 years after Charcot and Freud, it is now possible to demonstrate that conversion paralysis is associated with a “functional or dynamic lesion” in brain pathways, without organic damage, as the founders of modern neurology and psychiatry had indeed postulated. Importantly, brain-imaging results also indicate that functional changes may not only concern those brain regions directly associated with the symptoms

(e.g. motor areas in paralysis, visual areas in blindness) but also several others in frontal, parietal, and subcortical areas, whose exact role in conversion still remains to be fully determined. Furthermore, by using specific experimental paradigms and various methodological approaches, it has also become possible to test more specific hypotheses about underlying neural and psychodynamic mechanisms that have been postulated in the past – such as the role of active inhibition, impaired access to conscious awareness or dissociation from conscious will, links with emotion dysregulation or traumatic memories, similarities with hypnosis, and so forth.

For motor conversion, work by our group and others suggest that motor imagery and motor intention are preserved and continue to normally activate primary motor cortex; whereas movement execution is impaired, presumably due to a suppression or modulation of motor output pathways in cortical-basal ganglia loops under the influence of other brain regions (e.g. limbic prefrontal areas). Our results provide no evidence for a recruitment of inhibitory control systems, at least as mediated by premotor or lateral prefrontal cortices, such as the right IFG [18,111]. Furthermore, the neural changes observed in conversion differ from those associated with simulation, where voluntary inhibition and/or attentional mechanisms instead seem to play a role. Our results also reveal only a partial similarity between motor conversion disorders and hypnotic paralysis rather than a complete overlap.

Taken together, these data lead to a new tentative functional neuroanatomy model of psychogenic paralysis [17,105,107]. On the one hand, in line with the classic views originating from Charcot, Janet, Babinski and others at the turn of the 20th century, brain activity and connectivity patterns suggest that both conversion and hypnosis might entail an apparent dominance of internal representations from imagery and memory on the control of motor behavior (Fig. 6). In both conditions, the motor pathways (e.g. M1) appear functionally less coupled with premotor cortical areas but more coupled with midline brain regions typically associated with self-related processing and mental imagery, such as the precuneus. On the other hand, however, unlike the classic view, conversion and hypnosis

appear to act on behavior and perception via partly distinct brain circuits. In conversion, modulations of motor and sensory awareness might primarily be driven by an increased recruitment of regions in VMPFC, implicated in the access to self-relevant affective representations and memories [17,104,105,107], as well as other subcortical limbic regions such as the amygdala [45,79,101,102]. These areas might influence movement, sensation, and self-awareness more broadly by promoting or suppressing certain patterns of behaviors through modulatory inputs to motor or sensory pathways (as observed for more primitive adaptive reactions to threat, see [47,104,110]), and/or by imbuing behavior with particular affective and self-relevant associations though an integration of sensorimotor activity with internal representations retrieved from memory or imagery. This model echoes the long-established notion that conversion symptoms generally arise under the influence of emotional factors or past emotional trauma, real or imagined [7,42], and the Freudian view that “hysterics primarily suffer from reminiscences” [30], although without necessarily invoking the role of repression, sexual origin, and symbolization as postulated by Freud. Conversely, under hypnosis, alterations in conscious perception and movement might arise from interaction between imagery and sensorimotor process through a modulation imposed by executive attentional mechanisms mediated by lateral prefrontal cortical areas (e.g. right IFG) and perhaps ACC [16,19,73,74].

Nonetheless, more research is needed to go beyond these general descriptive models focusing on the generation of specific symptoms, in order to better understand the exact mechanistic interplay between different brain systems involved in conversion (and hypnosis), in order to elucidate the causal factors responsible for triggering conversion episodes and associated brain patterns, and to clarify the relationships with other psychiatric diseases reflecting maladaptive emotional adjustment and frequently associated with conversion (such as depression, anxiety, or posttraumatic stress disorder). Future research should also establish whether similar mechanisms underlie conversion disorders in different domains (e.g. motor, visual, etc.), and whether different types of conversion exist in different patients. This knowledge will be invaluable for improving the clinical

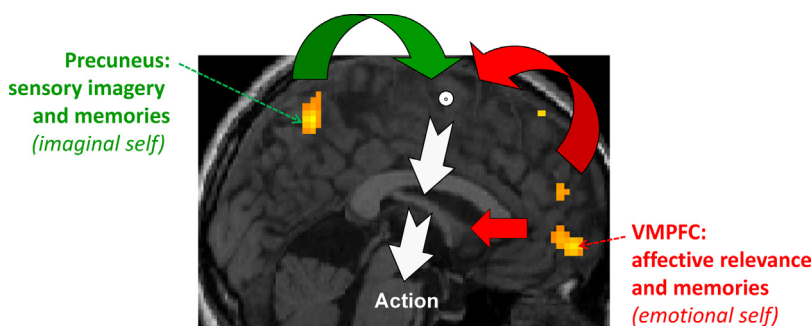


Figure 6 Schematic neuroanatomical model of psychogenic paralysis. Both precuneus and ventromedial prefrontal cortex (VMPFC) are core components of brain networks mediating access to self-representations and personal episodic memories, including sensory or agency information (for precuneus) and affective relevance (for VMPFC). Frequent recruitment of these areas in conversion patients and enhanced connectivity with motor or sensory areas suggests an important role in modulating behavior and self-awareness, perhaps by modulating motor or sensory processes (at cortical and/or subcortical level) under the influence of memory and affective representations unconsciously generated in these regions. VMPFC activity appears specific to conversion, whereas precuneus is also recruited during hypnosis.

diagnosis and management of these patients, for better defining their prognosis, but also more generally for illuminating the intricate relationships between mind and body and their pathological distortion in conversion disorders.

Disclosure of interest

The author declares that he has no conflicts of interest concerning this article.

Acknowledgments

This work has been supported by grants from the Swiss National Science Foundation (No 127560 and 143764), the Cogito Foundation, and the Geneva Academic Society (Foremane Fund). The author thanks Yann Cojan, Lakshmi Weber, Indrit Sinanaj, Alain Forster, Nicole Cheseaux, and Selma Aybeck for contributions to various projects and fruitful discussions.

References

- [1] Alexander WH, Brown JW. Medial prefrontal cortex as an action-outcome predictor. *Nat Neurosci* 2011;14(10):1338–44 [PubMed PMID: 21926982. Pubmed Central PMCID: 3183374].
- [2] American Psychiatric Association. *Diagnostic and Statistical Manual of Mental Disorders, DSM V*. Washington, DC: American Psychiatric Association; 2013.
- [3] Aron AR, Fletcher PC, Bullmore ET, Sahakian BJ, Robbins TW. Stop-signal inhibition disrupted by damage to right inferior frontal gyrus in humans. *Nat Neurosci* 2003;6(2):115–6 [PubMed PMID: 12536210].
- [4] Stone J, LaFrance Jr WC, Brown R, Spiegel D, Levenson JL, Sharpe M. Conversion disorder: current problems and potential solutions for DSM-5. *J Psychosom Res* 2011;71(6):369–76 [PubMed PMID: 22118377].
- [5] Atmaca M, Aydin A, Tezcan E, Poyraz AK, Kara B. Volumetric investigation of brain regions in patients with conversion disorder. *Prog Neuropsychopharmacol Biol Psychiatry* 2006;30(4):708–13 [PubMed PMID: 16600450].
- [6] Aybek S, Hubschmid M, Vuilleumier P, Burkhard PR, Berney A, Vingerhoets FJ. Hysteria: an historical entity, a psychiatric condition or a neurological disease? *Rev Med Suisse* 2008;4(156):1151–6 [PubMed PMID: 18630169].
- [7] Babinski J. *Démembrement de l'hystérie traditionnelle: pithiatisme*. Paris: Semaine Médicale; 1988.
- [8] Ballmaier M, Schmidt R. Conversion disorder revisited. *Funct Neurol* 2005;20(3):105–13 [PubMed PMID: 16324233].
- [9] Becker B, Scheele D, Moessner R, Maier W, Hurlmann R. Deciphering the neural signature of conversion blindness. *Am J Psychiatry* 2013;170(1):121–2 [PubMed PMID: 23288388].
- [10] Bell V, Oakley DA, Halligan PW, Deeley Q. Dissociation in hysteria and hypnosis: evidence from cognitive neuroscience. *J Neurol Neurosurg Psychiatry* 2011;82(3):332–9 [PubMed PMID: 20884677].
- [11] Burgmer M, Konrad C, Jansen A, Kugel H, Sommer J, Heindel W, et al. Abnormal brain activation during movement observation in patients with conversion paralysis. *Neuroimage* 2006;29(4):1336–43 [PubMed PMID: 16213162].
- [12] Carrive P. The periaqueductal gray and defensive behavior: functional representation and neuronal organization. *Behav Brain Res* 1993;58(1–2):27–47 [PubMed PMID: 8136048].
- [13] Carson AJ, Brown R, David AS, Duncan R, Edwards MJ, Goldstein LH, et al. Functional (conversion) neurological symptoms: research since the millennium. *J Neurol Neurosurg Psychiatry* 2012;83(8):842–50 [PubMed PMID: 22661497].
- [14] Cavanna AE, Trimble MR. The precuneus: a review of its functional anatomy and behavioural correlates. *Brain* 2006;129(Pt 3):564–83 [PubMed PMID: 16399806].
- [15] Charcot JM. *Leçons du Mardi à la Salpêtrière (1887–1888)*. CEPL 1974 ed. Paris: Bureau du Progrès Médical; 1892.
- [16] Cojan Y, Archimi A, Cheseaux N, Waber L, Vuilleumier P. Time-course of motor inhibition during hypnotic paralysis: EEG topographical and source analysis. *Cortex* 2013;49(2):423–36 [PubMed PMID: 23211547].
- [17] Cojan Y, Vuilleumier P. Functional brain-imaging of psychogenic paralysis during conversion and hypnosis. In: Hallett M, Cloninger C, Fahn S, Halligan P, Jankovic J, Lang A, et al., editors. *Psychogenic movement disorders and other conversion disorders*. Cambridge: Cambridge University Press; 2011. p. 143–59.
- [18] Cojan Y, Waber L, Carruzzo A, Vuilleumier P. Motor inhibition in hysterical conversion paralysis. *Neuroimage* 2009;47(3):1026–37 [PubMed PMID: 19450695].
- [19] Cojan Y, Waber L, Schwartz S, Rossier L, Forster A, Vuilleumier P. The brain under self-control: modulation of inhibitory and monitoring cortical networks during hypnotic paralysis. *Neuron* 2009;62(6):862–75 [PubMed PMID: 19555654].
- [20] D'Argembeau A, Feyers D, Majerus S, Collette F, Van der Linden M, Maquet P, et al. Self-reflection across time: cortical midline structures differentiate between present and past selves. *Soc Cogn Affect Neurosci* 2008;3(3):244–52 [PubMed PMID: 19015116].
- [21] D'Argembeau A, Ruby P, Collette F, Degueldre C, Baeteau E, Luxen A, et al. Distinct regions of the medial prefrontal cortex are associated with self-referential processing and perspective taking. *J Cogn Neurosci* 2007;19(6):935–44 [PubMed PMID: 17536964].
- [22] Dalenberg C, Loewenstein R, Spiegel D, Brewin C, Lanius R, Frankel S, et al. Scientific study of the dissociative disorders. *Psychother Psychosom* 2007;76(6):400–1 [Author reply 1–3. PubMed PMID: 17917478].
- [23] De Ceballos ML, Baker M, Rose S, Jenner P, Marsden CD. Do enkephalins in basal ganglia mediate a physiological motor rest mechanism? *Movement Disorders* 1986;1:223–333.
- [24] de Lange FP, Roelofs K, Toni I. Increased self-monitoring during imagined movements in conversion paralysis. *Neuropsychologia* 2007;45(9):2051–8 [PubMed PMID: 17367826].
- [25] de Lange FP, Roelofs K, Toni I. Motor imagery: a window into the mechanisms and alterations of the motor system. *Cortex* 2008;44(5):494–506 [PubMed PMID: 18387583].
- [26] Del Casale A, Ferracuti S, Rapinesi C, Serata D, Sani G, Savoia V, et al. Neurocognition under hypnosis: findings from recent functional neuroimaging studies. *Int J Clin Exp Hypn* 2012;60(3):286–317 [PubMed PMID: 22681327].
- [27] Farrer C, Frith CD. Experiencing oneself vs. another person as being the cause of an action: the neural correlates of the experience of agency. *Neuroimage* 2002;15(3):596–603 [PubMed PMID: 11848702].
- [28] Faymonville ME, Boly M, Laureys S. Functional neuroanatomy of the hypnotic state. *J Physiol Paris* 2006;99(4–6):463–9 [PubMed PMID: 16750615].
- [29] Flor-Henry P, Fromm-Auch D, Tapper M, Schopflocher D. A neuropsychological study of the stable syndrome of hysteria. *Biol Psychiatry* 1981;16:601–16.
- [30] Freud S, Breuer J. *Studien über Hysterie*. Leipzig and Vienna: Deutike; 1895.
- [31] Frewen P, Lane RD, Neufeld RW, Densmore M, Stevens T, Lanius R. Neural correlates of levels of emotional awareness during trauma script-imagery in posttraumatic stress disorder. *Psychosom Med* 2008;70(1):27–31 [PubMed PMID: 18158370].

- [32] Fuentes P, Barros-Loscertales A, Bustamante JC, Rosell P, Costumero V, Avila C. Individual differences in the Behavioral Inhibition System are associated with orbitofrontal cortex and precuneus gray matter volume. *Cogn Affect Behav Neurosci* 2012;12(3):491–8 [PubMed PMID: 22592859].
- [33] Fujiwara E, Piefke M, Lux S, Fink GR, Kessler J, Kracht L, et al. Brain correlates of functional retrograde amnesia in three patients. *Brain Cogn* 2004;54(2):135–6 [PubMed PMID: 15022660].
- [34] Galin D, Diamond R, Braff D. Lateralization of conversion symptoms: more frequent on the left. *Am J Psychiatry* 1977;134(5):578–80.
- [35] Ghaffar O, Staines WR, Feinstein A. Unexplained neurologic symptoms: an fMRI study of sensory conversion disorder. *Neurology* 2006;67(11):2036–8 [PubMed PMID: 17159115].
- [36] Gusnard DA, Akbudak E, Shulman GL, Raichle ME. Medial prefrontal cortex and self-referential mental activity: relation to a default mode of brain function. *Proc Natl Acad Sci U S A* 2001;98(7):4259–64 [PubMed PMID: 11259662. Pubmed Central PMCID: 31213].
- [37] Halligan PW, Athwal BS, Oakley DA, Frackowiak RS. Imaging hypnotic paralysis: implications for conversion hysteria. *Lancet* 2000;355(9208):986–7 [PubMed PMID: 10768440].
- [38] Halligan PW, Oakley DA. Hypnosis and cognitive neuroscience: bridging the gap. *Cortex* 2013;49(2):359–64 [PubMed PMID: 23375442].
- [39] Hampshire A, Chamberlain SR, Monti MM, Duncan J, Owen AM. The role of the right inferior frontal gyrus: inhibition and attentional control. *Neuroimage* 2010;50(3):1313–9 [PubMed PMID: 20056157. Pubmed Central PMCID: 2845804].
- [40] Heilman KM. The neurobiology of emotional experience. *J Neuropsychiatry Clin Neurosci* 1997;9(3):439–48 [PubMed PMID: 9276845].
- [41] Hodgson TL, Mort D, Chamberlain MM, Hutton SB, O'Neill KS, Kennard C. Orbitofrontal cortex mediates inhibition of return. *Neuropsychologia* 2002;40(12):1891–901 [PubMed PMID: 12207988].
- [42] Janet P. *L'état mental des hystériques*. Paris: Rueff; 1894.
- [43] Jenkins AC, Macrae CN, Mitchell JP. Repetition suppression of ventromedial prefrontal activity during judgments of self and others. *Proc Natl Acad Sci U S A* 2008;105(11):4507–12 [PubMed PMID: 18347338. Pubmed Central PMCID: 2393803. Epub 2008/03/19. eng].
- [44] Johnson SC, Baxter LC, Wilder LS, Pipe JG, Heiserman JE, Prigatano GP. Neural correlates of self-reflection. *Brain* 2002;125(Pt 8):1808–14 [PubMed PMID: 12135971. Epub 2002/07/24. eng].
- [45] Kanaan RA, Craig TK, Wessely SC, David AS. Imaging repressed memories in motor conversion disorder. *Psychosom Med* 2007;69(2):202–5 [PubMed PMID: 17327215].
- [46] Kelley AE, Bakshi VP, Haber SN, Steininger TL, Will MJ, Zhang M. Opioid modulation of taste hedonics within the ventral striatum. *Physiol Behav* 2002;76(3):365–77 [PubMed PMID: 12117573].
- [47] Kretschmer E. *Hysteria: reflex and instinct*. London: Peter Owen; 1948. p. 1926.
- [48] Lemonnier E, Allilaire J. Treatments of hysteria. *Rev Prat* 1995;45(20):2573–7.
- [49] Luauté J, Saladini O, Cojan Y, Bellaiche S, Ciancia S, Garcia-Larrea L, et al., editors. Simulation, conversion ou majoration? Évolution des explorations fonctionnelles. Discussion à propos d'un cas en rééducation. *Annales Médico-psychologiques, revue psychiatrique*. 2010. p. 306–10, 168(4).
- [50] Ludwig AM. Hysteria: a neurobiological theory. *Arch Gen Psychiatry* 1972;27:771–7.
- [51] Ludwig VU, Stelzel C, Krutiak H, Magrabi A, Steimke R, Paschke LM, et al. The suggestible brain: posthypnotic effects on value-based decision-making. *Soc Cogn Affect Neurosci* 2013, <http://dx.doi.org/10.1093/scan/nst110> [PubMed PMID: 23887809].
- [52] Macrae CN, Moran JM, Heatherton TF, Banfield JF, Kelley WM. Medial prefrontal activity predicts memory for self. *Cereb Cortex* 2004;14(6):647–54 [PubMed PMID: 15084488. Epub 2004/04/16. eng].
- [53] Mailis-Gagnon A, Giannoylis I, Downar J, Kwan CL, Mikulis DJ, Crawley AP, et al. Altered central somatosensory processing in chronic pain patients with "hysterical" anesthesia. *Neurology* 2003;60(9):1501–7 [PubMed PMID: 12743239].
- [54] Mantini D, Marzetti L, Corbetta M, Romani GL, Del Gratta C. Multimodal integration of fMRI and EEG data for high spatial and temporal resolution analysis of brain networks. *Brain Topogr* 2010;23(2):150–8 [PubMed PMID: 20052528].
- [55] Markowitsch HJ. Psychogenic amnesia. *Neuroimage* 2003;20(Suppl. 1):S132–8 [PubMed PMID: 14597306].
- [56] Marshall JC, Halligan PW, Fink GR, Wade DT, Frackowiak RSJ. The functional anatomy of a hysterical paralysis. *Cognition* 1997;64:B1–8.
- [57] Moene FC, Hoogduin KA, Van Dyck R. The inpatient treatment of patients suffering from (motor) conversion symptoms: a description of eight cases. *Int J Clin Exp Hypn* 1998;46(2):171–90 [PubMed PMID: 9558806].
- [58] Moran JM, Heatherton TF, Kelley WM. Modulation of cortical midline structures by implicit and explicit self-relevance evaluation. *Soc Neurosci* 2009;4(3):197–211 [PubMed PMID: 19424905. Epub 2009/05/09. eng].
- [59] Nicholson TR, Aybek S, Kempton MJ, Daly EM, Murphy DG, David AS, et al. A structural MRI study of motor conversion disorder: evidence of reduction in thalamic volume. *J Neurol Neurosurg Psychiatry* 2013 [PubMed PMID: 24039028].
- [60] Nicholson TR, Stone J, Kanaan RA. Conversion disorder: a problematic diagnosis. *J Neurol Neurosurg Psychiatry* 2011;82(11):1267–73 [PubMed PMID: 21036784].
- [61] Nijenhuis ER, van der Hart O, Kruger K, Steele K. Somatoform dissociation, reported abuse and animal defence-like reactions. *Aust N Z J Psychiatry* 2004;38(9):678–86 [PubMed PMID: 15324331].
- [62] Nijenhuis ER, Vanderlinden J, Spinhoven P. Animal defensive reactions as a model for trauma-induced dissociative reactions. *J Trauma Stress* 1998;11(2):243–60 [PubMed PMID: 9565914].
- [63] Northoff G, Panksepp J. The trans-species concept of self and the subcortical-cortical midline system. *Trends Cogn Sci* 2008;12(7):259–64 [PubMed PMID: 18555737].
- [64] Oakley DA. Hypnosis and conversion hysteria: a unifying model. *Cog Neuropsychiatry* 1999;4:3.
- [65] Organization WH. *The international classification of diseases (ICD) - 10*. 2010.
- [66] Parsons LM, Fox PT, Downs JH, Glass T, Hirsch TB, Martin CC, et al. Use of implicit motor imagery for visual shape discrimination as revealed by PET. *Nature* 1995;375(6526):54–8 [PubMed PMID: 7723842].
- [67] Pavlov J. *Essai d'une interprétation physiologique de l'hystérie*. *Encephale* 1933:285–93.
- [68] Peterson DS, Pickett KA, Earhart GM. Effects of levodopa on vividness of motor imagery in Parkinson disease. *J Parkinson's Dis* 2012;2(2):127–33 [PubMed PMID: 23939437. Pubmed Central PMCID: 3744123].
- [69] Piguet C, Sterpenich V, Desseilles M, Cojan Y, Bertschy G, Vuilleumier P. Neural substrates of cognitive switching and inhibition in a face processing task. *Neuroimage* 2013;82:489–99 [PubMed PMID: 23774397].
- [70] Pyka M, Burgmer M, Lenzen T, Pioch R, Dannlowski U, Pfeleiderer B, et al. Brain correlates of hypnotic paralysis—a resting state fMRI study. *Neuroimage* 2011;56(4):2173–82 [PubMed PMID: 21497656].

- [71] Raichle ME, MacLeod AM, Snyder AZ, Powers WJ, Gusnard DA, Shulman GL. A default mode of brain function. *Proc Natl Acad Sci U S A* 2001;98(2):676–82 [PubMed PMID: 11209064. Pubmed Central PMCID: 14647].
- [72] Rainville P, Hofbauer RK, Paus T, Duncan GH, Bushnell MC, Price DD. Cerebral mechanisms of hypnotic induction and suggestion. *J Cogn Neurosci* 1999;11(1):110–25 [PubMed PMID: 9950718].
- [73] Raz A. Hypnosis: a twilight zone of the top-down variety. *Trends Cogn Sci* 2011;15(12):555–7 [PubMed PMID: 22079011].
- [74] Raz A. Hypnosis as a lens to the development of attention. *Conscious Cogn* 2012;21(3):1595–8 [PubMed PMID: 22728139].
- [75] Reich SG. Psychogenic movement disorders. *Semin Neurol* 2006;26(3):289–96 [PubMed PMID: 16791775].
- [76] Roelofs K, de Bruijn ER, Van Galen GP. Hyperactive action monitoring during motor-initiation in conversion paralysis: an event-related potential study. *Biol Psychol* 2006;71(3):316–25 [PubMed PMID: 16112792].
- [77] Roelofs K, Hoogduin KA, Keijsers GP, Naring GW, Moene FC, Sandijck P. Hypnotic susceptibility in patients with conversion disorder. *J Abnorm Psychol* 2002;111(2):390–5 [PubMed PMID: 12003460].
- [78] Sackeim HA, Nordlie JW, Gur RC. A model of hysterical and hypnotic blindness: cognition, motivation, and awareness. *J Abnorm Psychol* 1979;88(5):474–89.
- [79] Sagaspe P, Schwartz S, Vuilleumier P. Fear and stop: a role for the amygdala in motor inhibition by emotional signals. *Neuroimage* 2011;55(4):1825–35 [PubMed PMID: 21272655. Epub 2011/01/29. eng].
- [80] Saj A, Arzy S, Vuilleumier P. Functional brain-imaging in a woman with spatial neglect due to conversion disorder. *JAMA* 2009;302(23):2552–4 [PubMed PMID: 20009053. Epub 2009/12/17. eng].
- [81] Samuel M, Ceballos-Baumann AO, Boecker H, Brooks DJ. Motor imagery in normal subjects and Parkinson's disease patients: an H215O PET study. *Neuroreport* 2001;12(4):821–8 [PubMed PMID: 11277590].
- [82] Schacter DL, Addis DR, Buckner RL. Remembering the past to imagine the future: the prospective brain. *Nat Rev Neurosci* 2007;8(9):657–61 [PubMed PMID: 17700624. Epub 2007/08/21. eng].
- [83] Schall JD, Stuphorn V, Brown JW. Monitoring and control of action by the frontal lobes. *Neuron* 2002;36(2):309–22 [PubMed PMID: 12383784].
- [84] Schneider F, Bermpohl F, Heinzel A, Rotte M, Walter M, Tempelmann C, et al. The resting brain and our self: self-relatedness modulates resting state neural activity in cortical midline structures. *Neuroscience* 2008;157(1):120–31 [PubMed PMID: 18793699. Epub 2008/09/17. eng].
- [85] Schoenfeld MA, Hassa T, Hopf JM, Eulitz C, Schmidt R. Neural correlates of hysterical blindness. *Cereb Cortex* 2011;21(10):2394–8 [PubMed PMID: 21368085].
- [86] Schrag AE, Mehta AR, Bhatia KP, Brown RJ, Frackowiak RS, Trimble MR, et al. The functional neuroimaging correlates of psychogenic versus organic dystonia. *Brain* 2013;136(Pt 3):770–81 [PubMed PMID: 23436503. Pubmed Central PMCID: 3580272].
- [87] Soon CS, Brass M, Heinze HJ, Haynes JD. Unconscious determinants of free decisions in the human brain. *Nat Neurosci* 2008;11(5):543–5 [PubMed PMID: 18408715].
- [88] Spiegel D. Neurophysiological correlates of hypnosis and dissociation. *J Neuropsychiatry Clin Neurosci* 1991;3:440–5.
- [89] Spiegel D, Loewenstein RJ, Lewis-Fernandez R, Sar V, Simeon D, Vermetten E, et al. Dissociative disorders in DSM-5. *Depress Anxiety* 2011;28(9):824–52 [PubMed PMID: 21910187].
- [90] Stern DB. Psychogenic somatic symptoms on the left side: review and interpretation. In: Myslobodsky MS, editor. *Hemisyndromes: psychobiology, neurology, psychiatry*. New York: Academic Press; 1983. p. 415–45.
- [91] Sterpenich V, Albouy G, Boly M, Vandewalle G, Darsaud A, Balteau E, et al. Sleep-related hippocampo-cortical interplay during emotional memory recollection. *PLoS Biol* 2007;5(11):e282 [PubMed PMID: 17958471. Pubmed Central PMCID: 2039770].
- [92] Stone J, Carson A. Functional neurologic symptoms: assessment and management. *Neurol Clin* 2011;29(1):1–18 [vii. PubMed PMID: 21172567].
- [93] Stone J, Carson A, Duncan R, Roberts R, Coleman R, Warlow C, et al. Which neurological diseases are most likely to be associated with “symptoms unexplained by organic disease”. *J Neurol* 2012;259(1):33–8 [PubMed PMID: 21674198].
- [94] Stone J, Sharpe M, Carson A, Lewis SC, Thomas B, Goldbeck R, et al. Are functional motor and sensory symptoms really more frequent on the left? A systematic review. *J Neurol Neurosurg Psychiatry* 2002;73(5):578–81 [PubMed PMID: 12397155].
- [95] Stone J, Vuilleumier P, Friedman JH. Conversion disorder: separating “how” from “why”. *Neurology* 2010;74(3):190–1 [PubMed PMID: 20083794].
- [96] Stone J, Warlow C, Sharpe M. The symptom of functional weakness: a controlled study of 107 patients. *Brain* 2010;133(Pt 5):1537–51 [PubMed PMID: 20395262].
- [97] Stone J, Zeman A, Simonotto E, Meyer M, Azuma R, Flett S, et al. fMRI in patients with motor conversion symptoms and controls with simulated weakness. *Psychosom Med* 2007;69(9):961–9 [PubMed PMID: 17991812].
- [98] Thomas-Anterion C, Guedj E, Decoux M, Laurent B. Can we see personal identity loss? A functional imaging study of typical “hysterical amnesia”. *J Neurol Neurosurg Psychiatry* 2010;81(4):468–9 [PubMed PMID: 20360169].
- [99] Tremblay F, Leonard G, Tremblay L. Corticomotor facilitation associated with observation and imagery of hand actions is impaired in Parkinson's disease. *Exp Brain Res* 2008;185(2):249–57 [PubMed PMID: 17926025].
- [100] Vincent JL, Patel GH, Fox MD, Snyder AZ, Baker JT, Van Essen DC, et al. Intrinsic functional architecture in the anaesthetized monkey brain. *Nature* 2007;447(7140):83–6 [PubMed PMID: 17476267].
- [101] Voon V, Brezing C, Gallea C, Ameli R, Roelofs K, LaFrance Jr WC, et al. Emotional stimuli and motor conversion disorder. *Brain* 2010;133(Pt 5):1526–36 [PubMed PMID: 20371508. Pubmed Central PMCID: 2859149].
- [102] Voon V, Brezing C, Gallea C, Hallett M. Aberrant supplementary motor complex and limbic activity during motor preparation in motor conversion disorder. *Mov Disord* 2011;26(13):2396–403 [PubMed PMID: 21935985].
- [103] Voon V, Ekanayake V, Wiggs E, Kranick S, Ameli R, Harrison NA, et al. Response inhibition in motor conversion disorder. *Mov Disord* 2013;28(5):612–8 [PubMed PMID: 23554084].
- [104] Vuilleumier P. Hysterical conversion and brain function. *Prog Brain Res* 2005;150:309–29 [PubMed PMID: 16186033].
- [105] Vuilleumier P. The neurophysiology of self-awareness disorders in conversion hysteria. In: Laureys S, Tononi G, editors. *The neurology of consciousness*. 2008. p. 282–302.
- [106] Vuilleumier P, Chicherio C, Assal F, Schwartz S, Slosman D, Landis T. Functional neuroanatomical correlates of hysterical sensorimotor loss. *Brain* 2001;124(Pt 6):1077–90 [PubMed PMID: 11353724].
- [107] Vuilleumier P, Vocat R. Neuroanatomy of impaired body awareness in anosognosia and hysteria: a multi-component account. In: Prigatano GP, editor. *Advances in the study of anosognosia*. Oxford: Oxford University Press; 2010. p. 359–403.

- [108] Ward NS, Oakley DA, Frackowiak RS, Halligan PW. Differential brain activations during intentionally simulated and subjectively experienced paralysis. *Cognit Neuropsychiatry* 2003;8(4):295–312 [PubMed PMID: 16571568].
- [109] Werring DJ, Weston L, Bullmore ET, Plant GT, Ron MA. Functional magnetic resonance imaging of the cerebral response to visual stimulation in medically unexplained visual loss. *Psychol Med* 2004;34(4):583–9 [PubMed PMID: 15099413].
- [110] Whitlock FA. The aetiology of hysteria. *Acta Psychiatrica Scandinavica* 1967;43:144–62.
- [111] Xue G, Aron AR, Poldrack RA. Common neural substrates for inhibition of spoken and manual responses. *Cereb Cortex* 2008;18(8):1923–32 [PubMed PMID: 18245044].